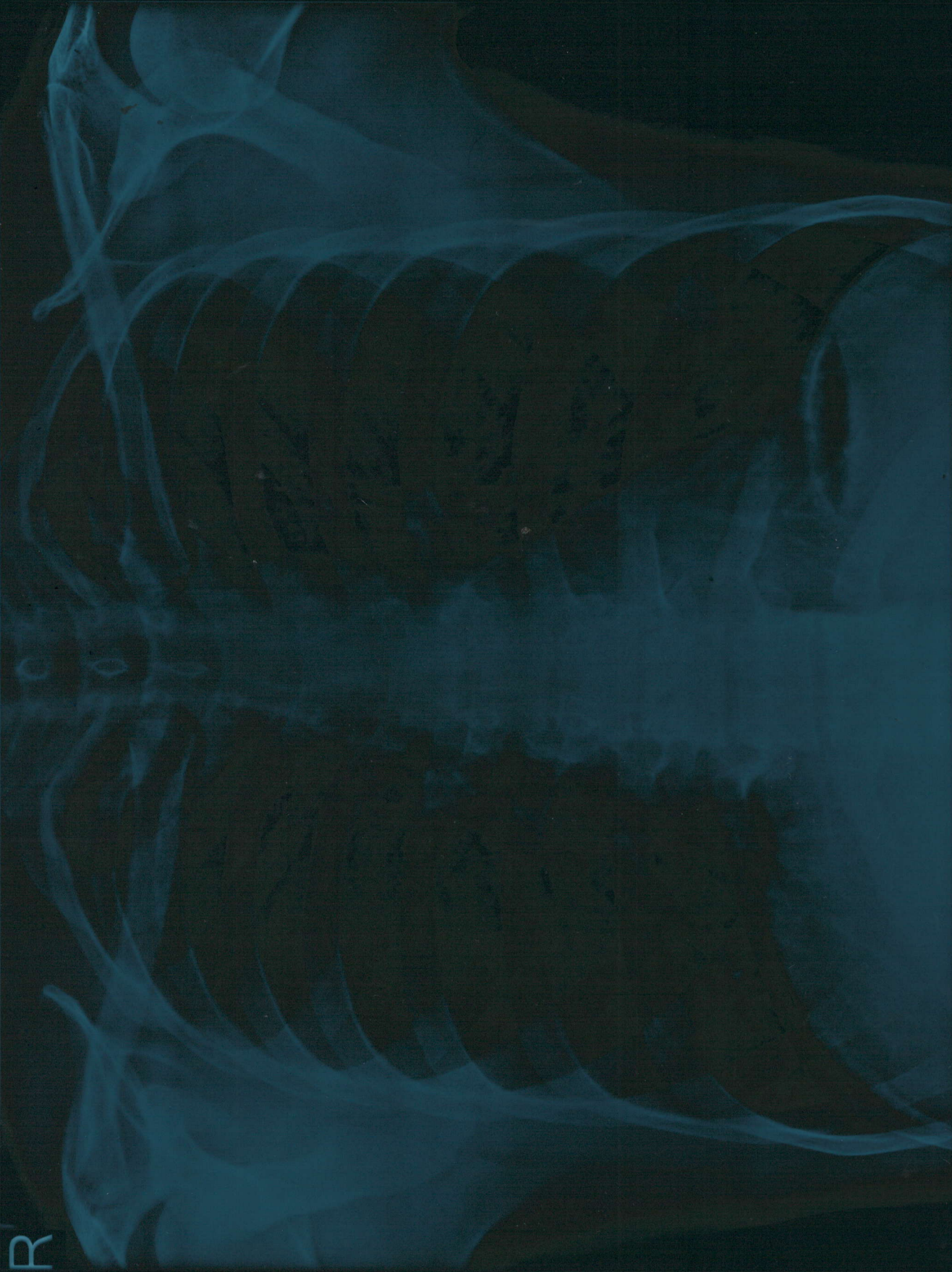


R



MR. AVNESH KUMAR ROY M/32 YRS CHEST PA 8/28/2021
SUBURBAN DIAGNOSTIC PIMPLE SAUDAGAR

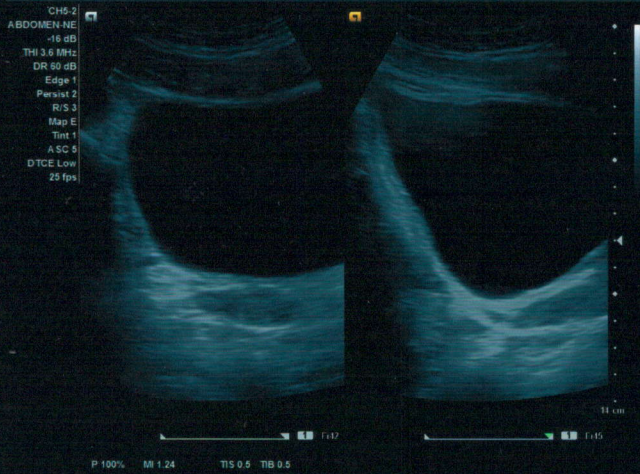
SUBURBAN DIAGNOSTIC CENTRE

Name : AVINESH KUMAR 032Y / M

28 Aug 2021 Study : Abd

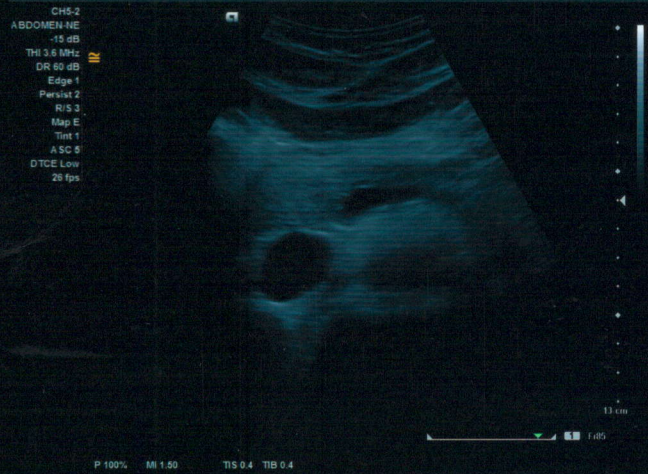
SUBURBAN DIAGNOSTICS 10:49:53 Sa 28/08/2021

AVINESH KUMAR 32Years M 28_08_2021_10_49_02



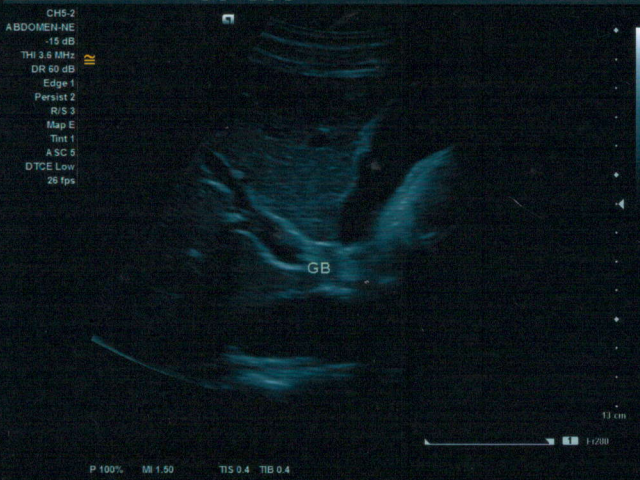SUBURBAN DIAGNOSTICS 10:50:27 Sa 28/08/2021

AVINESH KUMAR 32Years M 28_08_2021_10_49_02



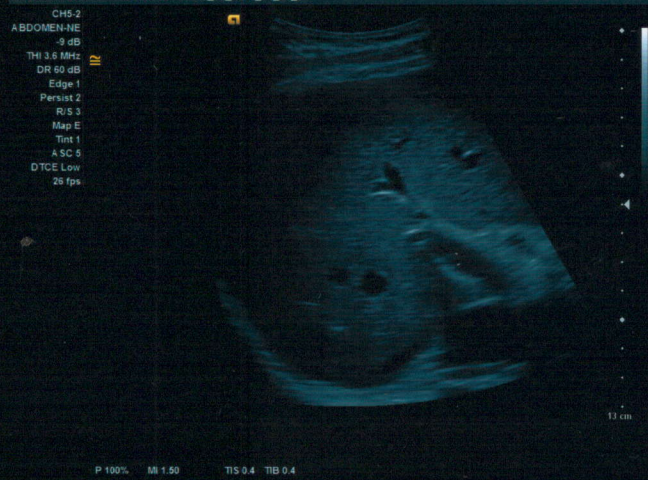SUBURBAN DIAGNOSTICS 10:50:43 Sa 28/08/2021

AVINESH KUMAR 32Years M 28_08_2021_10_49_02



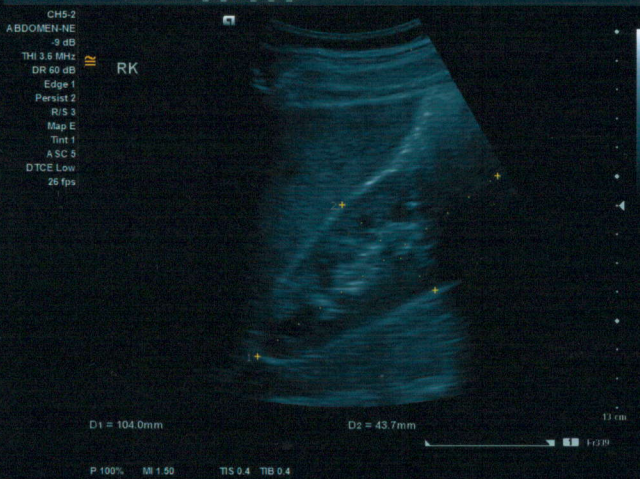SUBURBAN DIAGNOSTICS 10:50:53 Sa 28/08/2021

AVINESH KUMAR 32Years M 28_08_2021_10_49_02



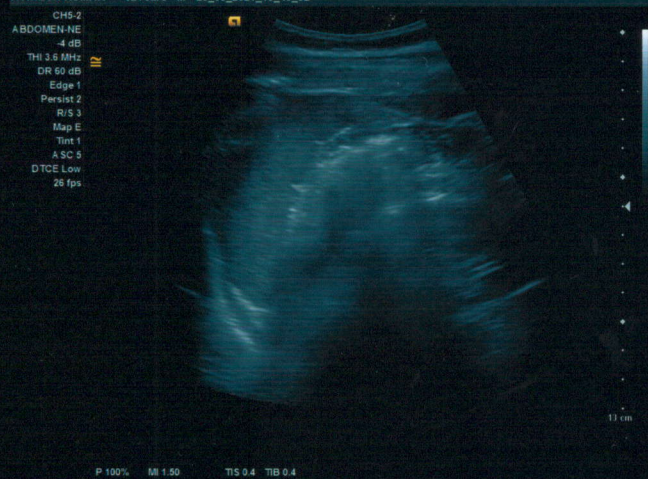SUBURBAN DIAGNOSTICS 10:51:35 Sa 28/08/2021

AVINESH KUMAR 32Years M 28_08_2021_10_49_02



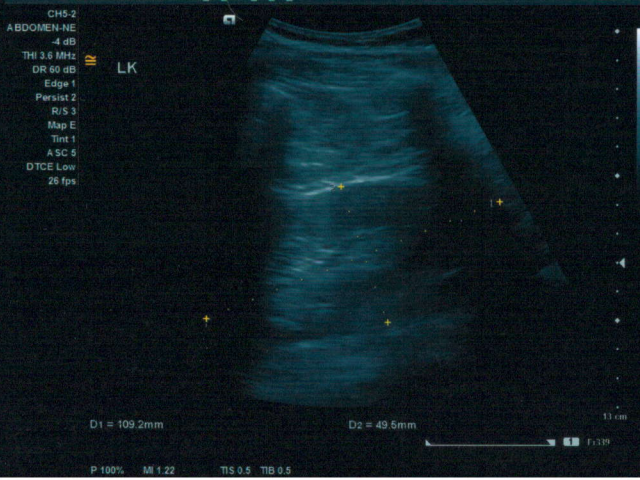
SUBURBAN DIAGNOSTICS 10:52:15 Sa 28/08/2021

AVINESH KUMAR 32Years M 28_08_2021_10_49_02



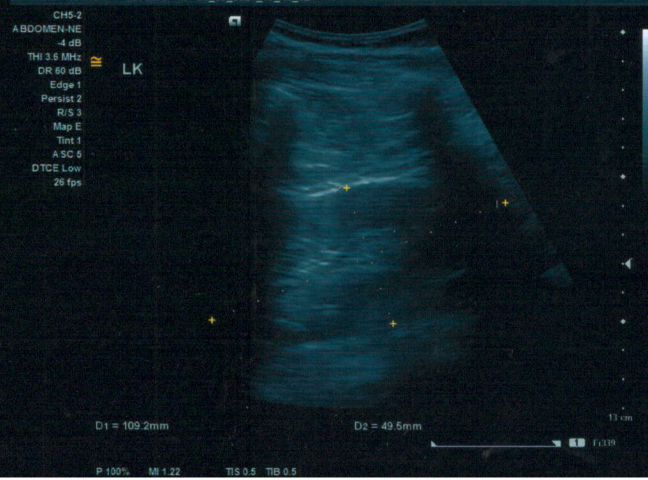
SUBURBAN DIAGNOSTICS 10:54:15 Sa 28/08/2021

AVINESH KUMAR 32Years M 28_08_2021_10_49_02



SUBURBAN DIAGNOSTICS 10:54:15 Sa 28/08/2021

AVINESH KUMAR 32Years M 28_08_2021_10_49_02



28.8.21

PHY2.

History and Complaints:

COVID - April '21 - ↓ home isolation

EXAMINATION FINDINGS:

Height (cms): <i>178</i>	Weight (kg): <i>75</i>	BMI: <i>23.7</i>
Temp (0c): <i>Afebrile</i>	Skin: <i>Normal</i>	<i>gms</i>
Blood Pressure (mm/hg): <i>130/80</i>	Nails: <i>Healthy</i>	
Pulse: <i>74</i>	Lymph Node: <i>Not Palpable</i>	

Systems

Cardiovascular: *S1,S2 Normal No Murmurs*
 Respiratory: *Air Entry Bilaterally Equal*
 Genitourinary: *Normal*
 GI System: *Soft non tender No Organomegaly*
 CNS: *Normal*

IMPRESSION:

FSS
↑ in LDL chol, TGS, non-HDL chol.

ADVICE:


Regular exercise, diet mod.

CHIEF COMPLAINTS:

1)	Hypertension:	<i>NIL</i>
2)	IHD:	
3)	Arrhythmia:	
4)	Diabetes Mellitus :	
5)	Tuberculosis :	
6)	Asthama:	
7)	Pulmonary Disease :	

8)	Thyroid/ Endocrine disorders :	
9)	Nervous disorders :	
10)	GI system :	
11)	Genital urinary disorder :	
12)	Rheumatic joint diseases or symptoms :	NIL
13)	Blood disease or disorder :	
14)	Cancer/lump growth/cyst :	
15)	Congenital disease :	
16)	Surgeries :	
PERSONAL HISTORY:		
1)	Alcohol	once a month / 250ml / No
2)	Smoking	No
3)	Diet	Mixed
4)	Medication	No

BASIC ENT - WNL
No lateralization
AC > BC



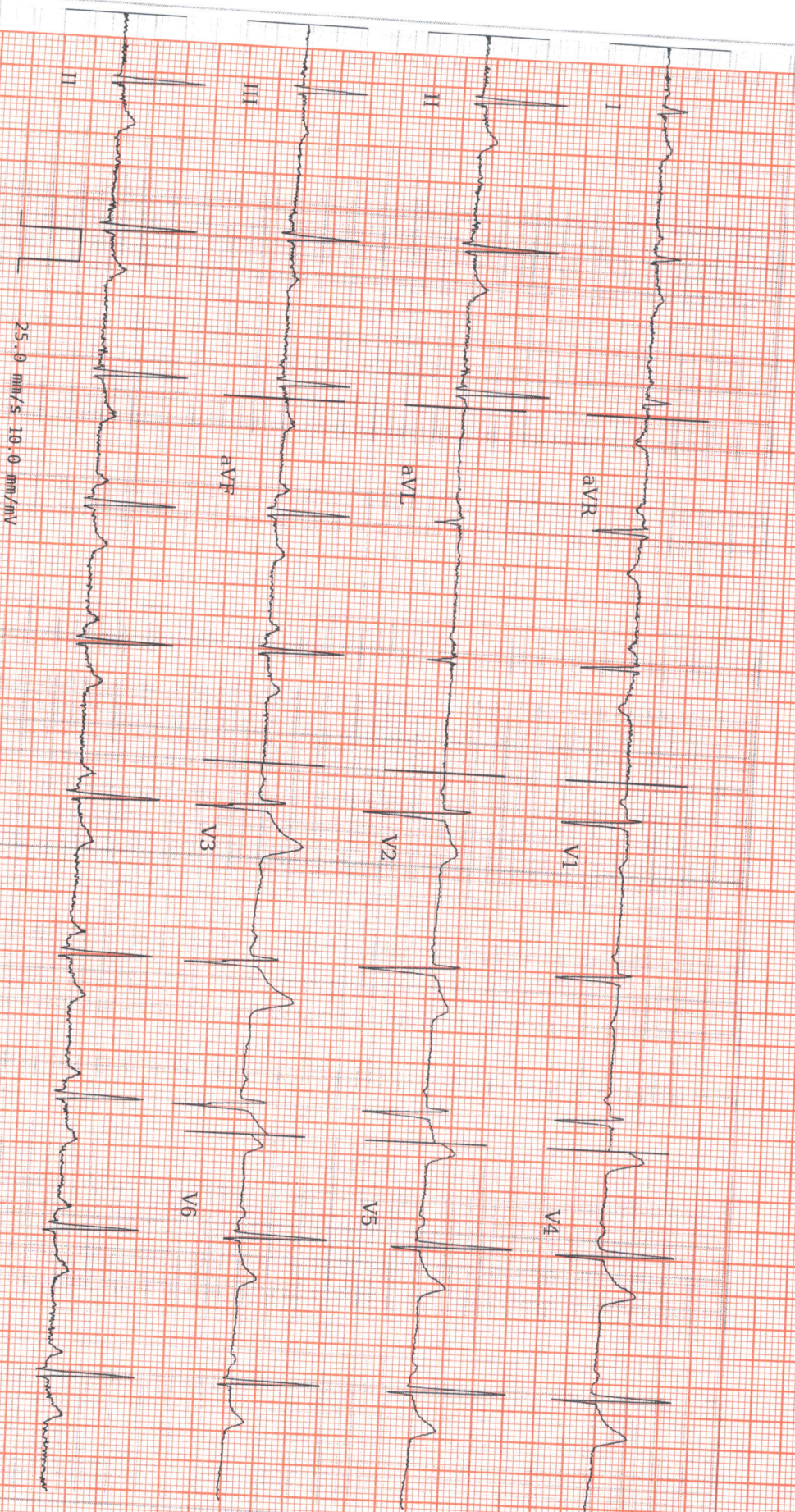
Dr. KRUTIKA INGLE

MBBS, D.DM, PG in Diabetology (USA)
MMC Regd - 2012 103018

SUBURBAN DIAGNOSTICS - PIMPLE SAUDAGAR, PUNE

Patient Name: AVNESH KUMAR ROY
Patient ID: 2124037437

Date and Time: 28th Aug 21 9:53 AM



Age 32 NA 26
years months days

Gender Male

Heart Rate 64 bpm

Patient Vitals

BP: 130/80 mmHg
Weight: 75 kg
Height: 178 cm
Pulse: 74 bpm
SpO2: NA
Resp: NA
Others:

Measurements

OSRD: 78 ms
QT: 392 ms
QTc: 404 ms
PR: 154 ms
P-R-T: 74° 76° 66°

REPORTED BY

DR. KRUTIKA INGLE

SUBURBAN DIAGNOSTIC (I) PVT. LTD
"Fortuna" Ground Floor, Near Shivkar Garden Chowk, Next to Radha Krishna Hotel, Pimple Saudagar, Pune-411 027.

DR. KRUTIKA INGLE
MBBS, D.DM, Pg in Diabetology (USA)
MMC Regd - 2012 103018

DR. KRUTIKA INGLE
MBBS, D.DM, Pg in Diabetology (USA)
2012103018

Disclaimer: This report is based on ECG data and should be used as an advisory only. It is not intended to be used as a substitute for a qualified physician's (2) patient's vital signs and other test results. The clinician and not derived from this ECG.

Name: Arvish Kumar Roy

Date: 28.8.21

Age/sex: 32/M

VISION

EYE EXAMINATION

Distance Vision Without Glasses	Right Eye	<u>(N)</u>	Left Eye	<u>(N)</u>
Distance Vision With Glasses	Right Eye	<u>—</u>	Left Eye	<u>—</u>
Near Vision Without Glasses	Right Eye	<u>(N)</u>	Left Eye	<u>(N)</u>
Near Vision With Glasses	Right Eye	<u>—</u>	Left Eye	<u>—</u>

GENERAL EXAMINATION:

LIDS
CORNEA
CONJUNCTIVAE
EYE MOVEMENTS
COLOUR VISION

Normal

Krutika Ingle

Dr. KRUTIKA INGLE

MBBS, D.DM, PG in Diabetology (USA)
MMC Regd - 2012 103018

CID	: 2124037437	SID	: 177804077404
Name	: MR.AVNESH KUMAR ROY	Registered	: 28-Aug-2021 / 09:24
Age / Gender	: 32 Years/Male	Collected	: 28-Aug-2021 / 09:24
Ref. Dr	: -	Reported	: 28-Aug-2021 / 12:14
Reg.Location	: Pimple Saudagar, Pune (Main Centre)	Printed	: 28-Aug-2021 / 12:16

USG WHOLE ABDOMEN

Gaseous Abdomen

Liver is normal in size, shape and shows normal echogenicity. No focal lesion seen. Intrahepatic biliary radicals and portal vein appear normal. CBD appears normal.

Gall bladder is well distended with normal wall thickness.

Pancreas appears normal in size, shape and echopattern. No focal lesion seen.

Spleen appears normal in size, shape & echopattern. No focal lesion seen.

Right Kidney - 10.4 x 4.8cm.

Left Kidney - 10.9 x 4.9cm.

Both kidneys appear normal in size, shape, position & echopattern with maintained C-M differentiation. No signs of obstruction or large calculus are seen.

Ureters are not dilated.

Urinary bladder is well distended & shows normal wall with clear contents.

Prostate is normal in size, shape and echopattern. No focal lesion seen.

No e/o free fluid in abdomen or pelvis.

No abnormal bowel dilatation or wall thickening is seen.

CONCLUSION:

· **NO SIGNIFICANT ABNORMALITY IS NOTED.**

*** End Of Report ***



DR.RUJUTA RAJESH SAWANT
M.B.B.S D.M.R.E
RADIOLOGIST

CID : 2124037437
Name : MR.AVNESH KUMAR ROY
Age / Gender : 32 Years/Male
Ref. Dr : -
Reg.Location : Pimple Saudagar, Pune (Main Centre)

SID : 177804077404
Registered : 28-Aug-2021 / 09:24
Collected : 28-Aug-2021 / 09:24
Reported : 28-Aug-2021 / 12:16
Printed : 28-Aug-2021 / 12:17

X-RAY CHEST PA VIEW

There is no evidence of any parenchymal lesion in either lung.

Both lung fields are clear.

Cardio-aortic silhouette has a normal appearance.

Diaphragmatic domes have normal contours and positions.

There is no evidence of any pleural effusion.

Bony thorax and soft-tissues are normal.

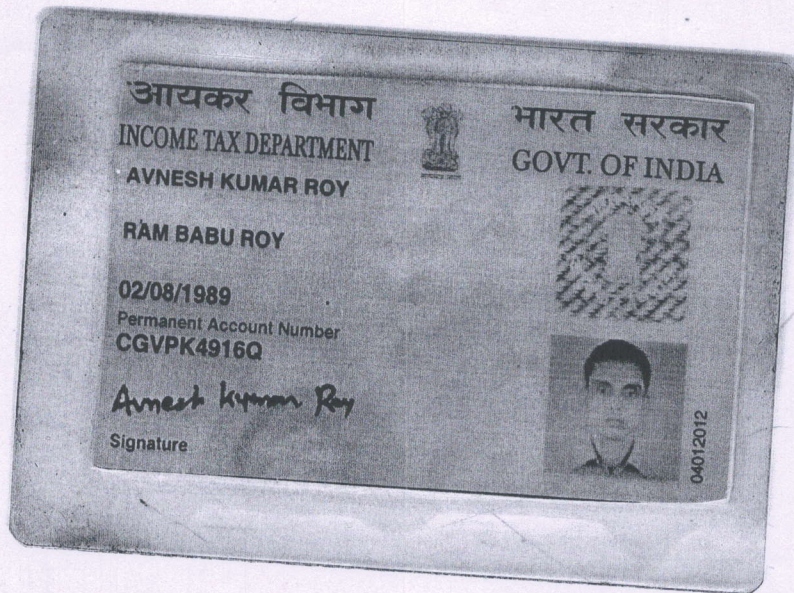
CONCLUSION:

· NORMAL CHEST X-RAY.

*** End Of Report ***



Dr.RUJUTA RAJESH SAWANT
M.B.B.S D.M.R.E
RADIOLOGIST



(Handwritten signature)

SUBURBAN DIAGNOSTIC (I) PVT. LTD.
"Fortuna" Ground Floor, Near Shivar
Garden Chowk, Next to Radha Krishna
Hotel, Pimple Saudagar, Pune-411 027.