

MR. NO- FSIN.0000000

SEX-MALE

NAME: -MR.SAIKAT BERA

EXAMINATION DATE- 26.06.2021

AGE- 28 YRS

REPORT DATE- 26.06.2021

REF DR. SELF

**FINDINGS:**

- Bilateral lung fields are clear.
- Tracheal shadow is in the midline.
- Bilateral CP angle are clear
- Both hilum appear normal .
- CTR appears normal .
- No definite bone fracture is noted.

  
**DR. ARNAB MANDAL**

MD, Physician, PGDUS (Delhi) CEBT-USG (WBUHS KOLKATA)  
Fellow of Jefferson Ultrasound Radiology and Education Institute  
Philadelphia Ex-Radiology Resident (S.E.Railway)  
Regd.No:72022(WBMC)

|                             |                        |                         |
|-----------------------------|------------------------|-------------------------|
| <b>NAME: MR.SAIKAT BERA</b> | <b>AGE:29YRS</b>       | <b>SEX:MALE</b>         |
| <b>REF BY: CORPORATE</b>    | <b>MR NO:FSIN-0000</b> | <b>DATE: 26.06.2021</b> |

**ULTRASOUND OF WHOLE ABDOMEN**

**LIVER:** Liver is **Enlarged Moderate fatty changes seen**. The intrahepatic tubular structures are normal. No focal area of altered echogenicity is noted. The porta hepatis is normal. The common bile duct at porta measures **0.31cm**. The portal vein measures **0.85cm** at porta.

**GALL BLADDER:** Gall bladder is distended. Wall is normal limits. No calculus or mass is seen within the gall bladder.

**PANCREAS:** It is normal in size, Shape, Outline and echotexture. Pancreatic duct is not dilated.

**SPLEEN:** Spleen in normal size **10.49cm**, Shape, Outline and echotexture. No parenchymal lesion is noted.

**RIGHT KIDNEY:** kidneys are normal in position, size, shape, outline and echotexture. The cortico medullary differentiation is maintained. No calculus or hydronephrosis is seen.

**RIGHT KIDNEY:** measures – **9.07cm**.

**LEFT KIDNEY:** kidneys are normal in position, size, shape, outline and echotexture. The cortico medullary differentiation is maintained. No calculus or hydronephrosis is seen.


**LEFT KIDNEY:** measures – **9.47cm**.

**URINARY BLADDER:** : It is well distended with normal wall thickness. No calculus or mass is seen within the urinary bladder. The post void residual volume of urine is insignificant.

**PROSTATE:** It is normal in size, Shape & homogenous echotexture. The prostatic outline is smooth. The periprostatic plane is normal. It is normal size measures (**2.63cmX2.83cmX2.97cm**)  
**Vol-11.58ml**.

**IMPRESSION:**

- **HEPATOMEGALY WITH MODERATE FATTY CHANGES. MBBS, MD.**

  
**DR.SUSMITA CHOWDHURY**

**CONSULTANT SONOLOGIST**



Patient Name: Mr. SAIKAT BERA 28/M

Resting ECG Report

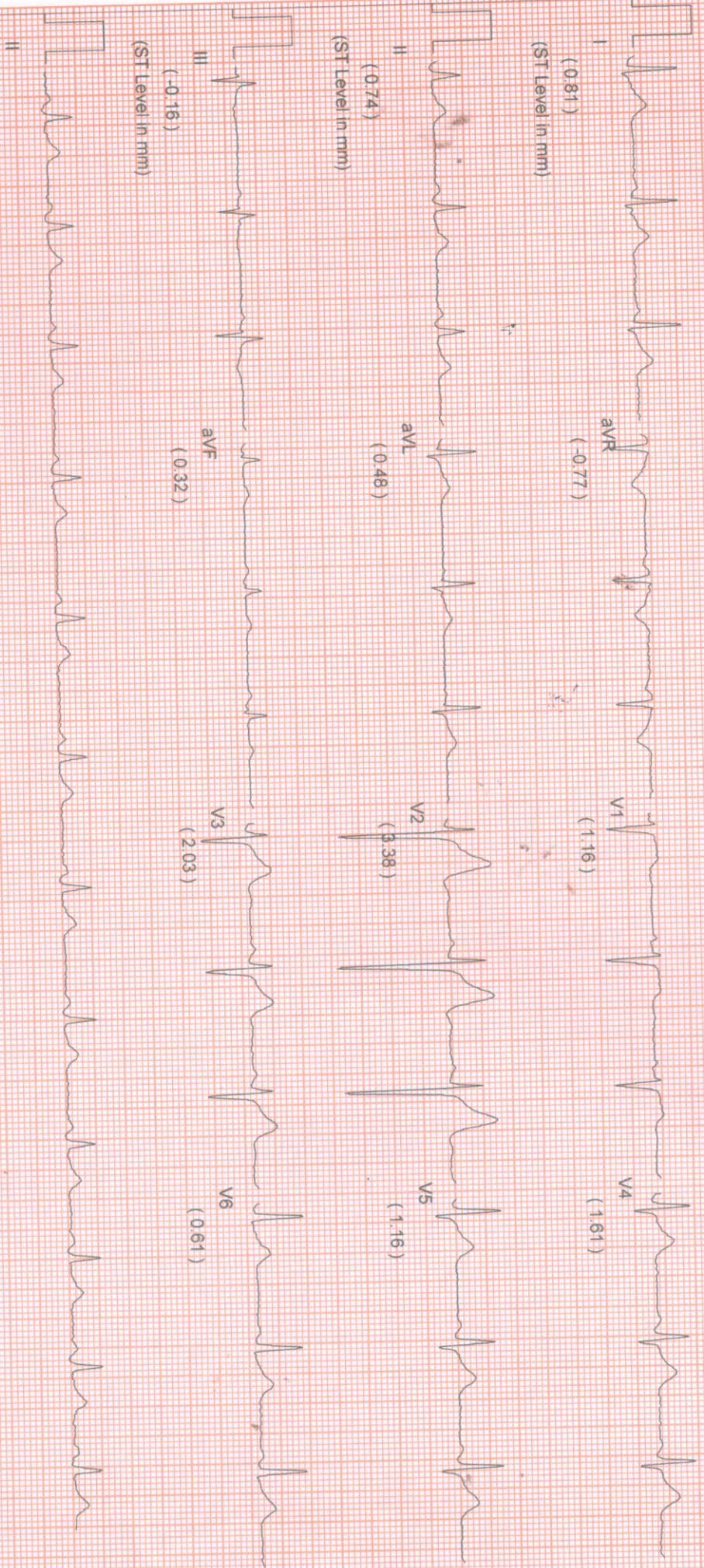
June 26, 2021  
Time: 11:36:53

QT / QTc : 0.376 / 0.409 Sec  
P-QRS-T Axis (36)-(1)-(18) deg

PR Interval: 0.14 sec  
QRS Duration: 0.092 Sec

RR Interval: 0.84 sec

HR : 70 bpm    BP : 120 / 80 mmHg



Comments :-

*Dr. Suman*  
net report


|                            |                         |                                |
|----------------------------|-------------------------|--------------------------------|
| <b>NAME:MR.SAIKAT BERA</b> | <b>MR NO: FSIN-0000</b> | <b>DATE : 26.06.2021</b>       |
| <b>AGE: 28YRS.</b>         | <b>SEX:MALE</b>         | <b>REF BY:SELF (CORPORATE)</b> |

ECG REPORT

HR : 70 b/min  
AXIS : NORMAL  
RHYTHM : SINUS  
PR INTERVAL : 0.14 sec  
QT INTERVAL : 0.409 sec  
QRS DURATION : 0.092 sec  
T-WAVE : NORMAL

IMPRESSION:

- RESTING ECG IS WITHIN NORMAL LIMITS.

  
**Dr. SIDDHARTHA KUNDU**  
MBBS (Cal), PGDCC, CCEBDM  
Clinical Cardiologist  
Ex Sr Resident, Cardiology Dept  
B.R Singh Hospital, Eastern Railway

**APOLLO CLINIC @ OM TOWER**  
Opp. of Rabindra Bharati University  
**Licensee : Satyam Credit Pvt. Ltd.**  
36C, B. T. Road, Kolkata - 700 002  
E-mail : [sinthimor@theapolloclinic.com](mailto:sinthimor@theapolloclinic.com)  
[satyamcreditpvtltd@gmail.com](mailto:satyamcreditpvtltd@gmail.com)



033 2556 3333



033 2556 5555



+91 98521 66666



+91 74392 97827