

Patient Name : Mrs.RACHNA SINGH	Collected : 24/Jun/2023 09:16AM
Age/Gender : 29 Y 6 M 16 D/F	Received : 24/Jun/2023 10:23AM
UHID/MR No : CKON.0000411704	Reported : 24/Jun/2023 11:11AM
Visit ID : CKONOPV586760	Status : Final Report
Ref Doctor : Dr.SELF	Sponsor Name : ARCOFEMI HEALTHCARE LIMITED
Emp/Auth/TPA ID : 204329925156	

DEPARTMENT OF HAEMATOLOGY

ARCOFEMI - MEDIWHEEL - FULL BODY ANNUAL PLUS CHECK ADVANCED - FEMALE - 2D ECHO - PAN INDIA - FY2324

Test Name	Result	Unit	Bio. Ref. Range	Method
-----------	--------	------	-----------------	--------

HEMOGRAM , WHOLE BLOOD-EDTA

HAEMOGLOBIN	14.2	g/dL	12-15	Spectrophotometer
PCV	42.50	%	36-46	Electronic pulse & Calculation
RBC COUNT	4.57	Million/cu.mm	3.8-4.8	Electrical Impedence
MCV	93	fL	83-101	Calculated
MCH	31.1	pg	27-32	Calculated
MCHC	33.5	g/dL	31.5-34.5	Calculated
R.D.W	12.6	%	11.6-14	Calculated
TOTAL LEUCOCYTE COUNT (TLC)	5,900	cells/cu.mm	4000-10000	Electrical Impedence

DIFFERENTIAL LEUCOCYTIC COUNT (DLC)

NEUTROPHILS	55	%	40-80	Electrical Impedence
LYMPHOCYTES	35	%	20-40	Electrical Impedence
EOSINOPHILS	04	%	1-6	Electrical Impedence
MONOCYTES	06	%	2-10	Electrical Impedence
BASOPHILS	00	%	<1-2	Electrical Impedence

ABSOLUTE LEUCOCYTE COUNT

NEUTROPHILS	3245	Cells/cu.mm	2000-7000	Electrical Impedence
LYMPHOCYTES	2065	Cells/cu.mm	1000-3000	Electrical Impedence
EOSINOPHILS	236	Cells/cu.mm	20-500	Electrical Impedence
MONOCYTES	354	Cells/cu.mm	200-1000	Electrical Impedence
PLATELET COUNT	159000	cells/cu.mm	150000-410000	Electrical impedence

ERYTHROCYTE SEDIMENTATION RATE (ESR)	08	mm at the end of 1 hour	0-20	Modified Westergren
---	----	-------------------------	------	---------------------

PERIPHERAL SMEAR

RBCs ARE NORMOCYTIC NORMOCHROMIC.

TLC , DLC WITHIN NORMAL LIMIT. NO IMMATURE CELLS ARE SEEN.

PLATELETS ARE ADEQUATE.

NO HEMOPARASITES SEEN

SIN No:BED230145208

Apollo Health and Lifestyle Limited (CIN - U85110TG2000PLC115819)

Regd. Office: 1-10-60/62, Ashoka Raghupathi Chambers, 5th Floor, Begumpet, Hyderabad, Telangana - 500 016 | www.apollohl.com | Email ID: enquiry@apollohl.com, Ph No: 040-4904 7777, Fax No: 4904 7744

APOLLO CLINICS NETWORK

Telangana: Hyderabad (AS Rao Nagar | Chanda Nagar | Kondapur | Nallakunta | Nizampet | Manikonda | Uppal) Andhra Pradesh: Vizag (Seethamma Peta) Karnataka: Bangalore (Basavanagudi | Bellandur | Electronics City | Fraser Town | HSR Layout | Indira Nagar | JP Nagar | Kundalahalli | Koramangala | Sarjapur Road) Mysore (VV Mohalla) Tamilnadu: Chennai (Annanagar | Kotturpuram | Mogappair | T Nagar | Valasaravakkam | Velachery) Maharashtra: Pune (Aundh | Nigdi Pradhikaran | Viman Nagar | Wanowrie) Uttar Pradesh: Ghaziabad (Indrapuram) Gujarat: Ahmedabad (Satellite) Punjab: Amritsar (Court Road) Haryana: Faridabad (Railway Station Road)

Address:
The Apollo Medical Centre, 2-20/6/A, Kothaguda X Roads, Kondapur,
Hyderabad, Telangana, India - 500032



Patient Name : Mrs.RACHNA SINGH	Collected : 24/Jun/2023 09:16AM
Age/Gender : 29 Y 6 M 16 D/F	Received : 24/Jun/2023 10:23AM
UHID/MR No : CKON.0000411704	Reported : 24/Jun/2023 01:51PM
Visit ID : CKONOPV586760	Status : Final Report
Ref Doctor : Dr.SELF	Sponsor Name : ARCOFEMI HEALTHCARE LIMITED
Emp/Auth/TPA ID : 204329925156	

DEPARTMENT OF HAEMATOLOGY

ARCOFEMI - MEDIWHEEL - FULL BODY ANNUAL PLUS CHECK ADVANCED - FEMALE - 2D ECHO - PAN INDIA - FY2324

Test Name	Result	Unit	Bio. Ref. Range	Method
-----------	--------	------	-----------------	--------

BLOOD GROUP ABO AND RH FACTOR , WHOLE BLOOD-EDTA

BLOOD GROUP TYPE	B			Forward & Reverse Grouping with Slide/Tube Aggluti
Rh TYPE	POSITIVE			Forward & Reverse Grouping with Slide/Tube Agglutination

SIN No:BED230145208

Apollo Health and Lifestyle Limited (CIN - U85110TG2000PLC115819)

Regd. Office: 1-10-60/62, Ashoka Raghupathi Chambers, 5th Floor, Begumpet, Hyderabad, Telangana - 500 016 | www.apollohl.com | Email ID: enquiry@apollohl.com, Ph No: 040-4904 7777, Fax No: 4904 7744

APOLLO CLINICS NETWORK

Telangana: Hyderabad (AS Rao Nagar | Chanda Nagar | Kondapur | Nallakunta | Nizampet | Manikonda | Uppal) Andhra Pradesh: Vizag (Seethamma Peta) Karnataka: Bangalore (Basavanagudi | Bellandur | Electronics City | Fraser Town | HSR Layout | Indira Nagar | JP Nagar | Kundalahalli | Koramangala | Sarjapur Road) Mysore (VV Mohalla) Tamilnadu: Chennai (Annanagar | Kotturpuram | Mogappair | T Nagar | Valasaravakkam | Velachery) Maharashtra: Pune (Aundh | Nigdi Pradhikaran | Viman Nagar | Wanowrie) Uttar Pradesh: Ghaziabad (Indrapuram) Gujarat: Ahmedabad (Satellite) Punjab: Amritsar (Court Road) Haryana: Faridabad (Railway Station Road)

Address:
The Apollo Medical Centre, 2-20/6/A, Kothaguda X Roads, Kondapur, Hyderabad, Telangana, India - 500032



1860 500 7788
www.apolloclinic.com

Patient Name : Mrs.RACHNA SINGH	Collected : 24/Jun/2023 09:16AM
Age/Gender : 29 Y 6 M 16 D/F	Received : 24/Jun/2023 10:07AM
UHID/MR No : CKON.0000411704	Reported : 24/Jun/2023 10:12AM
Visit ID : CKONOPV586760	Status : Final Report
Ref Doctor : Dr.SELF	Sponsor Name : ARCOFEMI HEALTHCARE LIMITED
Emp/Auth/TPA ID : 204329925156	

DEPARTMENT OF BIOCHEMISTRY

ARCOFEMI - MEDIWHEEL - FULL BODY ANNUAL PLUS CHECK ADVANCED - FEMALE - 2D ECHO - PAN INDIA - FY2324

Test Name	Result	Unit	Bio. Ref. Range	Method
-----------	--------	------	-----------------	--------

GLUCOSE, FASTING , NAF PLASMA	100	mg/dL	70-100	GOD - POD
-------------------------------	-----	-------	--------	-----------

Comment:

As per American Diabetes Guidelines

Fasting Glucose Values in mg/d L	Interpretation
<100 mg/dL	Normal
100-125 mg/dL	Prediabetes
≥126 mg/dL	Diabetes

SIN No:PLF01989925

Apollo Health and Lifestyle Limited (CIN - U85110TG2000PLC115819)

Regd. Office: 1-10-60/62, Ashoka Raghupathi Chambers, 5th Floor, Begumpet, Hyderabad, Telangana - 500 016 | www.apollohl.com | Email ID: enquiry@apollohl.com, Ph No: 040-4904 7777, Fax No: 4904 7744

APOLLO CLINICS NETWORK

Telangana: Hyderabad (AS Rao Nagar | Chanda Nagar | Kondapur | Nallakunta | Nizampet | Manikonda | Uppal) Andhra Pradesh: Vizag (Seethamma Peta) Karnataka: Bangalore (Basavanagudi | Bellandur | Electronics City | Fraser Town | HSR Layout | Indira Nagar | JP Nagar | Kundalahalli | Koramangala | Sarjapur Road) Mysore (VV Mohalla) Tamilnadu: Chennai (Annanagar | Kotturpuram | Mogappair | T Nagar | Valasaravakkam | Velachery) Maharashtra: Pune (Aundh | Nigdi Pradhikaran | Viman Nagar | Wanowrie) Uttar Pradesh: Ghaziabad (Indrapuram) Gujarat: Ahmedabad (Satellite) Punjab: Amritsar (Court Road) Haryana: Faridabad (Railway Station Road)

Address:
The Apollo Medical Centre, 2-20/6/A, Kothaguda X Roads, Kondapur,
Hyderabad, Telangana, India - 500032



Patient Name : Mrs.RACHNA SINGH	Collected : 25/Jun/2023 11:55AM
Age/Gender : 29 Y 6 M 17 D/F	Received : 25/Jun/2023 01:12PM
UHID/MR No : CKON.0000411704	Reported : 25/Jun/2023 01:19PM
Visit ID : CKONOPV586760	Status : Final Report
Ref Doctor : Dr.SELF	Sponsor Name : ARCOFEMI HEALTHCARE LIMITED
Emp/Auth/TPA ID : 204329925156	

DEPARTMENT OF BIOCHEMISTRY

ARCOFEMI - MEDIWHEEL - FULL BODY ANNUAL PLUS CHECK ADVANCED - FEMALE - 2D ECHO - PAN INDIA - FY2324

Test Name	Result	Unit	Bio. Ref. Range	Method
-----------	--------	------	-----------------	--------

GLUCOSE, POST PRANDIAL (PP), 2 HOURS , NAF PLASMA	79	mg/dL	70-140	GOD - POD
--	----	-------	--------	-----------

Post Prandial blood sugar is less than Fasting level due to the following causes. Inappropriate Insulin release. Post absorptive hypoglycemia Please ensure that you had taken adequate meal after giving fasting sample. Please provide clinical details.

Comment:

It is recommended that FBS and PPBS should be interpreted with respect to their Biological reference ranges and not with each other.

Conditions which may lead to lower postprandial glucose levels as compared to fasting glucose levels may be due to reactive hypoglycemia, dietary meal content, duration or timing of sampling after food digestion and absorption, medications such as insulin preparations, sulfonylureas, amylin analogues, or conditions such as overproduction of insulin.

Ref: Marks medical biochemistry and clinical approach

SIN No:PLP1342756

Apollo Health and Lifestyle Limited (CIN - U85110TG2000PLC115819)

Regd. Office: 1-10-60/62, Ashoka Raghupathi Chambers, 5th Floor, Begumpet, Hyderabad, Telangana - 500 016 | www.apollohl.com | Email ID: enquiry@apollohl.com, Ph No: 040-4904 7777, Fax No: 4904 7744

APOLLO CLINICS NETWORK

Telangana: Hyderabad (AS Rao Nagar | Chanda Nagar | Kondapur | Nallakunta | Nizampet | Manikonda | Uppal) Andhra Pradesh: Vizag (Seethamma Peta) Karnataka: Bangalore (Basavanagudi | Bellandur | Electronics City | Fraser Town | HSR Layout | Indira Nagar | JP Nagar | Kundalahalli | Koramangala | Sarjapur Road) Mysore (VV Mohalla) Tamilnadu: Chennai (Annanagar | Kotturpuram | Mogappair | T Nagar | Valasaravakkam | Velachery) Maharashtra: Pune (Aundh | Nigdi Pradhikaran | Viman Nagar | Wanowrie) Uttar Pradesh: Ghaziabad (Indrapuram) Gujarat: Ahmedabad (Satellite) Punjab: Amritsar (Court Road) Haryana: Faridabad (Railway Station Road)

Address: The Apollo Medical Centre, 2-20/6/A, Kothaguda X Roads, Kondapur, Hyderabad, Telangana, India - 500032



1860 500 7788
www.apolloclinic.com

Patient Name : Mrs.RACHNA SINGH	Collected : 24/Jun/2023 09:16AM
Age/Gender : 29 Y 6 M 16 D/F	Received : 24/Jun/2023 11:54AM
UHID/MR No : CKON.0000411704	Reported : 24/Jun/2023 01:55PM
Visit ID : CKONOPV586760	Status : Final Report
Ref Doctor : Dr.SELF	Sponsor Name : ARCOFEMI HEALTHCARE LIMITED
Emp/Auth/TPA ID : 204329925156	

DEPARTMENT OF BIOCHEMISTRY

ARCOFEMI - MEDIWHEEL - FULL BODY ANNUAL PLUS CHECK ADVANCED - FEMALE - 2D ECHO - PAN INDIA - FY2324

Test Name	Result	Unit	Bio. Ref. Range	Method
-----------	--------	------	-----------------	--------

HBA1C, GLYCATED HEMOGLOBIN , WHOLE BLOOD-EDTA	5.3	%		HPLC
ESTIMATED AVERAGE GLUCOSE (eAG) , WHOLE BLOOD-EDTA	105	mg/dL		Calculated

Comment:

Reference Range as per American Diabetes Association (ADA):

REFERENCE GROUP	HBA1C IN %
NON DIABETIC ADULTS >18 YEARS	<5.7
AT RISK (PREDIABETES)	5.7 – 6.4
DIAGNOSING DIABETES	≥ 6.5
DIABETICS	
· EXCELLENT CONTROL	6 – 7
· FAIR TO GOOD CONTROL	7 – 8
· UNSATISFACTORY CONTROL	8 – 10
· POOR CONTROL	>10

Note: Dietary preparation or fasting is not required.

1. A1C test should be performed at least two times a year in patients who are meeting treatment goals (and who have stable glycemic control).
2. Lowering A1C to below or around 7% has been shown to reduce microvascular and neuropathic complications of type 1 and type 2 diabetes. When mean annual HbA1c is <1.1 times ULN (upper limit of normal), renal and retinal complications are rare, but complications occur in >70% of cases when HbA1c is >1.7 times ULN.
3. Falsely low HbA1c (below 4%) may be observed in patients with clinical conditions that shorten erythrocyte life span or decrease mean erythrocyte age. HbA1c may not accurately reflect glycemic control when clinical conditions that affect erythrocyte survival are present. Fructosamine may be used as an alternate measurement of glycemic control

Patient Name : Mrs.RACHNA SINGH	Collected : 24/Jun/2023 09:16AM
Age/Gender : 29 Y 6 M 16 D/F	Received : 24/Jun/2023 11:54AM
UHID/MR No : CKON.0000411704	Reported : 24/Jun/2023 01:55PM
Visit ID : CKONOPV586760	Status : Final Report
Ref Doctor : Dr.SELF	Sponsor Name : ARCOFEMI HEALTHCARE LIMITED
Emp/Auth/TPA ID : 204329925156	

DEPARTMENT OF BIOCHEMISTRY

ARCOFEMI - MEDIWHEEL - FULL BODY ANNUAL PLUS CHECK ADVANCED - FEMALE - 2D ECHO - PAN INDIA - FY2324

Test Name	Result	Unit	Bio. Ref. Range	Method
-----------	--------	------	-----------------	--------

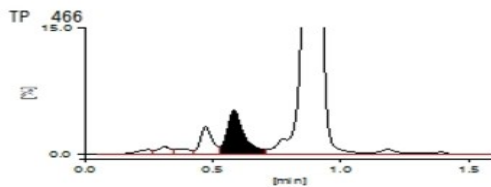
Chromatogram Report

HLC72368 V5.28 1 2023-06-24 12:45:12
 ID EDT230057807
 Sample No. 06240070 SL 0001 - 02
 Patient ID
 Name
 Comment

CALIB Name	%	Time	Area
A1A	0.4	0.24	7.05
A1B	0.6	0.31	9.85
F	0.5	0.37	7.96
LA1C+	1.8	0.47	31.67
SA1C	5.3	0.58	70.97
A0	93.1	0.88	1617.11
H-V0			
H-V1			
H-V2			

Total Area 1744.61

HbA1c 5.3 % **IFCC 35 mmol/mol**
 HbA1 6.3 % HbF 0.5 %



SIN No:EDT230057807

Apollo Health and Lifestyle Limited, Apollo Health & Lifestyle Ltd, Global Reference Laboratory, Hyderabad

Regd. Office: 1-10-60/62, Ashoka Raghupathi Chambers, 5th Floor, Begumpet, Hyderabad, Telangana - 500 016 | www.apollohl.com | Email ID: enquiry@apollohl.com, Ph No: 040-4904 7777, Fax No: 4904 7744

The Apollo Medical Centre, 2-20/6/A, Kothaguda X Roads, Kondapur, Hyderabad, Telangana, India - 500032



APOLLO CLINICS NETWORK

Telangana: Hyderabad (AS Rao Nagar | Chanda Nagar | Kondapur | Nallakunta | Nizampet | Manikonda | Uppal) Andhra Pradesh: Vizag (Seethamma Peta) Karnataka: Bangalore (Basavanagudi | Bellandur | Electronics City | Fraser Town | HSR Layout | Indira Nagar | JP Nagar | Kundalahalli | Koramangala | Sarjapur Road) Mysore (VV Mohalla) Tamil Nadu: Chennai (Annanagar | Kotturpuram | Mogappair | T Nagar | Valasaravakkam | Velachery) Maharashtra: Pune (Aundh | Nigdi Pradhikaran | Viman Nagar | Wanowrie) Uttar Pradesh: Ghaziabad (Indrapuram) Gujarat: Ahmedabad (Satellite) Punjab: Amritsar (Court Road) Haryana: Faridabad (Railway Station Road)

Patient Name : Mrs.RACHNA SINGH	Collected : 24/Jun/2023 09:16AM
Age/Gender : 29 Y 6 M 16 D/F	Received : 24/Jun/2023 12:38PM
UHID/MR No : CKON.0000411704	Reported : 24/Jun/2023 01:04PM
Visit ID : CKONOPV586760	Status : Final Report
Ref Doctor : Dr.SELF	Sponsor Name : ARCOFEMI HEALTHCARE LIMITED
Emp/Auth/TPA ID : 204329925156	

DEPARTMENT OF BIOCHEMISTRY

ARCOFEMI - MEDIWHEEL - FULL BODY ANNUAL PLUS CHECK ADVANCED - FEMALE - 2D ECHO - PAN INDIA - FY2324

Test Name	Result	Unit	Bio. Ref. Range	Method
-----------	--------	------	-----------------	--------

LIPID PROFILE , SERUM

TOTAL CHOLESTEROL	144	mg/dL	<200	CHE/CHO/POD
TRIGLYCERIDES	90	mg/dL	<150	Enzymatic
HDL CHOLESTEROL	63	mg/dL	>40	CHE/CHO/POD
NON-HDL CHOLESTEROL	81	mg/dL	<130	Calculated
LDL CHOLESTEROL	63	mg/dL	<100	Calculated
VLDL CHOLESTEROL	18	mg/dL	<30	Calculated
CHOL / HDL RATIO	2.29		0-4.97	Calculated

Comment:

Reference Interval as per National Cholesterol Education Program (NCEP) Adult Treatment Panel III Report.

	Desirable	Borderline High	High	Very High
TOTAL CHOLESTEROL	< 200	200 - 239	≥ 240	
TRIGLYCERIDES	<150	150 - 199	200 - 499	≥ 500
LDL	Optimal < 100 Near Optimal 100-129	130 - 159	160 - 189	≥ 190
HDL	≥ 60			
NON-HDL CHOLESTEROL	Optimal <130; Above Optimal 130-159	160-189	190-219	>220

Measurements in the same patient can show physiological and analytical variations.

NCEP ATP III identifies non-HDL cholesterol as a secondary target of therapy in persons with high triglycerides.

SIN No:SE04404375

Apollo Health and Lifestyle Limited (CIN - U85110TG2000PLC115819)

Regd. Office: 1-10-60/62, Ashoka Raghupathi Chambers, 5th Floor, Begumpet, Hyderabad, Telangana - 500 016 |
www.apollohl.com | Email ID: enquiry@apollohl.com, Ph No: 040-4904 7777, Fax No: 4904 7744

APOLLO CLINICS NETWORK

Telangana: Hyderabad (AS Rao Nagar | Chanda Nagar | Kondapur | Nallakunta | Nizampet | Manikonda | Uppal) Andhra Pradesh: Vizag (Seethamma Peta) Karnataka: Bangalore (Basavanagudi | Bellandur | Electronics City | Fraser Town | HSR Layout | Indira Nagar | JP Nagar | Kundalahalli | Koramangala | Sarjapur Road) Mysore (VV Mohalla) Tamilnadu: Chennai (Annanagar | Kotturpuram | Mogappair | T Nagar | Valasaravakkam | Velachery) Maharashtra: Pune (Aundh | Nigdi Pradhikaran | Viman Nagar | Wanowrie) Uttar Pradesh: Ghaziabad (Indrapuram) Gujarat: Ahmedabad (Satellite) Punjab: Amritsar (Court Road) Haryana: Faridabad (Railway Station Road)

Address:
The Apollo Medical Centre, 2-20/6/A, Kothaguda X Roads, Kondapur,
Hyderabad, Telangana, India - 500032



Patient Name : Mrs.RACHNA SINGH	Collected : 24/Jun/2023 09:16AM
Age/Gender : 29 Y 6 M 16 D/F	Received : 24/Jun/2023 12:38PM
UHID/MR No : CKON.0000411704	Reported : 24/Jun/2023 01:04PM
Visit ID : CKONOPV586760	Status : Final Report
Ref Doctor : Dr.SELF	Sponsor Name : ARCOFEMI HEALTHCARE LIMITED
Emp/Auth/TPA ID : 204329925156	

DEPARTMENT OF BIOCHEMISTRY

ARCOFEMI - MEDIWHEEL - FULL BODY ANNUAL PLUS CHECK ADVANCED - FEMALE - 2D ECHO - PAN INDIA - FY2324

Test Name	Result	Unit	Bio. Ref. Range	Method
-----------	--------	------	-----------------	--------

LIVER FUNCTION TEST (LFT) , SERUM

BILIRUBIN, TOTAL	0.50	mg/dL	0.20-1.20	DIAZO METHOD
BILIRUBIN CONJUGATED (DIRECT)	0.10	mg/dL	0.0-0.3	Calculated
BILIRUBIN (INDIRECT)	0.40	mg/dL	0.0-1.1	Dual Wavelength
ALANINE AMINOTRANSFERASE (ALT/SGPT)	14	U/L	<35	Visible with P-5-P
ASPARTATE AMINOTRANSFERASE (AST/SGOT)	20.0	U/L	14-36	UV with P-5-P
ALKALINE PHOSPHATASE	52.00	U/L	38-126	p-nitrophenyl phosphate
PROTEIN, TOTAL	7.30	g/dL	6.3-8.2	Biuret
ALBUMIN	4.00	g/dL	3.5 - 5	Bromocresol Green
GLOBULIN	3.30	g/dL	2.0-3.5	Calculated
A/G RATIO	1.21		0.9-2.0	Calculated

SIN No:SE04404375

Apollo Health and Lifestyle Limited (CIN - U85110TG2000PLC115819)

Regd. Office: 1-10-60/62, Ashoka Raghupathi Chambers, 5th Floor, Begumpet, Hyderabad, Telangana - 500 016 | www.apollohl.com | Email ID: enquiry@apollohl.com, Ph No: 040-4904 7777, Fax No: 4904 7744

APOLLO CLINICS NETWORK

Telangana: Hyderabad (AS Rao Nagar | Chanda Nagar | Kondapur | Nallakunta | Nizampet | Manikonda | Uppal) Andhra Pradesh: Vizag (Seethamma Peta) Karnataka: Bangalore (Basavanagudi | Bellandur | Electronics City | Fraser Town | HSR Layout | Indira Nagar | JP Nagar | Kundalahalli | Koramangala | Sarjapur Road) Mysore (VV Mohalla) Tamilnadu: Chennai (Annanagar | Kotturpuram | Mogappair | T Nagar | Valasaravakkam | Velachery) Maharashtra: Pune (Aundh | Nigdi Pradhikaran | Viman Nagar | Wanowrie) Uttar Pradesh: Ghaziabad (Indrapuram) Gujarat: Ahmedabad (Satellite) Punjab: Amritsar (Court Road) Haryana: Faridabad (Railway Station Road)

Address:
The Apollo Medical Centre, 2-20/6/A, Kothaguda X Roads, Kondapur,
Hyderabad, Telangana, India - 500032



Patient Name : Mrs.RACHNA SINGH	Collected : 24/Jun/2023 09:16AM
Age/Gender : 29 Y 6 M 16 D/F	Received : 24/Jun/2023 12:38PM
UHID/MR No : CKON.0000411704	Reported : 24/Jun/2023 01:04PM
Visit ID : CKONOPV586760	Status : Final Report
Ref Doctor : Dr.SELF	Sponsor Name : ARCOFEMI HEALTHCARE LIMITED
Emp/Auth/TPA ID : 204329925156	

DEPARTMENT OF BIOCHEMISTRY

ARCOFEMI - MEDIWHEEL - FULL BODY ANNUAL PLUS CHECK ADVANCED - FEMALE - 2D ECHO - PAN INDIA - FY2324

Test Name	Result	Unit	Bio. Ref. Range	Method
-----------	--------	------	-----------------	--------

RENAL PROFILE/KIDNEY FUNCTION TEST (RFT/KFT) , SERUM

CREATININE	0.60	mg/dL	0.5-1.04	Creatinine amidohydrolase
UREA	17.60	mg/dL	15-36	Urease
BLOOD UREA NITROGEN	8.2	mg/dL	8.0 - 23.0	Calculated
URIC ACID	3.50	mg/dL	2.5-6.2	Uricase
CALCIUM	9.80	mg/dL	8.4 - 10.2	Arsenazo-III
PHOSPHORUS, INORGANIC	3.10	mg/dL	2.5-4.5	PMA Phenol
SODIUM	134	mmol/L	135-145	Direct ISE
POTASSIUM	3.8	mmol/L	3.5-5.1	Direct ISE
CHLORIDE	103	mmol/L	98 - 107	Direct ISE

SIN No:SE04404375

Apollo Health and Lifestyle Limited (CIN - U85110TG2000PLC115819)

Regd. Office: 1-10-60/62, Ashoka Raghupathi Chambers, 5th Floor, Begumpet, Hyderabad, Telangana - 500 016 | www.apollohl.com | Email ID: enquiry@apollohl.com, Ph No: 040-4904 7777, Fax No: 4904 7744

APOLLO CLINICS NETWORK

Telangana: Hyderabad (AS Rao Nagar | Chanda Nagar | Kondapur | Nallakunta | Nizampet | Manikonda | Uppal) Andhra Pradesh: Vizag (Seethamma Peta) Karnataka: Bangalore (Basavanagudi | Bellandur | Electronics City | Fraser Town | HSR Layout | Indira Nagar | JP Nagar | Kundalahalli | Koramangala | Sarjapur Road) Mysore (VV Mohalla) Tamilnadu: Chennai (Annanagar | Kotturpuram | Mogappair | T Nagar | Valasaravakkam | Velachery) Maharashtra: Pune (Aundh | Nigdi Pradhikaran | Viman Nagar | Wanowrie) Uttar Pradesh: Ghaziabad (Indrapuram) Gujarat: Ahmedabad (Satellite) Punjab: Amritsar (Court Road) Haryana: Faridabad (Railway Station Road)

Address:
The Apollo Medical Centre, 2-20/6/A, Kothaguda X Roads, Kondapur,
Hyderabad, Telangana, India - 500032



Patient Name : Mrs.RACHNA SINGH	Collected : 24/Jun/2023 09:16AM
Age/Gender : 29 Y 6 M 16 D/F	Received : 24/Jun/2023 12:38PM
UHID/MR No : CKON.0000411704	Reported : 24/Jun/2023 12:54PM
Visit ID : CKONOPV586760	Status : Final Report
Ref Doctor : Dr.SELF	Sponsor Name : ARCOFEMI HEALTHCARE LIMITED
Emp/Auth/TPA ID : 204329925156	

DEPARTMENT OF BIOCHEMISTRY

ARCOFEMI - MEDIWHEEL - FULL BODY ANNUAL PLUS CHECK ADVANCED - FEMALE - 2D ECHO - PAN INDIA - FY2324

Test Name	Result	Unit	Bio. Ref. Range	Method
GAMMA GLUTAMYL TRANSPEPTIDASE (GGT) , SERUM	12.00	U/L	12-43	Glycylglycine Nitoranalide

SIN No:SE04404375

Apollo Health and Lifestyle Limited (CIN - U85110TG2000PLC115819)

Regd. Office: 1-10-60/62, Ashoka Raghupathi Chambers, 5th Floor, Begumpet, Hyderabad, Telangana - 500 016 | www.apollohl.com | Email ID: enquiry@apollohl.com, Ph No: 040-4904 7777, Fax No: 4904 7744

APOLLO CLINICS NETWORK

Telangana: Hyderabad (AS Rao Nagar | Chanda Nagar | Kondapur | Nallakunta | Nizampet | Manikonda | Uppal) **Andhra Pradesh:** Vizag (Seethamma Peta) **Karnataka:** Bangalore (Basavanagudi | Bellandur | Electronics City | Fraser Town | HSR Layout | Indira Nagar | JP Nagar | Kundalahalli | Koramangala | Sarjapur Road) **Mysore** (VV Mohalla) **Tamilnadu:** Chennai (Annanagar | Kotturpuram | Mogappair | T Nagar | Valasaravakkam | Velachery) **Maharashtra:** Pune (Aundh | Nigdi Pradhikaran | Viman Nagar | Wanowrie) **Uttar Pradesh:** Ghaziabad (Indrapuram) **Gujarat:** Ahmedabad (Satellite) **Punjab:** Amritsar (Court Road) **Haryana:** Faridabad (Railway Station Road)

Address:
The Apollo Medical Centre, 2-20/6/A, Kothaguda X Roads, Kondapur,
Hyderabad, Telangana, India - 500032



Patient Name : Mrs.RACHNA SINGH	Collected : 24/Jun/2023 09:16AM
Age/Gender : 29 Y 6 M 16 D/F	Received : 24/Jun/2023 10:23AM
UHID/MR No : CKON.0000411704	Reported : 24/Jun/2023 11:27AM
Visit ID : CKONOPV586760	Status : Final Report
Ref Doctor : Dr.SELF	Sponsor Name : ARCOFEMI HEALTHCARE LIMITED
Emp/Auth/TPA ID : 204329925156	

DEPARTMENT OF IMMUNOLOGY

ARCOFEMI - MEDIWHEEL - FULL BODY ANNUAL PLUS CHECK ADVANCED - FEMALE - 2D ECHO - PAN INDIA - FY2324

Test Name	Result	Unit	Bio. Ref. Range	Method
-----------	--------	------	-----------------	--------

THYROID PROFILE TOTAL (T3, T4, TSH) , SERUM

TRI-IODOTHYRONINE (T3, TOTAL)	1.19	ng/mL	0.7-2.04	CLIA
THYROXINE (T4, TOTAL)	9.87	µg/dL	6.09-12.23	CLIA
THYROID STIMULATING HORMONE (TSH)	6.592	µIU/mL	0.34-5.60	CLIA

Comment:

Serum TSH concentrations exhibit a diurnal variation with the peak occurring during the night and the nadir occurring between 10 a.m. and 4 p.m. In primary hypothyroidism, thyroid-stimulating hormone (TSH) levels will be elevated. In primary hyperthyroidism, TSH levels will be low. Elevated or low TSH in the context of normal free thyroxine is often referred to as subclinical hypo- or hyperthyroid-ism, respectively. Physiological rise in Total T3 / T4 levels is seen in pregnancy and in patients on steroid therapy.

Recommended test for T3 and T4 is unbound fraction or free levels as it is metabolically active.

Note:

For pregnant females	Bio Ref Range for TSH in uIU/ml (As per American Thyroid Association)
First trimester	0.1 - 2.5
Second trimester	0.2 - 3.0
Third trimester	0.3 - 3.0



Patient Name : Mrs.RACHNA SINGH	Collected : 24/Jun/2023 09:16AM
Age/Gender : 29 Y 6 M 16 D/F	Received : 24/Jun/2023 10:23AM
UHID/MR No : CKON.0000411704	Reported : 24/Jun/2023 11:19AM
Visit ID : CKONOPV586760	Status : Final Report
Ref Doctor : Dr.SELF	Sponsor Name : ARCOFEMI HEALTHCARE LIMITED
Emp/Auth/TPA ID : 204329925156	

DEPARTMENT OF CLINICAL PATHOLOGY

ARCOFEMI - MEDIWHEEL - FULL BODY ANNUAL PLUS CHECK ADVANCED - FEMALE - 2D ECHO - PAN INDIA - FY2324

Test Name	Result	Unit	Bio. Ref. Range	Method
-----------	--------	------	-----------------	--------

COMPLETE URINE EXAMINATION (CUE) , URINE

PHYSICAL EXAMINATION

COLOUR	PALE YELLOW		PALE YELLOW	Visual
TRANSPARENCY	CLEAR		CLEAR	Visual
pH	5.5		5-7.5	DOUBLE INDICATOR
SP. GRAVITY	1.020		1.002-1.030	Bromothymol Blue

BIOCHEMICAL EXAMINATION

URINE PROTEIN	NEGATIVE		NEGATIVE	PROTEIN ERROR OF INDICATOR
GLUCOSE	NEGATIVE		NEGATIVE	GLUCOSE OXIDASE
URINE BILIRUBIN	NEGATIVE		NEGATIVE	AZO COUPLING REACTION
URINE KETONES (RANDOM)	NEGATIVE		NEGATIVE	SODIUM NITRO PRUSSIDE
UROBILINOGEN	NORMAL		NORMAL	MODIFIED EHRlich REACTION
BLOOD	NEGATIVE		NEGATIVE	Peroxidase
NITRITE	NEGATIVE		NEGATIVE	Diazotization
LEUCOCYTE ESTERASE	NEGATIVE		NEGATIVE	LEUCOCYTE ESTERASE

CENTRIFUGED SEDIMENT WET MOUNT AND MICROSCOPY

PUS CELLS	4-5	/hpf	0-5	Microscopy
EPITHELIAL CELLS	2-3	/hpf	<10	MICROSCOPY
RBC	NIL	/hpf	0-2	MICROSCOPY
CASTS	NIL		0-2 Hyaline Cast	MICROSCOPY
CRYSTALS	ABSENT		ABSENT	MICROSCOPY

SIN No:UR2134315

Apollo Health and Lifestyle Limited (CIN - U85110TG2000PLC115819)

Regd. Office: 1-10-60/62, Ashoka Raghupathi Chambers, 5th Floor, Begumpet, Hyderabad, Telangana - 500 016 | www.apollohl.com | Email ID: enquiry@apollohl.com, Ph No: 040-4904 7777, Fax No: 4904 7744

APOLLO CLINICS NETWORK

Telangana: Hyderabad (AS Rao Nagar | Chanda Nagar | Kondapur | Nallakunta | Nizampet | Manikonda | Uppal) Andhra Pradesh: Vizag (Seethamma Peta) Karnataka: Bangalore (Basavanagudi | Bellandur | Electronics City | Fraser Town | HSR Layout | Indira Nagar | JP Nagar | Kundalahalli | Koramangala | Sarjapur Road) Mysore (VV Mohalla) Tamilnadu: Chennai (Annanagar | Kotturpuram | Mogappair | T Nagar | Valasaravakkam | Velachery) Maharashtra: Pune (Aundh | Nigdi Pradhikaran | Viman Nagar | Wanowrie) Uttar Pradesh: Ghaziabad (Indrapuram) Gujarat: Ahmedabad (Satellite) Punjab: Amritsar (Court Road) Haryana: Faridabad (Railway Station Road)

Address: The Apollo Medical Centre, 2-20/6/A, Kothaguda X Roads, Kondapur, Hyderabad, Telangana, India - 500032



1860 500 7788
www.apolloclinic.com

Patient Name : Mrs.RACHNA SINGH	Collected : 25/Jun/2023 11:55AM
Age/Gender : 29 Y 6 M 17 D/F	Received : 25/Jun/2023 01:12PM
UHID/MR No : CKON.0000411704	Reported : 25/Jun/2023 01:19PM
Visit ID : CKONOPV586760	Status : Final Report
Ref Doctor : Dr.SELF	Sponsor Name : ARCOFEMI HEALTHCARE LIMITED
Emp/Auth/TPA ID : 204329925156	

DEPARTMENT OF CLINICAL PATHOLOGY

ARCOFEMI - MEDIWHEEL - FULL BODY ANNUAL PLUS CHECK ADVANCED - FEMALE - 2D ECHO - PAN INDIA - FY2324

Test Name	Result	Unit	Bio. Ref. Range	Method
-----------	--------	------	-----------------	--------

URINE GLUCOSE(POST PRANDIAL)	NEGATIVE		NEGATIVE	Dipstick
------------------------------	----------	--	----------	----------

SIN No:UPP015008

Apollo Health and Lifestyle Limited (CIN - U85110TG2000PLC115819)

Regd. Office: 1-10-60/62, Ashoka Raghupathi Chambers, 5th Floor, Begumpet, Hyderabad, Telangana - 500 016 |
www.apollohl.com | Email ID: enquiry@apollohl.com, Ph No: 040-4904 7777, Fax No: 4904 7744

APOLLO CLINICS NETWORK

Telangana: Hyderabad (AS Rao Nagar | Chanda Nagar | Kondapur | Nallakunta | Nizampet | Manikonda | Uppal) **Andhra Pradesh:** Vizag (Seethamma Peta) **Karnataka:** Bangalore (Basavanagudi | Bellandur | Electronics City | Fraser Town | HSR Layout | Indira Nagar | JP Nagar | Kundalahalli | Koramangala | Sarjapur Road) **Mysore** (VV Mohalla) **Tamilnadu:** Chennai (Annanagar | Kotturpuram | Mogappair | T Nagar | Valasaravakkam | Velachery) **Maharashtra:** Pune (Aundh | Nigdi Pradhikaran | Viman Nagar | Wanowrie) **Uttar Pradesh:** Ghaziabad (Indrapuram) **Gujarat:** Ahmedabad (Satellite) **Punjab:** Amritsar (Court Road) **Haryana:** Faridabad (Railway Station Road)

Address:
The Apollo Medical Centre, 2-20/6/A, Kothaguda X Roads, Kondapur,
Hyderabad, Telangana, India - 500032



Patient Name : Mrs.RACHNA SINGH	Collected : 24/Jun/2023 09:16AM
Age/Gender : 29 Y 6 M 16 D/F	Received : 24/Jun/2023 10:23AM
UHID/MR No : CKON.0000411704	Reported : 24/Jun/2023 11:25AM
Visit ID : CKONOPV586760	Status : Final Report
Ref Doctor : Dr.SELF	Sponsor Name : ARCOFEMI HEALTHCARE LIMITED
Emp/Auth/TPA ID : 204329925156	

DEPARTMENT OF CLINICAL PATHOLOGY

ARCOFEMI - MEDIWHEEL - FULL BODY ANNUAL PLUS CHECK ADVANCED - FEMALE - 2D ECHO - PAN INDIA - FY2324

Test Name	Result	Unit	Bio. Ref. Range	Method
-----------	--------	------	-----------------	--------

URINE GLUCOSE(FASTING)	NEGATIVE		NEGATIVE	Dipstick
------------------------	----------	--	----------	----------

SIN No:UF008824

Apollo Health and Lifestyle Limited (CIN - U85110TG2000PLC115819)

Regd. Office: 1-10-60/62, Ashoka Raghupathi Chambers, 5th Floor, Begumpet, Hyderabad, Telangana - 500 016 |
www.apollohl.com | Email ID: enquiry@apollohl.com, Ph No: 040-4904 7777, Fax No: 4904 7744

APOLLO CLINICS NETWORK

Telangana: Hyderabad (AS Rao Nagar | Chanda Nagar | Kondapur | Nallakunta | Nizampet | Manikonda | Uppal) **Andhra Pradesh:** Vizag (Seethamma Peta) **Karnataka:** Bangalore (Basavanagudi | Bellandur | Electronics City | Fraser Town | HSR Layout | Indira Nagar | JP Nagar | Kundalahalli | Koramangala | Sarjapur Road) **Mysore** (VV Mohalla) **Tamilnadu:** Chennai (Annanagar | Kotturpuram | Mogappair | T Nagar | Valasaravakkam | Velachery) **Maharashtra:** Pune (Aundh | Nigdi Pradhikaran | Viman Nagar | Wanowrie) **Uttar Pradesh:** Ghaziabad (Indrapuram) **Gujarat:** Ahmedabad (Satellite) **Punjab:** Amritsar (Court Road) **Haryana:** Faridabad (Railway Station Road)

Address:
The Apollo Medical Centre, 2-20/6/A, Kothaguda X Roads, Kondapur,
Hyderabad, Telangana, India - 500032



Patient Name : Mrs.RACHNA SINGH	Collected : 24/Jun/2023 12:32PM
Age/Gender : 29 Y 6 M 16 D/F	Received : 24/Jun/2023 02:36PM
UHID/MR No : CKON.0000411704	Reported : 26/Jun/2023 04:35PM
Visit ID : CKONOPV586760	Status : Final Report
Ref Doctor : Dr.SELF	Sponsor Name : ARCOFEMI HEALTHCARE LIMITED
Emp/Auth/TPA ID : 204329925156	

DEPARTMENT OF CYTOLOGY

ARCOFEMI - MEDIWHEEL - FULL BODY ANNUAL PLUS CHECK ADVANCED - FEMALE - 2D ECHO - PAN INDIA - FY2324


LBC PAP TEST (PAPSURE) , LBC FLUID

	CYTOLOGY NO.	10628/23
I	SPECIMEN	
a	SPECIMEN ADEQUACY	ADEQUATE
b	SPECIMEN TYPE	CONVENTIONAL SMEAR
	SPECIMEN NATURE/SOURCE	CERVICAL SMEAR
c	ENDOCERVICAL-TRANSFORMATION ZONE	PRESENT WITH ENDOCERVICAL CELLS
d	COMMENTS	SATISFACTORY FOR EVALUATION
II	MICROSCOPY	Superficial and intermediate squamous epithelial cells with benign morphology. Negative for intraepithelial lesion/ malignancy.
III	RESULT	
a	EPITHELIAL CELL	
	SQUAMOUS CELL ABNORMALITIES	NOT SEEN
	GLANDULAR CELL ABNORMALITIES	NOT SEEN
b	ORGANISM	NIL
IV	INTERPRETATION	NEGATIVE FOR INTRAEPITHELIAL LESION OR MALIGNANCY


Pap Test is a screening test for cervical cancer with inherent false negative results. Regular screening and follow-up is recommended (Bethesda-TBS-2014) revised

*** End Of Report ***


Result/s to Follow:
PERIPHERAL SMEAR



DR. K. RAMA KRISHNA REDDY
M.B.B.S, M.D
CONSULTANT PATHOLOGIST



Dr.Sukumar Sannidhi
MD(Path)
Consultant Pathologist



DR. SHALINI SINGH
M.B.B.S, MD
Consultant Pathologist



SIN No:CS064698

Apollo Health and Lifestyle Limited, Apollo Health & Lifestyle Ltd, Global Reference Laboratory, Hyderabad

Regd. Office: 1-10-60/62, Ashoka Raghupathi Chambers, 5th Floor, Begumpet, Hyderabad, Telangana - 500 016 | www.apollohl.com | Email ID: enquiry@apollohl.com, Ph No: 040-4904 7777, Fax No: 4904 7744

The Apollo Medical Centre, 2-20/6/A, Kothaguda X Roads, Kondapur, Hyderabad, Telangana, India - 500032

APOLLO CLINICS NETWORK

Telangana: Hyderabad (AS Rao Nagar | Chanda Nagar | Kondapur | Nallakunta | Nizampet | Manikonda | Uppal) | Andhra Pradesh: Vizag (Seethamma Peta) | Karnataka: Bangalore (Basavanagudi | Bellandur | Electronics City | Fraser Town | HSR Layout | Indira Nagar | JP Nagar | Kundalahalli | Koramangala | Sarjapur Road) | Mysore (VV Mohalla) | Tamil Nadu: Chennai (Annanagar | Kotturpuram | Mogappair | T Nagar | Valasaravakkam | Velachery) | Maharashtra: Pune (Aundh | Nigdi Pradhikaran | Viman Nagar | Wanowrie) | Uttar Pradesh: Ghaziabad (Indrapuram) | Gujarat: Ahmedabad (Satellite) | Punjab: Amritsar (Court Road) | Haryana: Faridabad (Railway Station Road)

Patient Name : Mrs. RACHNA SINGH

Age/Gender : 29 Y/F

UHID/MR No. : CKON.0000411704

OP Visit No : CKONOPV586760

Sample Collected on :

Reported on : 26-06-2023 12:37

LRN# : RAD2030028

Specimen :

Ref Doctor : SELF

Emp/Auth/TPA ID : 204329925156

DEPARTMENT OF RADIOLOGY

ULTRASOUND - WHOLE ABDOMEN

Liver appears normal in size and echotexture. No focal lesion is seen. PV and CBD normal. No dilatation of the intrahepatic biliary radicals.

Gall bladder is distended normal. No evidence of calculus. Wall thickness appears normal. No evidence of periGB collection. No evidence of focal lesion is seen.

Spleen appears normal. No focal lesion seen. Splenic vein appears normal.

Pancreas appears normal in echopattern. No focal/mass lesion/calcification. No evidence of peripancreatic free fluid or collection. Pancreatic duct appears normal.

Both the kidneys appear normal in size, shape and echopattern. Cortical thickness and CM differentiation are maintained. No calculus / hydronephrosis seen on either side.

Right Kidney Measures 104 x 40 mm. Left Kidney Measures : 106 x 45 mm.

Urinary Bladder : EMPTY.

IMPRESSION:-


**** NORMAL STUDY OF UPPER ABDOMEN.**

Suggest – clinical correlation.

(The sonography findings should always be considered in correlation with the clinical and other investigation finding where applicable.) It is only a professional opinion, Not valid for medico legal purpose.

Patient Name : Mrs. RACHNA SINGH

Age/Gender : 29 Y/F



Dr. VIJAYA KUMAR M
MBBS, DMRD
Consultant Radiologist

Patient Name : Mrs. RACHNA SINGH Age : 29 Y/F
UHID : CKON.0000411704 OP Visit No : CKONOPV586760
Conducted By: : Dr. VENKATA RAYUDU NEKKANTI Conducted Date : 24-06-2023 15:31
Referred By : SELF

2D-ECHO WITH COLOUR DOPPLER

Dimensions:

Ao (cd)	2.97 CM
LA (es)	2.46 CM
LVID (cd)	4.33 CM
LVID (cs)	2.90 CM
IVS (Ed)	0.8 CM
LVPW (Ed)	0.7 CM
EF	63.00%
%FD	39.00%
MITRAL VALVE :	NORMAL
AML	NORMAL
PML	NORMAL
AORTIC VALVE	NORMAL
TRICUSPID VALVE	NORMAL
RIGHT VENTRICLE	NORMAL
INTER ATRIAL SEPTUM	INTACT
INTER VENTRICULAR SEPTUM	INTACT
AORTA	NORMAL
RIGHT ATRIUM	NORMAL
LEFT ATRIUM	NORMAL
Pulmonary Valve	NORMAL
PERICARDIUM	NORMAL
LEFT VENTRICLE:	

NO REGIONAL WALL MOTION ABNORMALITY

COLOUR AND DOPPLER STUDIES

NORMAL FLOW

Apollo Health and Lifestyle Limited

(CIN - U85110TG2000PLC046089) Regd. Office: 7-1-617/A, 7th Floor, Imperial Towers, Ameerpet, Hyderabad-500016, Telangana.

APOLLO CLINICS NETWORK

Andhra Pradesh: **Tirupati** (Sankarambadi Circle) **Vizag** (Seethamma Peta)

Telangana: **Hyderabad** (AS Rao Nagar | Chanda Nagar | Jubilee Hills | Kondapur | Nallakunta | Nizampet | SR Nagar | Vanasthalipuram)

Online appointments: www.apolloedoc.in | Online reports: <https://phr.apolloclinic.com> | www.apolloclinic.com

TO BOOK AN APPOINTMENT



1860 500 7788

IMPRESSION :-
NORMAL STUDY

Dr. VENKATA
RAYUDU
NEKKANTI

Apollo Health and Lifestyle Limited

(CIN - U85110TG2000PLC046089) Regd. Office: 7-1-617/A, 7th Floor, Imperial Towers, Ameerpet, Hyderabad-500016, Telangana.

APOLLO CLINICS NETWORK

Andhra Pradesh: **Tirupati** (Sankarambadi Circle) **Vizag** (Seethamma Peta)

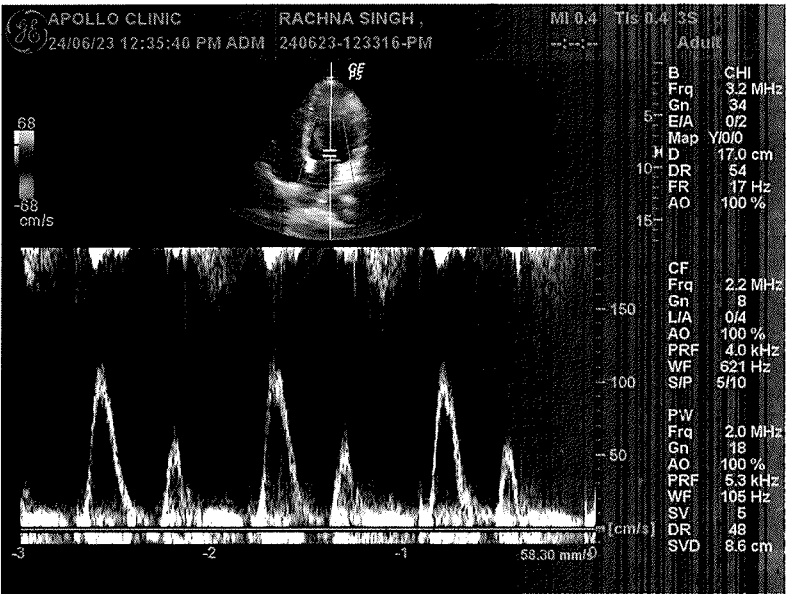
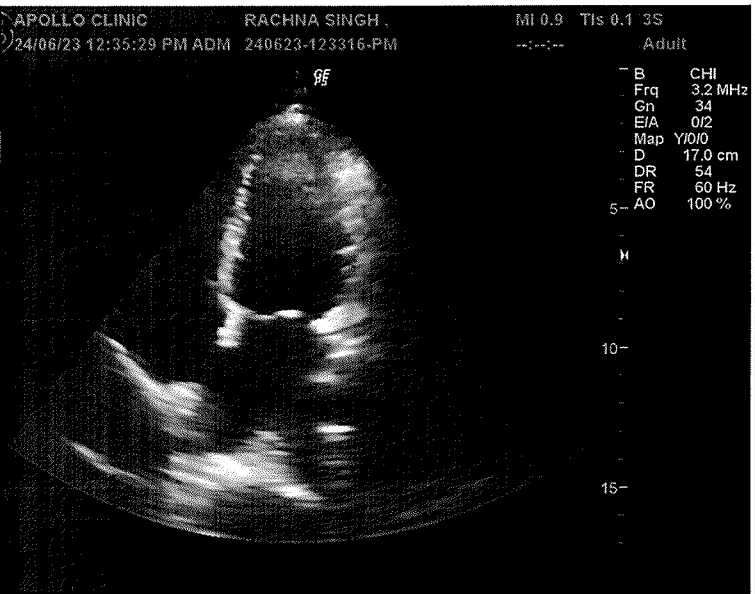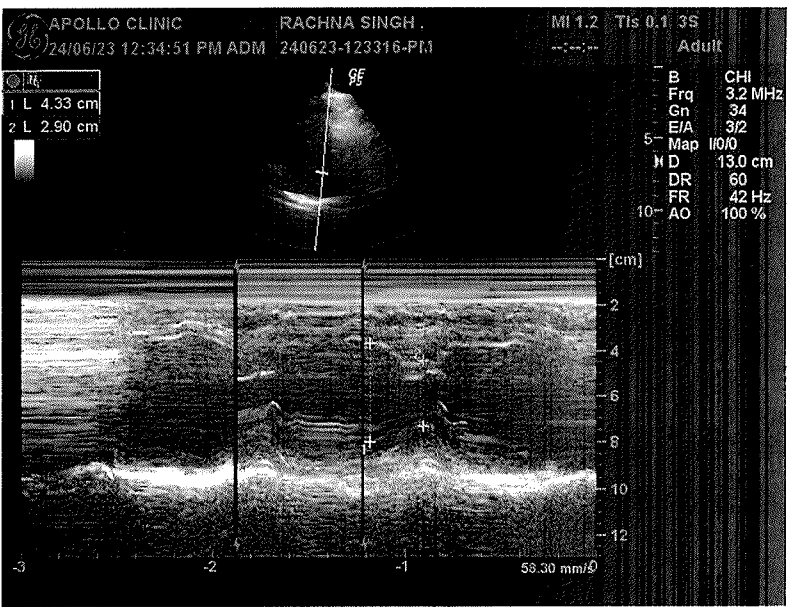
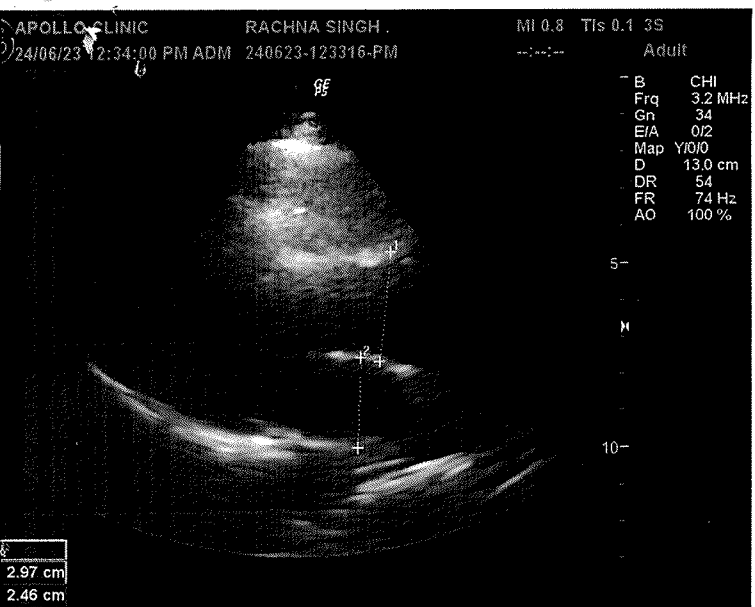
Telangana: **Hyderabad** (AS Rao Nagar | Chanda Nagar | Jubilee Hills | Kondapur | Nallakunta | Nizampet | SR Nagar | Vanasthalipuram)

Online appointments: www.apolloedoc.in | Online reports: <https://phr.apolloclinic.com> | www.apolloclinic.com

TO BOOK AN APPOINTMENT



1860 500 7788



Name <u>Mrs. Rachna Singh</u>	Date <u>24/06/2023</u>
Age <u>24y</u>	UHID No. <u>111704</u>
<input type="checkbox"/> Male <input checked="" type="checkbox"/> Female	Ref. Physician
Ref. Diagnosis	<u>Dr. Rayudu</u>

Echocardiogram Report

Echogenicity Poor Adequate Good Ht. _____ Wt. _____ BSA _____

DIMENSIONS	NORMAL	DIMENSIONS	NORMAL
Ao (ed) <u>2.97</u> cm	(1.5cm / m2)	IVS (Ed) <u>0.8</u> cm	(0.6 - 1.2 cm)
LA (es) <u>2.46</u> cm	(1.5cm / m2)	LVPW (Ed) <u>0.7</u> cm	(0.6 - 1.1 cm)
RVID (ed) _____ cm	(0.9 cm / m2)	EF <u>63%</u>	(0.62 - 0.85)
LVID (ed) <u>4.33</u> cm	(2.6 - 3.4 cm / m2)	% FD <u>39%</u>	(2.8% - 42%)
LVID (es) <u>2.90</u>			

MORPHOLOGICAL DATA

Mitral Valve AML (N)
 PML (N)

Aortic Valve _____

Tricuspid valve _____ (N)

Pulmonary valve _____

Right ventricle _____

Interatrial septum (N)

Interventricular septum (N)

Pulmonary artery _____

Aorta _____

Right atrium (N)

Left atrium _____

Patient Name : Mrs. RACHNA SINGH Age : 29 Y/F
UHID : CKON.0000411704 OP Visit No : CKONOPV586760
Reported By: : Dr. VENKATA RAYUDU NEKKANTI Conducted Date : 24-06-2023 16:12
Referred By : SELF

ECG REPORT

Observation :-

1. Sinus Rhythm.
2. Heart rate is 78 beats per minutes.
3. No pathological Q wave or S-T,T changes seen.
4. Normal P,Q,R,S,T waves and axis.
5. No evidence of chamber, hypertrophy or enlargement seen.

Impression:

R S R VI.
NO ST CHANGES.

----- END OF THE REPORT -----

Dr. VENKATA RAYUDU NEKKANTI



Name: Mrs. RACHNA SINGH
 Age/Gender: 29 Y/F
 Address: HYD
 Location: HYDERABAD, TELANGANA
 Doctor:
 Department: GENERAL
 Rate Plan: KONDAPUR_06042023
 Sponsor: ARCOFEMI HEALTHCARE LIMITED

MR No: CKON0000411704
 Visit ID: CKONOPV586760
 Visit Date: 24-06-2023 09:12
 Discharge Date:
 Referred By: SELF

Vitals:

Date	Pulse (Beats/min)	B/P (mmHg)	Resp (Rate/min)	Temp (F)	Height (cms)	Weight (Kgs)	Body Fat Percentage (%)	Visceral Fat Level (%)	Body Age (Years)	BMI (cms)	Waist Circum (cms)	Hip (cms)	Waist (cms)	Waist & Hip Ratio	User
24-06-2023 15:31	78	120/70 mmHg	Rate/min	F	171 cms	69 Kgs	%	%	Years	23.6	cms	100 cms	93 cms		AHLL04664

95% J. Singh
No ST

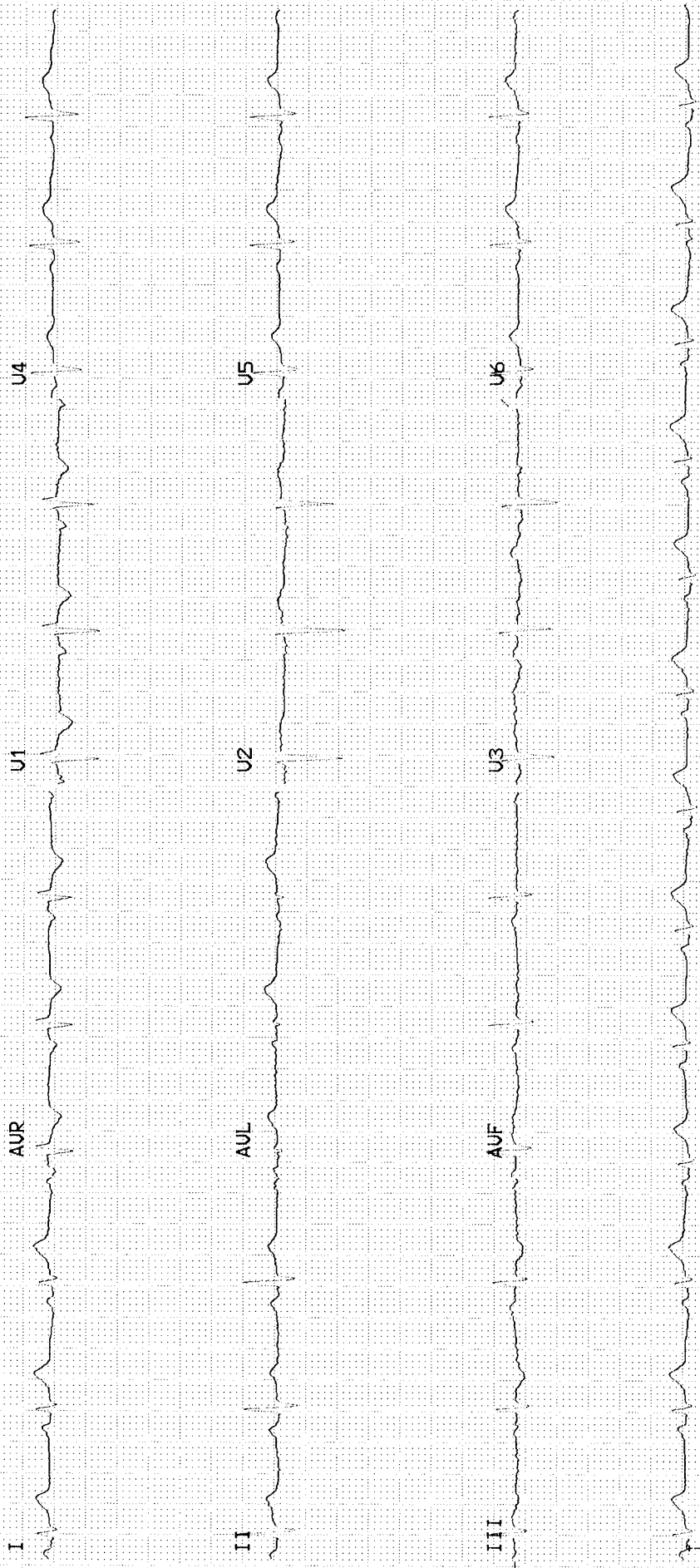
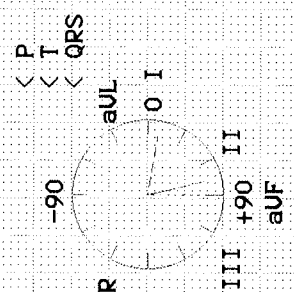
Unconfirmed report.

AGE: 29
Measurement Results:

QRS	360 /	96 ms
QT/QTcB	412 ms	
PR	146 ms	
P	102 ms	
RR/PP	764 /	770 ms
P/QRS/T	90 / 75 /	10 degrees
QTcD/QTcBD	66 /	76 ms
Sokolow		mV
NK		11

Interpretation:

Low QRS amplitudes
probably abnormal ECG



GLASS PRESCRIPTION

DATE: 24/06/22.

UHID: 411704.

PATIENT NAME:

Mrs. Rohana Singh.

AGE/ GENDER:

80/41/83/90

	UAVA	SPH	CYL	AXIS	ADD	BCVA
OD	6/6	—	—	—		No
OS	6/6	—	—	—		No

COLOR VISION:

RR Normal.

INSTRUCTIONS:

Pls use better lens.

SIGNATURE



Patient Name : Mrs. RACHNA SINGH

Age/Gender : 29 Y/F

UHID/MR No. : CKON.0000411704

OP Visit No : CKONOPV586760

Sample Collected on :

Reported on : 24-06-2023 18:47

LRN# : RAD2030028

Specimen :

Ref Doctor : SELF

Emp/Auth/TPA ID : 204329925156

DEPARTMENT OF RADIOLOGY

SONO MAMMOGRAPHY - SCREENING

B-Mode Two Dimensional real time Sono Mammography

Both Breasts imaged with 10 MHZ probe.

No evidence of solid or cystic space occupying lesion.

No evidence of calcification.

No e/o vascularity on colour flow mapping.

Both axillary regions appear normal.

IMPRESSION :

**** NORMAL STUDY.**

Ultrasonography is the study of images hence not 100% accurate. Serial scans and reconfirmation is recommended. The reports are not valid for medicolegal purpose. Clinical opinion needs to be taken.

Dr.HARSHINI REDDY K
Consultant Radiologist.

HARSHINI REDDY K
BMEPK3203J
Radiology

Patient Name : Mrs. RACHNA SINGH

Age/Gender : 29 Y/F

UHID/MR No. : CKON.0000411704

OP Visit No : CKONOPV586760

Sample Collected on :

Reported on : 24-06-2023 15:43

LRN# : RAD2030028

Specimen :

Ref Doctor : SELF

Emp/Auth/TPA ID : 204329925156

DEPARTMENT OF RADIOLOGY

X-RAY CHEST PA

Both lung fields and hila are normal .

No obvious active pleuro-parenchymal lesion seen .


Both costophrenic and cardiophrenic angles are clear .

Both diaphragms are normal in position and contour .

Thoracic wall and soft tissues appear normal.

CONCLUSION :

No obvious abnormality seen



Dr. VIJAYA KUMAR M
MBBS, DMRD
Consultant Radiologist