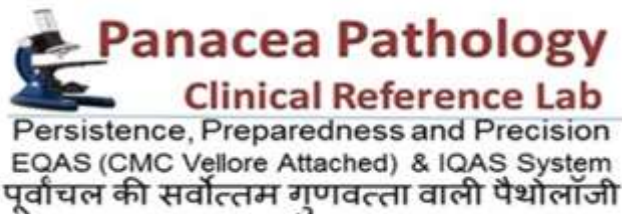


Facilities:
 All clinical Biomedical & Hematology Investigations
 including Bone Marrow Examination
 VPT, Podiascan & Complete Foot Care (First Time in Purvanchal)
 All Hormonal Investigation by Chemiluminescent Method
 Visceral Fat by (AB-140) Ambulatory BP Monitoring
 CGMS & Insulin Pump Available
 PFT, 2D-ECHO (Color Doppler), Holter, TMT, Cardiac-3 available
 VIA, VILI, Colposcopy available
 Special Endocrinological Investigation Protocols.

ISO 9001:2008 Certified
 Mobile: 9389994334, 9554572190, 9453837595



PATIENT NAME : KUSUM MAURYA	AGE/GENDER : 45 YRS/FEMALE
REFD BY DR. : ARCO FEMI HEALTHCARE LTD.	RECEIVED DATE : 11-12-2022 (09:45 AM)
SAMPLE : BLOOD & URINE	REPORT DATE : 11-12-2022 (18:15 PM)

PATHOLOGY REPORT

COMPLETE BLOOD COUNT (CBC)

TEST	LAB TEST VALUES	NORMAL RANGE
HEMOGRAM		
HEMOGLOBIN (FLOW CYTOMETRY)	7.0	13 – 16 gm/dl
TOTAL LEUCOCYTE COUNT (TLC)	5,700	4000 – 11000
RBC COUNT	4.11	3.5 – 5.5
PCV (HCT)	25.0	37 – 47
MCV	60.8	80 – 95
MCH	17.1	28 – 34
MCHC	28.1	30 – 36
PLATELET COUNT	0.90000	1,50,000 – 4,00,000
E.S.R. (WINTROBE FIRST HOURS)	18.0	20 mm/1 st hr
DIFFERENTIAL LEUCOCYTE		
NEUTROPHILS	41	40 – 75%
LYMPHOCYTES	48	20 – 45%
EOSINOPHILS	06	1 – 6%
MONOCYTES	05	2 – 8%
BASOPHILS	00	< 2 %

RENAL & KIDNEY PROFILE, SERUM

TEST	LAB TEST VALUES	NORMAL RANGE
RENAL FUNCTION TESTS		
BLOOD UREA NITROGEN (BUN)	12.0	10 – 50 mg/dl
SERUM CREATININE	0.92	0.60 – 1.60 mg/dl
URIC ACID	4.16	3.60 – 7.70 mg/dl
ALKALINE PHOSPHATASE (ALP)	86.0	142 – 353 mg/dl
TOTAL PROTIENS	6.12	0 – 39 mg/dl
ALBUMIN	4.05	3.8 – 5.4 mg/dl
SERUM GLOBULIN	3.02	2.1 – 3.5 mg/dl
CALCIUM	9.1	8.80 – 10.20
PHOSPHORUS	3.62	2.50 – 5.00
SERUM SODIUM NA+	143.0	135.00 – 155.00 mEq/Ltr
SERUM POTASIUM K+	4.20	3.60 – 5.50 mEq/Ltr
ICALCIUM	1.20	1.10 – 1.35 mmol/L
SERUM CHLORIDE CL+	109.3	98.00 – 110.00 mEq/Ltr

PAGE 1

Lab Technician

M.D., Pathology

Timing : 8.00 a.m. to 9.00 p.m. (Sunday 8.00 a.m. to 3.00 p.m.)

This Report is not valid for medico legal purpose

Note: These tests have technical limitations. Clinico-pathological interpretation is necessary. In case of any disparity test may be repeated immediately.

Address : 36/44 FK Kabir Nagar, Durgakund, Varanasi – 221005

Email: dramishra@gmail.com, drpallaviojha@gmail.com Website: panaceahospital.org

Facilities:
 All clinical Biomedical & Hematology Investigations
 including Bone Marrow Examination
 VPT, Podiascan & Complete Foot Care (First Time in Purvanchal)
 All Hormonal Investigation by Chemiluminescent Method
 Visceral Fat by (AB-140) Ambulatory BP Monitoring
 CGMS & Insulin Pump Available
 PFT, 2D-ECHO (Color Doppler), Holter, TMT, Cardiac-3 available
 VIA, VILI, Colposcopy available
 Special Endocrinological Investigation Protocols.

ISO 9001:2008 Certified
 Mobile: 9389994334, 9554572190, 9453837595



Panacea Pathology Clinical Reference Lab

Persistence, Preparedness and Precision
 EQAS (CMC Vellore Attached) & IQAS System
 पूर्वांचल की सर्वोत्तम गुणवत्ता वाली पैथोलॉजी

PATIENT NAME : KUSUM MAURYA	AGE/GENDER : 45 YRS/FEMALE
REFD BY DR. : ARCO FEMI HEALTHCARE LTD.	RECEIVED DATE : 11-12-2022 (09:45 AM)
SAMPLE : BLOOD & URINE	REPORT DATE : 11-12-2022 (18:15 PM)

PATHOLOGY REPORT

LIPID PROFILE, SERUM

TEST	LAB TEST VALUES	NORMAL RANGE
BLOOD CHEMISTRY		
TOTAL CHOLESTEROL (SERUM)	136.0	Desirable:- < 200 mg/dl Borderline:- 200 – 239 mg/dl High:- > 240 mg/dl
TRIGLYCERIDES (SERUM)	142.0	35 – 170 mg/dl
HDL CHOLESTEROL (SERUM)	33.0	35.30 – 79.50 mg/dl
LDL CHOLESTEROL (SERUM)	74.6	< 130 mg/dl
VLDL	28.4	< 40 mg/dl
NON HDL	69.0	0.00 – 100.00 mg/dl
CHOLESTROL/HDL RATIO	4.12	< 3.0 Low Risk Ratio 3.0 – 5.0 Avg Risk > 5.0 High Risk
LDL/HDL RATIO	2.24	< 3 Ratio

BLOOD GROUP

TEST	LAB TEST VALUES
BLOOD GROUP ABO & RH FACTOR	
BLOOD GROUP	"B"
RH FACTOR	POSITIVE

GLYCOSYLATED HEMOGLOBIN (HBA1C)

TEST	LAB TEST VALUES	NORMAL RANGE
HBA1C	5.2	Normal : <5.97 % Good Control : 5.97 – 6.81% Fair Control : 6.81 – 7.65% Poor Control : >7.65%

THYROID PROFILE (T3, T4, TSH)

TEST	LAB TEST VALUES	NORMAL RANGE
THYROID FUNCTION TEST		
T3	1.12	0.60 – 1.81 ng/ml
T4	7.56	4.50 – 10.90 ug/dl
TSH	1.39	0.39 – 6.10 uIU/mL

PAGE 2

Lab Technician

M.D., Pathology

Timing : 8.00 a.m. to 9.00 p.m. (Sunday 8.00 a.m. to 3.00 p.m.)

This Report is not valid for medico legal purpose


Note: These tests have technical limitations. Clinico-pathological interpretation is necessary. In case of any disparity test may be repeated immediately.

Address : 36/44 FK Kabir Nagar, Durgakund, Varanasi – 221005

Email: dramishra@gmail.com, drpallaviojha@gmail.com Website: panaceahospital.org

Facilities:
 All clinical Biomedical & Hematology Investigations
 including Bone Marrow Examination
 VPT, Podiascan & Complete Foot Care (First Time in Purvanchal)
 All Hormonal Investigation by Chemiluminescent Method
 Visceral Fat by (AB-140) Ambulatory BP Monitoring
 CGMS & Insulin Pump Available
 PFT, 2D-ECHO (Color Doppler), Holter, TMT, Cardiac-3 available
 VIA, VILI, Colposcopy available
 Special Endocrinological Investigation Protocols.

ISO 9001:2008 Certified
 Mobile: 9389994334, 9554572190, 9453837595



Panacea Pathology
Clinical Reference Lab
 Persistence, Preparedness and Precision
 EQAS (CMC Vellore Attached) & IQAS System
 पूर्वांचल की सर्वोत्तम गुणवत्ता वाली पैथोलॉजी

PATIENT NAME : KUSUM MAURYA	AGE/GENDER : 45 YRS/FEMALE
REFD BY DR. : ARCO FEMI HEALTHCARE LTD.	RECEIVED DATE : 11-12-2022 (09:45 AM)
SAMPLE : BLOOD & URINE	REPORT DATE : 11-12-2022 (18:15 PM)

PATHOLOGY REPORT

LIVER PROFILE TEST, SERUM

TEST	LAB TEST VALUES	NORMAL RANGE
BIO CHEMISTRY		
TOTAL BILIRUBIN	0.72	0.0 – 1.1 mg/dl
DIRECT BILIRUBIN	0.25	0.0 – 0.2 mg/dl
INDIRECT BILIRUBIN	0.47	< 0.90 mg/dl
SGOT (AST)	22.0	0 – 52 mg/dl
SGPT (ALT)	25.0	0 – 39 mg/dl
GGT (GYT)	30.0	< 55 U/L
AG RATIO	1.93	-

URINE ROUTINE EXAMINATION

TEST	LAB TEST VALUES	NORMAL RANGE
PHYSICAL EXAMINATION		
QUANTITY	29	ML
COLOUR	STRAW	PALE YELLOW
APPEARANCE	CLEAR	CLEAR
SPECIFIC GRAVITY	1.010	1.01 – 1.03
PH	5.5	4.7 – 7.5
CHEMICAL EXAMINATION		
GLUCOSE	Not Detected	Not Detected
PROTEIN	NIL	Not Detected
MICROSCOPIC EXAMINATION		
PUS CELLS	1-2	0-5
RBC	Not Detected	Not Detected
EPITHELIAL CELLS	1-2	0-5
CASTS	Not Detected	Not Detected
CRYSTALS	Not Detected	Not Detected
BACTERIA	Not Detected	Not Detected

FASTING/RANDOM BLOOD SUGER

TEST	LAB TEST VALUES	NORMAL RANGE
FBS/RBS		
FASTING BLOOD SUGER	86.0	110-125 mg/dl
RANDOM BLOOD SUGER	125.0	125-140 mg/dl

----- End of Report -----

Lab Technician

M.D., Pathology

Timing : 8.00 a.m. to 9.00 p.m. (Sunday 8.00 a.m. to 3.00 p.m.)

This Report is not valid for medico legal purpose

Note: These tests have technical limitations. Clinico-pathological interpretation is necessary. In case of any disparity test may be repeated immediately.

Address : 36/44 FK Kabir Nagar, Durgakund, Varanasi – 221005

Email: dramishra@gmail.com, drpallaviojha@gmail.com Website: panaceahospital.org



IS
shamiya

PANACEA HOSPITAL

B 36/44 F.K KABIR NAGAR, DURGAKUND
TOLLFREE NO-18001233070.
Whatsapp No - 8795832852
www.piire.org



OP Slip

Print Date : 10-Dec-2022 10:24AM



UHID No	:- UD-22230002878	OP No	:- OP-22230010802	OP Date	:- 10 Dec 2022 10:23AM
Patient Name	:- Mrs KUSUM MAURYA BOB	Age/Sex	:- 45 Y/Female	Mobile No	:- 9650509501
Husband	:- AWADHBIHARI MAURYA	Department	:- DIABETES, ENDOCRINOLOGY & METABOLIC PHYSICIAN		
Pay Type	:- Cash	Consultant	:- Dr ASHUTOSH MISHRA (MD(MEDICINE), IMS, BHU)		
Token No	:- NOR. - 15	Paid/Bal	:- 0.00 / 500.00.		
Patient Type	:- Normal				
Address	:- LAMHI, varanasi				

BP :- 120/70
height :- 147
Weight (kg) :- 52.6
BMI :-

Rx
C/O
Bachache
y

PIVD

SpO₂ - 99
PR - 94
NC - 31
LOC - 83

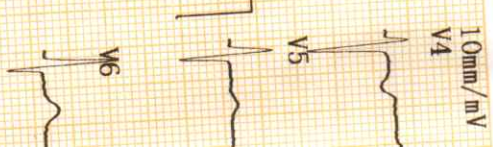
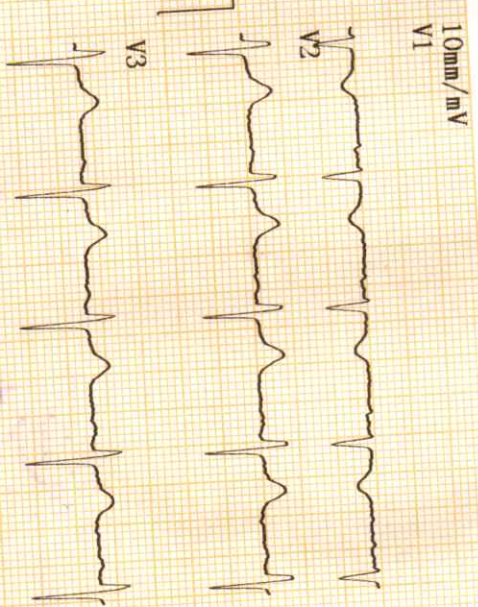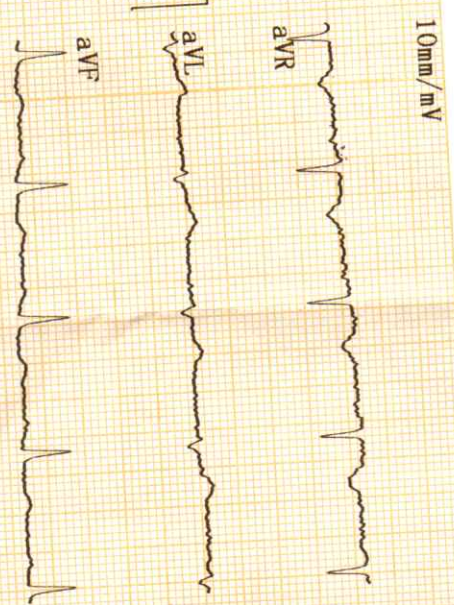
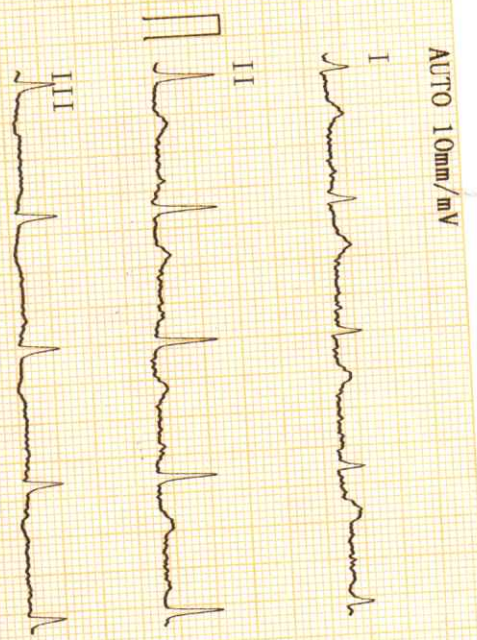
Allergy H/O - (-nt)
Seasonal variation - (-nt)
Past H/O - No
Menses H/O - Regular
family H/O - No
Medicine H/O - ?

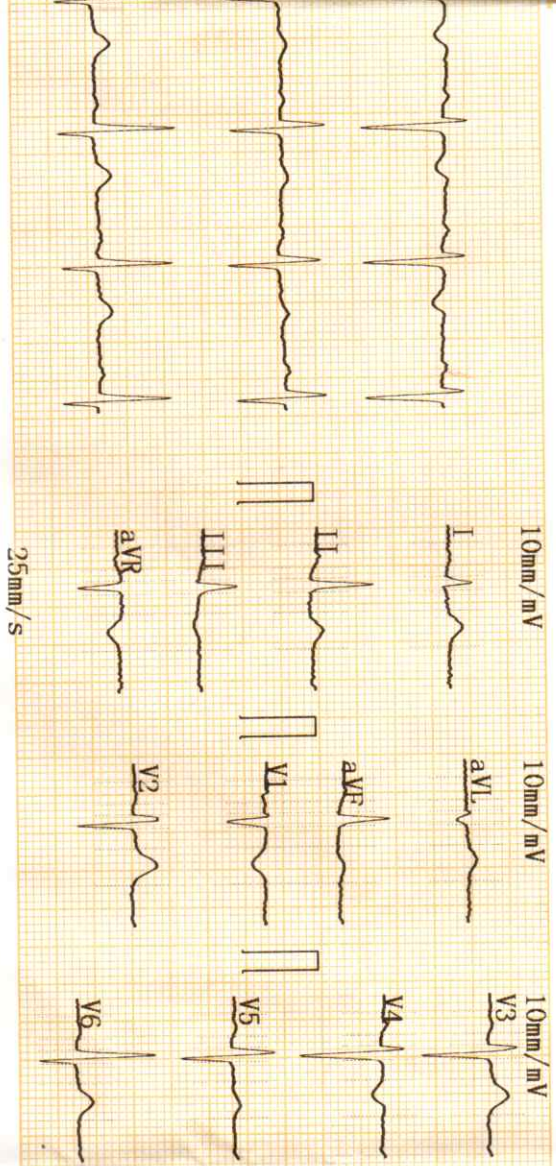
Printed By : Mr NITIN YADAV

Created By : Mr NITIN YADAV

25mm/s AC50Hz+EMG35Hz

CARDIART





2022-12-10 10:53

ID :
 Name : Kusum mawrya
 Sex : f
 Height :
 SYS :
 DIA :
 HR : 86 bpm
 PR Interval : 180 ms
 P Duration : 120 ms
 QRS Duration : 76 ms
 T Duration : 195 ms
 QT/QTc : 381/455 ms
 P/QRS/T Axis : 67.2/70.5/8.7 deg
 R(V5)/S(V1) : 0.56/0.49 mV
 R(V5)+S(V1) : 1.05 mV

<< Conclusions >>

Normal Sinus Rhythm;
 Cardiac electric axis normal;
 I II III aVF V4 Abnormal T wave;

Report need physician confirm

DR. PALLAVI MISHRA
 MBBS,MD (GENERAL MEDICINE)
 MCI Reg.No. 52033

CARDIARI
 Physician

VanAm01 070A

Call Now - 1800-123-3070



PANACEA HOSPITAL

A shelter for many hearts A Home for many lives

(An ISO 9001:2008 Certified Organisation)
Lab Attached with CMC Vellore Under EQAS Scheme

Name	MRS.KUSUM MAURYA	Sex /Age	47/M	Date	10/12/2022
Ref. by	Dr.Pallavi Mishra(MD)	BSA - m ²		Echo window	fair

Echo - Cardiography

MITRAL VALVE Doppler	AML - normal morphology MV Flow - E - 0.8 A-0.6 E/A=1.48	PML - normal morphology MVA - 3.0 cm ² Mitral Regurgitation - No
TRICUSPID VALVE Doppler	Normal TV Flow -No	Tricuspid Regurgitation -No
PULMONARY VALVE Doppler	Normal PV Flow -No	Pulmonary Regurgitation - No
AORTIC VALVE Doppler	Trileaflet-No AV Flow - no	Aortic Regurgitation - no
MEASUREMENT	Aorta - 27.4 (20-38) mm IVS ed - 6.3 (6 -12) mm LVID ed - 46.3 (35 - 55) mm LVPW ed - 14.3 (6 -12) mm OA - 7 (> 5) mm	LA - 25.1 (24-32) mm IVS es -17.1 (6 - 12) mm LVID es - 30.3 (24 - 40) mm LVPW es - 14.3 (6 -12) mm EPSS - 5 (< 9) mm

CONCLUSION

All cardiac chamber dimensions are WNL
No valvular abnormalities
Good LV systolic function present Modified Simpson's method (4C, 2C) (LVEF-85%)
No diastolic dysfunction present (E/A = 1.48) by tissue Doppler (E/e'=8.9)
No RWMA
No pericardial effusion
Intact IAS / IV
No PAH
No intra cardiac mass /thrombus /vegetation

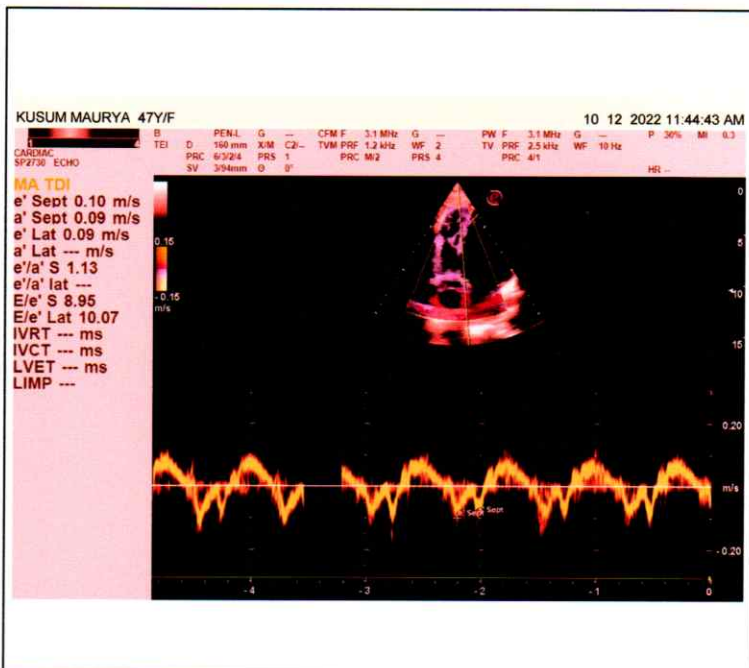
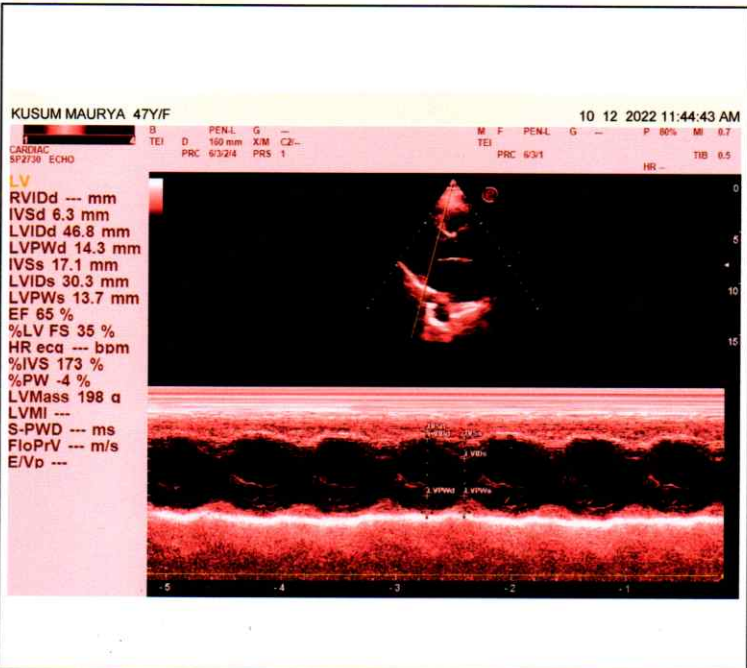
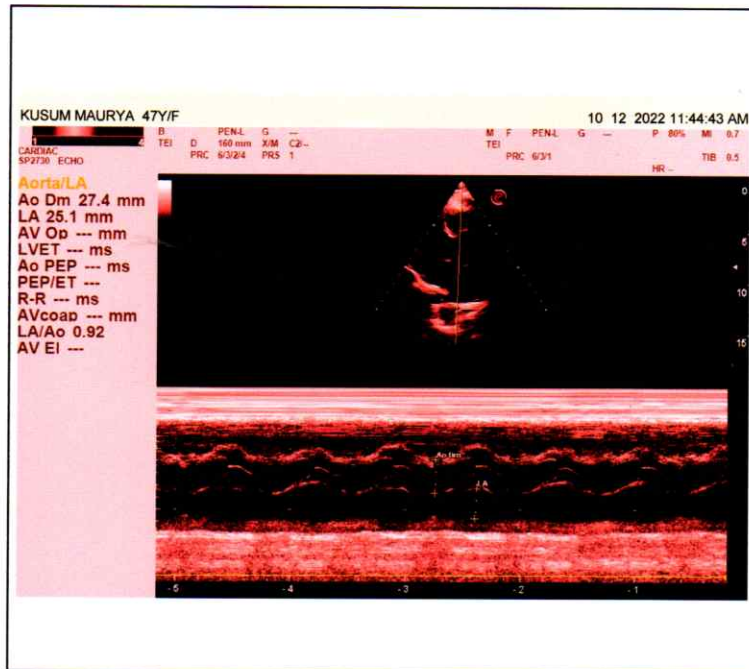
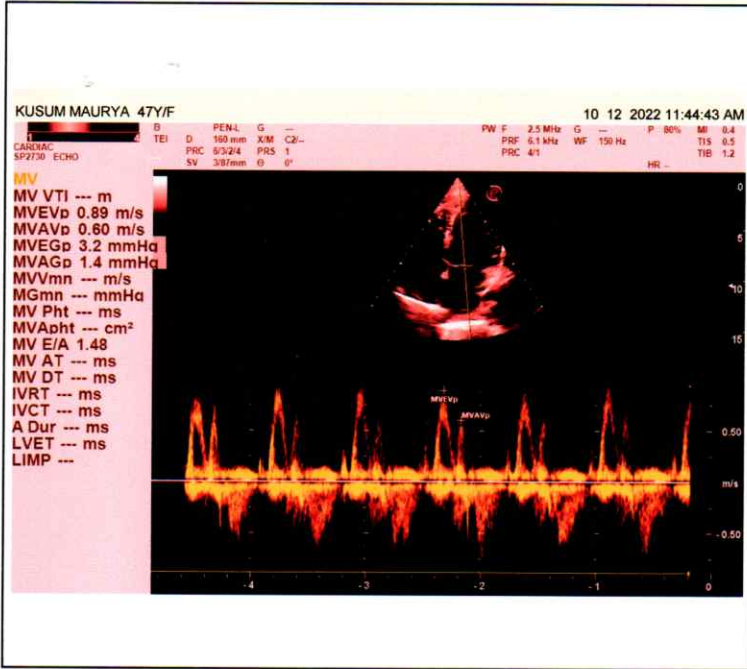
IMPRESSION **Normal Echocardiogram**

Niraj Mishra
Niraj Mishra
Physician Assistant
(PIIRE)

Pallavi
DR. PALLAVI MISHRA
MBBS, MD (GENERAL MEDICINE)
MCI Reg.No. 52033

Dr. Pallavi Mishra
MBBS, MD (MED) Lucknow
Echocardiography Specialist, MIAE
Non-invasive cardiologist
Women Cardiologist
Diabetocardiologist

Address : Kabir Nagar (Near Sanjay Shiksha Niketan), Durgakund, Varanasi
Mobile : 9554572190 / 9453837595 / Recpn. 9389994334
E-mail : dramishra@gmail.com, drpallaviojha@gmail.com, Website: www.piire.org





PANACEA HOSPITAL

A shelter for many hearts A Home for many lives

(An ISO 9001:2008 Certified Organisation)

Lab Attached with CMC Vellore Under EQAS Scheme

NAME: MRS.KUSUM MAURYA

AGE/SEX: 47 YRS / FEMALE

REF BY: DR. ASHUTOSH MISHRA (MD)

DATE: 10 /12/2022

ULTRA SOUND FOR ABDOMAN REPORT

- Liver:** Normal in shape and size(9.3cm) and shows smooth and regular margin.
No diffuse/focal lesion seen.
- Gall bladder** Partially distended with normal wall thickness and echo-free lumen.
- CBD** Visualized part normal in course & caliber.
- Pancreas:** Normal in size, shape & echogenicity.
Margins are smooth & regular.
No diffuse/ focal lesion seen. Pancreatic tail obscured.
- Spleen:** Normal in size(8.8 cm) shape & echogenicity.
Margins are smooth & regular. No diffuse / focal lesion seen.
Splenic vessels at hilum is normal.
- Kidney:** Right kidney: 8.2 X 4.2cm
Left kidney: 10.4 X 5.2 cm
Normal cortical echogenicity with well maintained Cortical-medullary differentiation.
Pelvicalyceal system normal.
No calculus/mass lesion seen.
No hydronephrosis/ hydroureter seen.

Address : Kabir Nagar (Near Sanjay Shiksha Niketan), Durgakund, Varanasi

Mobile : 9554572190 / 9453837595 / Recpn. 9389994334

E-mail : dramishra@gmail.com, drpallaviojha@gmail.com, Website: www.piire.org



Call Now - 1800-123-3070

PANACEA HOSPITAL

A shelter for many hearts A Home for many lives

(An ISO 9001:2008 Certified Organisation)

Lab Attached with CMC Vellore Under EQAS Scheme

Urinary bladder: Normally distended, wall thickness is normal.

No echogenic foci lumen or diverticula seen.

Both VUJ appears normal.

No E.R. calculus / mass lesion seen.

Uterus: Uterus normal in size shape, & echogenicity.

Margins are smooth & regular.

Endometrial thickness within normal limits(4.2 mm) .

Ovary: Right ovary normal in size and shows normal morphology.

Left ovary normal in size and shows normal morphology.

Others: No free fluid in peritoneal cavity.

No free fluid in bilateral pleural cavity.

IMPRESSION:

- NO SIGNIFICANT SONOLOGICAL ABNORMALITY DETECTED.

Please correlate clinically and further investigations.

DR. PALLAVI MISHRA
MBBS,MD (GENERAL MEDICINE)

MCI Reg.No. 52033

DR. PALLAVI MISHRA

MBBS MD(MED) Lucknow

Echocardiography specialist, MIAE

Non invasive cardiologist

Women cardiologist


Radiologist

Dr.Tusharika Rai

MBBS MS

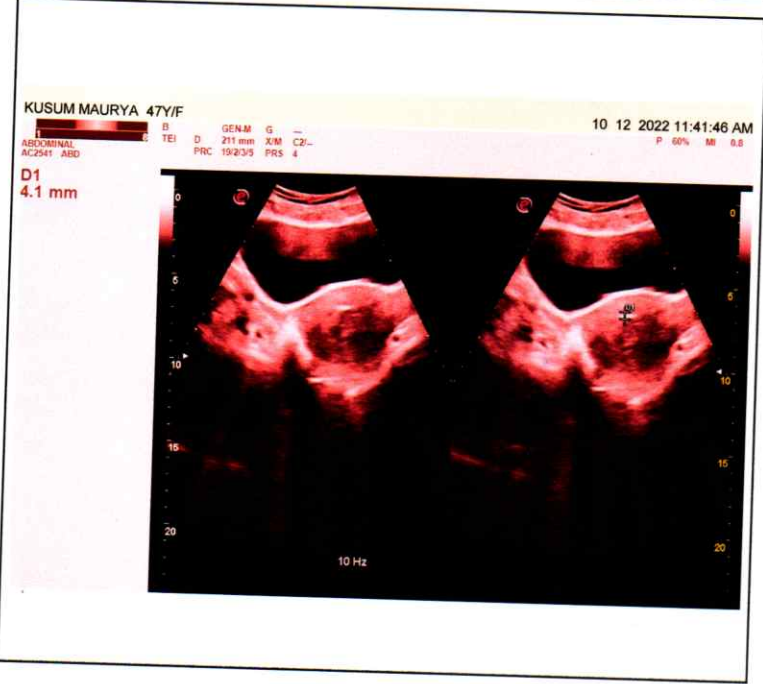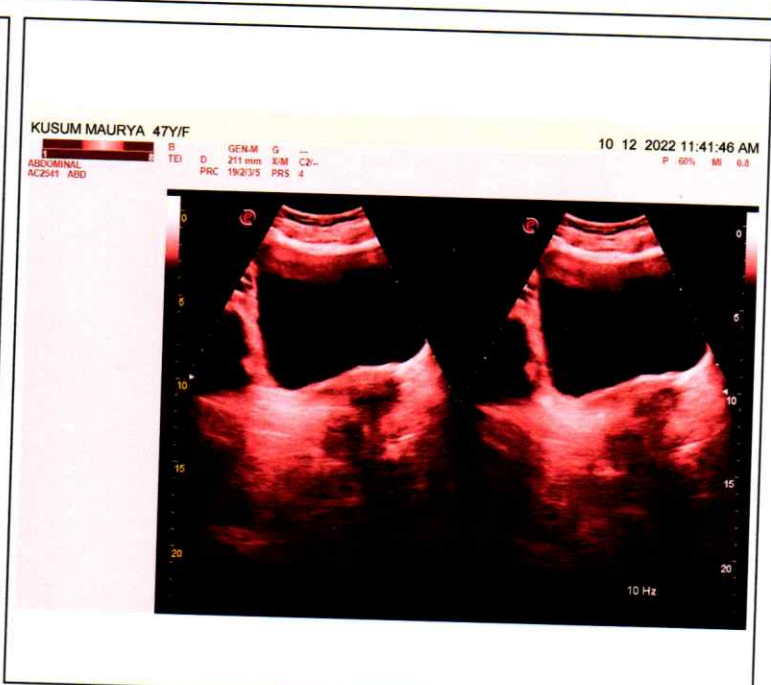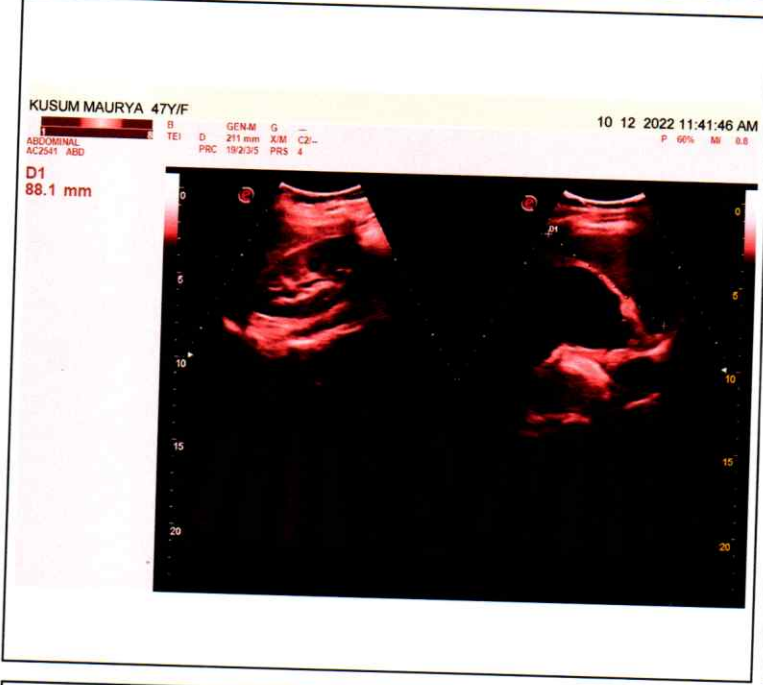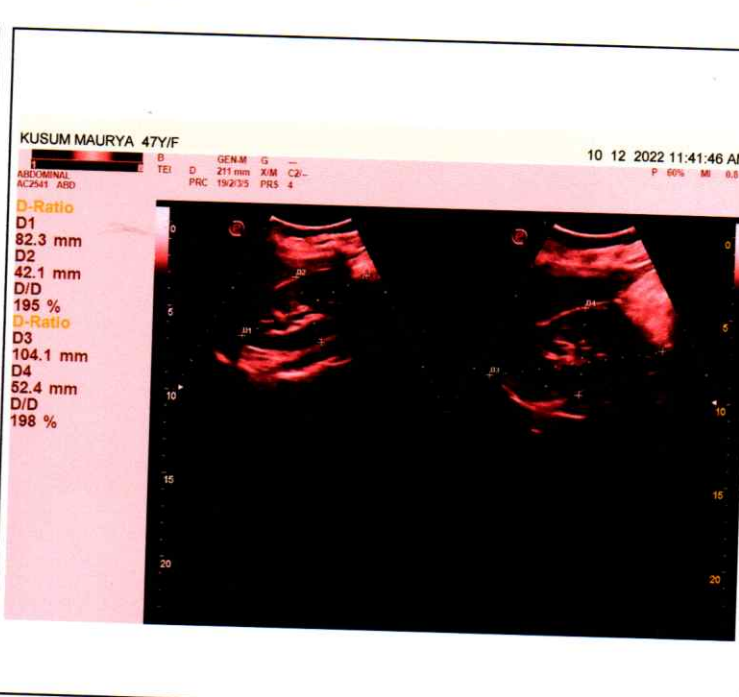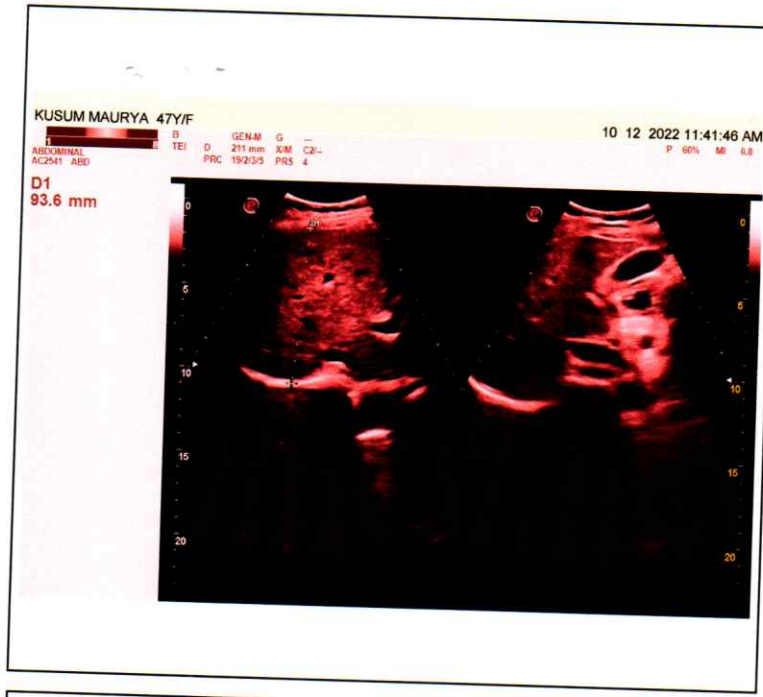Note: (1) This report is not valid for medico-legal purposes.

(2) In case of any discrepancy due typing error, please get it Rectified immediately.

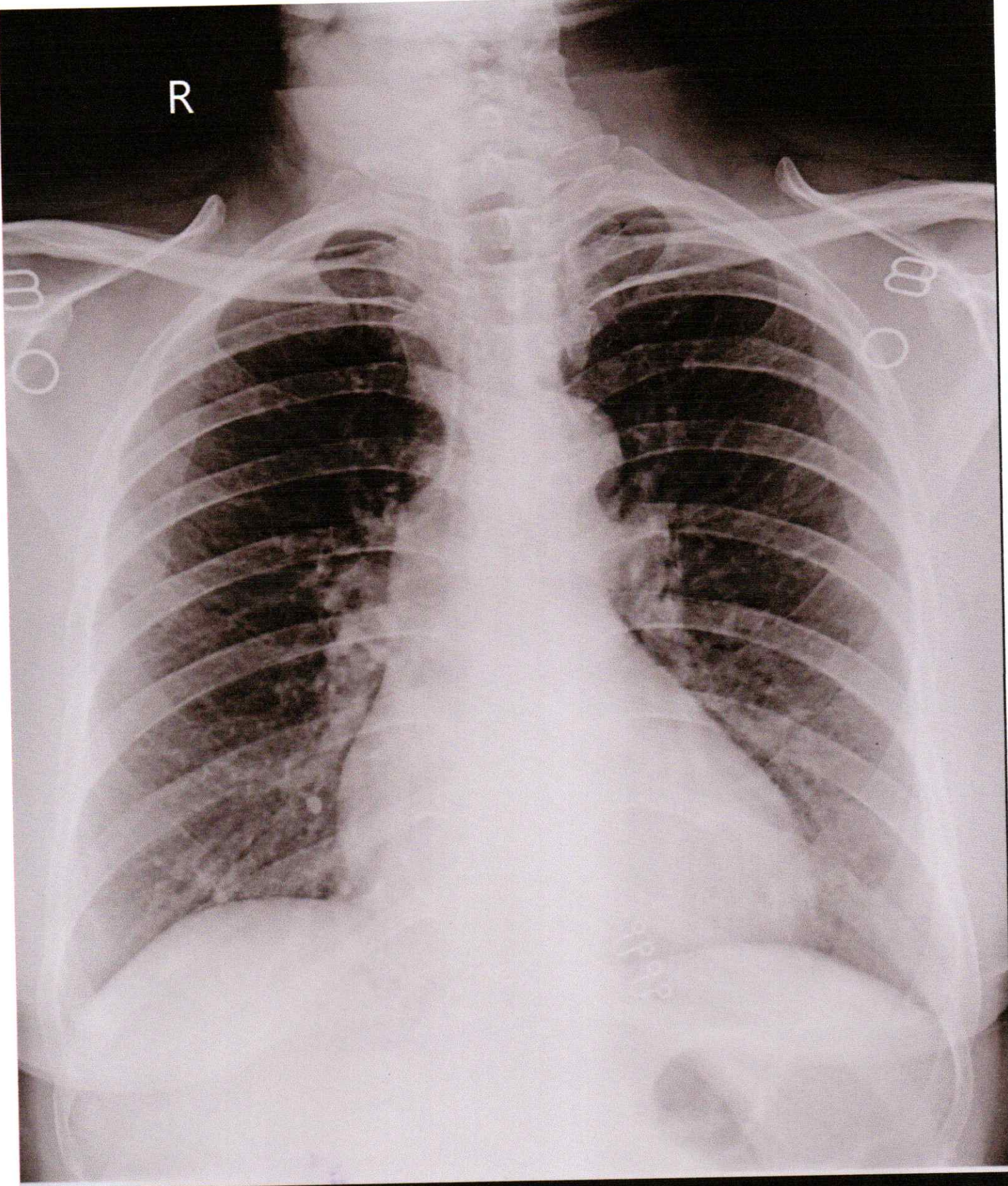
Address : Kabir Nagar (Near Sanjay Shiksha Niketan), Durgakund, Varanasi

Mobile : 9554572190 / 9453837595 / Recpn. 9389994334

E-mail : dramishra@gmail.com, drpallaviojha@gmail.com, Website: www.piire.org



R



KUSHUM MAURYA 45Y/F 2878 O CHEST P.A. 10-Dec-22 11:03 AM

PANACEA HOSPITAL, KABIR NAGAR, DURGAKUND, VARANASI