

Dr. B. M. ~~Sharma~~ ^{Arwal}
MEBS, DCP
Consultant Pathologist



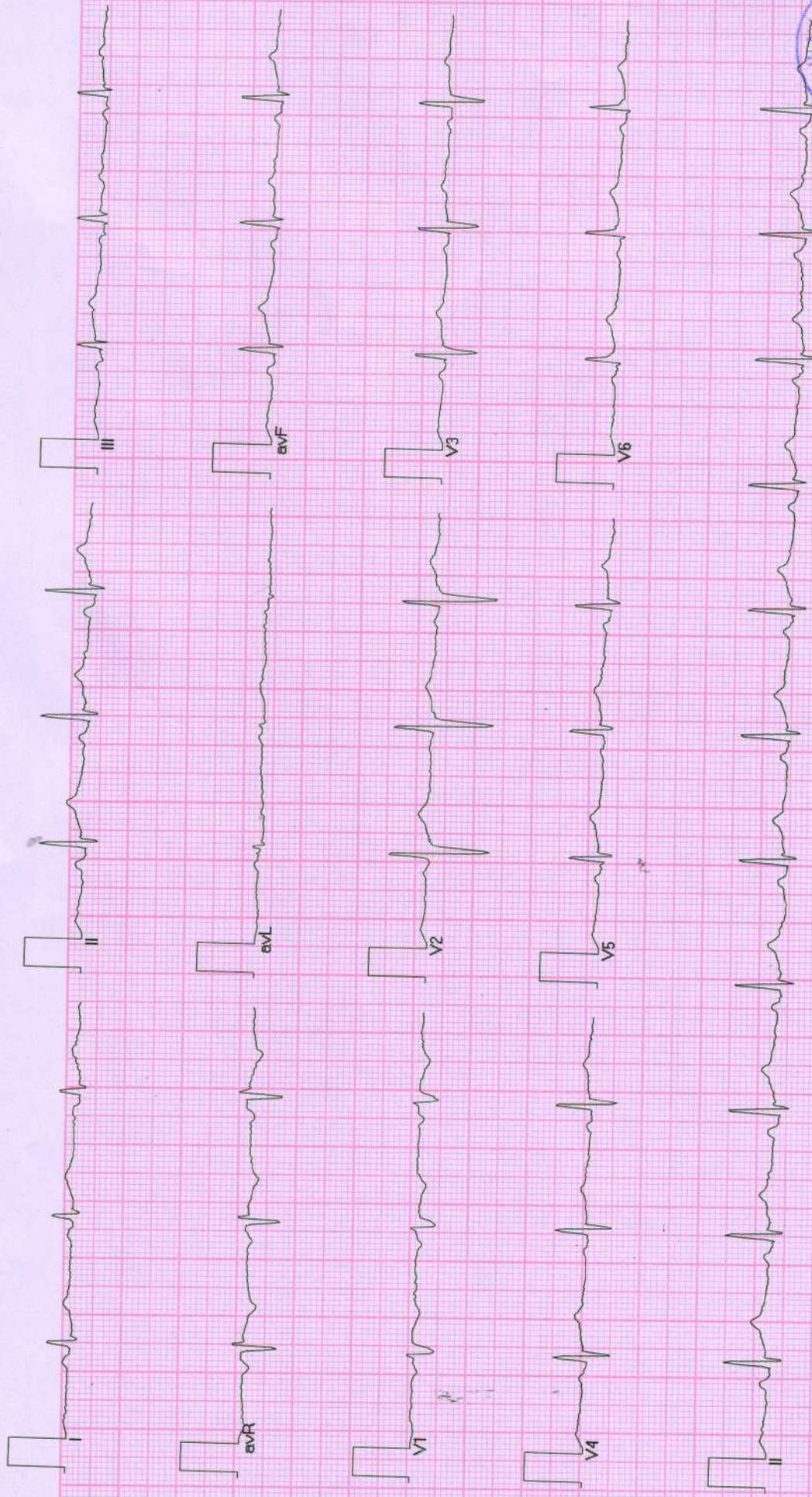
Signature



Allengers Global Healthcare Pvt Ltd.

97 / MR. SUJEET KUMAR SHRIVASTAVA / 50 Yrs / M / 182Cms. / 100Kgs.
Heart Rate : 68 bpm / Tested On : 02-Oct-21 13:11:34 / HF 0.05 Hz - LF 100 Hz / Notch 50 Hz / Sn 1.00 Cm/mV / Sw 25 mm/s
/ Refd By.: BOB

ECG



Srinivas

Allengers ECG (Pisces)(PIS213180317)



डिवाकर डायग्नोस्टिक सेन्टर

E-7/636, पञ्जाब नगर बक के पास, धन रोड, अरुण कॉलोनी अण्डाल (म.प.)

फोन: 0755-2465288, 0755-3520545 फा: 9826340190

Pt Name :	Mr. Sujeet Kumar Shrivastava
Age :	50y/M
Ref.By :	BOB
Lab. No. :	117
Date :	02/10/2021

EXAMINATION OF BLOOD

TEST	RESULT	NORMAL VALUE
Haemoglobin	16.2gms%	Female 12-16gms%, Male 14-18gms%
Red Cell count	5.8	4.5-5.6 million /cumm
Platelet Count	2.25	1.5-5.6 Lac/cumm
Leucocytes per.cu.mm	6700/cumm	5000-11000/cumm
Neutrophils	58%	50-70%
Lymphocytes	32%	20-40%
Eosinophils	06%	0-7%
Monocytes	04%	2-8%
PCV	42.8	37-47
MCV	82.9	76-96
MCH	31.5	27-32
MCHC	33.0	31-35
ESR	05	Male 0-9, Female 0-20mm/FHR
Blood Group	" AB"Positive	By Slide Method
S.Bilirubin(Total)	0.86	0.2-1.0mg/dl
Direct	0.33	0.0-0.25mg/dl
Indirect	0.53	
SGOT	32.0	5-35 U/L
SGPT	36.0	8-40 U/L
Alk Phosphatase	8.2	3-13 KA units
S. Protein(Total)	7.2	6.0-8.0mg%
Albumin	4.1	3.7-5.3mg%
Globulin	3.1	1.5 to 3.5 mg%
A/G Ratio	1.28	0.5-2.0
Blood Urea Nitrogen (BUN)	16.8	7-20 mg/dl
S.Creatinine	1.1	0.5-1.4mg/dl
S. Uric Acid	5.5	3.5-7.5mg%
Serum Calcium	9.0	8.8-10.2mg/dl
GGTP	33.5	5-35 U/L/dl
HIV 1&2	Negative	By Elisa method
HbsAg	Negative	By Card method
Random Blood Sugar	188.6	70 to 110 mg%
Total Serum Cholesterol	172.5	100-250 mg%
Serum Triglyceride	166.7	Up to 150 mg%
Serum Cholesterol HDL	47.2	Up to 65 mg%
Serum Cholesterol/LDL	91.9	Up to 125 mg%
LDL	33.3	Up to 30 mg%
TC/HDL Ratio	3.65	Below 5
Glycosylated Hemoglobin	8.1	Below - 6.0 % -Non Diabetic control 6-7 % -Excellent control Above- 8 % -Poor control

Dr. B. M. Agarwal
MBBS, DCP
Pathologist



All test have technical limitation. Collaborative clinic pathological interpretation is mandatory. In case of disparity test may be repeated immediately. Typographical mistakes should be get correct instantly. This report is not valid for medico legal purpose

All test have technical limitation. Collaborative clinic pathological interpretation is mandatory. This report is not valid for medico legal purpose



Dr. B. M. Karwal
Pathologist
Consultant Pathologist
DDP
In case of discrepancy test may be repeated immediately. Typographic

URINE COTININE	Negative	By Card method
----------------	----------	----------------

A. PHYSICAL EXAMINATION		C. MICROSCOPIE EXAMINATION
1. Colour	Yellow	Pus Cells 3-4/HPF
2. Appearance	Clear	R.B.C. Nil
3. Specific Gravity	Q.N.S.	Epithelial Cell Occ/HPF
B. CHEMICAL EXAMINATION		Cast Nil
1. Reaction	Acidic	Crystals (Cal. Oxa) Nil
2. Albumin	Absent	Bacteria Nil
3. Sugar	Nil	Amorphous Nil
4. Bile Salts	Absent	T. Vaginatis Nil

URINE ANALYSIS

Pt Name :	Mr. Sujeet Kumar Shrivastava
Age :	50y/M
Ref. By :	BOB
Lab. No. :	117
Date :	02/10/2021



All test have technical limitation. Collaborative clinic pathological interpretation is mandatory. In case of disparity test may be repeated immediately. Typographic mistakes should be get correct instantly. This report is not valid for medico legal purpose

Dr. B. M. Arora
MBBS, DCP
Pathologist
Consultant Pathologist

TEST	RESULT	NORMAL VALUE
T3-Total	96.5	82-213 ng/dL
T4-Total	6.16	6.09-12.23ug/dL
THYROID STIMULATING HORMONE (TSH)	2.85	0.45-4.25u/ml

Thyroid profile, Total (T3T4TSH)

EXAMINATION OF BLOOD

Pt Name	: Mr. Sujeet Kumar Shrivastava
Age	: 50y/M
Ref.By	: BOB
Lab. No.	: 117
Date	: 02/10/2021





All test have technical limitation. Collaborative clinic pathological interpretation is mandatory. In case of disparity test may be repeated immediately. Typographic mistakes should be get correct instantly. This report is not valid for medico legal purpose

Dr. B. M. Arwal
MBBS, DCP
Pathologist
Consultant Pathologist

TEST	RESULT	NORMAL VALUE
PSA	4.10ng/ml.	0.21-6.77 ng/ml.

EXAMINATION OF BLOOD

Pt Name :	Mr. Sujeet Kumar Shrivastava
Age :	50y/M
Ref.By :	BOB
Lab. No. :	117
Date :	02/10/2021

डिवाकर डायग्नोस्टिक सेंटर
E-7/636, पंचाल रेणुमल बैंक के पास, फोन रोड, अरुण कॉलोनी थापाल (म.प्र.)
फोन: 0755-2465288, 0755-3520545 फॉ: 9826340190





Dr. B. M. Agarwal
MD, Radiology
Consultant Radiologist

-NO CARDIO PULMONARY PATHOLOGY
-CORRELATE WITH CLINICAL FINDINGS.

IMPRESSION

Both domes and diaphragm normal

Both cp angles clear

Cardiac border normal

Both hilers normal

Both Lungs Field Clear.

Thoracic cage normal

Tricia Central

.....
REPORT

Pt Name :	Mr. Sujeet Kumar Shrivastava
Age :	50y/M
Ref.By :	BOB
Lab. No. :	117
Date :	02/10/2021
Skigram	X Ray Chest PA View
Radiologist	Dr. B.M.Agarwal MD (Radiology)

डिवाकर डायग्नोस्टिक सेंटर



E-7/636, पंजाब नगरपाल बँक के पास, मन रोड, अरुण कॉलोनी भापाल (म.प्र.)
फोन: 0755-2465288, 0755-3520545 फा: 9826340190

2.4 cm pt. Residual calculus is noted.
is noted

Right kidney is normal in size, shape and position. Corticomedullary differentiation (CMD) is well maintained. Normal cortical thickness is noted. No E/O hydronephrosis or calculus is noted.

No evidence of free fluid is noted.

No evidence of lymphadenopathy is noted.

IVC and aorta appear to be normal.

Spleen is normal in size and echo texture.

Pancreas appear normal in size, shape and echo texture with smooth contour. No peripancreatic pathology seen. (Not seen due to gases)

Common duct reveals normal course and caliber.

Gall Bladder is physiologically well distended. No E/O echogenic foci in GB lumen. GB wall is normal / thickened. No E/O pericholecystic collection.

No E/O subdiaphragmatic collection.

Liver appears normal in size and shape with normal outline. Normal/ increased parenchymal echogenicity is noted. No E/O focal lesion/ IHRB dilatation is seen. Hepatic veins and portal veins appear normal.

Liver appears normal in size and shape with normal outline. Normal/ increased parenchymal echogenicity is noted. No E/O focal lesion/ IHRB dilatation is seen. Hepatic veins and portal veins appear normal.

Liver appears normal in size and shape with normal outline. Normal/ increased parenchymal echogenicity is noted. No E/O focal lesion/ IHRB dilatation is seen. Hepatic veins and portal veins appear normal.

Indication:

WHOLE ABDOMEN ULTRASOUND REPORT

Name: Mr. Jayant Shrivastava
R/B: Health check-up
Age: 50 YRS./Male
Date: 2/10/2021



डॉ. सविता क्लिनिक
34, भूतल, मोहिनी आर्टि आर्कड, शाहपुरा मस्जिद के पास
भरत नगर रोड, ई-7/194, अररा कॉलोनी, भीमल - 462038
Mob.: 8989649694, 9516333619
Clinic Registration: CL/5392/Jun/2017
PNDT Registration: MPPCPNDT/BPL/2017/206



Advised clinical Correlation.

Impression: ~~Normal study.~~
Cyst 2.4 cm
Grade III
Right Renal Sinus
with fatty liver
Peak MRA

Left Ovary appears enlarged/Normal in size, shape and echo texture.

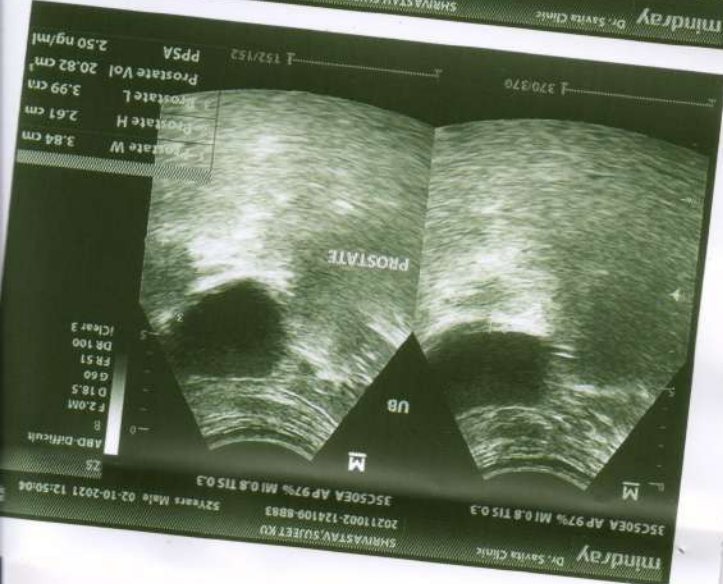
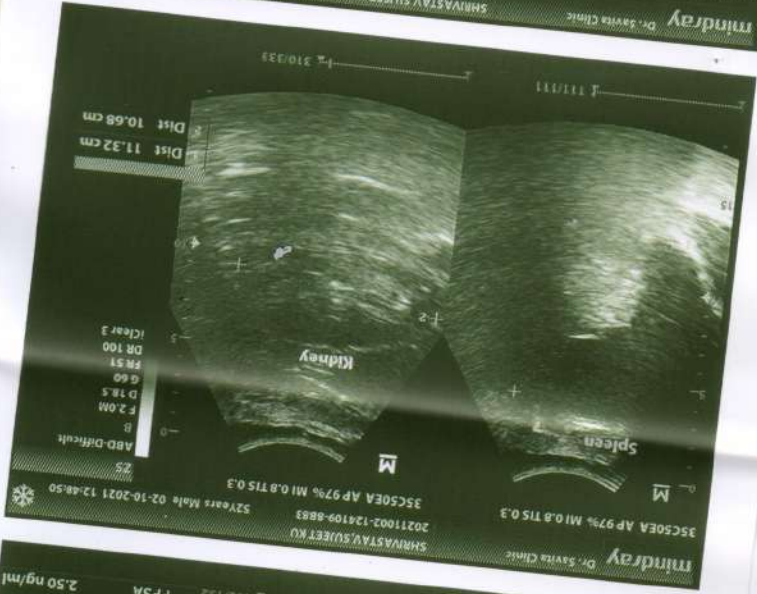
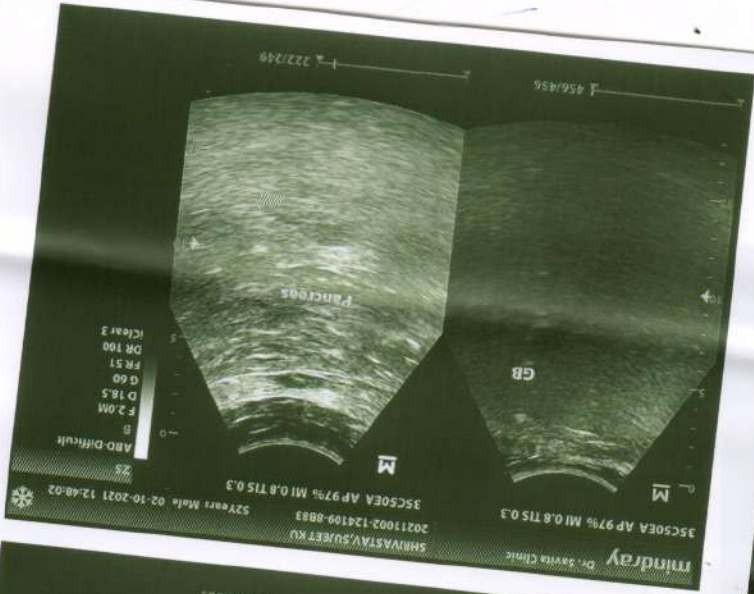
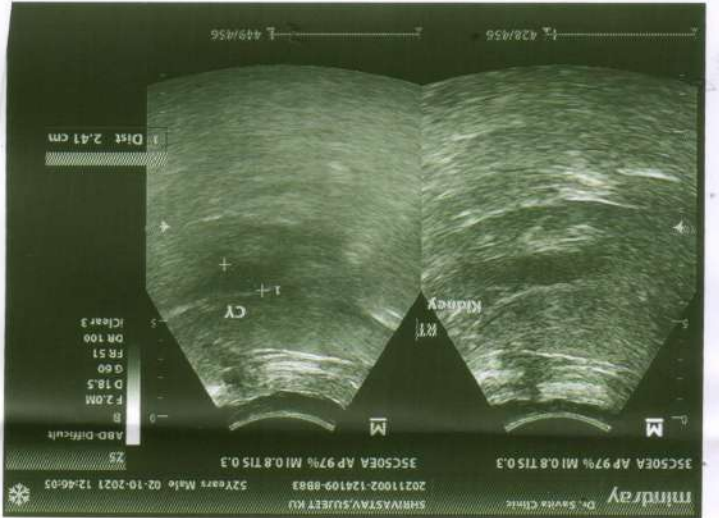
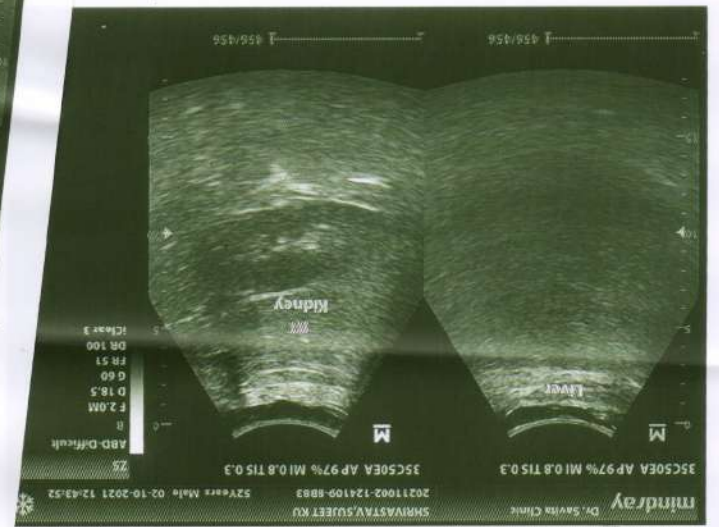
Right Ovary appears enlarged/Normal in size, shape and echo texture.

Uterus is ante/retro verted and normal in size, shape and echotexture with smooth outline. No E/O focal lesion is noted. Endometrial echo appear normal. Cervical and vaginal shadows appear normal.

Prostate is normal in size. Shape and echo texture with smooth outline. No E/O focal lesion is noted.

Urinary Bladder is well distended (physiological). its contents are echo free. No E/O bladder wall thickening is noted. Post void residue is insignificant.

Left Kidney is normal in size, shape and position. CMD is well maintained. Normal cortical thickness is noted. No E/O hydronephrosis or calculus is noted.





Report :

TEST OBJECTIVE	: ROUTINE CHECK UP
RISK FACTOR	: HYPERTENSION
ACTIVITY	: MODERATE ACTIVE
MEDICATION	: TAB ATEND
OTHER INVESTIGATION	: ROUTINE BLOOD INVESTIGATION, X RAY
REASON FOR TERMINATION	: FATIGUE, FEELING UNCOMFORTABLE
EXERCISE TOLERANCE	: FAIR
EXERCISE INDUCED ARRHYTHMIAS	: NO
HAEMODYNAMIC RESPONSE	: NORMAL
CHRONOTROPIC RESPONSE	: ABNORMAL
FINAL IMPRESSION	: STRESS TEST IS NEGATIVE FOR EXERCISE INDUCED ISCHAEMIC HEART DISEASE



Doctor : Cardiologist

433 / MR. SUJEET KUMAR SHRIVASTAVA / 50 Yrs / M / 182 Cms / 100 Kg Date: 02-Oct-2021 Refd By : BOB

Stage	Time	Duration	Belt Speed (mph)	Elevation	MEts	Rate	% THR Achieved	BP	RPP	PVC	Comments
Supine	00:11	0:01	00.0	00.0	01.0	65	38 %	130/80	084	00	
Standing	00:19	0:01	00.0	00.0	01.0	65	38 %	130/80	084	00	
HV	00:25	0:01	00.0	00.0	01.0	069	41 %	130/80	089	00	
Warm Up	00:41	0:01	01.0	00.0	01.0	060	35 %	130/80	078	00	
ExStart	00:53	0:06	01.7	10.0	01.1	069	41 %	130/80	089	00	
BRUCE Stage 1	03:53	3:00	01.7	10.0	04.7	104	61 %	140/90	145	00	
PeakEx	05:28	1:35	02.5	12.0	06.0	116	68 %	150/96	174	00	
Recovery	06:27	1:00	00.0	00.0	01.0	099	58 %	150/90	148	00	
Recovery	07:27	2:00	00.0	00.0	01.0	072	42 %	140/80	100	00	
Recovery	07:40	2:12	00.0	00.0	01.0	071	42 %	140/80	099	00	

Findings :

Exercise Time : 04:36
 Max HR Attained : 116 bpm 68% of Target 170
 Max BP Attained : (Sys) 150/96
 Max Workload Attained : 6 Fair response to induced stress
 Test End Reasons : Fatigue, Feeling Uncomfortable

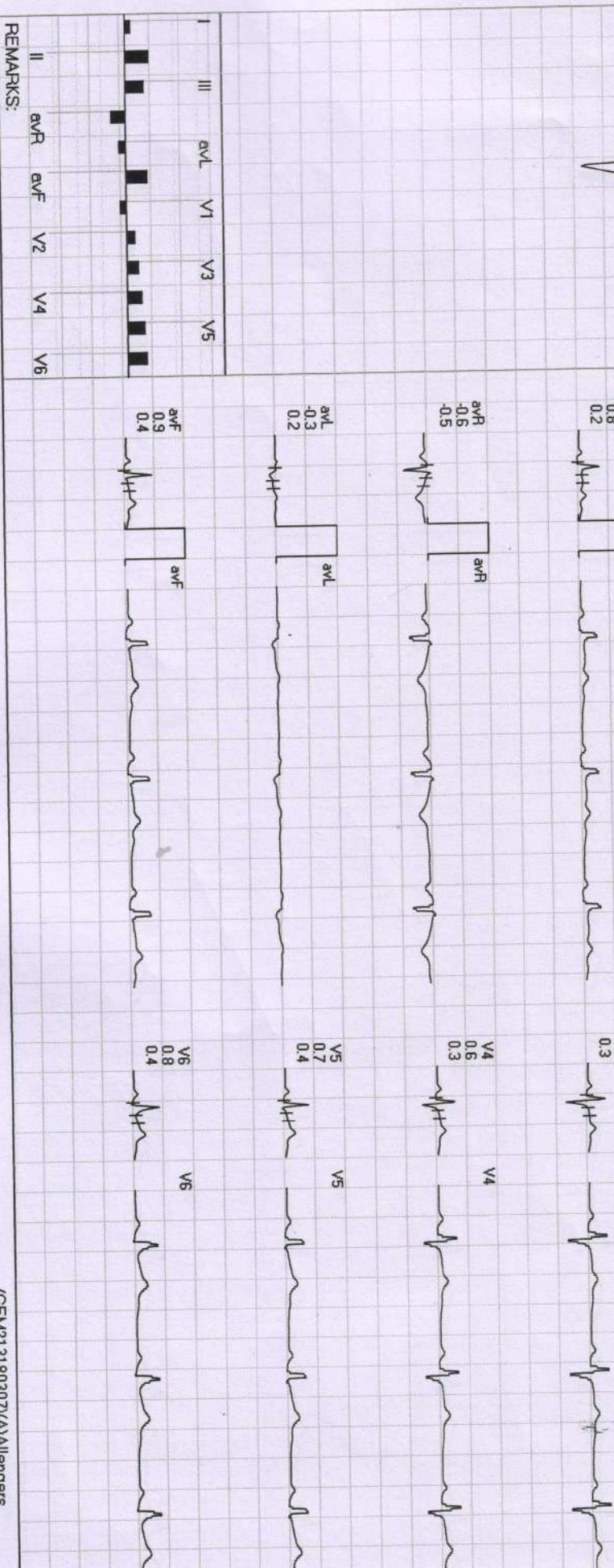
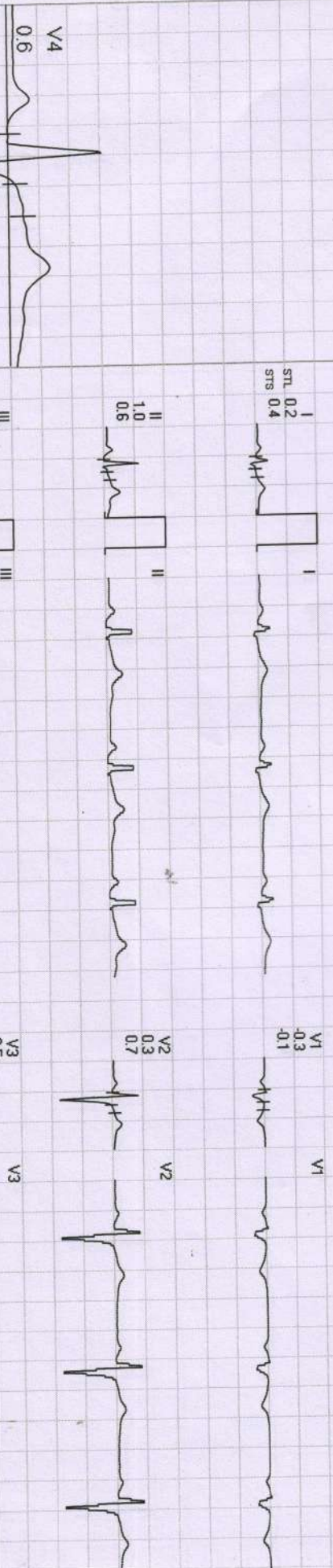
Doctor : Cardiologist

433 / MR. SUEET KUMAR SHRIWASTAVA / 50 YRS / M / 182 Cms / 100 Kg / HR : 65

Date: 02-Oct-2021 01:12:33 PM METS: 1.0/ 65 bpm 38% of THR BP: 130/80 mmHg Raw ECG/ BLC On/ Notch On/ HF 0.05 Hz/LF 20 Hz

ExTime: 00:10 0.0 mph, 0.0%
25 mm/Sec. 1.0 Cm/mV

4X 80 ms Post J



REMARKS:



483/MR. SUEET KUMAR SHRIVASTAVA / 50 Yrs / M / 182 Cms / 100 Kg / HR : 65

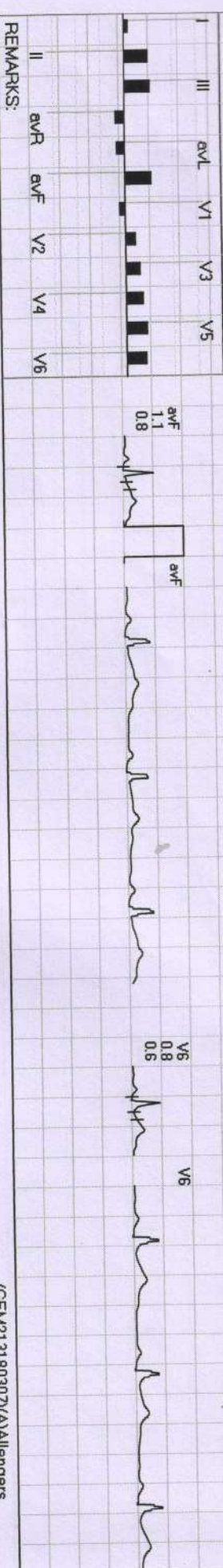
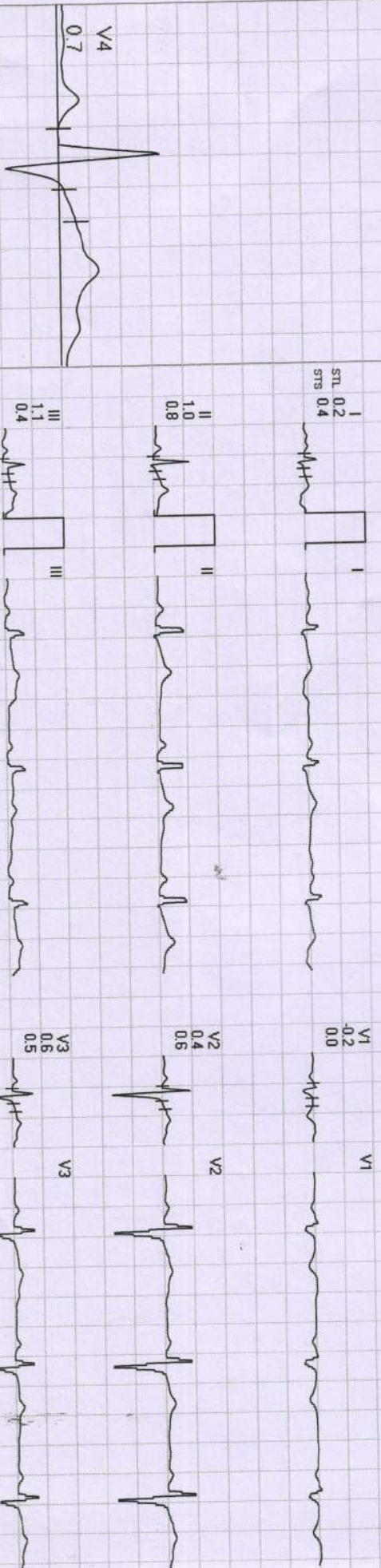
Date: 02-Oct-2021 01:12:33 PM

METS: 1.0/ 65 bpm 38% of THR BP: 130/80 mmHg Raw ECG/ BLC On/ Notch On/ HF 0.05 Hz/LF 20 Hz

EXTime: 00:18 0.0 mph, 0.0%

25 mm/Sec. 1.0 Cm/mV

4X 80 ms Post J



REMARKS:

433 / MR. SUEET KUMAR SHRIVASTAVA / 60 Yrs / M / 182 Cms / 100 Kg / HR : 69

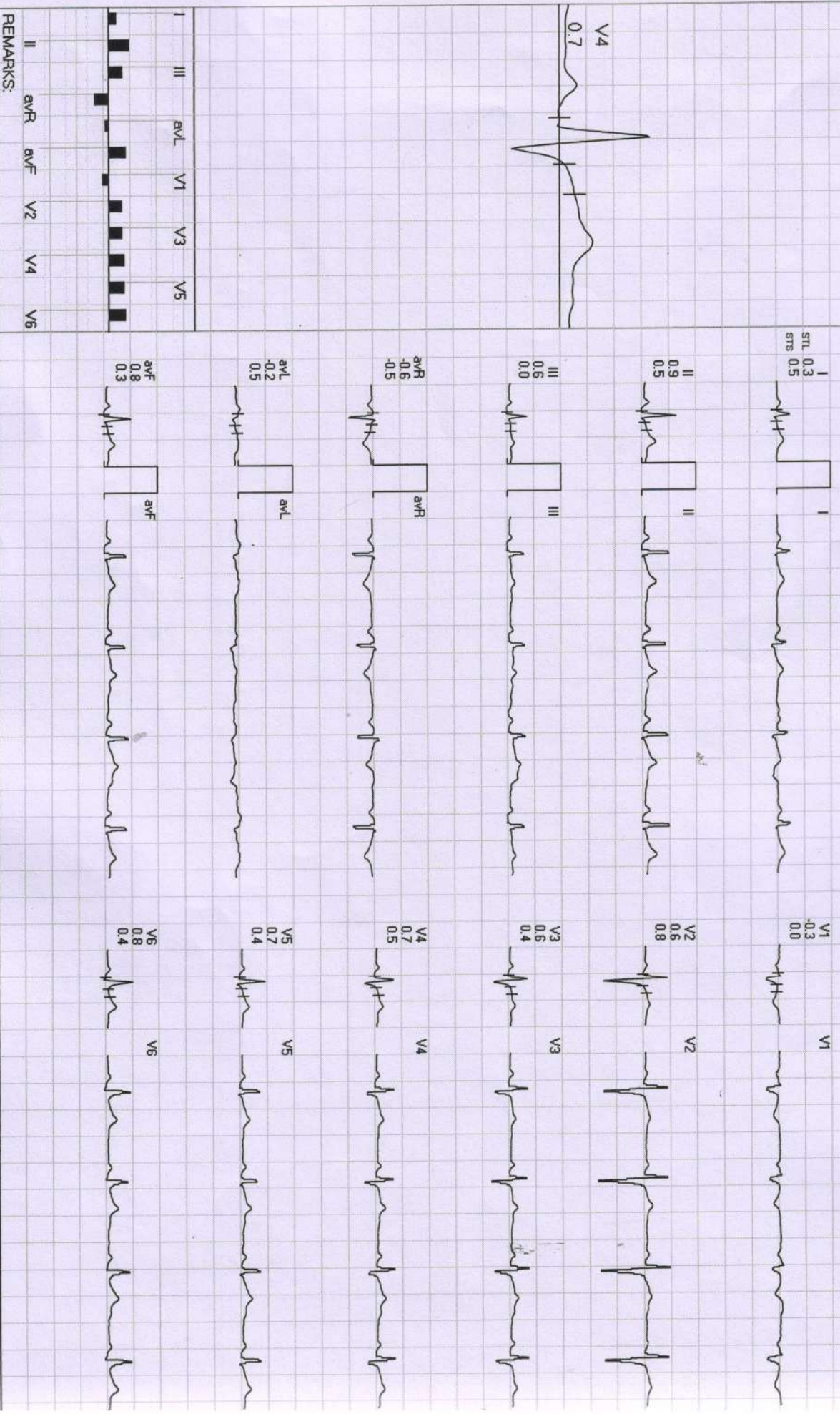
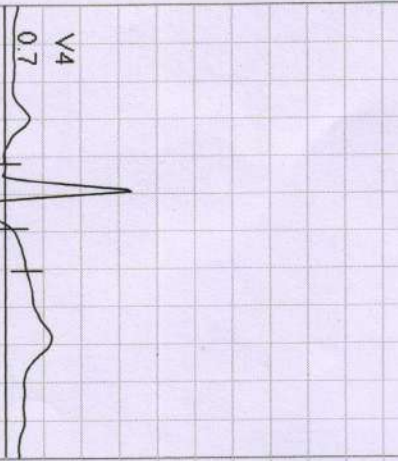
Date: 02-Oct-2021 01:12:33 PM

METS: 1.0 / 69 bpm 40% of THR BP: 130/80 mmHg Raw ECG/ BLC On/ Notch On/ HF 0.05 Hz/ LF 20 Hz

EXTime: 00:24 0.0 mph 0.0%

4X 90 ms Post J

25 mm/Sec. 1.0 Cm/mV



REMARKS:

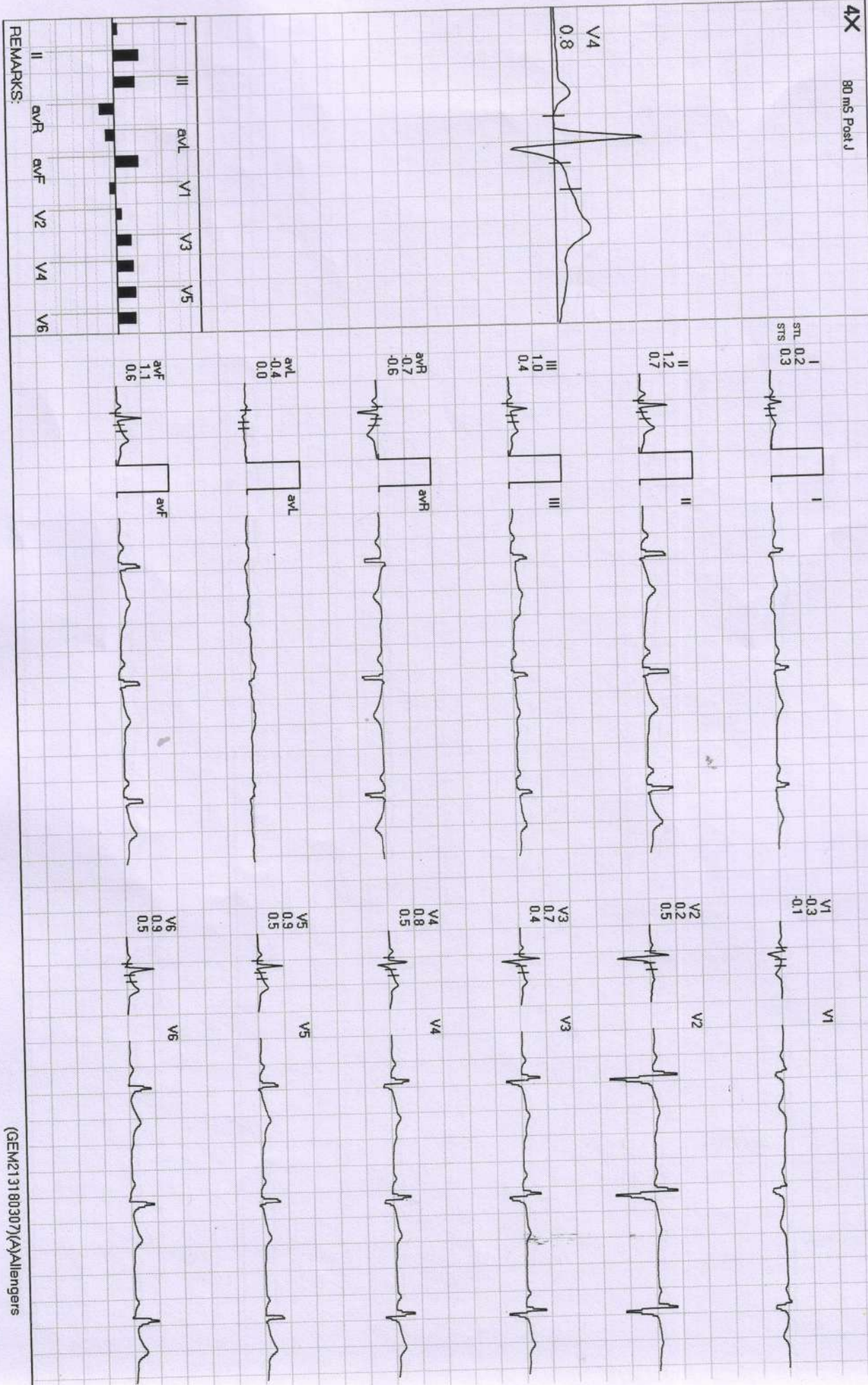
433 / MR. SUEET KUMAR SHRIVASTAVA / 50 Yrs / M / 182 Cms / 100 Kg / HR : 60

Date: 02-Oct-2021 01:12:33 PM

METS: 1.0/ 60 bpm 35% of THR BP: 130/80 mmHg Raw ECG/ BLC On/ Notch On/ HF 0.05 Hz/LF 20 Hz

ExTime: 00:40 1.0 mph, 0.0%
25 mm/Sec. 1.0 Cm/mV

4X 80 mS Post J




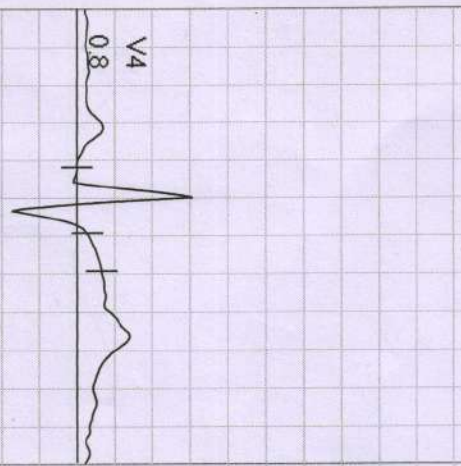
433 / MR. SUEET KUMAR SHRIWASTAVA / 60 Yrs / M / 182 Cms / 100 Kg / HR : 65

Date: 02-Oct-2021 01:12:33 PM METS: 1.0/ 65 bpm 38% of THR BP: 130/80 mmHg Raw ECG/ BLC On/ Natch On/ HF 0.05 Hz/ LF 20 Hz

EXTime: 00:00 0.0 mph, 0.0%

4X 80 ms Post J

25 mm/Sec. 1.0 Cm/mV



REMARKS:



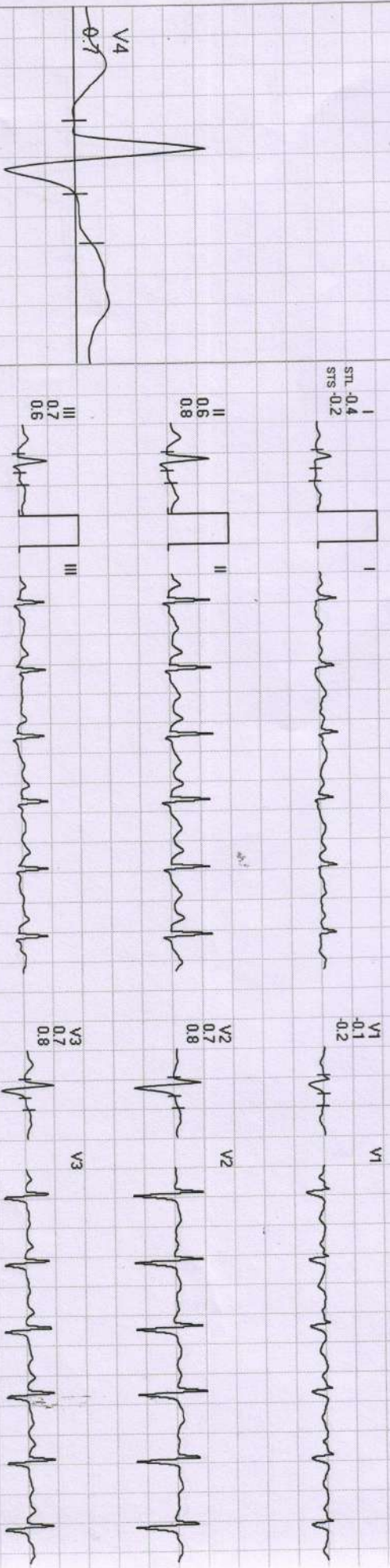
433 / MR. SUEET KUMAR SHRIVASTAVA / 50 Yrs / M / 182 Cms / 100 Kg / HR : 104

Date: 02-Oct-2021 01:12:33 PM METS: 4.7 / 104 bpm 61% of THR BP: 140/90 mmHg Raw ECG/BLC On/ Notch On/ HF 0.05 Hz/LF 20 Hz

EXTime: 03:00 1.7 mph, 10.0%

4X 80 mS Post J

25 mm/Sec. 1.0 Cm/mV



I	III	aVL	V1	V3	V5
II	aVR	aVF	V2	V4	V6

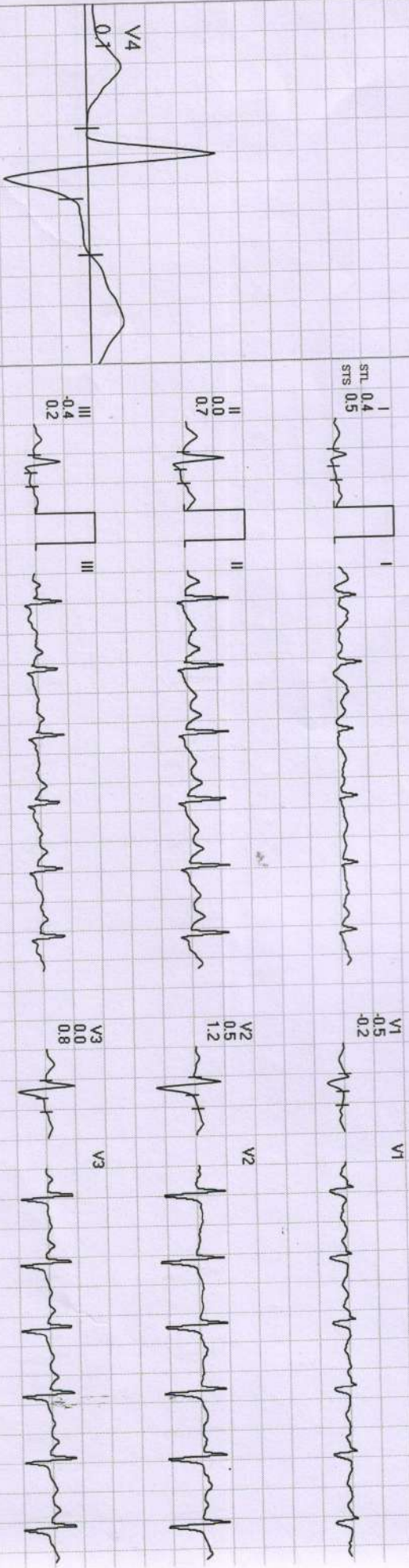
REMARKS:

433 / MR. SUEET KUMAR SHRI/VASTAVA / 60 YRS / M / 182 Cms / 100 Kg / HR : 116

Date: 02-Oct-2021 01:12:33 PM METS: 6.0 / 116 bpm 68% of THR BP: 150/96 mmHg Raw ECG/ BLC On/ Notch On/ HF 0.05 Hz/LF 20 Hz

EXTime: 04:35 2.5 mph, 12.0%
25 mm/Sec. 1.0 Cm/mV

4X 90 mS Post J



REMARKS:

Diwakar Diagnostic Centre

433/MR. SUEET KUMAR SHRIVASTAVA /50 Yrs /M/182 Cms/100 Kg/HR : 99

Recovery : (01:00)



Date: 02-Oct-2021 01:12:33 PM

METS: 1.0/ 99 bpm 58% of THR

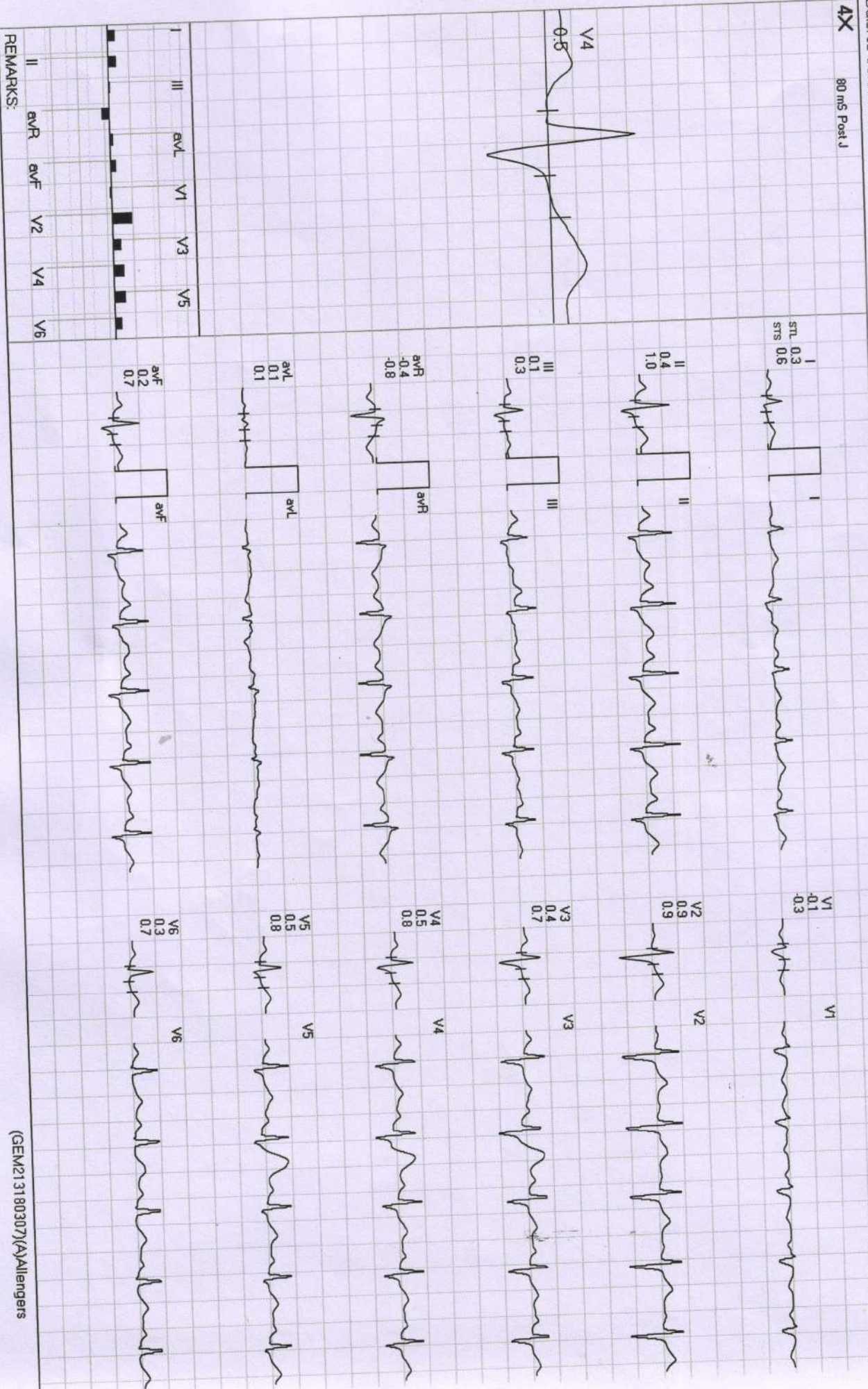
BP: 150/90 mmHg Raw ECG/ BLC On/Notch On/HF 0.05 Hz/LF 20 Hz

EXTime: 04:35 0.0 mph, 0.0%

25 mm/Sec. 1.0 Cm/mV

4X

80 mS Post J



REMARKS: