

Facilities:
 All clinical Biomedical & Hematology Investigations
 including Bone Marrow Examination
 VPT, Podiascan & Complete Foot Care (First Time in Purvanchal)
 All Hormonal Investigation by Chemiluminescent Method
 Visceral Fat by (AB-140) Ambulatory BP Monitoring
 CGMS & Insulin Pump Available
 PFT, 2D-ECHO (Color Doppler), Holter, TMT, Cardiac-3 available
 VIA, VILI, Colposcopy available
 Special Endocrinological Investigation Protocols.

ISO 9001:2008 Certified
 Mobile: 9389994334, 9554572190, 9453837595



Panacea Pathology

Clinical Reference Lab

Persistence, Preparedness and Precision
 EQAS (CMC Vellore Attached) & IQAS System
 पूर्वांचल की सर्वोत्तम गुणवत्ता वाली पैथोलॉजी

PATIENT NAME : SHRI RAM ARYA

AGE/GENDER : 56YRS/MALE

REFD BY DR. : ARCO FEMI HEALTHCARE LTD.

RECEIVED DATE : 25-03-2023 (09:00 AM)

SAMPLE : BLOOD & URINE

REPORT DATE : 25-03-2023 (07:00 PM)

PATHOLOGY REPORT

COMPLETE BLOOD COUNT (CBC)

TEST	LAB TEST VALUES	NORMAL RANGE
HEMOGRAM		
HEMOGLOBIN (FLOW CYTOMETRY)	13.6	13 – 16 gm/dl
TOTAL LEUCOCYTE COUNT (TLC)	5,700	4000 – 11000
RBC COUNT	4.76	3.5 – 5.5
PCV (HCT)	42.8	37 – 47
MCV	89.9	80 – 95
MCH	28.5	28 – 34
MCHC	31.8	30 – 36
PLATELET COUNT	2,01,000	1,50,000 – 4,00,000
E.S.R. (WINTROBE FIRST HOURS)	10.0	20 mm/1 st hr
DIFFERENTIAL LEUCOCYTE		
NEUTROPHILS	53	40 – 75%
LYMPHOCYTES	41	20 – 45%
EOSINOPHILS	03	1 – 6%
MONOCYTES	03	2 – 8%
BASOPHILS	00	< 2%

RANDOM/FASTING BLOOD SUGAR

TEST	LAB TEST VALUES	NORMAL RANGE
RBS/FBS		
RANDOM BLOOD SUGAR	135.0	125-140 mg/dl
FASTING BLOOD SUGAR	88.0	70-125 mg/dl

GLYCOSYLATED HEMOGLOBIN (HBA1C)

TEST	LAB TEST VALUES	NORMAL RANGE
HBA1C	6.4	Normal : <5.97 % Good Control : 5.97 – 6.81% Fair Control : 6.81 – 7.65% Poor Control : >7.65%

PAGE 1

PANACEA HOSPITAL
 UNIT OF ARCO HEALTH CARE PVT. LTD.)
 REG. NO.: AL-1500
 B.36/44, B-4, KABIR NAGAR
 DURGAKUND, VARANASI
 M.D. Pathology

Lab Technician

Timing : 8.00 a.m. to 9.00 p.m. (Sunday 8.00 a.m. to 3.00 p.m.)

This Report is not valid for medico legal purpose

Note: These tests have technical limitations. Clinico-pathological interpretation is necessary. In case of any disparity test may be repeated immediately.

Address : 36/44 FK Kabir Nagar, Durgakund, Varanasi – 221005

Email: dramishra@gmail.com, drpallaviojha@gmail.com Website: panaceahospital.org

Facilities:

All clinical Biomedical & Hematology Investigations including Bone Marrow Examination
VPT, Podiascan & Complete Foot Care (First Time in Purvanchal)
All Hormonal Investigation by Chemiluminescent Method
Visceral Fat by (AB-140) Ambulatory BP Monitoring
CGMS & Insulin Pump Available
PFT, 2D-ECHO (Color Doppler), Holter, TMT, Cardiac-3 available
VIA, VILI, Colposcopy available
Special Endocrinological Investigation Protocols.

ISO 9001:2008 Certified
Mobile: 9389994334, 9554572190, 9453837595



Panacea Pathology

Clinical Reference Lab

Persistence, Preparedness and Precision
EQAS (CMC Vellore Attached) & IQAS System
पूर्वाचल की सर्वोत्तम गुणवत्ता वाली पैथोलॉजी

PATIENT NAME : SHRI RAM ARYA

AGE/GENDER : 56YRS/MALE

REFD BY DR. : ARCO FEMI HEALTHCARE LTD.

RECEIVED DATE : 25-03-2023 (09:00 AM)

SAMPLE : BLOOD & URINE

REPORT DATE : 25-03-2023 (07:00 PM)

PATHOLOGY REPORT

LIPID PROFILE, SERUM

TEST	LAB TEST VALUES	NORMAL RANGE
BLOOD CHEMISTRY		
TOTAL CHOLESTEROL (SERUM)	174.0	Desirable:- < 200 mg/dl Borderline:- 200 – 239 mg/dl High:- > 240 mg/dl
TRIGLYCERIDES (SERUM)	168.0	35 – 170 mg/dl
HDL CHOLESTEROL (SERUM)	46.0	35.30 – 79.50 mg/dl
LDL CHOLESTEROL (SERUM)	94.4	< 130 mg/dl
VLDL	33.6	< 40 mg/dl
CHOLESTROL/HDL RATIO	3.78	< 3.0 Low Risk Ratio 3.0 – 5.0 Avg Risk < 5.0 High Risk
LDL/HDL RATIO	2.05	< 3 Ratio

BLOOD GROUP

TEST	LAB TEST VALUES
BLOOD GROUP ABO & RH FACTOR	
BLOOD GROUP	"B"
RH FACTOR	POSITIVE

LIVER PROFILE TEST, SERUM

TEST	LAB TEST VALUES	NORMAL RANGE
BIO CHEMISTRY		
TOTAL BILIRUBIN	0.71	0.0 – 1.1 mg/dl
DIRECT BILIRUBIN	0.29	0.0 – 0.2 mg/dl
INDIRECT BILIRUBIN	0.42	< 0.90 mg/dl
SGOT (AST)	24.0	0 – 52 mg/dl
SGPT (ALT)	28.0	0 – 39 mg/dl
GGT (GYT)	20.0	< 55 U/L

THYROID PROFILE (T3, T4, TSH)

TEST	LAB TEST VALUES	NORMAL RANGE
THYROID FUNCTION TEST		
T3	1.01	0.60 – 1.81 ng/ml
T4	7.56	4.50 – 10.90 ug/dl
TSH	3.49	0.39 – 6.10 uIU/mL

PAGE 2

Lab Technician

PANACEA HOSPITAL
(A UNIT OF AAROHA HEALTHCARE PVT. LTD.)
REG. NO. 1500
M.D. Pathology
B.36/44, B-4, KABIR NAGAR
DURGAKUND, VARANASI

Timing : 8.00 a.m. to 9.00 p.m. (Sunday 8.00 a.m. to 3.00 p.m.)

This Report is not valid for medico legal purpose

Note: These tests have technical limitations. Clinico-pathological interpretation is necessary. In case of any disparity test may be repeated immediately.

Address : 36/44 FK Kabir Nagar, Durgakund, Varanasi – 221005

Email: dramishra@gmail.com, drpallaviojha@gmail.com Website: panaceahospital.org

Facilities:

All clinical Biomedical & Hematology Investigations including Bone Marrow Examination
VPT, Podiascan & Complete Foot Care (First Time in Purvanchal)
All Hormonal Investigation by Chemiluminescent Method
Visceral Fat by (AB-140) Ambulatory BP Monitoring
CGMS & Insulin Pump Available
PFT, 2D-ECHO (Color Doppler), Holter, TMT, Cardiac-3 available
VIA, VILI, Colposcopy available
Special Endocrinological Investigation Protocols.

ISO 9001:2008 Certified
Mobile: 9389994334, 9554572190, 9453837595



Panacea Pathology

Clinical Reference Lab

Persistence, Preparedness and Precision
EQAS (CMC Vellore Attached) & IQAS System
पूर्वाचल की सर्वोत्तम गुणवत्ता वाली पैथोलॉजी

PATIENT NAME : SHRI RAM ARYA

AGE/GENDER : 56YRS/MALE

REFD BY DR. : ARCO FEMI HEALTHCARE LTD.

RECEIVED DATE : 25-03-2023 (09:00 AM)

SAMPLE : BLOOD & URINE

REPORT DATE : 25-03-2023 (07:00 PM)

PATHOLOGY REPORT

RENAL & KIDNEY PROFILE, SERUM

TEST	LAB TEST VALUES	NORMAL RANGE
RENAL FUNCTION TESTS		
BLOOD UREA NITROGEN (BUN)	10.4	10 – 50 mg/dl
SERUM CREATININE	0.97	0.60 – 1.60 mg/dl
URIC ACID	3.56	3.60 – 7.70 mg/dl
ALKALINE PHOSPHATASE (ALP)	88.0	142 – 353 mg/dl
TOTAL PROTIENS	7.59	0 – 39 mg/dl
ALBUMIN	4.31	3.8 – 5.4 mg/dl
SERUM GLOBULIN	3.28	2.1 – 3.5 mg/dl
AG RATIO	1.31	-
CALCIUM	9.15	8.80 – 10.20
PHOSPHORUS	3.04	2.50 – 5.00
SERUM SODIUM NA+	137.6	135.00 – 155.00 mEq/Ltr
SERUM POTASIAM K+	4.32	3.60 – 5.50 mEq/Ltr
ICALCIUM	1.24	1.10 – 1.35 mmol/L
SERUM CHLORIDE CL+	103.2	98.00 – 110.00 mEq/Ltr

URINE ROUTINE EXAMINATION

TEST	LAB TEST VALUES	NORMAL RANGE
PHYSICAL EXAMINATION		
QUANTITY	30	ML
COLOUR	STRAW	PALE YELLOW
APPEARANCE	CLEAR	CLEAR
SPECIFIC GRAVITY	1.010	1.01 – 1.03
PH	6.0	4.7 – 7.5
CHEMICAL EXAMINATION		
GLUCOSE	Not Detected	Not Detected
PROTEIN	NIL	Not Detected
MICROSCOPIC EXAMINATION		
PUS CELLS	NIL	0-5
RBC	Not Detected	Not Detected
EPITHELIAL CELLS	01-05	0-5
CASTS	Not Detected	Not Detected
CRYSTALS	Not Detected	Not Detected
BACTERIA	Not Detected	Not Detected

----- End of Report -----

PANACEA HOSPITAL
(A UNIT OF AAROA HEALTH CARE PVT. LTD.)
REG. NO. 1500
M.D. Pathology
B.36/44, B-4, KABIR NAGAR
DURGAKUND, VARANASI

Lab Technician

Timing : 8.00 a.m. to 9.00 p.m. (Sunday 8.00 a.m. to 3.00 p.m.)

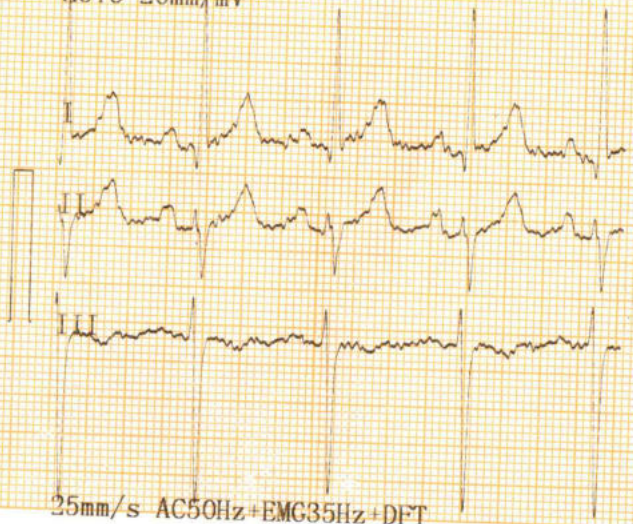
This Report is not valid for medico legal purpose

Note: These tests have technical limitations. Clinico-pathological interpretation is necessary. In case of any disparity test may be repeated immediately.

Address : 36/44 FK Kabir Nagar, Durgakund, Varanasi – 221005

Email: dramishra@gmail.com, drpallaviojha@gmail.com **Website:** panaceahospital.org

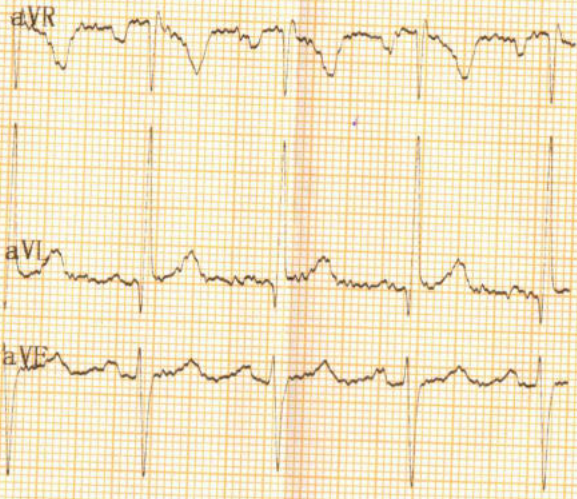AUTO 20mm/mV



25mm/s AC50Hz+EMG35Hz+DFT

20mm/mV

aVR



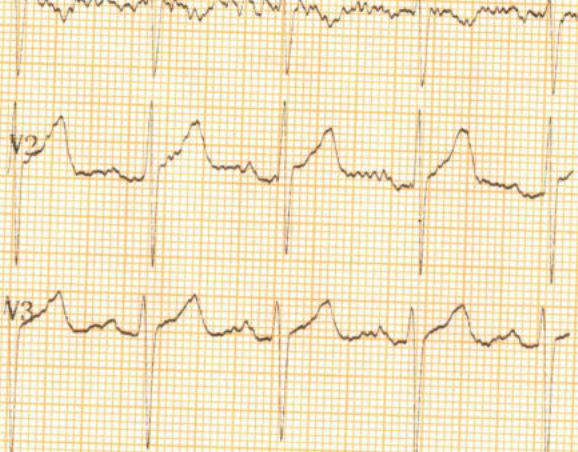aVL

aVF

CARDIART

20mm/mV

V1



V2

V3

BPL

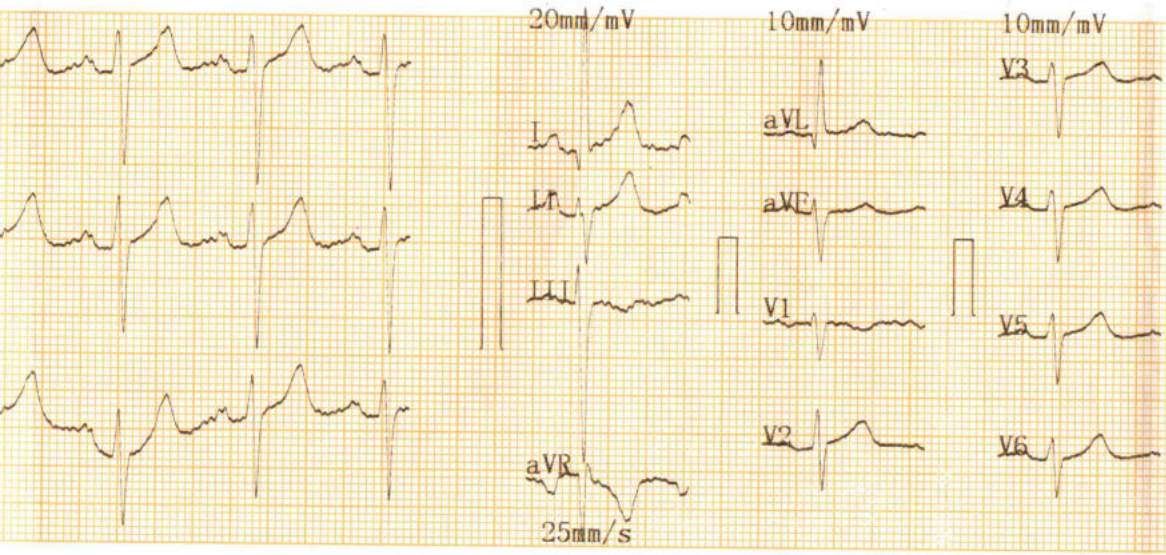
20mm/mV

V4

V5

V6

CARDIART



2022-03-25 11:21

<< Conclusions >>

ID :
 Name : *Shobhitam*
 Sex : *M* Age : *56*
 Height : Weight : kg
 SYS :
 DIA :

Normal Sinus Rhythm;
 Severity Left axis deviation;
 Report need physician confirm

HR bpm : 84
 PR Interval ms : 175
 P Duration ms : 97
 QRS Duration ms : 88
 T Duration ms : 179
 QT/QTc ms : 366/434
 P/QRS/T Axis deg : 49.5/-40.9/25.2
 R(V5)/S(V1) mV : 0.31/0.49
 R(V5)+S(V1) mV : 0.79

Dr. Pallavi Mishra
DR. PALLAVI MISHRA
 MBBS, MD (GENERAL MEDICINE)
 MCI Reg. No. 52033

Physician

CARDIART



Call Now - 1800-123-3070

PANACEA HOSPITAL

*A shelter for many hearts**A Home for many lives*

(An ISO 9001:2008 Certified Organisation)

Lab Attached with CMC Vellore Under EQAS Scheme

Name	MR. SHRIRAM ARYA	Sex /Age	57/M	Date	25/03/2023
Ref. by	DR.ASHUTOSH MISHRA (MD)	BSA - m ²		Echo window	fair

Echo - Cardiography

MITRAL VALVE Doppler	AML - normal morphology MV Flow - E - 0.6 A-0.9 E/A=0.67		PML - normal morphology MVA - 3.0 cm ² Mitral Regurgitation - Trivial MR
TRICUSPID VALVE Doppler	Normal TV Flow - No		Tricuspid Regurgitation - No
PULMONARY VALVE Doppler	Normal PV Flow - No		Pulmonary Regurgitation - No
AORTIC VALVE Doppler	Trileaflet- No AV Flow - no		Aortic Regurgitation - No
MEASUREMENT	Aorta - 31.4 IVS ed - 10.9 LVID ed - 58.3 LVPW ed - 11.4 OA - 7	(20-38) mm (6 - 12) mm (35 - 55) mm (6 - 12) mm (> 5) mm	LA - 38.3 IVS es - 17.7 LVID es - 40.5 LVPW es 15.4 EPSS - 5 (24-32) mm (6 - 12) mm (24 - 40) mm (6 - 12) mm (< 9) mm

CONCLUSION

*All cardiac chamber dimensions are WNL***Trivial MR is present, rest other valve are WNL***Normal LV systolic function present Modified Simpson's method (4C, 2C) (LVEF-57%)***Grade I diastolic dysfunction present (E/A = 0.71) by tissue Doppler (E/e'=7.3)**

No pericardial effusion

No RWMA

Intact IAS / IV

No PAH

No intra cardiac mass /thrombus /vegetation

IMPRESSION

*All cardiac chamber dimensions are WNL***Trivial MR is present, rest other valve are WNL***Normal LV systolic function present Modified Simpson's method (4C, 2C) (LVEF-57%)***Grade I diastolic dysfunction present (E/A = 0.71) by tissue Doppler (E/e'=7.3)**

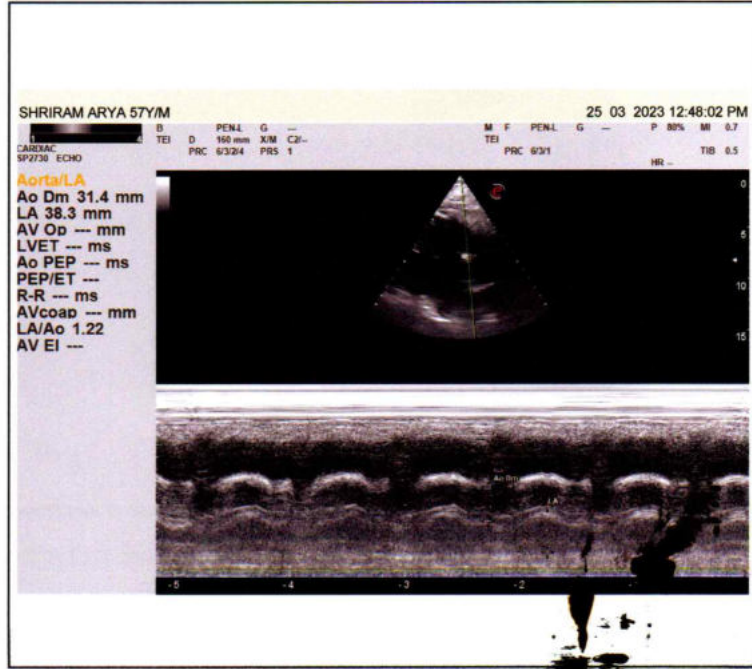
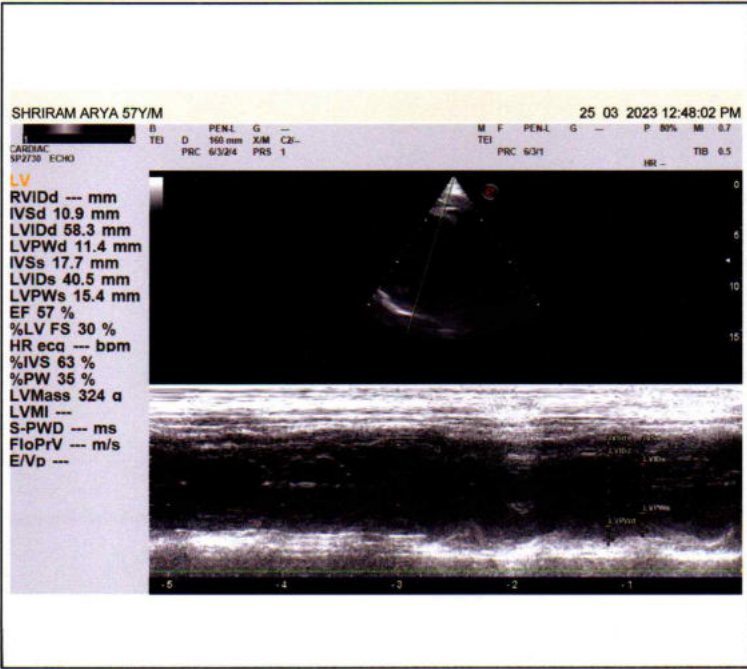
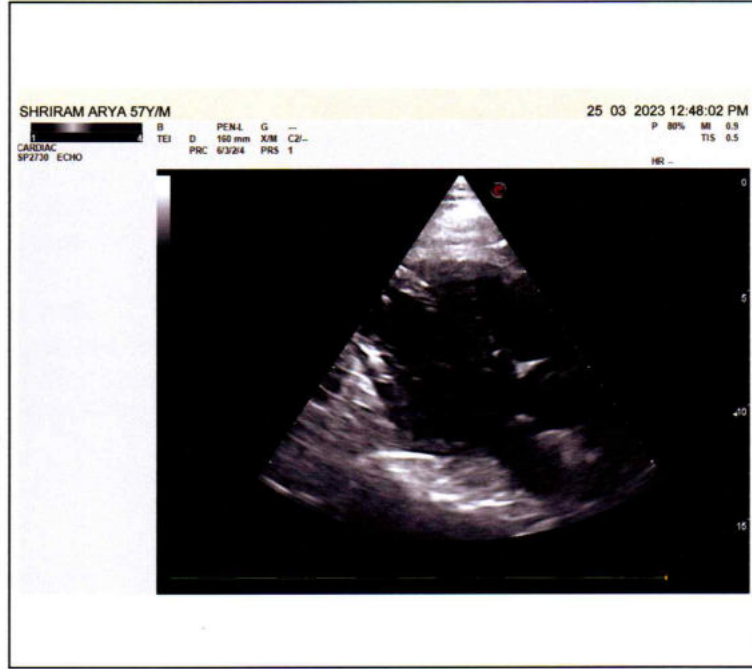
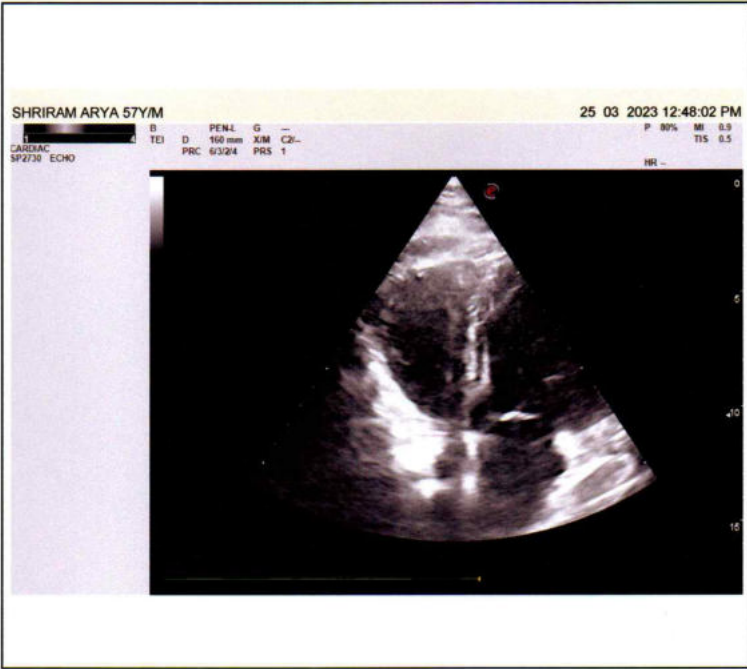
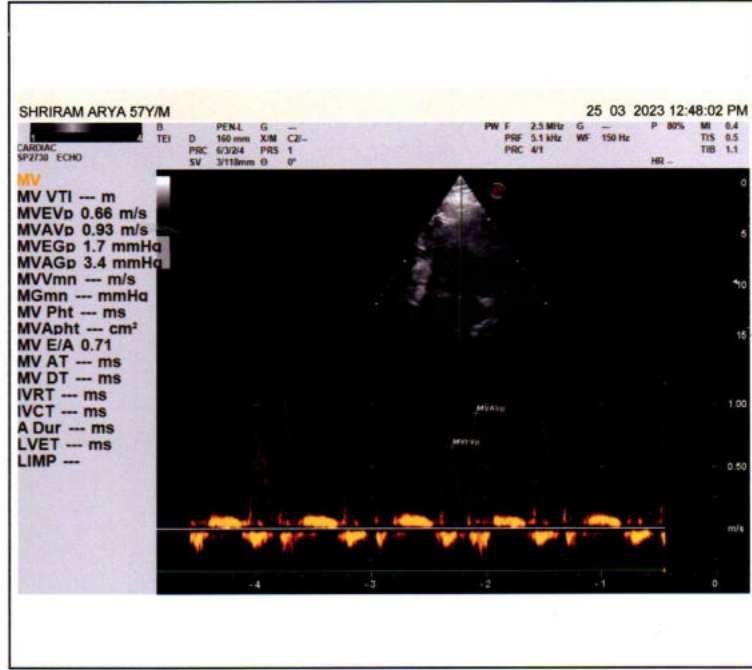
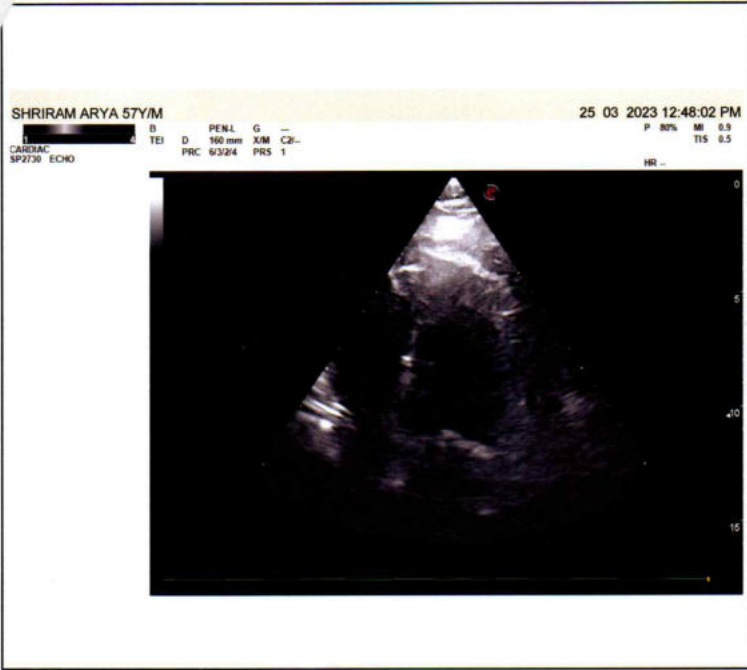Rest all other finding are WNL

Niraj Mishra
Physician Assistant
(PIIRE)Dr. Pallavi Mishra
MBBS, MD (MED) Lucknow
Echocardiography Specialist, MIAE
Non-invasive cardiologist
Women Cardiologist
DiabetocardiologistDR. PALLAVI MISHRA
MBBS, MD (GENERAL MEDICINE)
MCI Reg.No. 52033

Address : Kabir Nagar (Near Sanjay Shiksha Niketan), Durgakund, Varanasi

Mobile : 9554572190 / 9453837595 / Recpn. 9389994334

E-mail : dramishra@gmail.com, drpallaviojha@gmail.com, Website: www.piire.org





PANACEA HOSPITAL

A shelter for many hearts A Home for many lives

(An ISO 9001:2008 Certified Organisation)

Lab Attached with CMC Vellore Under EQAS Scheme

PATIENT'S NAME : Shriram arya AGE/SEX: 56 Y/M
REF. BY : Dr.Ashutosh Mishra Saturday, March 25, 2023

U/S. WHOLE ABDOMEN

- LIVER** : Liver is normal in size, shape & echotexture. Intra hepatic biliary radicals are normal. Portal venous channels are normal.
- G. B.** : Gall bladder is normal in size, lumen is clear. Wall thickness normal.
- C.B.D.** : C.B.D. is normal in caliber.
- PANCREAS** : Pancreas is normal in size, shape and echotexture. No evidence of any inflammatory disease or mass.
- SPLEEN** : Spleen is normal in size, shape and echotexture.
- Rt. KIDNEY** : Normal in size, shape and echotexture. Renal sinus is normal
Cortico medullary differentiation is normal. P. C. system is normal.
- Lt. KIDNEY** : Normal in size, shape and echotexture. Renal sinus is normal
Cortico medullary differentiation is normal. P. C. system is normal.
- URI. BLADDER** : Urinary bladder is normal in size, position. Wall thickness normal.
- PROSTATE** : Prostate is normal in size.
No ascites & retro peritoneal lymphadenopathy seen.
- IMPRESSION** : **NO OBVIOUS SONOLOGICAL ABNORMALITY SEEN.**

DR. R. TIWARI
(M.B.B.S, M.D.(KGMU, LKO)
(RADIODIAGNOSIS).

Thanks for reference.

Address : Kabir Nagar (Near Sanjay Shiksha Niketan), Durgakund, Varanasi

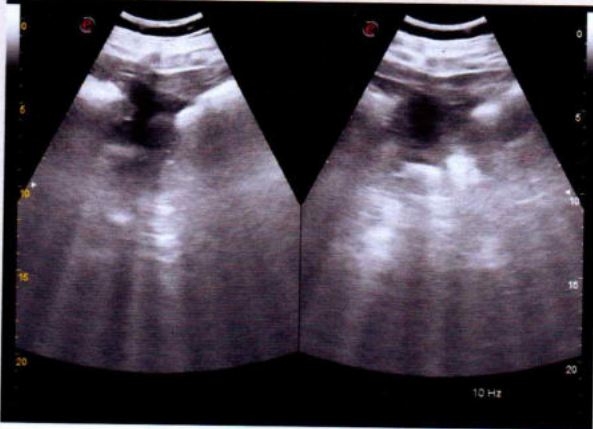
Mobile : 9554572190 / 9453837595 / Recpn. 9389994334

E-mail : dramishra@gmail.com, drpallaviojha@gmail.com, Website: www.piire.org

SHRIRAM AARYA 56Y/M

25 03 2023 10:17:26 AM

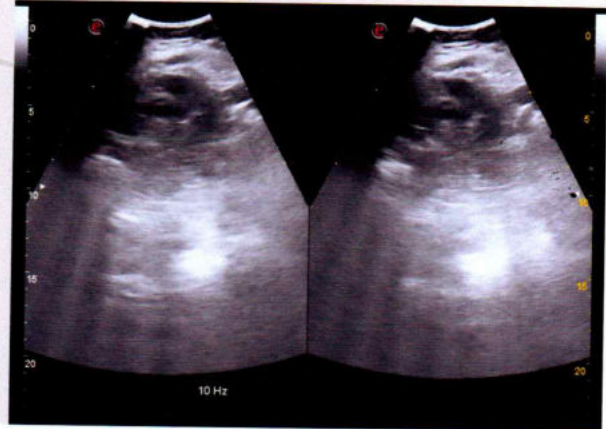
B GENM G --
TEI D 211 mm X/M C2/- P 60% MI 0.8
ABDOMINAL AC2541 ABD PRC 19/2/3/5 PRS 4



SHRIRAM AARYA 56Y/M

25 03 2023 10:17:26 AM

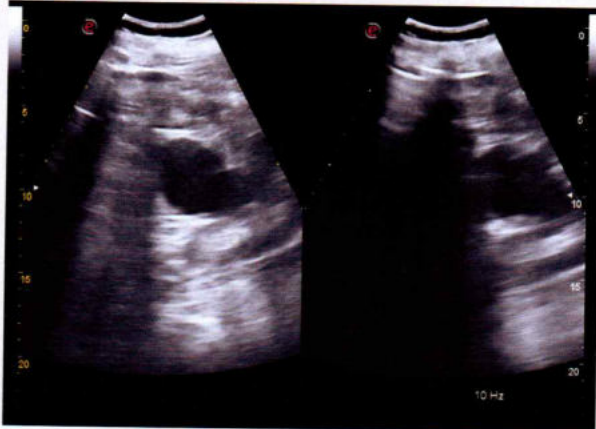B GENM G --
TEI D 211 mm X/M C2/- P 60% MI 0.8
ABDOMINAL AC2541 ABD PRC 19/2/3/5 PRS 4



SHRIRAM AARYA 56Y/M

25 03 2023 10:17:26 AM

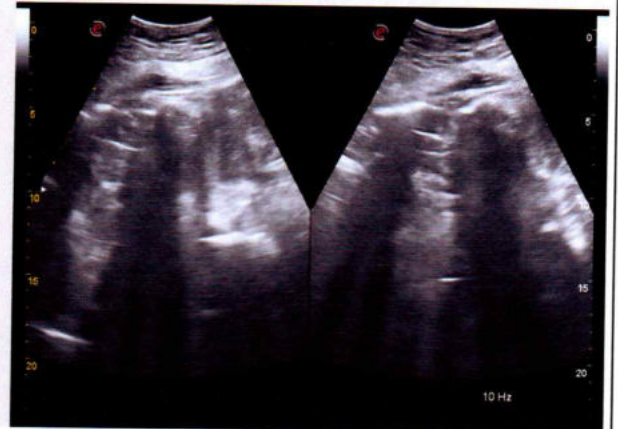
B GENM G --
TEI D 211 mm X/M C2/- P 60% MI 0.8
ABDOMINAL AC2541 ABD PRC 19/2/3/5 PRS 4



SHRIRAM AARYA 56Y/M

25 03 2023 10:17:26 AM

B GENM G --
TEI D 211 mm X/M C2/- P 60% MI 0.8
ABDOMINAL AC2541 ABD PRC 19/2/3/5 PRS 4





PANACEA HOSPITAL

Call Now - 1800-123-3070

A shelter for many hearts

A Home for many lives

(An ISO 9001:2008 Certified Organisation)

Lab Attached with CMC Vellore Under EQAS Scheme

NAME: ARYA SHRIRAM

AGE/SEX: 56 YRS /MALE

REFBY: DR. ASHUTOSH MISHRA (MD)

DATE: 25/03/2023

X-RAY CHEST PA

BOTH LUNG FIELDS AND PLEURAE:

Both lungs show normal bronchovascular pattern.

Right & left hila are normal

No focal mass or calcification is seen

There is no evidence of any fluid in the both the pleural cavities.

Both domes of diaphragms are normal in position.

MEDIASTINUM:

Trachea is central in position.


Cardiac silhouette is of normal size and configuration.

No evidence of pericardial effusion.

No significant lymphadenopathy is seen.

Visualized skeleton is normal.

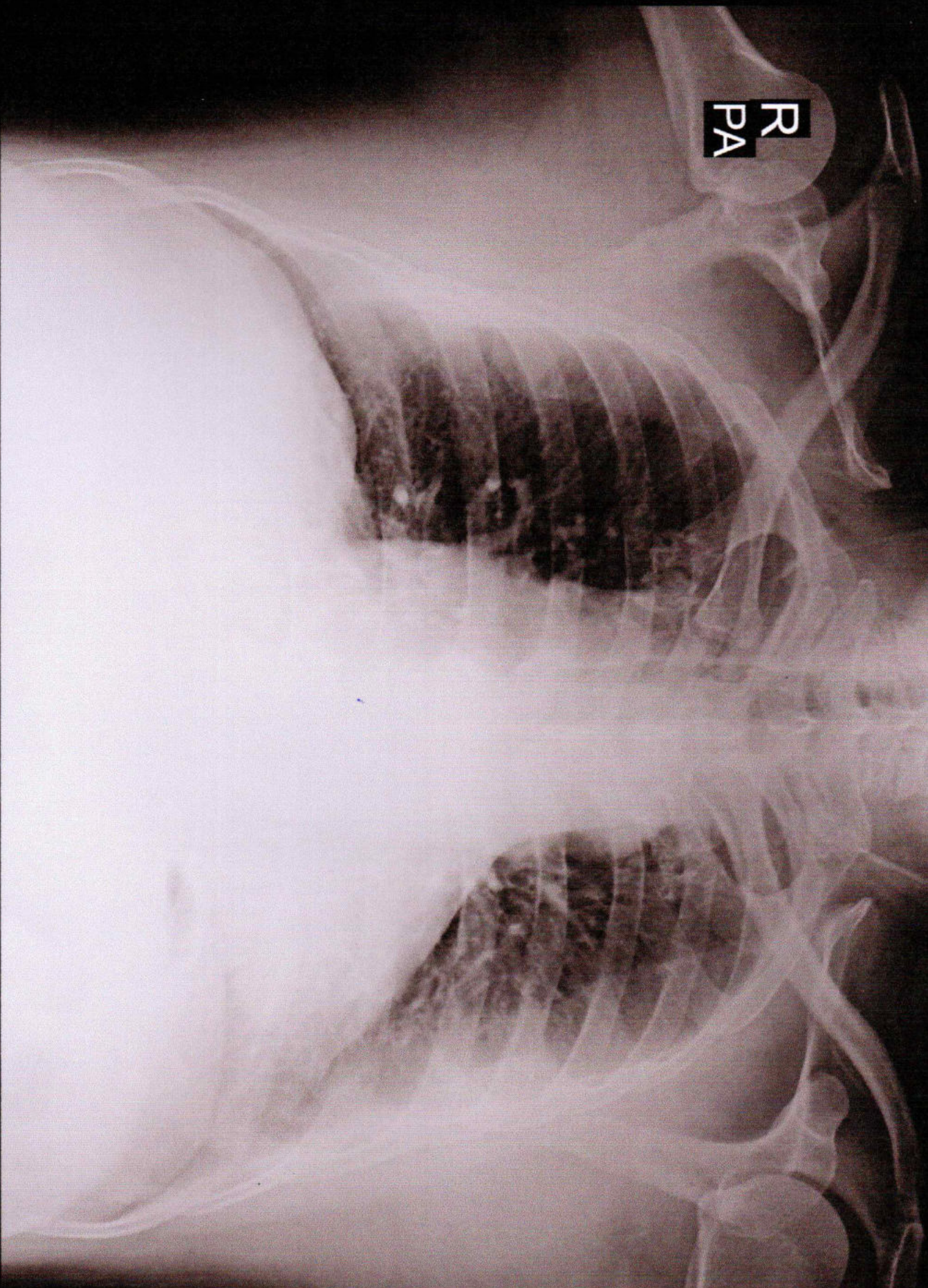
NO SIGNIFICANT RADIOGRAPHIC ABNORMALITY.


REPORTED BY
DR. Rahul Kumar Tiwari
MBBS, MD (Radio Diagnosis)
Reg.No. 57557

Address : Kabir Nagar (Near Sanjay Shiksha Niketan), Durgakund, Varanasi

Mobile : 9554572190 / 9453837595 / Recpn. 9389994334

E-mail : dramishra@gmail.com, drpallaviojha@gmail.com, Website: www.piire.org



R
PA

SHRIRAM ARYA 56YIM 4162 O CHEST P.A. 25-Mar-23 10:55 AM

PANACEA HOSPITAL, KABIR NAGAR, DURGAKUND, VARANASI