



भारतीय विशिष्ट पहचान प्राधिकरण

Unique Identification Authority of India

पता:
S/O: अशोक कुमार सिंह, 1/18, गोलाघाट, रामनगर,
भीटी, वाराणसी,
उत्तर प्रदेश - 221008

Address:

S/O: Ashok Kumar Singh, 1/18,
GOLAGHAT, RAMNAGAR, Bhatti,
Varanasi,
Uttar Pradesh - 221008



3469 5493 6048

VID : 9170 7003 9068 2065



help@uidai.gov.in



GPS Map Camera



Varanasi, Uttar Pradesh, India

44-B3, Durgakund, Bhelupur, Varanasi, Uttar
Pradesh 221001, India

Lat 25.289212°

Long 82.993349°


08/07/23 08:40 AM GMT +05:30

Google



भारत सरकार

Government of India



अभिषेक कुमार सिंह
Abhishek Kumar Singh
जन्म तिथि/DOB: 15/04/1992
पुरुष/ MALE



3469 5493 6048

VID : 9170 7003 9068 2065

मेरा आधार, मेरी पहचान



GPS Map Camera

Varanasi, Uttar Pradesh, India

44-B3, Durgakund, Bhelupur, Varanasi, Uttar
Pradesh 221001, India

Lat 25.289218°

Long 82.993356°

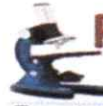08/07/23 08:40 AM GMT +05:30



Google

Facilities:
 All clinical Biomedical & Hematology Investigations
 including Bone Marrow Examination
 VPT, Podiascan & Complete Foot Care (First Time in Purvanchal)
 All Hormonal Investigation by Chemiluminescent Method
 Visceral Fat by (AB-140) Ambulatory BP Monitoring
 CGMS & Insulin Pump Available
 PFT, 2D-ECHO (Color Doppler), Holter, TMT, Cardiac-3 available
 VIA, VILI, Colposcopy available
 Special Endocrinological Investigation Protocols.

ISO 9001:2008 Certified
 Mobile: 9389994334, 9554572190, 9453837595



Panacea Pathology

Clinical Reference Lab

Persistence, Preparedness and Precision
 EQAS (CMC Vellore Attached) & IQAS System
 पूर्वांचल की सर्वोत्तम गुणवत्ता वाली पैथोलॉजी

PATIENT NAME : ABHISHEK KUMAR SINGH	AGE/GENDER : 31 YRS/MALE
REFD BY DR. : ARCO FEMI HEALTHCARE LTD.	RECEIVED DATE : 08-07-2023 (10:00AM)
SAMPLE : BLOOD & URINE	REPORT DATE : 08-07-2023 (07:00PM)

PATHOLOGY REPORT

COMPLETE BLOOD COUNT (CBC)

TEST	LAB TEST VALUES	NORMAL RANGE
HEMOGRAM		
HEMOGLOBIN (FLOW CYTOMETRY)	15.3	13 – 16 gm/dl
TOTAL LEUCOCYTE COUNT (TLC)	5,300	4000 – 11000
RBC COUNT	4.99	3.5 – 5.5
PCV (HCT)	42.5	37 – 47
MCV	96.3	80 – 95
MCH	30.6	28 – 34
MCHC	31.7	30 – 36
PLATELET COUNT	1,35,000	1,50,000 – 4,00,000
E.S.R. (WINTROBE FIRST HOURS)	10.0	20 mm/1 st hr
DIFFERENTIAL LEUCOCYTE		
NEUTROPHILS	45	40 – 75%
LYMPHOCYTES	44	20 – 45%
EOSINOPHILS	05	1 – 6%
MONOCYTES	06	2 – 8%
BASOPHILS	00	< 2%

RANDOM/FASTING BLOOD SUGAR

TEST	LAB TEST VALUES	NORMAL RANGE
RBS/FBS		
FASTING BLOOD SUGAR	128.0	70-125 mg/dl
RANDOM BLOOD SUGAR		125-140 mg/dl

GLYCOSYLATED HEMOGLOBIN (HBA1C)

TEST	LAB TEST VALUES	NORMAL RANGE
HBA1C	6.3	Normal : <5.97 % Good Control : 5.97 – 6.81% Fair Control : 6.81 – 7.65% Poor Control : >7.65%

PAGE 1

Lab Technician

PANACEA HOSPITAL
 A UNIT OF ARCO FEMI HEALTHCARE PVT. LTD.)
 M.D. Pathology

Timing : 8.00 a.m. to 9.00 p.m. (Sunday 8.00 a.m. to 3.00 p.m.)

This Report is not valid for medico-legal purpose

Note: These tests have technical limitations. Clinico-pathological interpretation is necessary in case of any disparity test may be repeated immediately.

REG NO. AL 1500
 83074, G-1, N.D.P.
 JIRGAUND, VARANASI-221005

Facilities:

All clinical Biomedical & Hematology Investigations including Bone Marrow Examination
 VPT, Podiascan & Complete Foot Care (First Time in Purvanchal)
 All Hormonal Investigation by Chemiluminescent Method
 Visceral Fat by (AB-140) Ambulatory BP Monitoring
 CGMS & Insulin Pump Available
 PFT, 2D-ECHO (Color Doppler), Holter, TMT, Cardiac-3 available
 VIA, VILI, Colposcopy available
 Special Endocrinological Investigation Protocols.

ISO 9001:2008 Certified
 Mobile: 9389994334, 9554572190, 9453837595



Panacea Pathology

Clinical Reference Lab

Persistence, Preparedness and Precision
 EQAS (CMC Vellore Attached) & IQAS System
 पूर्वांचल की सर्वोत्तम गुणवत्ता वाली पैथोलॉजी

PATIENT NAME : ABHISHEK KUMAR SINGH	AGE/GENDER : 31 YRS/MALE
REFD BY DR. : ARCO FEMI HEALTHCARE LTD.	RECEIVED DATE : 08-07-2023 (10:00AM)
SAMPLE : BLOOD & URINE	REPORT DATE : 08-07-2023 (07:00PM)

PATHOLOGY REPORT

LIPID PROFILE, SERUM

TEST	LAB TEST VALUES	NORMAL RANGE
BLOOD CHEMISTRY		
TOTAL CHOLESTEROL (SERUM)	169.0	Desirable :- < 200 mg/dl Borderline:- 200 – 239 mg/dl High:- > 240 mg/dl
TRIGLYCERIDES (SERUM)	153.0	35 – 170 mg/dl
HDL CHOLESTEROL(SERUM)	43.0	35.30 – 79.50 mg/dl
LDL CHOLESTEROL (SERUM)	95.0	< 130 mg/dl
VLDL	30.6	< 40 mg/dl
CHOLESTROL/HDL RATIO	3.93	< 3.0 Low Risk Ratio 3.0 – 5.0 Avg Risk > 5.0 High Risk
LDL/HDL RATIO	2.20	< 3 Ratio

BLOOD GROUP

TEST	LAB TEST VALUES
BLOOD GROUP ABO & RH FACTOR	
BLOOD GROUP	"B"
RH FACTOR	POSITIVE

LIVER PROFILE TEST, SERUM

TEST	LAB TEST VALUES	NORMAL RANGE
BIO CHEMISTRY		
TOTAL BILIRUBIN	0.68	0.0 – 1.1 mg/dl
DIRECT BILIRUBIN	0.26	0.0 – 0.2 mg/dl
INDIRECT BILIRUBIN	0.42	< 0.90 mg/dl
SGOT (AST)	28.0	0 – 52 mg/dl
SGPT (ALT)	24.0	0 – 39 mg/dl
GGT (GYT)	18.0	< 55 U/L

THYROID PROFILE (T3, T4, TSH)

TEST	LAB TEST VALUES	NORMAL RANGE
THYROID FUNCTION TEST		
T3	1.10	0.60 – 1.81 ng/ml
T4	7.56	4.50 – 10.90 ug/dl
TSH	2.66	0.39 – 6.10 uIU/mL

PAGE 2

Lab Technician

PANACEA HOSPITAL

(A UNIT OF) DR. ARCO FEMI HEALTHCARE PVT. LTD.

REG NO. AL 1500

Timing : 8.00 a.m. to 9.00 p.m. (Sunday 8.00 a.m. to 3.00 p.m.)

This Report is not valid for medico legal purpose

Note: These tests have technical limitations. Clinico-pathological interpretation is necessary. In case of any discrepancy test may be repeated immediately.

Facilities:

All clinical Biomedical & Hematology Investigations including Bone Marrow Examination
 VPT, Podiascan & Complete Foot Care (First Time in Purvanchal)
 All Hormonal Investigation by Chemiluminescent Method
 Visceral Fat by (AB-140) Ambulatory BP Monitoring
 CGMS & Insulin Pump Available
 PFT, 2D-ECHO (Color Doppler), Holter, TMT, Cardiac-3 available
 VIA, VILI, Colposcopy available
 Special Endocrinological Investigation Protocols.

ISO 9001:2008 Certified
 Mobile: 9389994334, 9554572190, 9453837595



Panacea Pathology

Clinical Reference Lab

Persistence, Preparedness and Precision
 EQAS (CMC Vellore Attached) & IQAS System
 पूर्वांचल की सर्वोत्तम गुणवत्ता वाली पैथोलॉजी

PATIENT NAME : ABHISHEK KUMAR SINGH

AGE/GENDER : 31 YRS/MALE

REFD BY DR. : ARCO FEMI HEALTHCARE LTD.

RECEIVED DATE : 08-07-2023 (10:00AM)

SAMPLE : BLOOD & URINE

REPORT DATE : 08-07-2023 (07:00PM)

PATHOLOGY REPORT

RENAL & KIDNEY PROFILE, SERUM

TEST	LAB TEST VALUES	NORMAL RANGE
RENAL FUNCTION TESTS		
BLOOD UREA NITROGEN (BUN)	11.00	10 – 50 mg/dl
SERUM CREATININE	0.96	0.60 – 1.60 mg/dl
URIC ACID	4.10	3.60 – 7.70 mg/dl
ALKALINE PHOSPHATASE (ALP)	71.0	142 – 353 mg/dl
TOTAL PROTIENS	7.48	0 – 39 mg/dl
ALBUMIN	4.21	3.8 – 5.4 mg/dl
SERUM GLOBULIN	3.27	2.1 – 3.5 mg/dl
AG RATIO	1.28	-

URINE ROUTINE EXAMINATION

TEST	LAB TEST VALUES	NORMAL RANGE
PHYSICAL EXAMINATION		
QUANTITY	30	ML
COLOUR	STRAW	PALE YELLOW
APPEARANCE	CLEAR	CLEAR
SPECIFIC GRAVITY	1.015	1.01 – 1.03
PH	6.0	4.7 – 7.5
CHEMICAL EXAMINATION		
GLUCOSE	Not Detected	Not Detected
PROTEIN	NIL	Not Detected
MICROSCOPIC EXAMINATION		
PUS CELLS	01-02	0-5
RBC	Not Detected	Not Detected
EPITHELIAL CELLS	01-02	0-5
CASTS	Not Detected	Not Detected
CRYSTALS	Not Detected	Not Detected
BACTERIA	Not Detected	Not Detected

----- End of Report -----

Lab Technician

PANACEA HOSPITAL

(A UNIT OF) ARCO FEMI HEALTHCARE PVT. LTD.

REG NO. AL 1500

REG NO. AL 1500

DURGAKUND, VARANASI, U.P.

Timing : 8.00 a.m. to 9.00 p.m. (Sunday 8.00 a.m. to 3.00 p.m.)

This Report is not valid for medico legal purpose

Note: These tests have technical limitations. Clinico-pathological interpretation is necessary. In case of any disparity test may be repeated immediately.



5

PANACEA HOSPITAL

B 36/44 F.K KABIR NAGAR, DURGAKUND
TOLLFREE NO-18001233070.
Whatsapp No - 8795832852
www.piire.org



OP Slip

Print Date : 08-Jul-2023 08:36AM



UHID No :- UD-23240001412 **OP No** :- OP-23240004932 **OP Date** :- 08 Jul 2023 8:35AM
Patient Name :- Mr Abhishek kumar singh **Age/Sex** :- 31 Y/Male **Mobile No** :- 9889120070
Father :- Ashok kumar singh **Department** :- DIABETES, ENDOCRINOLOGY & METABOLIC PHYSICIAN
Pay Type :- Cash **Consultant** :- Dr ASHUTOSH MISHRA (MD(MEDICINE), IMS, BHU)
Token No :- NOR. - 2 **Paid/Bal** :- 0.00 /600.00
Patient Type :- Normal
Address :- 1/18 Golaghat ramnagar bhitti ,varanasi

BP :- 120/80
height :- 174
Weight (kg) :- 95.3
BMI :- 31.4

Rx

Pre-Diabetes
obesity

SpO₂ - 100
 PA - 75
 NL - 42
 WL - 106
 FBS - 126
 PEFr - 230

Rx

Tab. Dichem (10) OD
 Es. Rybulsus (3mg) SUNDAY.
 Es. Rosuvast (20) OD
 Es. Belashin-M. h
 Es. Doxolm. (100) OD

ANJ
CAP.

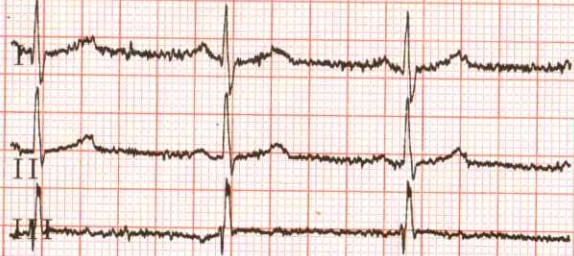20/7

R/A. 1 month

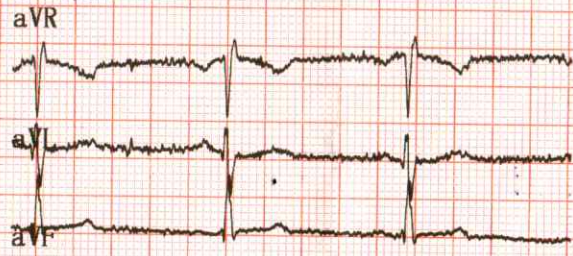Printed By : Ms. ANJALI
Created By : Ms. ANJALI

BPL - 02

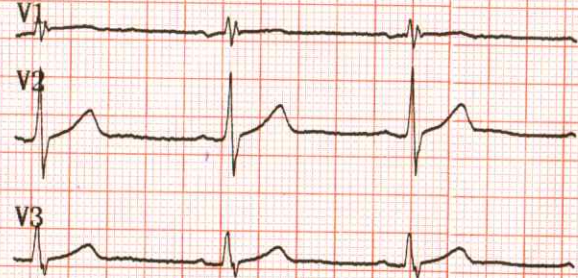AUTO 10mm/mV



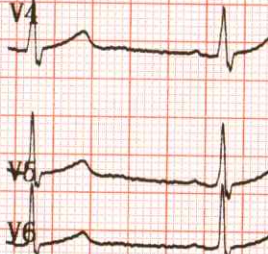10mm/mV



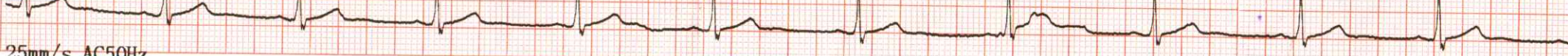5mm/mV



5mm/mV



V5 5mm/mV



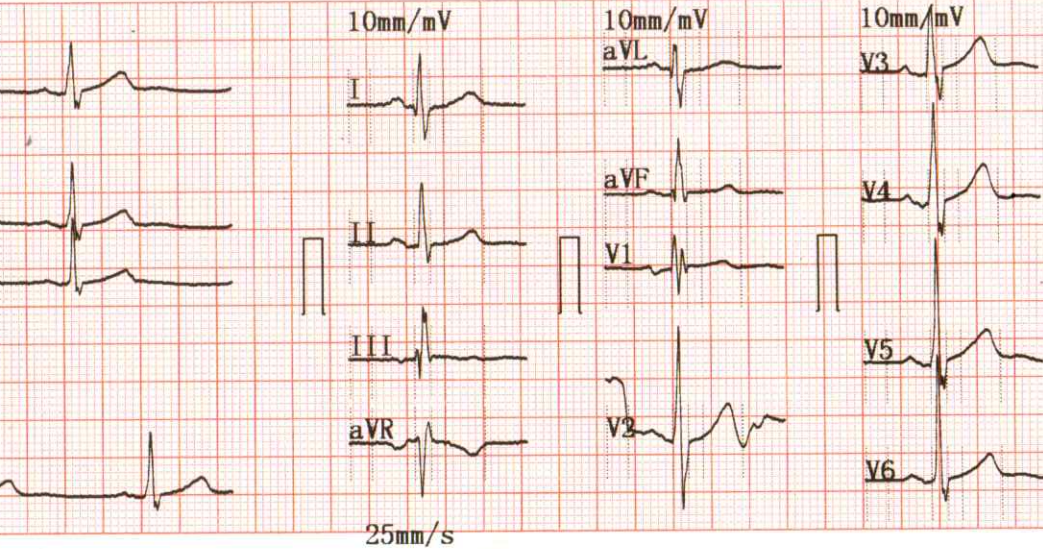
25mm/s AC50Hz

CARDIART

BPL - 02

2023-07-08 09:27

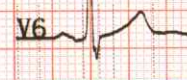
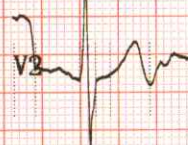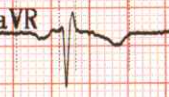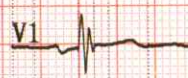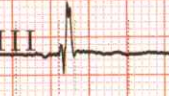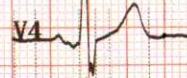
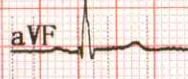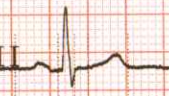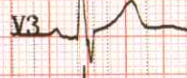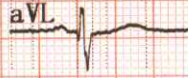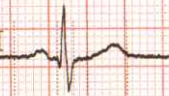<< Conclusions >>



10mm/mV

10mm/mV

10mm/mV



25mm/s

ID :
 Name : **ADHISHEK KUMAR SINGH**
 Sex : **MALE** Age : **31**
 Height : _____ Weight : _____ kg
 SYS : _____
 DIA : _____

Cardiac electric axis normal;
 No Completeness Right Bundle branch block;
 I AV block;
 Report need physician confirm

HR [bpm] : 68
 PR Interval [ms] : 350
 P Duration [ms] : 117
 QRS Duration [ms] : 89
 T Duration [ms] : 215
 QT/QTc [ms] : 380/403
 P/QRS/T Axis [deg] : 6.3/85.0/30.5
 R(V5)/S(V1) [mV] : 1.68/0.32
 R(V5)+S(V1) [mV] : 2.00

Physician
CARDIART



Call Now - 1800-123-3070

PANACEA HOSPITAL

A shelter for many hearts A Home for many lives

(An ISO 9001:2008 Certified Organisation)

Lab Attached with CMC Vellore Under EQAS Scheme

PATIENT'S NAME : MR.ABHISHEK KUMAR SINGH

AGE/SEX: 31 Y/M

REF. BY : Dr. ASHUTOSH MISHRA (MD)

Saturday, July 08, 2023

Echo - Cardiography

MITRAL VALVE Doppler	AML - normal morphology MV Flow - E - 0.7 A-0.5 E/A=1.57	PML - normal morphology MVA - 3.0 cm ² Mitral Regurgitation - No
TRICUSPID VALVE Doppler	Normal TV Flow -No	Tricuspid Regurgitation -No
PULMONARY VALVE Doppler	Normal PV Flow -No	Pulmonary Regurgitation - No
AORTIC VALVE Doppler	Trileaflet-No AV Flow - no	Aortic Regurgitation - no
MEASUREMENT	Aorta - 32.6 (20-38) mm IVS ed - 7.4 (6-12) mm LVID ed - 65.7 (35-55) mm LVPW ed - 8.6 (6-12) mm OA - 7 (> 5) mm	LA - 33.7 (24-32) mm IVS es -15.4 (6-12) mm LVID es - 45.7 (24-40) mm LVPW es - 12.0 (6-12) mm EPSS - 6 (< 9) mm

CONCLUSION All cardiac chamber dimensions are WNL
No valvular abnormalities
Good LV systolic function present Modified Simpson's method (4C, 2C) (LVEF-57%)
No diastolic dysfunction present (E/A = 1.57)
No RWMA
No pericardial effusion
Intact IAS / IV
No PAH
No intra cardiac mass /thrombus /vegetation

IMPRESSION

Normal Echocardiogram

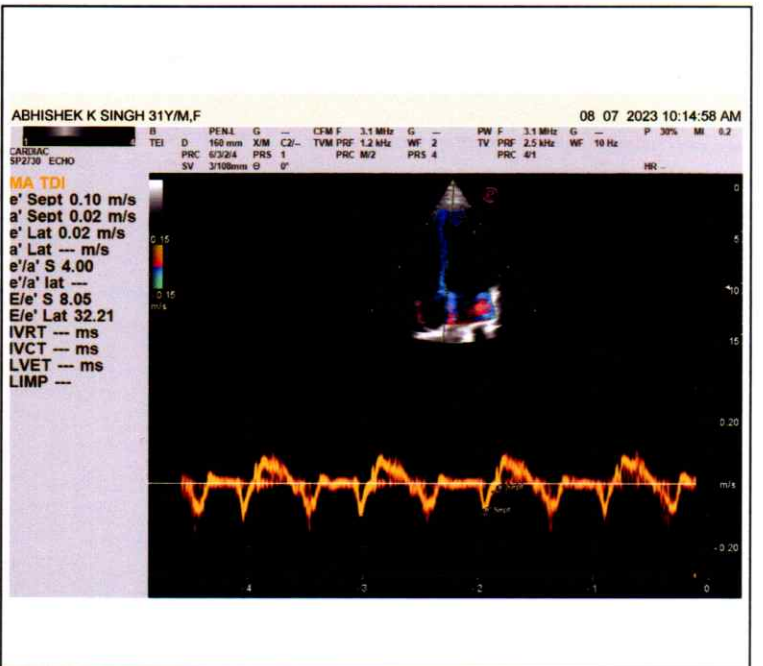
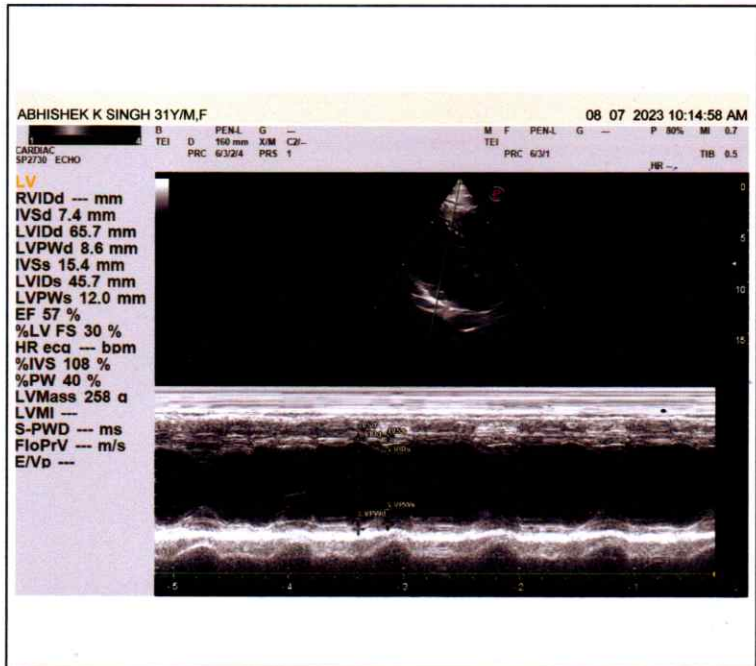
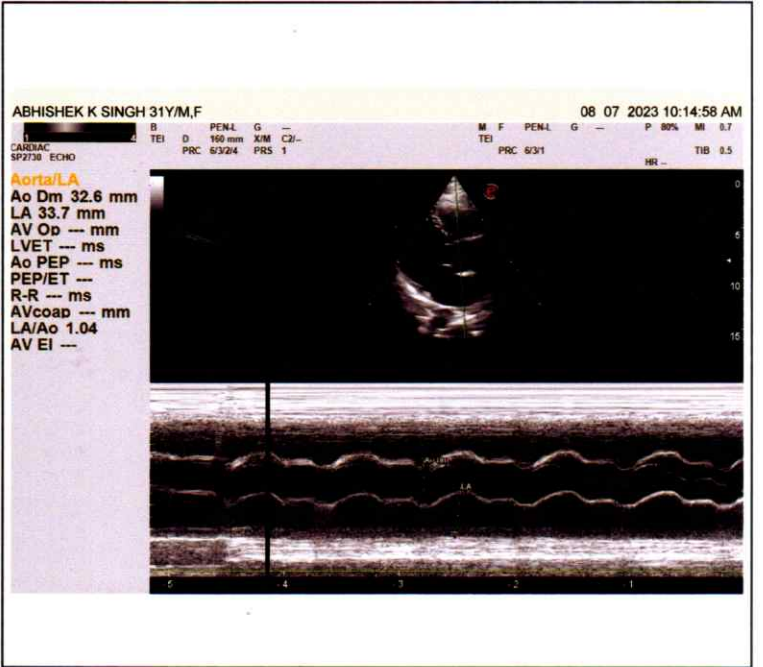
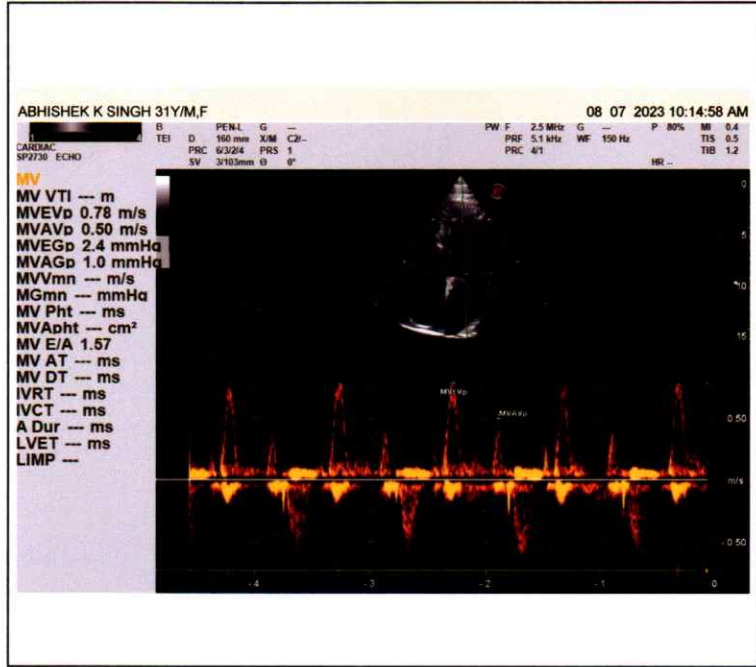

Niraj Mishra
Physician Assistant
(PIRE)


Dr. Pallavi Mishra
MBBS, MD (MED) Lucknow
Echocardiography Specialist, MIAE
Non-invasive cardiologist
Women Cardiologist
Diabetocardiologist

Address : Kabir Nagar (Near Sanjay Shiksha Niketan), Durgakund, Varanasi

Mobile : 9554572190 / 9453837595 / Recpn. 9389994334

E-mail : dramishra@gmail.com, drpallaviojha@gmail.com, Website: www.pire.org





GPS Map Camera

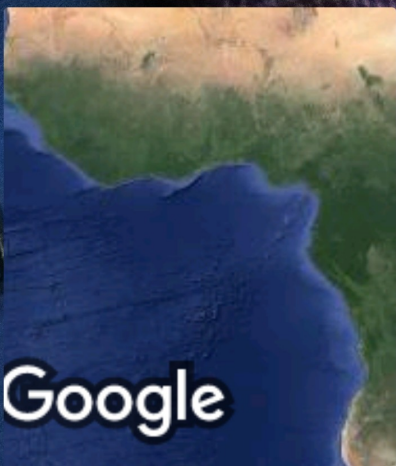Varanasi, Uttar Pradesh, India

44-B3, Durgakund, Bhelupur, Varanasi, Uttar Pradesh 221001, India

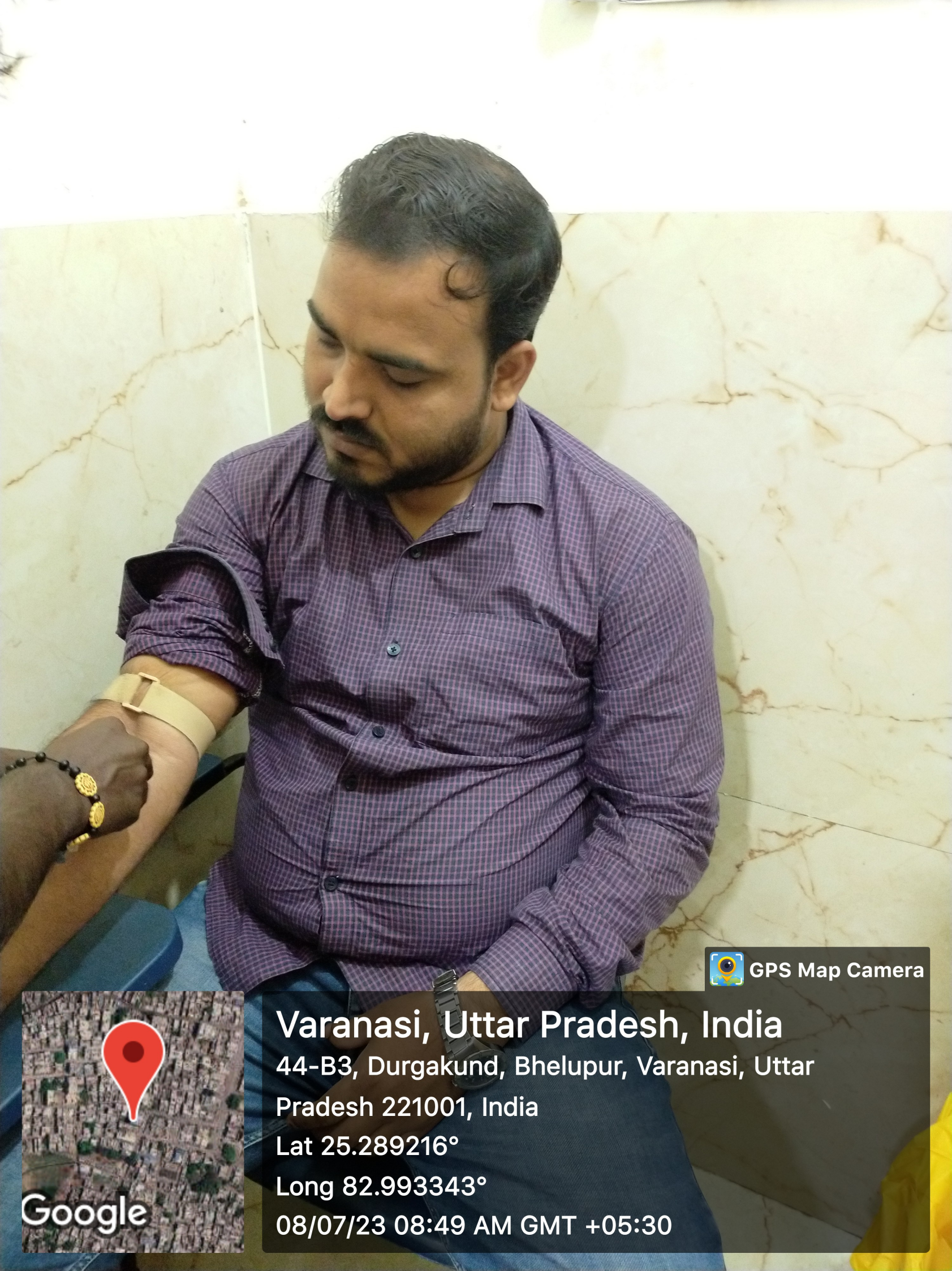Lat 25.289221°

Long 82.993338°

08/07/23 10:55 AM GMT +05:30



Google



GPS Map Camera



Varanasi, Uttar Pradesh, India

44-B3, Durgakund, Bhelupur, Varanasi, Uttar Pradesh 221001, India

Lat 25.289216°

Long 82.993343°

08/07/23 08:49 AM GMT +05:30

Panaceo Hospital

A Shelter For Many Lives

Diabetes Organisation



ओ. पी. डी. पंजीकरण
O.P.D. REGISTRATION

IPD BILLING



GPS Map Camera

Varanasi, Uttar Pradesh, India

B36/44B-A-R, Padampuri Colony, Durgakund,

Nagwa, Varanasi, Uttar Pradesh 221005, India

Lat 25.289209°

Long 82.993349°

08/07/23 09:00 AM GMT +05:30



Google



Call Now - 1800-123-3070

PANACEA HOSPITAL

A shelter for many hearts A Home for many lives

(An ISO 9001:2008 Certified Organisation)

Lab Attached with CMC Vellore Under EQAS Scheme

PATIENT'S NAME : Mr. ABHISHEK KUMAR SINGH

AGE/SEX: 31Y/M

REF. BY : Dr. ASHUTOSH MISHRA

Saturday, July 08, 2023

U/S. WHOLE ABDOMEN

LIVER : Liver is normal in size 148mm, **Diffuse increased echogenicity of liver parenchyma - Grade I fatty liver.** Intra hepatic biliary radicals are normal. Portal venous channels are normal.

G. B. : Gall bladder is normal in size, lumen is clear. Wall thickness normal.

C.B.D. : C.B.D. is normal in caliber.

PANCREAS : Pancreas is normal in size, shape and echotexture. No evidence of any inflammatory disease or mass.

SPLEEN : Spleen is normal in size, shape and echotexture.

Rt. KIDNEY : Normal in size, shape and echotexture. Renal sinus is normal
Cortico medullary differentiation is normal. P. C. system is normal.

Lt. KIDNEY : Normal in size, shape and echotexture. Renal sinus is normal
Cortico medullary differentiation is normal. P. C. system is normal.

URI. BLADDER : Urinary bladder is normal in size, position. Wall thickness normal.

PROSTATE : Prostate is normal in size.
No ascites & retro peritoneal lymphadenopathy seen.

IMPRESSION :

- **GRADE I FATTY LIVER.**


Radiologist

Thanks for reference.

Address : Kabir Nagar (Near Sanjay Shiksha Niketan), Durgakund, Varanasi

Mobile : 9554572190 / 9453837595 / Recpn. 9389994334

E-mail : dramishra@gmail.com, drpallaviojha@gmail.com, Website: www.piire.org

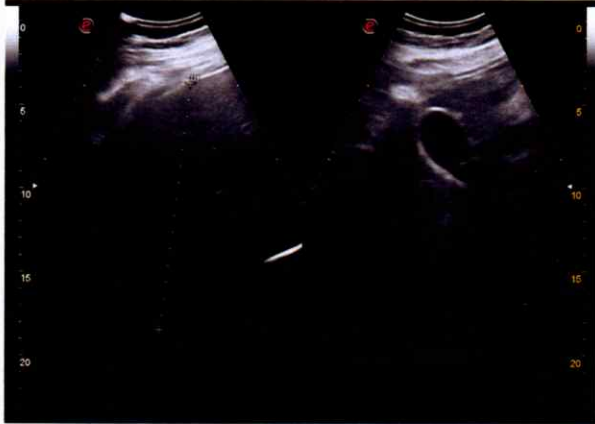ABHISHEK K SINGH 31Y/M,F

08 07 2023 10:12:14 AM

GEN:M G --
TEI D 211 mm X/M C2--
ABDOMINAL PRC 19/2/3/5 PRS 4
AC2541 ABD

P 60% MI 0.8

D1
148.4 mm

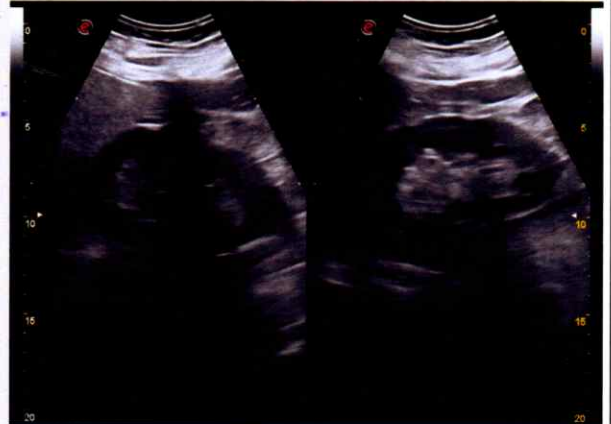

ABHISHEK K SINGH 31Y/M,F

08 07 2023 10:12:14 AM

GEN:M G --
TEI D 183 mm X/M C2--
ABDOMINAL PRC 19/2/3/5 PRS 4
AC2541 ABD

P 60% MI 0.8



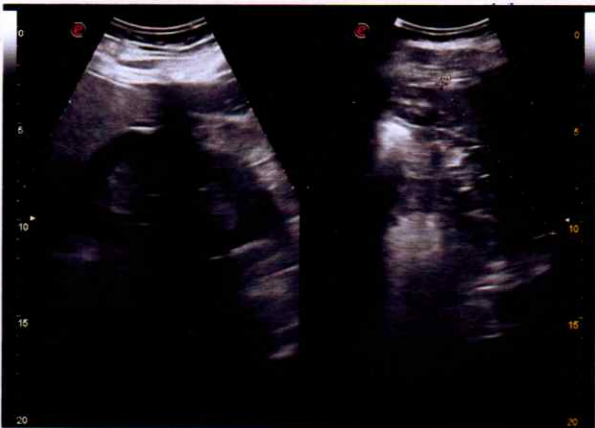ABHISHEK K SINGH 31Y/M,F

08 07 2023 10:12:14 AM

GEN:M G --
TEI D 183 mm X/M C2--
ABDOMINAL PRC 19/2/3/5 PRS 4
AC2541 ABD

P 60% MI 0.8

D1
96.7 mm

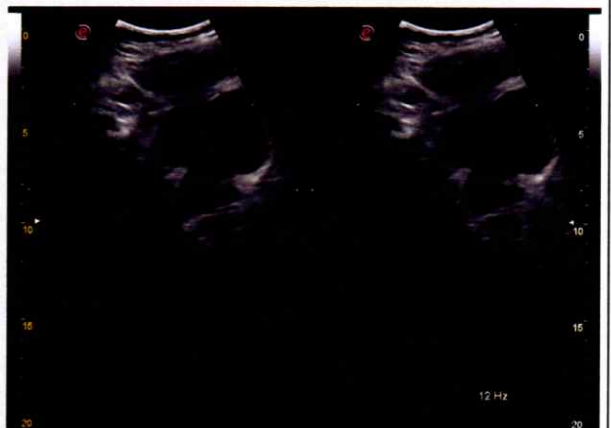


ABHISHEK K SINGH 31Y/M,F

08 07 2023 10:12:14 AM

GEN:M G --
TEI D 183 mm X/M C2--
ABDOMINAL PRC 19/2/3/5 PRS 4
AC2541 ABD

P 60% MI 0.8





Call Now - 1800-123-3070

PANACEA HOSPITAL

A shelter for many hearts A Home for many lives

(An ISO 9001:2008 Certified Organisation)

Lab Attached with CMC Vellore Under EQAS Scheme

PATIENT'S NAME : Mr. ABHISHEK KUMAR SINGH

AGE/SEX: 31Y/M

REF. BY

: Dr. ASHUTOSH MISHRA

Saturday, July 08, 2023

X-RAY CHEST PA

BOTH LUNG FIELDS AND PLEURAE:

Both lungs show normal bronchovascular pattern.

Right & left hila are normal

No focal mass or calcification is seen

There is no evidence of any fluid in the both the pleural cavities.

Both domes of diaphragms are normal in position.

MEDIASTINUM:

Trachea is central in position.

Cardiac silhouette is of normal size and configuration.

No evidence of pericardial effusion.

No significant lymphadenopathy is seen.

Visualized skeleton is normal.

NO SIGNIFICANT RADIOGRAPHIC ABNORMALITY.


Radiologist

Address : Kabir Nagar (Near Sanjay Shiksha Niketan), Durgakund, Varanasi

Mobile : 9554572190 / 9453837595 / Recpn. 9389994334

E-mail : dramishra@gmail.com, drpallaviojha@gmail.com, Website: www.piire.org

R
PA

ABHISHEK KUMAR 31Y/M 1412 O CHEST P.A. 08-Jul-23 10:46 AM

PANACEA HOSPITAL, KABIR NAGAR, DURGAKUND, VARANASI