



MURUGAN HOSPITALS

HEALING HANDS



SCAN REPORT

NAME : MRS. P.GAYATHRI
AGE / SEX : 29Y / FEMALE
CONSULTANT: DR. ARUN PRAKASH

UHID NO : MH20220041815
IP / OP NO: OUTPATIENT
DATE : 26-11-2022

ULTRA SOUND SCAN OF ABDOMEN

LIVER: Normal in size and normal in echotexture. No focal lesions are seen. No dilatation of intra-hepatic biliary radicals present. Hepatic veins and IVC appear normal. Portal vein is normal in caliber. Common bile duct is normal in caliber.

GALL BLADDER: Normal in size and wall thickness. No evidence of any calculus or mass present. No evidence of pericholecystic collections.

PANCREAS: Normal in size and echotexture. No focal lesions are seen. No evidence of calculi or calcifications. No evidence of pancreatic duct dilation.

PARA AORTIC AREAS: Aorta and IVC appear normal. No evidence of para aortic lymphadenopathy.

SPLEEN: Normal in size and measures 7.9 cm. Normal in echotexture. No evidence of focal lesions.

RIGHT KIDNEY: Measures 11.0 X 4.2 cm and is normal in size and echotexture. Cortico medullary differentiation is well maintained.

LEFT KIDNEY: Measures 10.9 X 3.6 cm and is normal in size and echotexture. Cortico medullary differentiation is well maintained. There is no calculus or hydronephrosis or mass.

Healing Hearts and Lives

264/125, Kilpauk Garden Road, Kilpauk, Chennai - 600 010. Phone : +91 44 4644 8989 / 75500 53335
Email : muruganhosp@gmail.com | Website : www.muruganhospitals.in

URINARY BLADDER: Normal in size, contour and wall thickness. There is no evidence of calculus or mass. No vesical diverticulum present.

UTERUS AND OVARIES : Normal in size and echotexture. Measures 4.8 X 3.6 cm.ET- 3.5 mm.

Right ovary measures- 3.7 x 2.0 cm.

Left ovary measures- 3.1 x 1.8 cm.

No ascites present. No retroperitoneal lymphadenopathy present.

IMPRESSION:

- **No significant abnormality detected seen in the visualized organs .**


Dr. SAKTHI, MDEd
Consultant Radiologist.



MURUGAN HOSPITALS

HEALING HANDS



ECHO CARDIOGRAM REPORT

NAME : MRS. P.GAYATHRI

UHID NO: MH20220041815

AGE&SEX : 29Y/FEMALE

IP/OP : OUTPATIENT

CONSULTANT:DR. ARUN PRAKASH

DATE : 26-11-2022

2D PLAX (mm)

RV - 21 mm
AO - 18 mm
LA - 20 mm

COLOR DOPPLER

Normal

M-Mode (mm)

IVS - 08 mm
PW - 09 mm
LVD - 23 mm
LVS - 16 mm
EF - 77 %
FS - 44 %

DOPPLER (m/sec)

MITRAL E - 0.4 m/s
MITRAL A - 0.4 m/s
PULMONARY - 0.9 m/s
AORTIC - 1.0 m/s
TRICUSPID - 0.4 m/s

IMPRESSION:

No RWMA
Normal biventricular function
No pulmonary hypertension
No pericardial effusion
No clot/ Vegetation.

DR.SIDHARTHAN MD,DM.,
CONSULTANT CARDIOLOGIST



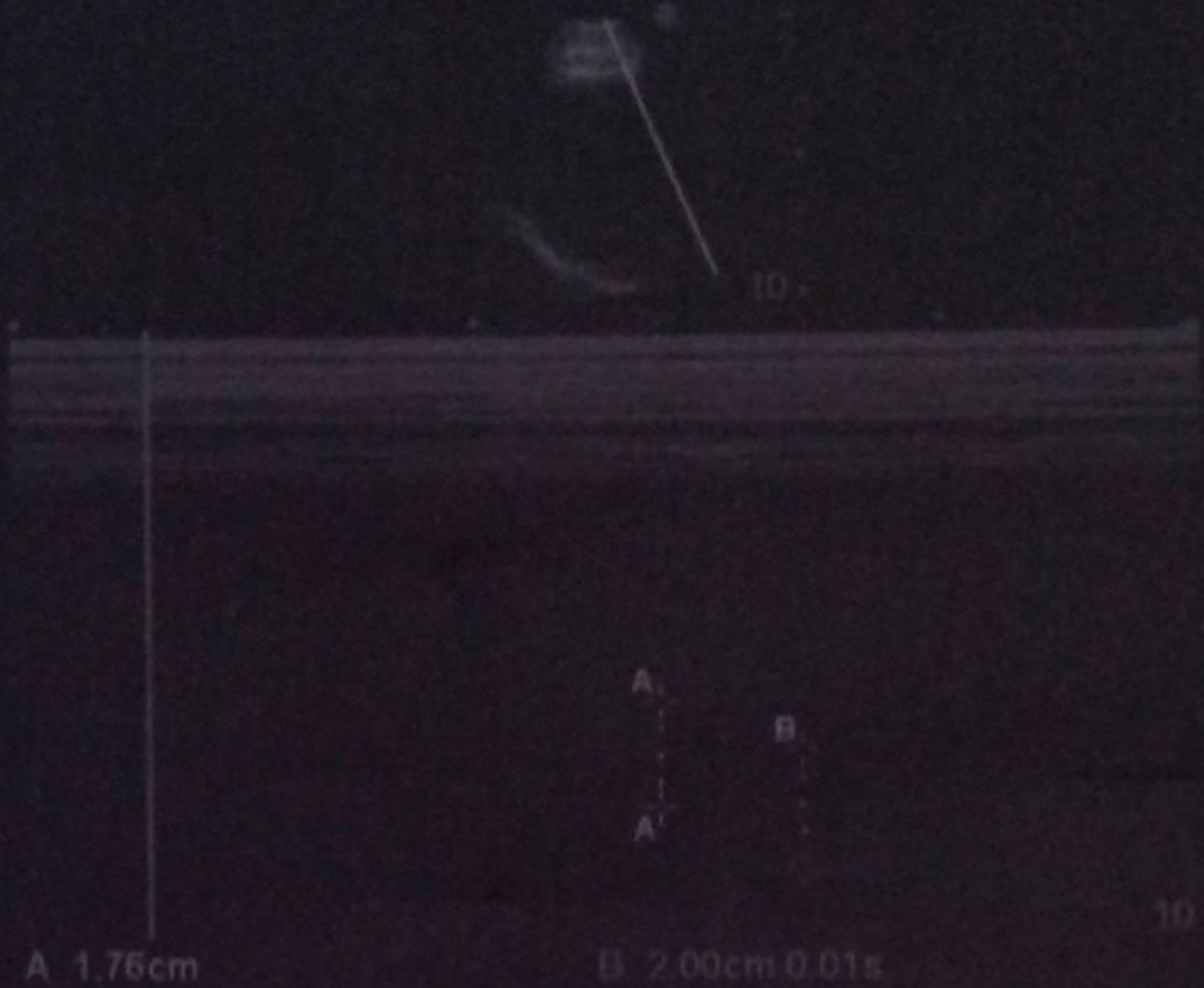
Healing Hearts and Lives

264/125, Kilpauk Garden Road, Kilpauk, Chennai - 600 010.
Phone : +91 44 4644 8989 / 75500 53335 | Email : muruganhosp@gmail.com
Website : www.muruganhospitals.in

GAYATHRI
Gen THI

2022Nov26 12:07

Crđ
P21
MI
1.2
TIS
0.3

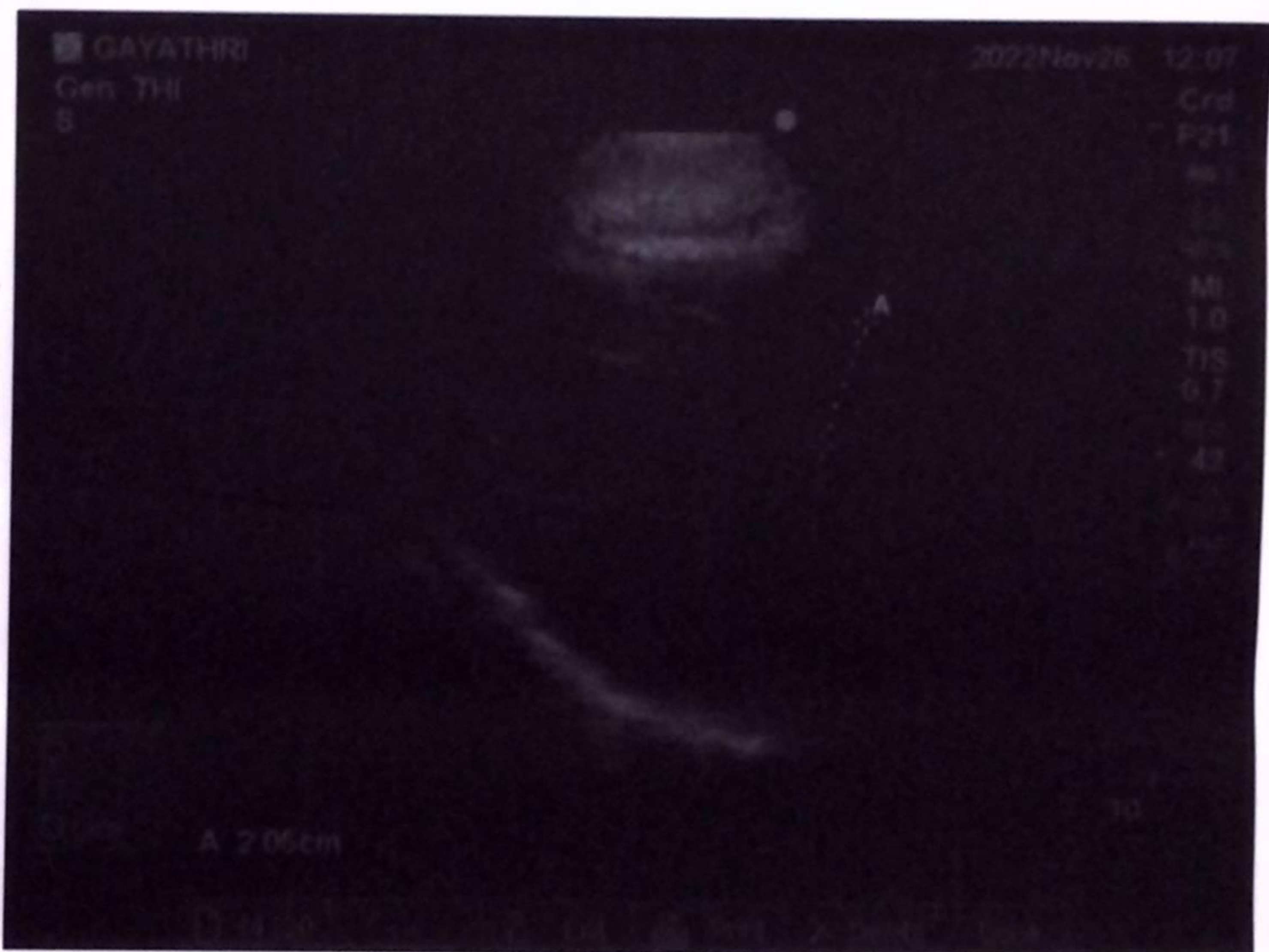
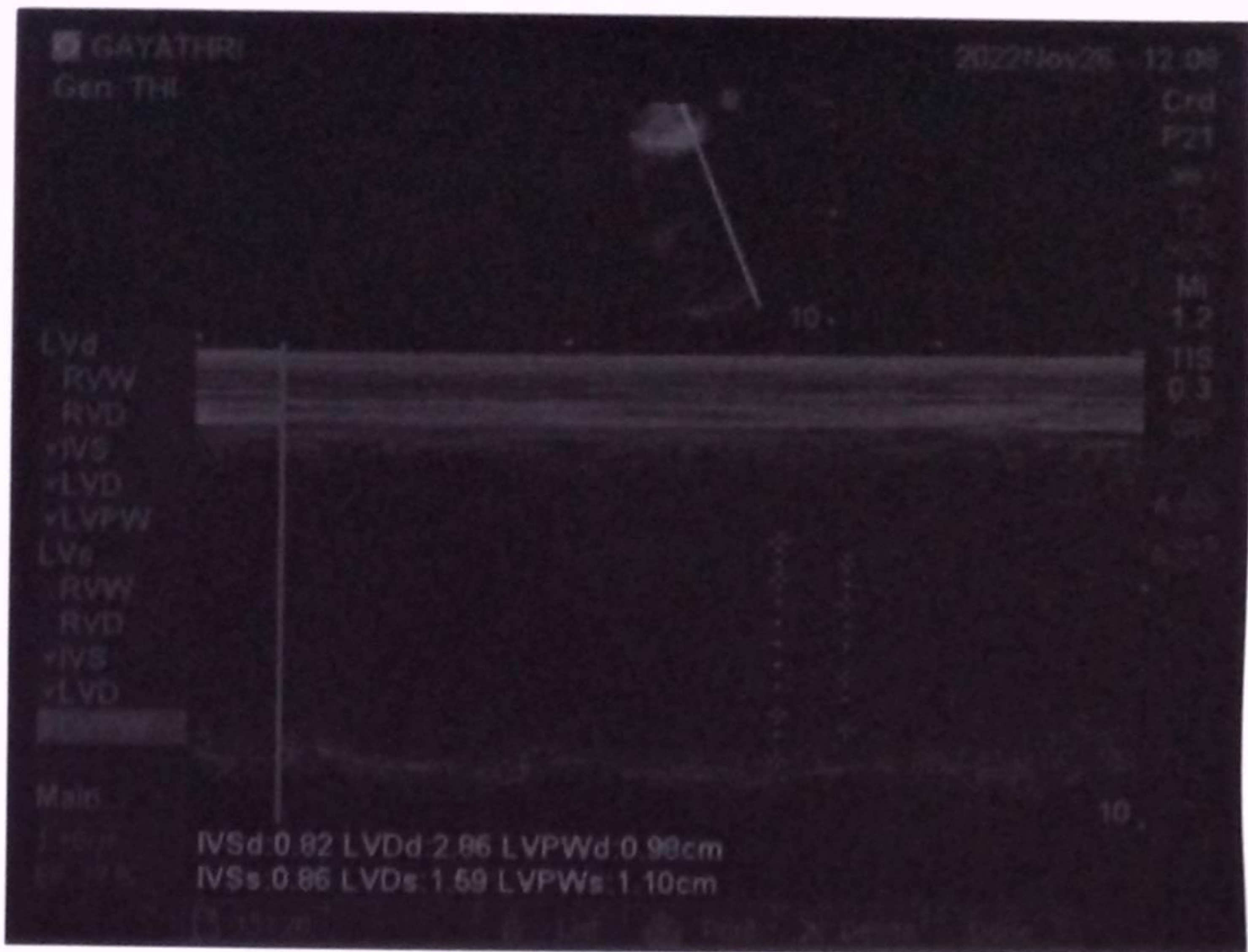
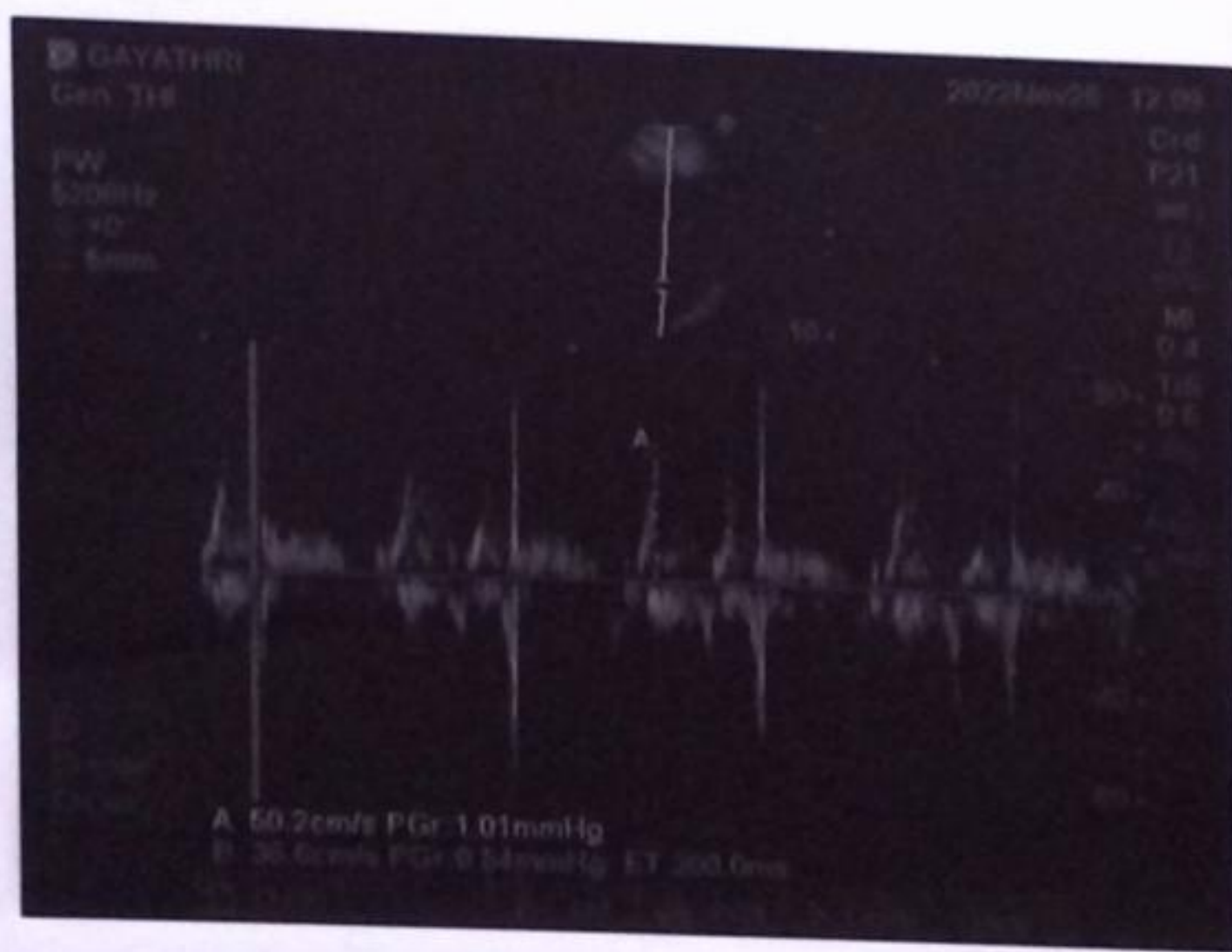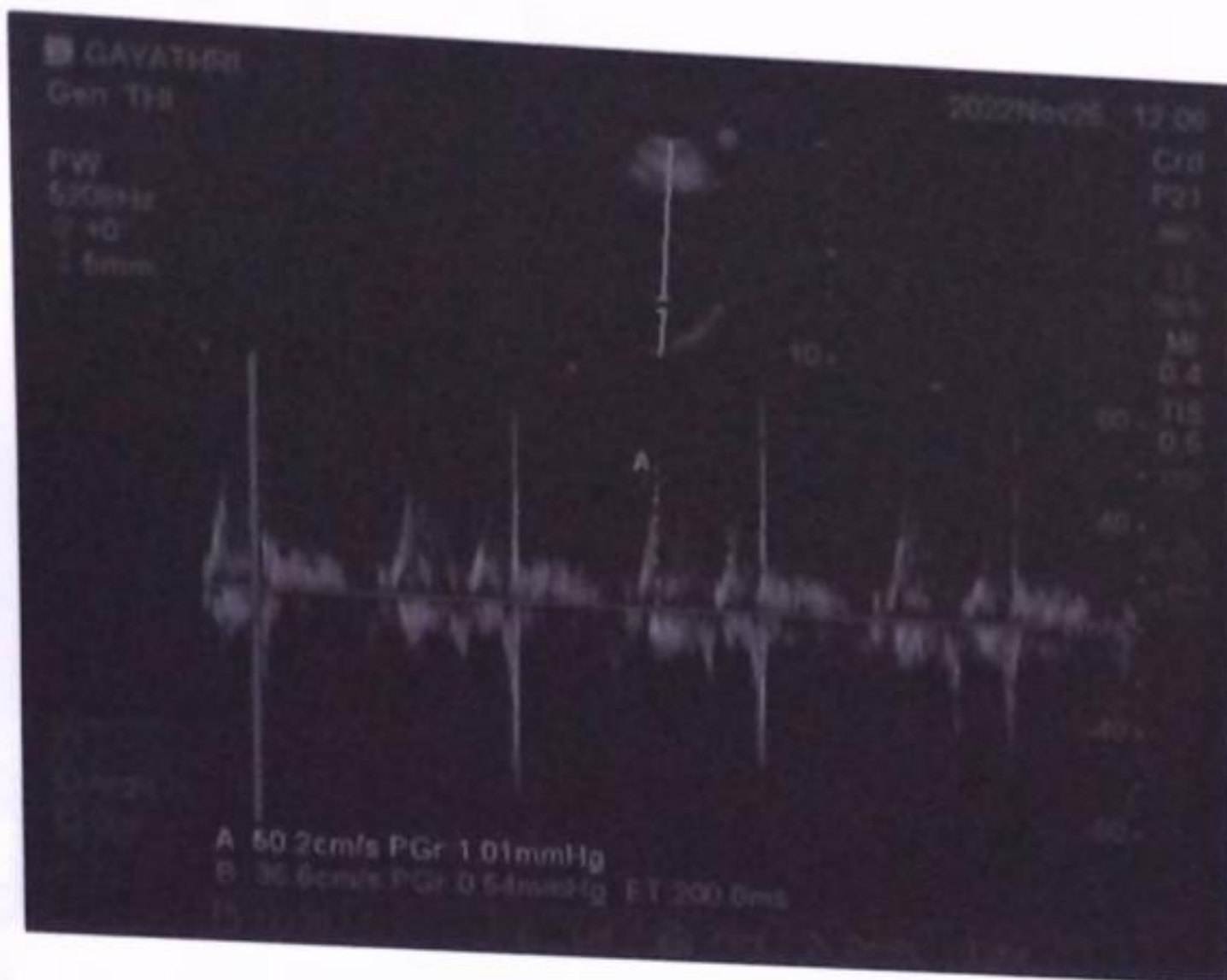
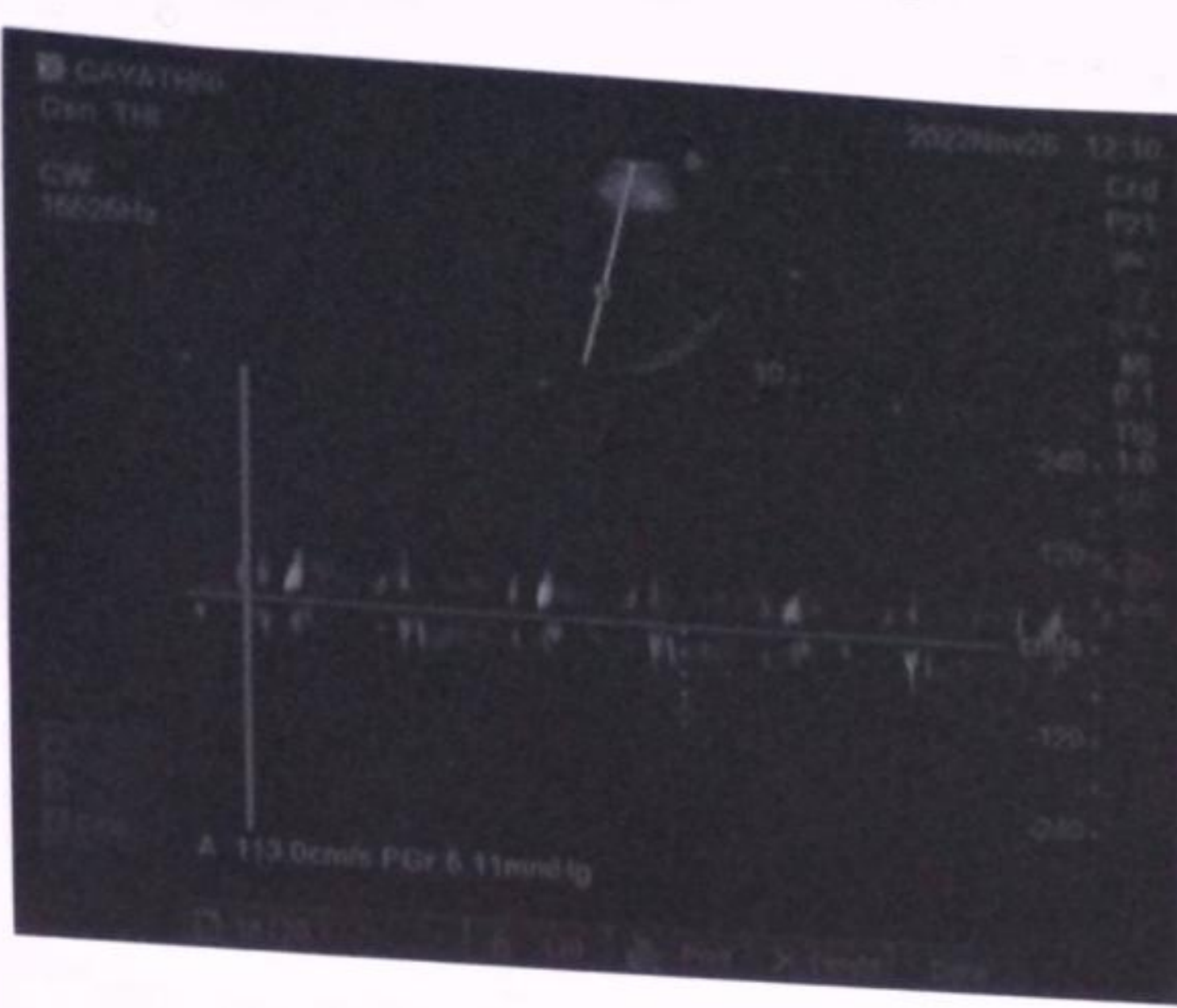
A 1.75cm

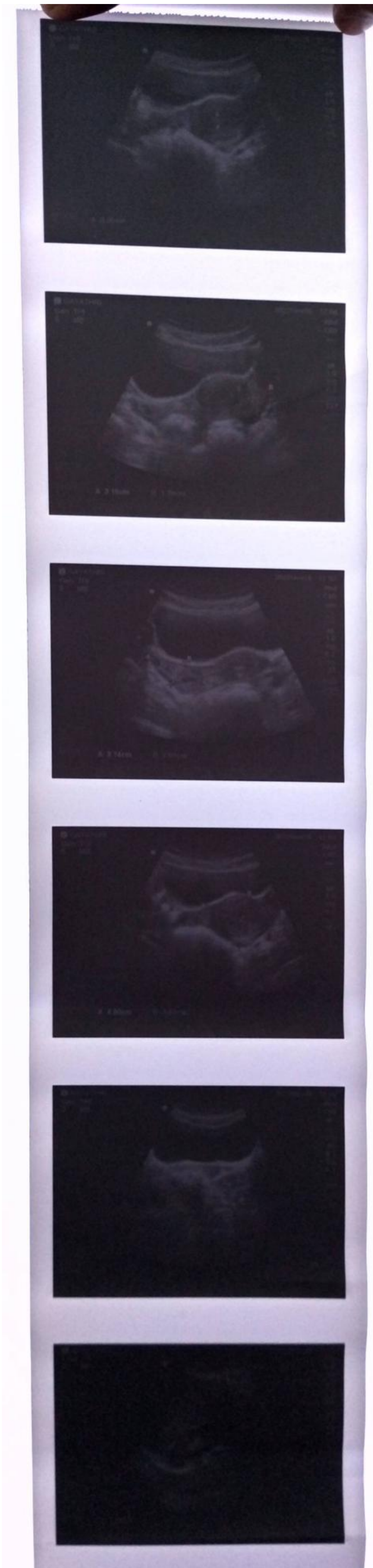B 2.00cm 0.015

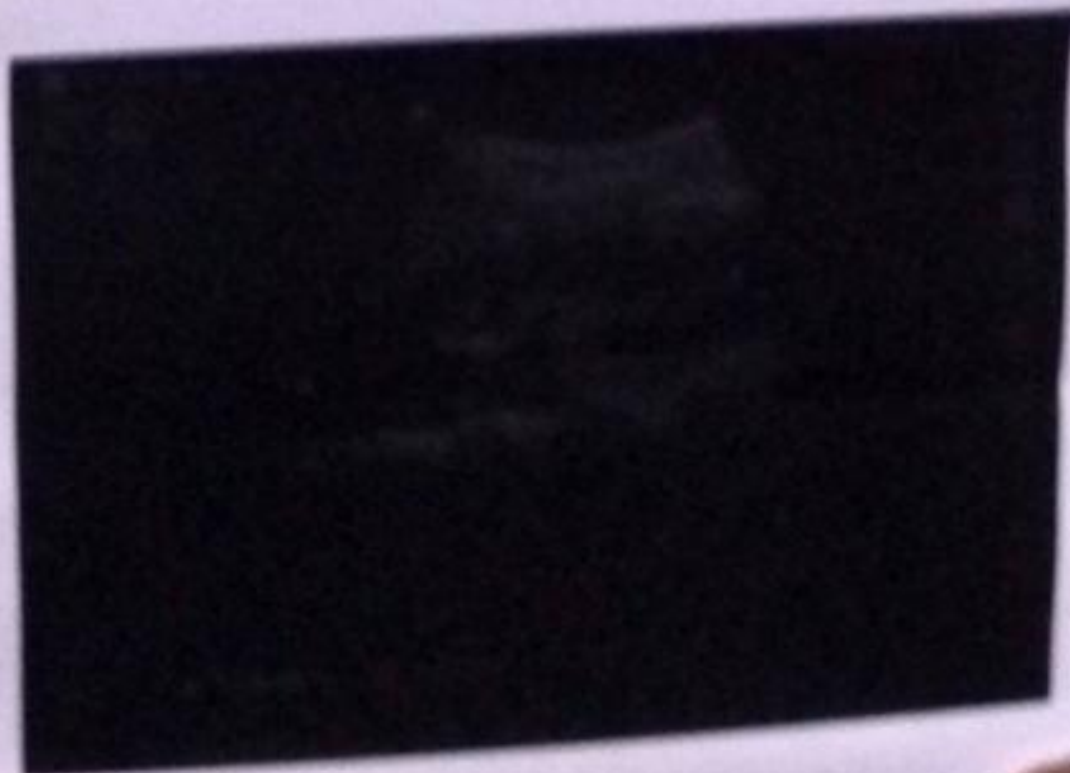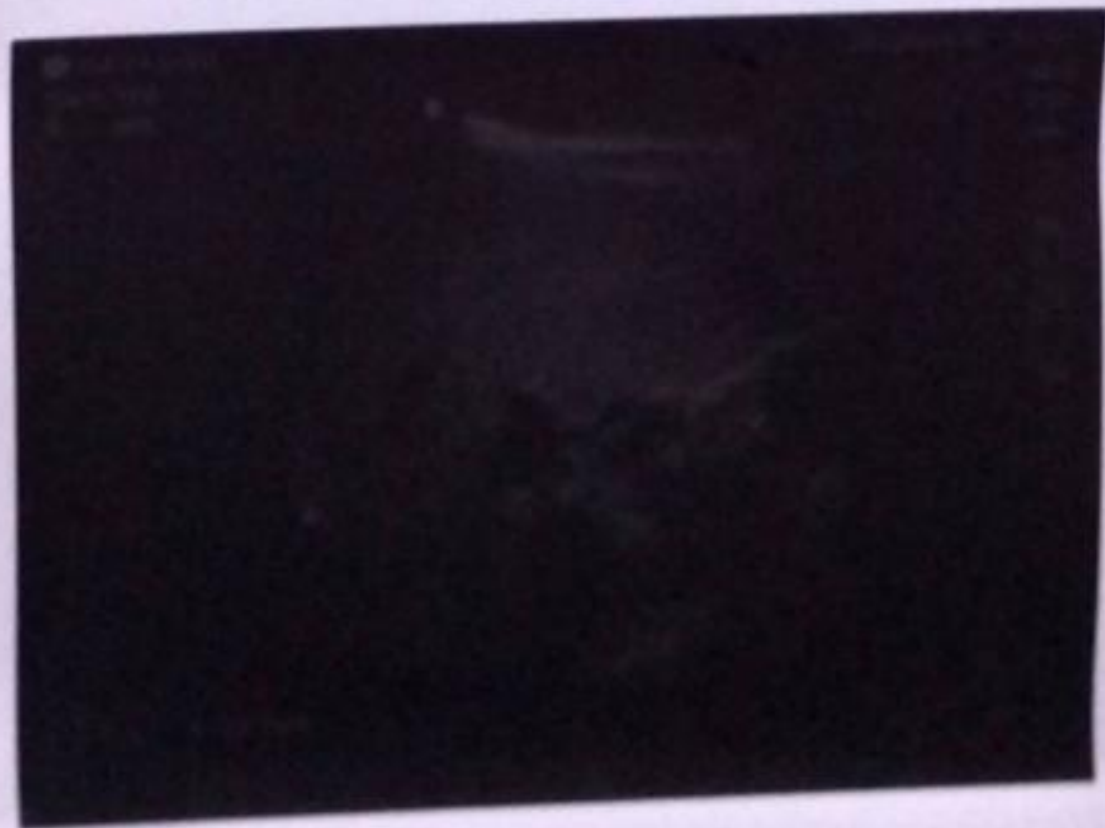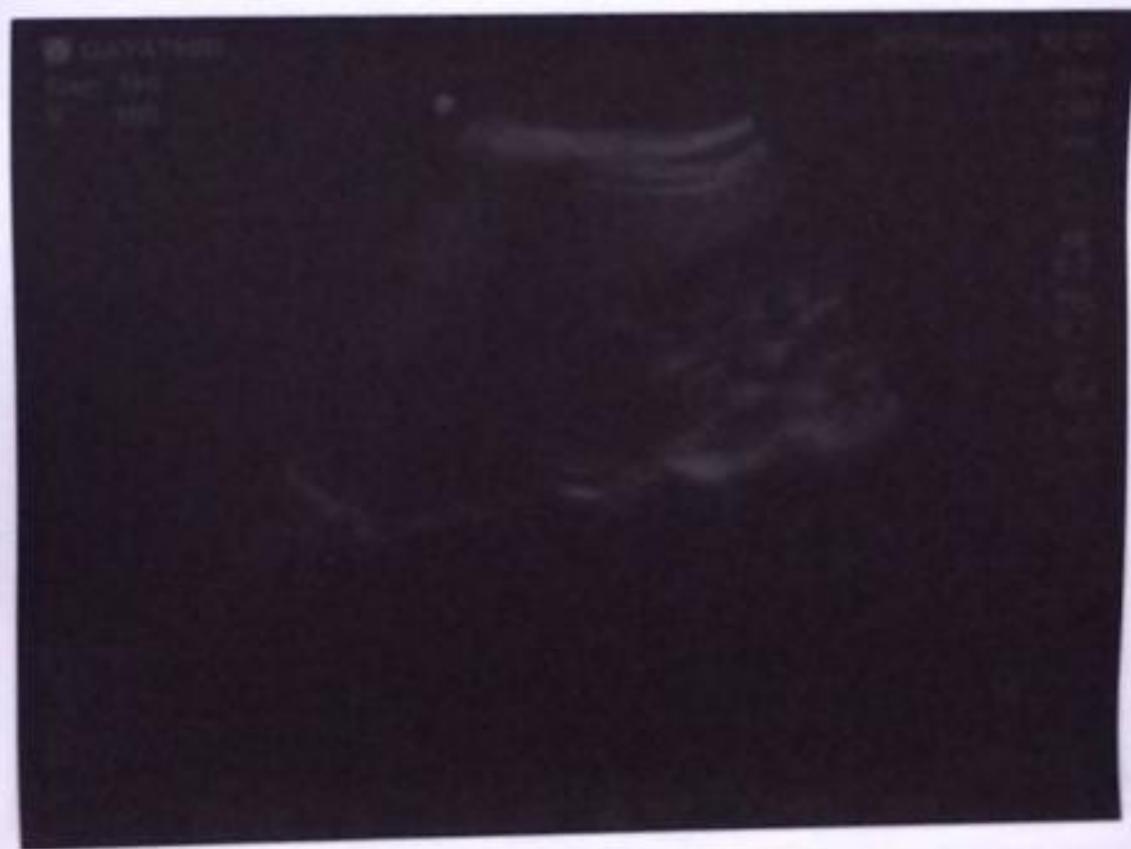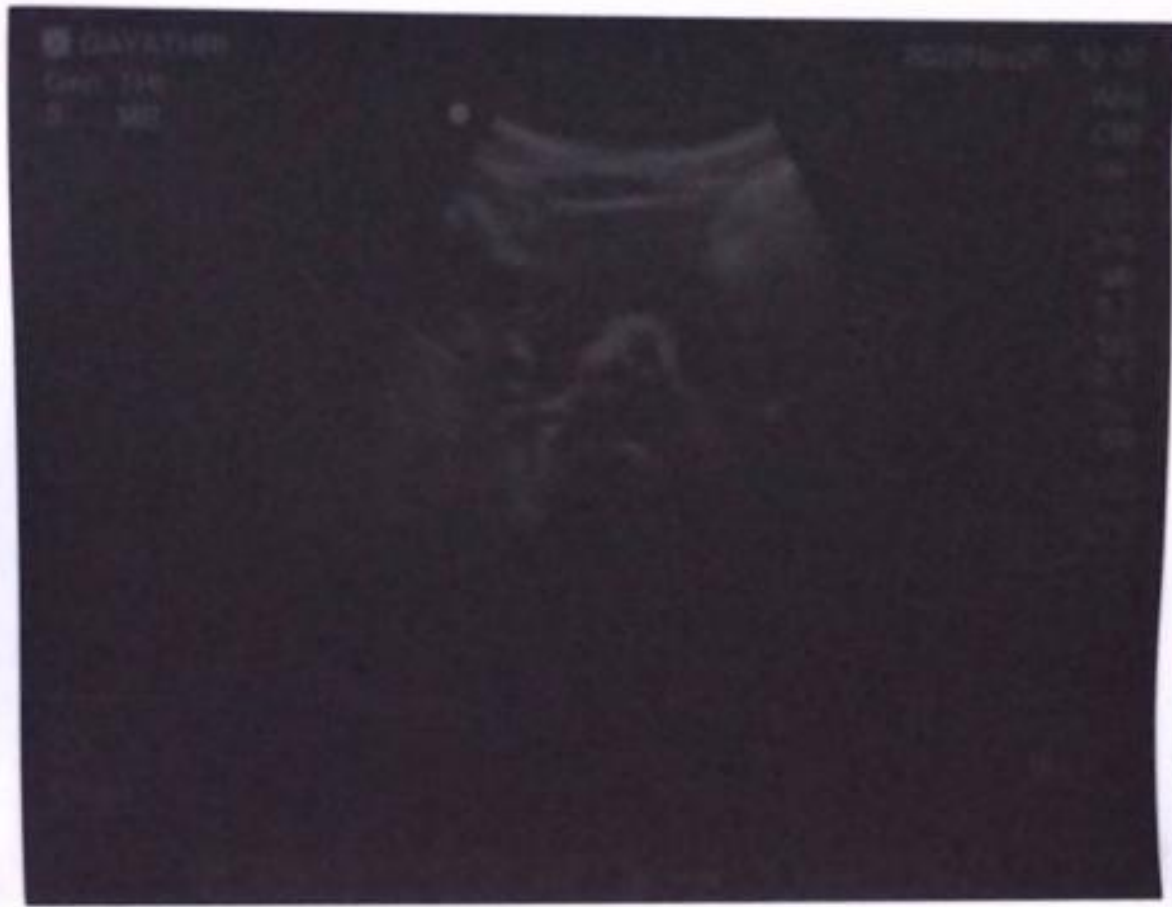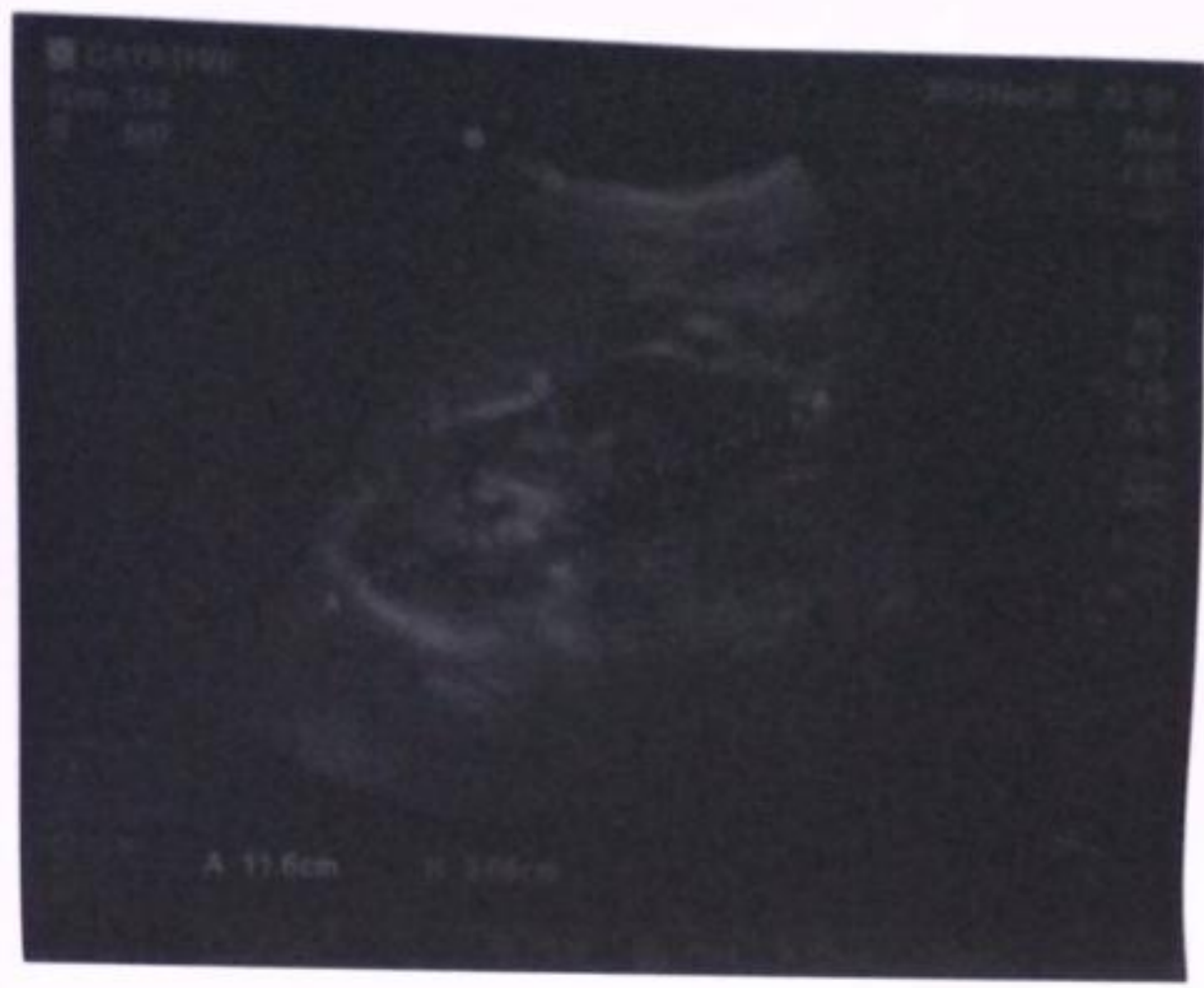13/20

Let Port X Dents Done











MURUGAN HOSPITALS

HEALING HANDS



LAB REPORT

Patient Name : Mrs. P.GAYATHRI
 Age / Gender : 29-Years / Female
 UHID ID : MH20220041815
 Doctor Name : Dr. ARUN PRAKASH

OP Report No. : INVA2107893
 Bill No. : INV2205625
 Sample Date : 26/11/2022 - 09:00 AM
 Report Date : 26/11/2022 - 04:11 PM

Test Name	Result	Units	Reference Interval
HAEMATOLOGY			
Complete Blood Cell Count(CBC)			
HAEMOGLOBIN	13.0	gms/dl	male :13.0 - 17.0 female :12.0 - 15.0
PACKED CELL VOLUME	40.0	%	male : 40 - 50 female : 36 - 46
RBC COUNT	<u>4.62</u>	millions cells/cu.mm	female: 3.8 - 4.8 male : 4.5 - 5.5
TOTAL WBC	6,200	Cells/Cumm	4,000 - 11,000
Differential Count			
NEUTROPHILS	62	%	40 - 65
LYMPHOCYTES	34	%	30-50
EOSINOPHILS	04	%	01-06
MONOCYTES	<u>00</u>	%	1-10
BASOPHILS	00	%	0-2
ESR 60 MTS	07	mm	5 - 20
PLATELET COUNT	3.43	Lakhs/cumm	1.5 - 4.5
MCV	86.7	fL	76 - 96
MCH	28.1	pg	27 - 32
MCHC	32.5	gms/dl	30 - 36
<i>INTERPRETATION: Test done on automated three part cell counter ,all abnormal results are reviewed and confirmed microscopically</i>			
BLOOD GROUPING & RH TYPING	" B "POSITIVE		

Healing Hearts and Lives

264/125, Kilpauk Garden Road, Kilpauk, Chennai - 600 010.
 Phone : +91 44 4644 8989 / 75500 53335 | Email : muruganhosp@gmail.com
 Website : www.muruganhospitals.in



LAB REPORT

Patient Name : Mrs. P.GAYATHRI
 Age / Gender : 29-Years / Female
 UHID ID : MH20220041815
 Doctor Name : Dr. ARUN PRAKASH

OP Report No. : INVA2107893
 Bill No. : INV2205625
 Sample Date : 26/11/2022 - 09:00 AM
 Report Date : 26/11/2022 - 05:47 PM

Test Name	Result	Units	Reference Interval
BIO CHEMISTRY			
BLOOD SUGAR FASTING	80	mgs/dl	70-110
BLOOD SUGAR POST PRANDIAL	88	mgs/dl	80- 160
SERUM URIC ACID	2.5	mg/dl	male 3.1-7.0 , female 2.5-5.6
SERUM CREATININE	0.7	mg/dl	0.6-1.4
LIPID PROFILE			
TOTALCHOLESTEROL	170	mg/dl	< 200
TRIGLYCERIDE	68	mg/dl	< 150
HDL	46	mg/dl	35 - 80
VLDL	14	mg/dl	2 to 30
LDL	110	mg/dl	<130
CHOLESTEROL/ HDL RATIO	3.6	mg/dl	



MURUGAN HOSPITALS

HEALING HANDS



LAB REPORT

Patient Name : Mrs. P.GAYATHRI
 Age / Gender : 29-Years / Female
 UHID ID : MH20220041815
 Doctor Name : Dr. ARUN PRAKASH

OP Report No. : INVA2107893
 Bill No. : INV2205625
 Sample Date : 26/11/2022 - 09:00 AM
 Report Date : 26/11/2022 - 04:11 PM

Test Name	Result	Units	Reference Interval
LIVER FUNCTION TEST			
BILLIRUBIN(TOTAL)	0.6	mg/dl	0.0 -1.0
BILLIRUBIN(DIRECT)	0.2	mg/dl	0.1- 0.30
BILLIRUBIN(INDIRECT)	0.4	mg/dl	0.2-0.8
SGOT	24	IU/L	0-38
SGPT	16	IU/L	0.0-40
ALKALINE PHOSPHATASE	85	IU/L	40-140 4-6Years 93-309 13-15Years 74-390
TOTAL PROTEIN	7.2	gm/dl	6.6-8.7
ALBUMIN	4.0	gm/dl	3.5 - 5.5
GLOBULIN	3.2	gm/dl	2.0-3.5
AG RATIO	1.2		
GAMMA G T	22	U/L	male<49 female<32
BLOOD UREA NITROGEN	7.0	mg/dl	7-21
HBA1C	4.7	%	normal: <6.0 good control: 6.1-7.0 fair control: 7.1- 8.0 poor control:8.1 -10.0 unsatisfactory: >10.0

Healing Hearts and Lives

264/125, Kilpauk Garden Road, Kilpauk, Chennai - 600 010.
 Phone : +91 44 4644 8989 / 75500 53335 | Email : muruganhosp@gmail.com
 Website : www.muruganhospitals.in



MURUGAN HOSPITALS

HEALING HANDS



LAB REPORT

Patient Name : Mrs. P.GAYATHRI
Age / Gender : 29-Years / Female
UHID ID : MH20220041815
Doctor Name : Dr. ARUN PRAKASH

OP Report No. : INVA2107893
Bill No. : INV2205625
Sample Date : 26/11/2022 - 09:00 AM
Report Date : 26/11/2022 - 04:11 PM

Test Name	Result	Units	Reference Interval
-----------	--------	-------	--------------------

SHENBAGAVALLI
Verified by

*** End of Report ***

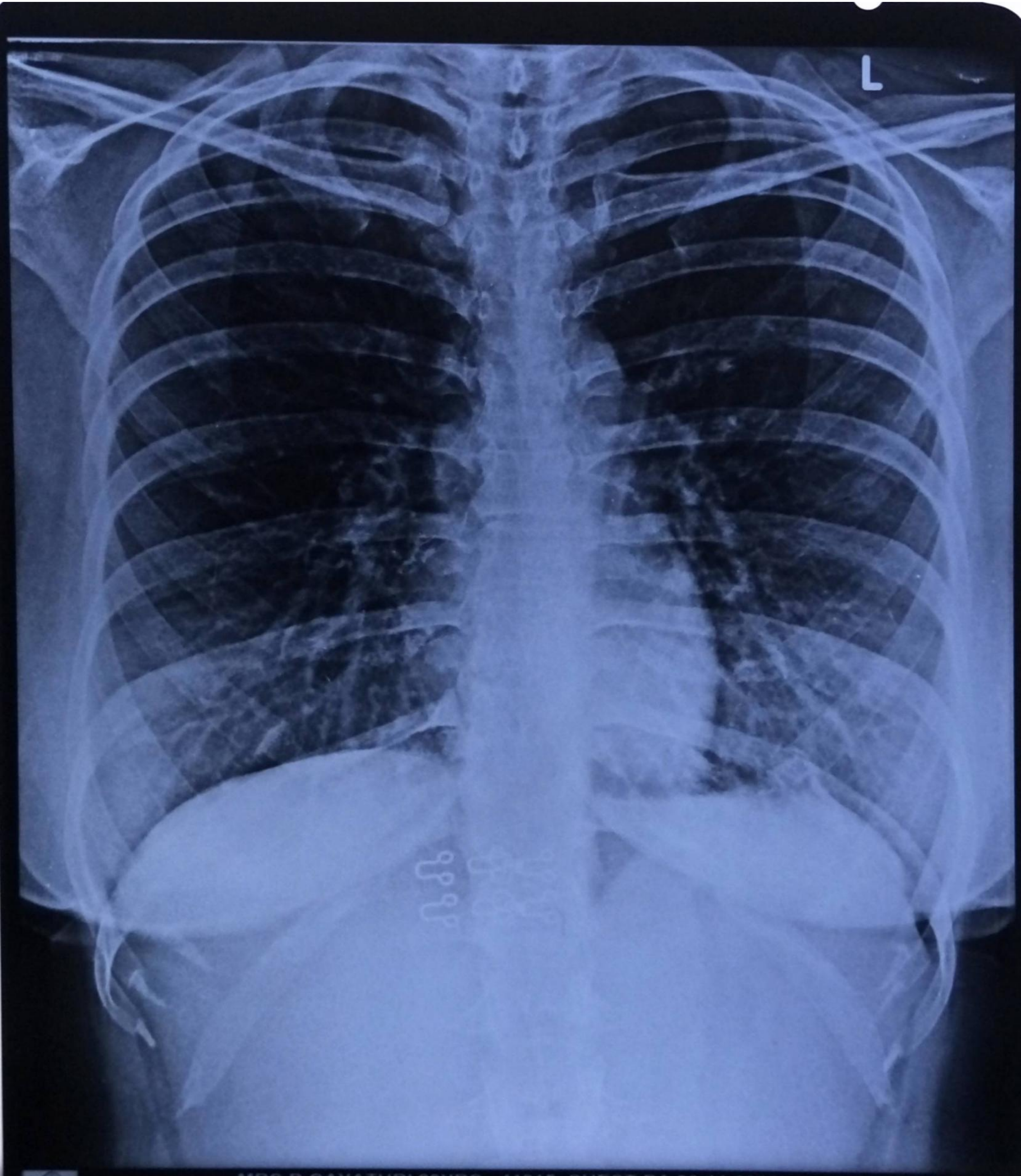
Authorized Signature

PAVITHRA
Pathologist
Reg. No. 78258



Healing Hearts and Lives

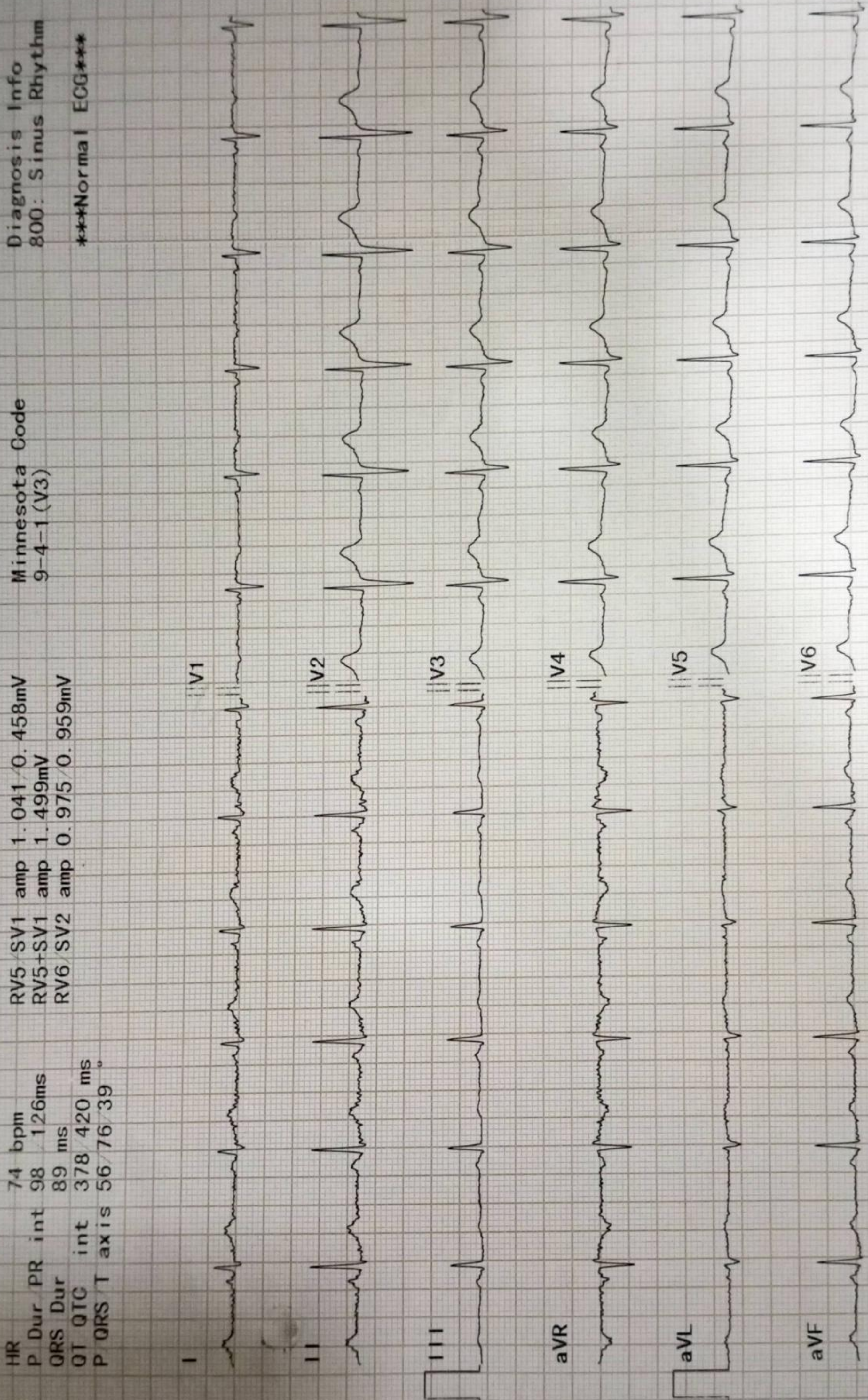
264/125, Kilpauk Garden Road, Kilpauk, Chennai - 600 010.
Phone : +91 44 4644 8989 / 75500 53335 | Email : muruganhosp@gmail.com
Website : www.muruganhospitals.in



MRS P. GAYATHRI 29YRS 41815 CHEST-PA 26-11-2022

MURUGAN HOSPITALS, KILPAIK, CHENNAI 10 PH. NO. 755005135

ID : 2211260002 DataTime: 2022-11-26 09:36 PatientID: Hospital: MURUGAN HOSPITALS
 Name: MRS GAYATHRI Age : 29 Height : 159 cm Diagnosis Info
 Sex : Female BP : 100/60 mmHg Weight : 54 kg 800: Sinus Rhythm
 Divisions: Bed No.: Hospital No.: ***Normal ECG***
 HR : 74 bpm RV5 SV1 amp 1.041/0.458mV Minnesota Code
 P Dur PR int 98 / 126ms RV5+SV1 amp 1.499mV 9-4-1 (V3)
 QRS Dur 89 ms RV6 SV2 amp 0.975/0.959mV
 QT QTC int 378 / 420 ms
 P QRS T axis 56 / 76 / 39



SIDDHARTHAN MD .DM
 Consultant Cardiologist
 Reg No: 62979

Diagnosis for reference, ask your doctor to confirm
 AUTO PRINT 6X2+1R 74bpm 10 mm/mV 0.50Hz-35Hz AC 50Hz 25 mm/sec Confirmed By:



MURUGAN HOSPITALS

HEALING HANDS

NAME : MRS.GAYATHRI
AGE /GENDER:29YRS/ FEMALE
CONSULTANT: DR.ARUNPRAKASH


UHID : MH20220041815
IP/OP : OP
DATE : 26.11.2022

X-RAY CHEST (PA VIEW)

- The cardio thoracic ratio is normal
- The heart size and configuration are within normal limits
- The aortic arch is normal
- The lung fields show normal broncho- Vascular markings
- Both the pulmonary hila are normal in size
- The costophrenic and cardiophrenic recesses and the domes of diaphragm are normal
- The bones and soft tissues of the chest wall show no abnormality

IMPRESSION:

Normal Study



264/125, Kilpauk Garden Road, Kilpauk, Chennai - 600 010.

☎ : +91 44 4644 8989 / 75500 53335 email : muruganhosp@gmail.com

Website : www.muruganhospitals.in