



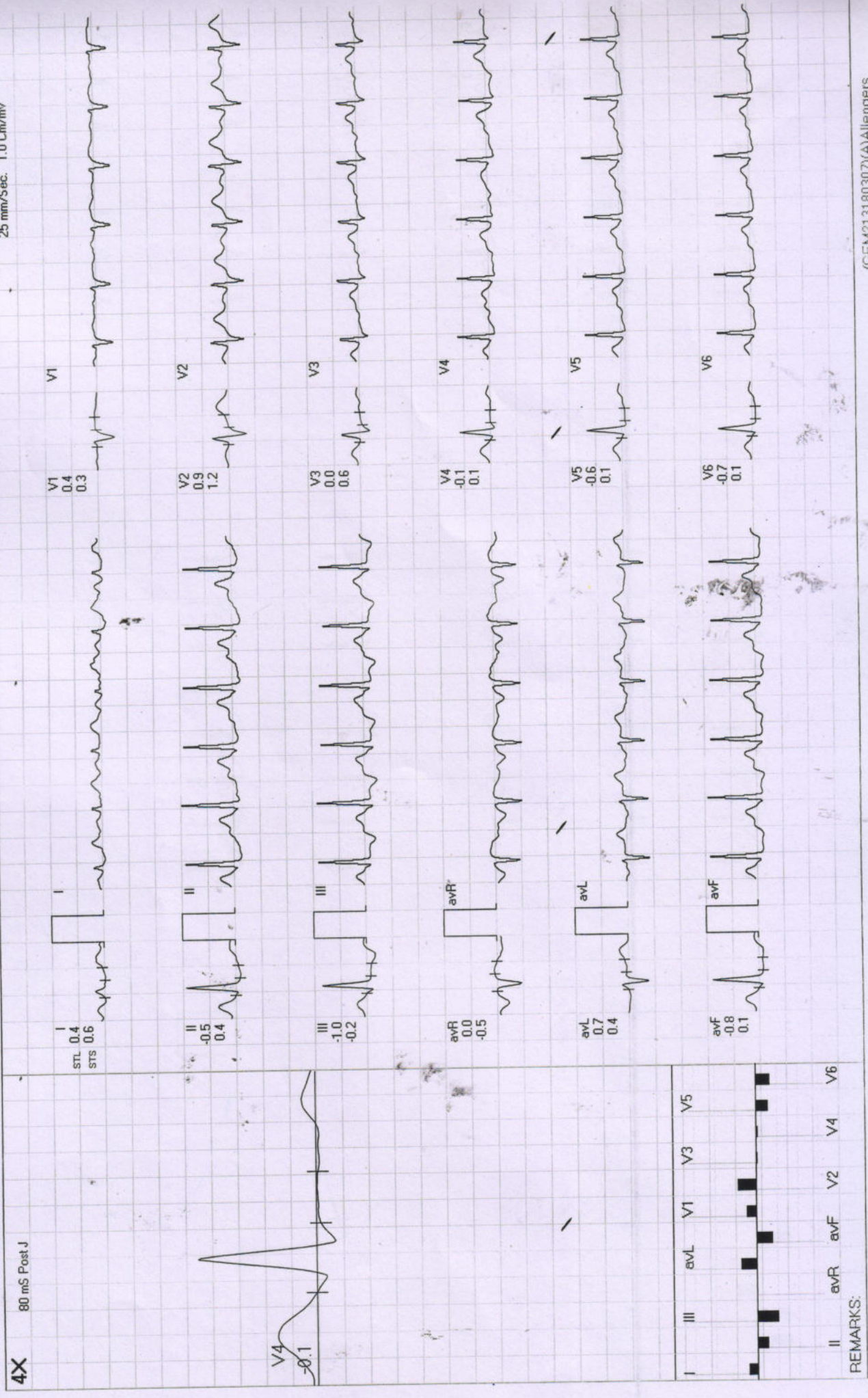
BRUCE : Stage 1 ( 03:00 )

Diwakar Diagnostic Centre

902 / PALLAVI TRIVEDI / 38 Yrs / F

ExTime: 03:00 1.7 mph, 10.0%  
25 mm/Sec. 1.0 Cm/mV

Date: 10-Dec-2022 11:09:17 AM METS: 4.7/121 bpm 66% of THR BP: 124/82 mmHg Raw ECG/BLC-On/Notch On/HF 0.05 Hz/LF 20 Hz



PTO

nonrelatv clinic beavda

Right Kidney is normal in size, shape and position. Corticomedullary differentiation (CMD) is well maintained. Normal cortical thickness is noted. No E/O hydronephrosis or calculus is noted.

THIS IS NOT A MASS REPORT

Pancreas appear normal in size, shape and echo texture with smooth contour. No peripancreatic pathology seen. (Not seen due to gases) Spleen is normal / enlarged in size and normal in echo texture. IVC and aorta appear to be normal. No evidence of lymphadenopathy is noted. No evidence of free fluid is noted.

Liver appears normal / enlarged in size and shape with smooth in outline. Normal / increased parenchymal echogenicity is noted. No E/O focal lesion / IHBR dilatation is seen. Hepatic veins and portal veins appear normal. No E/O Subdiaphragmatic Collection.

Gall Bladder is physiologically well distended / collapsed. No E/O echogenic foci in GB lumen. GB wall is normal / thickened. No E/O pericholecystic collection. common duct reveals normal course and caliber.

Indication :  
WHOLE ABDOMEN ULTRASOUND REPORT

Name : Mrs. Pallavi Invele 38/F  
R/B Health check-up  
Date 10/12/2022  
Age YRS/IF

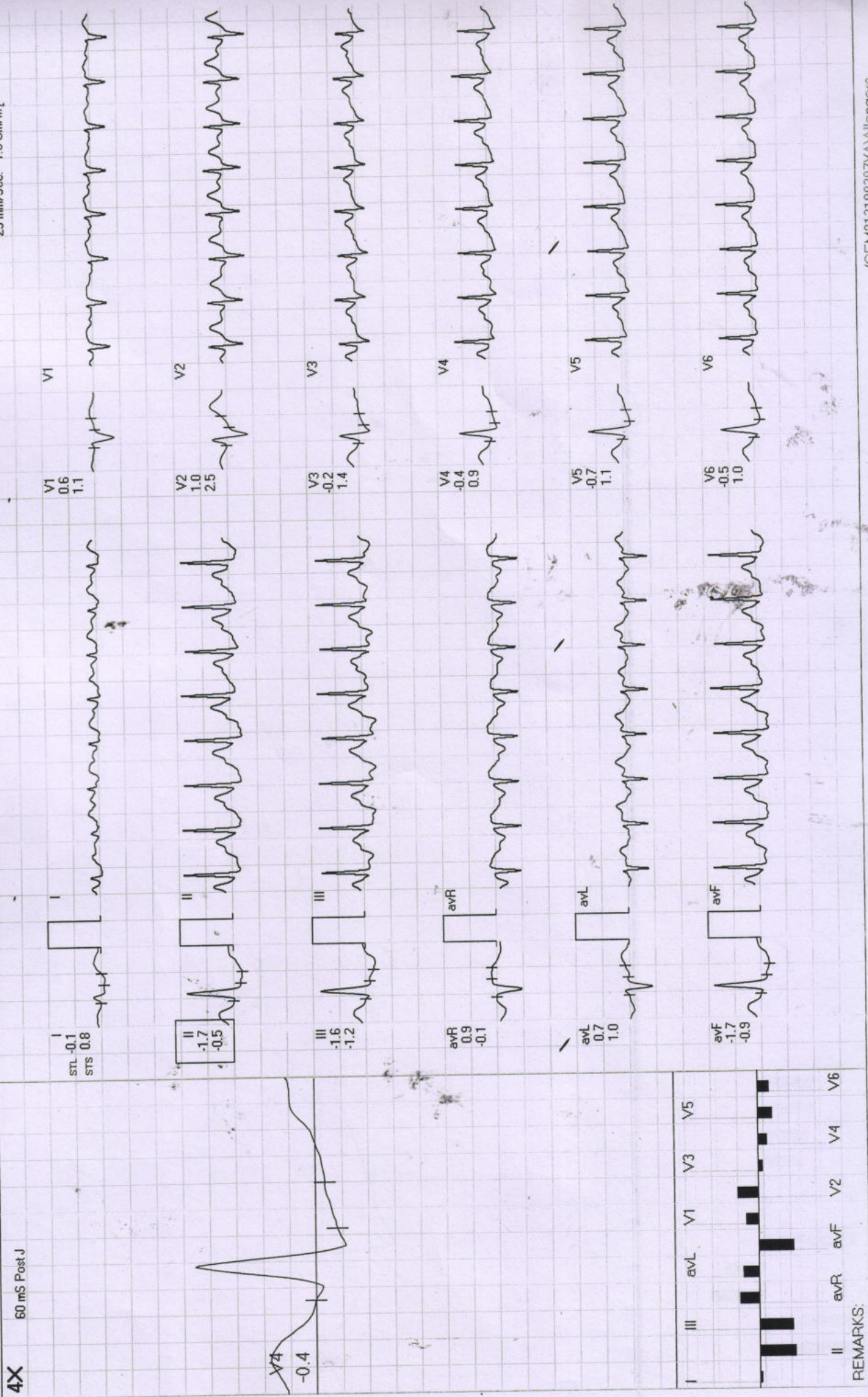
**डॉ. सविता रिडियोलॉजिक**  
34, भूल, मोहिनी आदि आर्कड, शाहपुरा मस्जिद के पास  
भरत नगर रोड, ई-7/194, अररा कॉलोनी, भोपाल - 462038  
Mob : 8989649694, 9516333619  
Clinic Registration : CL/5392/Jun/2017  
PNDT Registration : MP/CPNDT/BPL/2017/206





Date: 10-Dec-2022 11:09:17 AM METS: 7.1 / 145 bpm 79% of TH-R BP: 130/90 mmHg Raw ECG/BLC On/ HF 0.05 Hz/LF 20 Hz

ExTime: 06:00 2.5 mph, 12.0%  
25 mm/Sec. 1.0 Cm/mV



Left Kidney is normal in size, shape and position. CMD is well maintained. Normal cortical thickness is noted. No E/O hydronephrosis or calculus is noted.

Urinary Bladder is well distended (physiological) / collapsed. Its contents are echo free. No E/O bladder wall thickening is noted. Post-void residue is insignificant.

Prostate is normal in size, shape and echo texture with smooth outline. No E/O focal lesion is noted.

Uterus is ante/retro verted and normal in size, shape and echotexture with smooth outline. No E/O focal lesion is noted, endometrial echo appear normal. Cervical and vaginal shadows appear normal.

Right Ovary appears Enlarged / Normal in size, shape and echo texture.

Left Ovary appears Enlarged / Normal in size, shape and echo texture.

Impression : Normal study.

Advised clinical Correlation.


5 Oct

Date: 10-Dec-2022 11:09:17 AM METS: 7.2/149 bpm 81% of THR BP: 130/90 mmHg Raw ECG/BLC On/ HF 0.05 Hz/LF 20 Hz

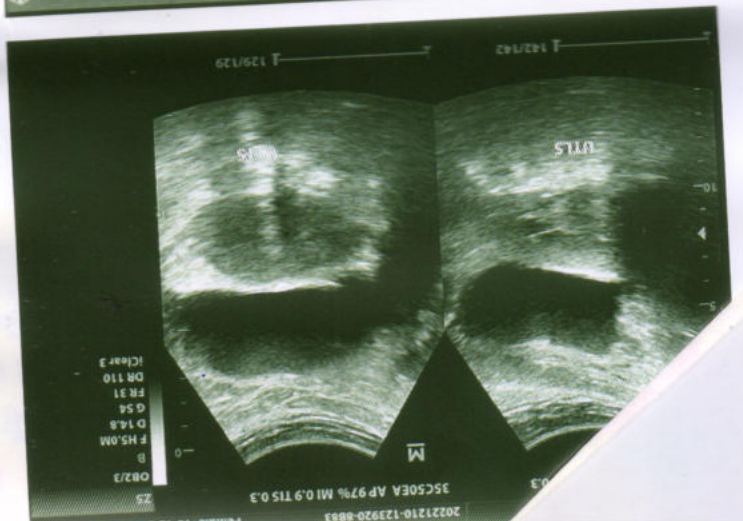
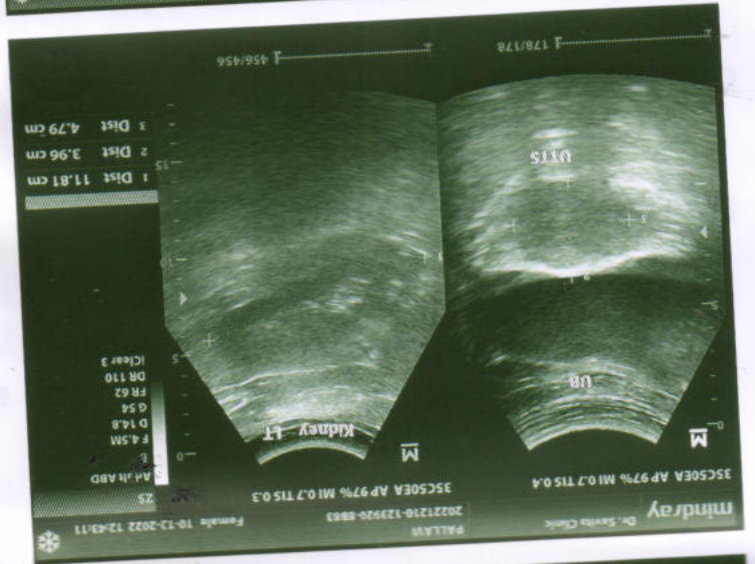
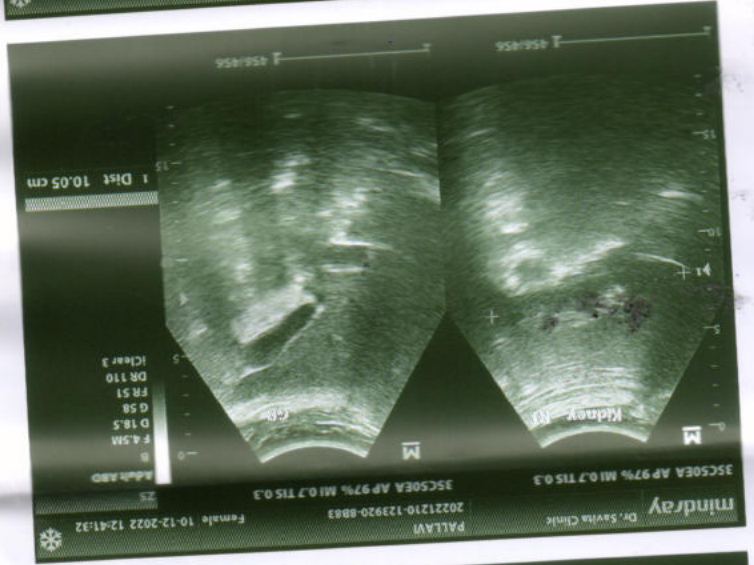
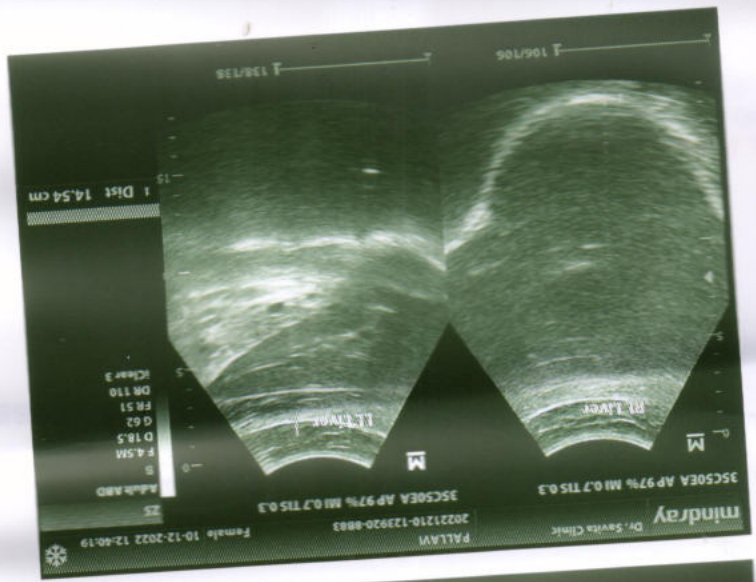
ExTime: 06:06 3.4 mph 14.0%

4X

50 mS Post J



REMARKS:



**SOUND REPORT**

kidney shape with smooth in outline. No E/O focal lesion / IHBR appear normal.

collapsed. No E/O echogenic foci in pericholecystic collection. common

texture with smooth (seen due to gases) echo texture.

Corticomedullary differentiation is noted. No E/O hydronephrosis

PTO

**Dr. Jayant Yadav, MD**  
MBBS, MD (Radiologist) Reg. No. 4166  
रिडियोलॉजिस्ट

No. .... Date 10/12/2022  
Age ..... YRS./F

**दत्तानन्द**  
शाहपुरा मस्जिद के पास  
लॉजी, भोपाल - 462038  
9516333619  
392/Jun/2017  
DT/BPL/2017/206





Recovery : ( 01:00 )

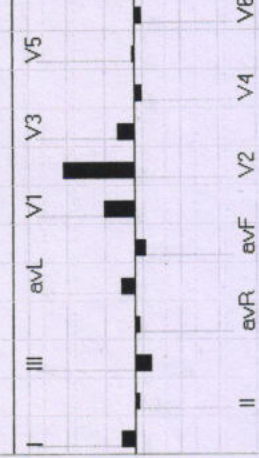
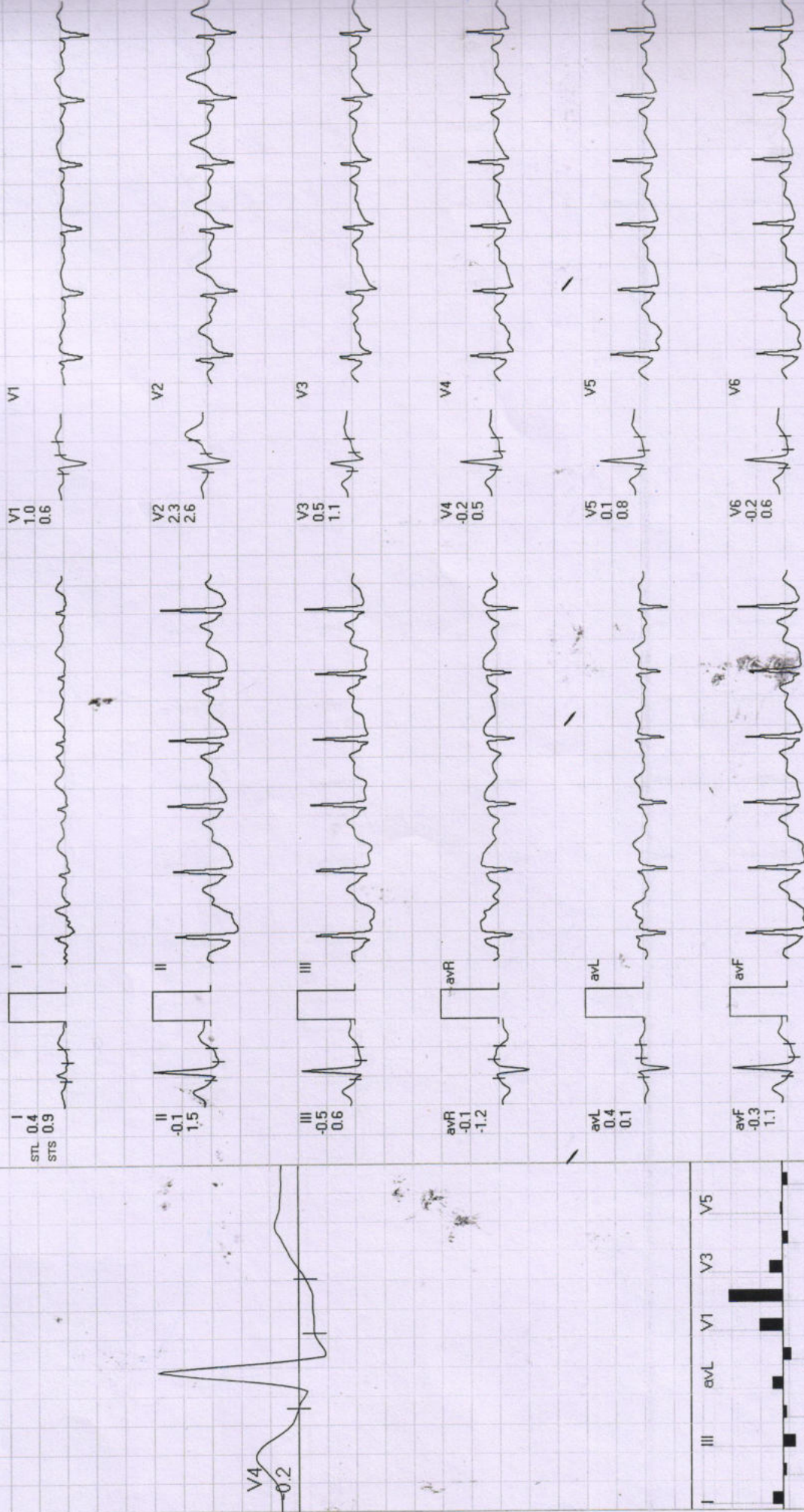
Diwakar Diagnostic Centre

902/PALLAVI TRIVEDI /38 Yrs /F

Date: 10-Dec-2022 11:09:17 AM METS: 1.1 / 114 bpm 62% of THR BP: 126/80 mmHg Raw ECG/BLC Or/ HF 0.05 Hz/LF 20 Hz

ExTime: 06:06 0.0 mph. 0.0%  
25 mm/Sec. 1.0 Cp/mV

4X -80 mS Post J



REMARKS:



Pt Name :- Mrs. Pallavi Trivedi  
 Age :- 38/F  
 Lab. No. :- 03  
 Date :- 10/12/2022

## EXAMINATION OF BLOOD

TEST	RESULT	NORMAL VALUE
Haemoglobin	12.7gms%	Female 12-16gms%, Male 14-18gms%
Red Cell count	4.53	4.5-5.6 million /cumm
Platelet Count	3.17	1.5-5.6 Lac/cumm
Leucocytes per.cu.mm	7500/cumm	5000-11000/cumm
Neutrophils	65%	50-70%
Lymphocytes	28%	20-40%
Eosinophils	03%	0-7%
Monocytes	04%	2-8%
PCV	38.0	37-47
MCV	83.9	76-96
MCH	28.0	27-32
MCHC	33.4	31-35
ESR	14	Male 0-9, Female 0-20mm/FHR
Blood Group	"B" Positive	By slide method
Total Serum Cholesterol	155.0	100-250 mg%
Serum Triglyceride	125.0	Up to 150 mg%
Serum Cholesterol HDL	45.0	Up to 65 mg%
Serum Cholesterol LDL	85.0	Up to 125 mg%
LDL	25.0	Up to 30 mg%
S.Bilirubin(Total)	0.80	0.2-1.0mg/dl
Direct	0.40	0.0-0.25mg/dl
Indirect	0.40	
SGOT	19.0	5-35U/L
SGPT	21.0	8-40U/L
Alk Phosphatase	9.5	3-13 KA units
S. Protein(Total)	6.0	6.0-8.0mg%
Albumin	4.0	3.7-5.3mg%
Globulin	2.0	1.5 to 3.5 mg%
Blood Urea	21.9	Up to 40 mg%
S.Creatine	0.85	0.5-1.4mg/dl
S. Uric Acid	6.0	3.5-7.5mg%
GTP	22.0	5-35 UL/dl
Fasting Blood Sugar	89.2	Up to 110 mg%
PP Blood Sugar	109.0	Up to 125 mg%
Glycosylated Hemoglobin	5.1	Below - 6.0 % -Non Diabetic control 6-7 % -Excellent control Above- 8 % -Poor control
HBA1c		
Thyrod Stimulating Hormone(TSH)	4.01	0.27-4.2

Pathologist

All test have technical limitation. Collaborative clinic pathological interpretation is mandatory. In case of disparity test may be repeated immediately. Typographical mistakes should be get correct instantly. This report is not valid for medico legal purpose



Dr. B. M. Agarwal  
 MBBS, DCP  
 Consultant Pathologist





Recovery : ( 02:00 )

Diwakar Diagnostic Centre


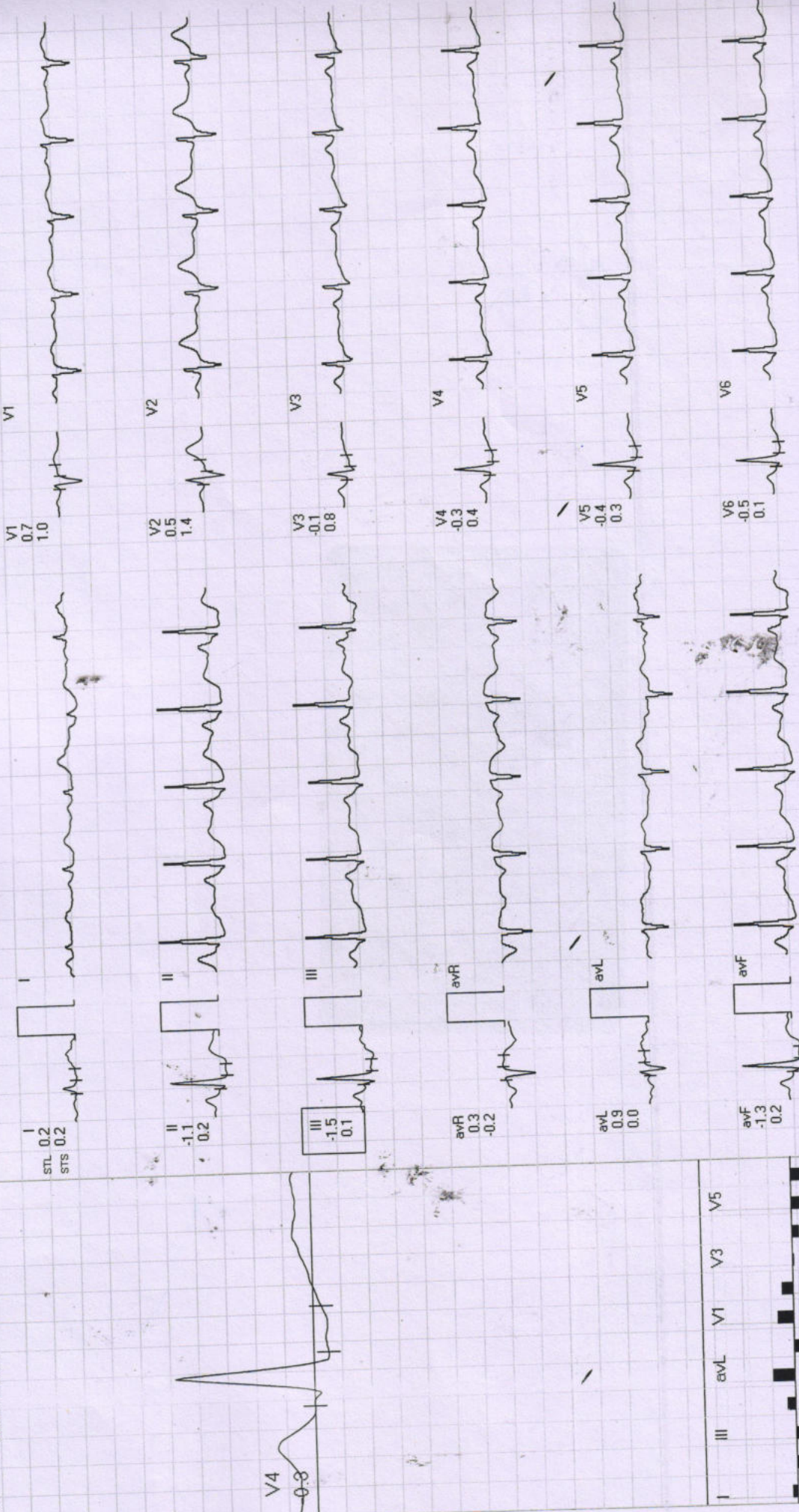
902 / PALLAVI TRIVEDI / 38 Yrs / F

ExTime: 06:06 0.0 mph. 0.0%

Date: 10-Dec-2022 11:09:17 AM METS: 1.0/97 bpm 53% of THR BP: 122/80 mmHg Raw ECG/BLC On/ Notch On/ HF 0.05 Hz/LF 20 Hz

25 mm/Sec. 1.0 Cm/mV

4X 80 mS Post J



REMARKS:



Pt Name :- Mrs. Pallavi Trivedi  
 Age :- 38/F  
 Lab. No. :- 03  
 Date :- 10/12/2022

## URINE ANALYSIS


A. PHYSICAL EXAMINATION	
1. Colour	Pale Yellow
2. Appearance	Clear
3. Specific Gravity	Q.N.S.
B. CHEMICAL EXAMINATION	
1. Reaction	Acidic
2. Albumin	Nil
3. Sugar	Nil
4. Bile Salts	Absent
C. MICROSCOPIC EXAMINATION	
Pus Cells	1-2/HPF
R.B.C.	Nil
Epithelial Cell	occ
Cast	Nil
Crystals(Cal.Oxa)	Nil
Bacteria	Nil
Amorphous	Nil
T. Vaginitis	Nil

Dr. B. M. Agarwal  
 MBBS, DCP  
 Consultant Pathologist

Pathologist




*Jawan*



Pallavi Shivach

Age - 38 Y / F

11/12/2022



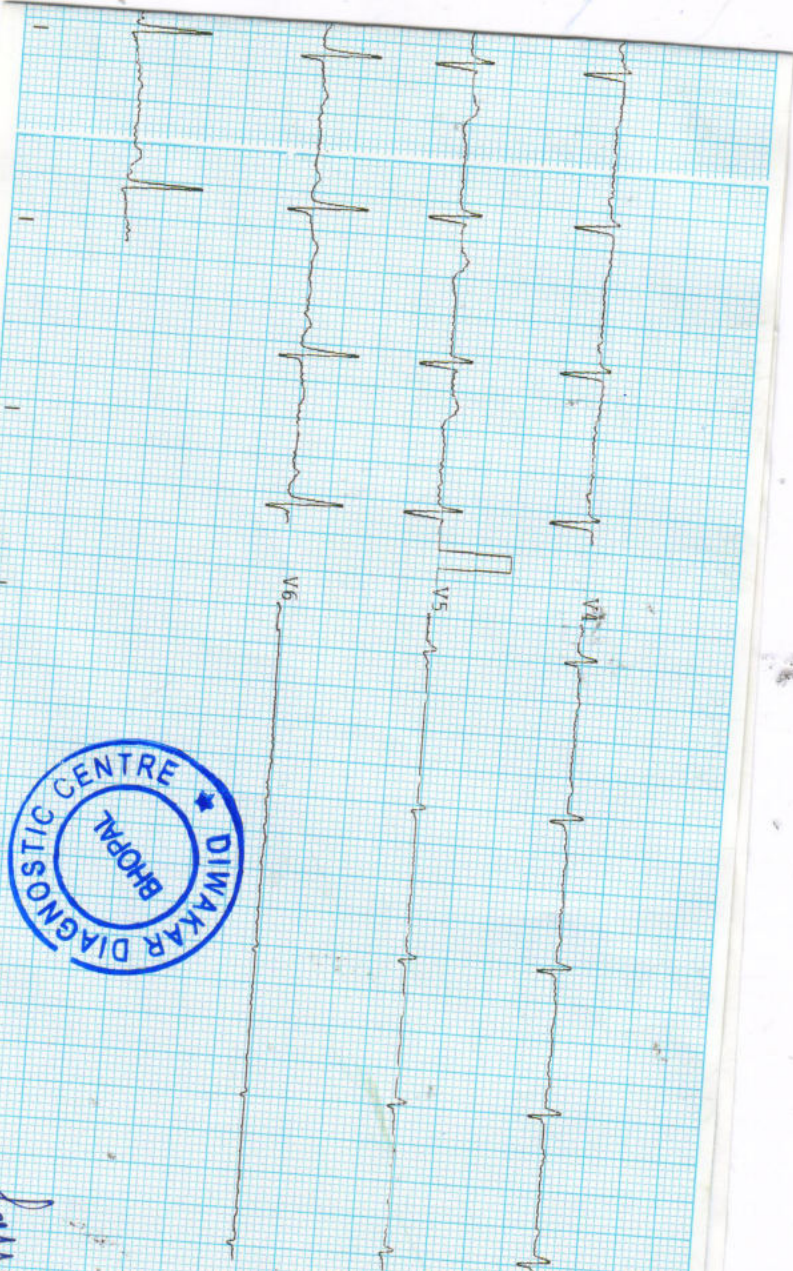


*Jain*

UrboMed report

Remarks: -

Observations :-  
HR : 75 bpm  
R-R : 792 ms  
P-R : 106 ms  
QRS : 56 ms  
QT/QTc : 214/240 ms  
P Axis: 55 °  
R Axis: 63 °  
T Axis: -75 °



**Diwakar Diagnostic Centre**  
**E-7/636, Arera Colony, Bhopal**

902 / PALLAVI TRIVEDI / 38 Yrs / F / 0 Cms / 0 Kg Date: 10-Dec-2022 Refd By : BOB

**Report :**

TEST OBJECTIVE : ROUTINE CHECK UP  
RISK FACTOR : FEMALE  
ACTIVITY : MODERATE ACTIVE  
MEDICATION : NONE  
REASON FOR TERMINATION : HEART RATE ACHIEVED  
EXERCISE TOLERANCE : GOOD  
EXERCISE INDUCED ARRHYTHMIAS : NO  
HAEMODYNAMIC RESPONSE : NORMAL  
CHRONOTROPIC RESPONSE : NORMAL  
FINAL IMPRESSION : STRESS TEST IS NEGATIVE FOR EXERCISE INDUCED ISCHAEMIC HEART DISEASE

*Pallavi*



PTO

Right Kidney is normal in size, shape and position. Corticomedullary differentiation (CMD) is well maintained. Normal cortical thickness is noted. No E/O hydronephrosis or calculus is noted.

Pancreas appear normal in size, shape and echo texture with smooth contour. No peripancreatic pathology seen. (Not seen due to gases) Spleen is normal / enlarged in size and normal in echo texture. IVC and aorta appear to be normal. No evidence of lymphadenopathy is noted. No evidence of free fluid is noted.

Gall Bladder is physiologically well distended / collapsed. No E/O echogenic foci in GB lumen. GB wall is normal / thickened. No E/O pericholecystic collection. common duct reveals normal course and caliber.

Liver appears normal / enlarged in size and shape with smooth in outline. Normal / increased parenchymal echogenicity is noted. No E/O focal lesion / IHBR dilatation is seen. Hepatic veins and portal veins appear normal. No E/O Subdiaphragmatic Collection.

WHOLE ABDOMEN ULTRASOUND REPORT

Indication :

Name : Mrs. Pallavi Invele 38/F  
R/B Health check-up  
Date 10/12/2022  
Age YRS/IF



902 / PALLAVI TRIVEDI / 38 Yrs / F / 0 Cms / 0 Kg Date: 10-Dec-2022 Refd By : BOB

Stage	Time	Duration	Belt Speed (mph)	Elevation	METs	Rate	% THR Achieved	BP	RPP	PVC	Comments
Supine	00:11	0:01	00.0	00.0	01.0	83	46 %	116/78	096	00	
Supine	00:24	0:01	00.0	00.0	01.0	87	48 %	116/78	100	00	
Standing	00:35	0:01	00.0	00.0	01.0	078	43 %	116/78	090	00	
HV	00:45	0:01	00.0	00.0	01.0	082	45 %	116/78	095	00	
Warm Up	00:58	0:02	01.7	10.0	01.0	078	43 %	116/78	090	00	
ExStart	01:02	0:06	01.7	10.0	01.1	092	51 %	116/78	106	00	
BRUCE Stage 1	04:02	3:00	01.7	10.0	04.7	121	66 %	124/82	150	00	
BRUCE Stage 2	07:02	3:00	02.5	12.0	07.1	145	80 %	130/90	188	00	
PeakEx	07:08	0:07	00.0	00.0	07.2	153	84 %	130/90	198	00	
Recovery	08:07	1:00	00.0	00.0	01.2	114	63 %	126/80	143	00	
Recovery	09:07	2:00	00.0	00.0	01.0	097	53 %	122/80	118	00	
Recovery	09:23	2:15	00.0	00.0	01.0	098	54 %	122/80	119	00	

**Findings :**

Exercise Time : 06:07  
 Max HR Attained : 153 bpm 84% of Target 182  
 Max BP Attained : (Sys) 130/90  
 Max WorkLoad Attained : 7.2 Fair response to induced stress  
 Test End Reasons : Heart Rate Achieved



Left Kidney is normal in size, shape and position. CMD is well maintained. Normal cortical thickness is noted. No E/O hydronephrosis or calculus is noted.

Urinary Bladder is well distended (physiological) / collapsed. Its contents are echo free. No E/O bladder wall thickening is noted. Post-void residue is insignificant.

Prostate is normal in size, shape and echo texture with smooth outline. No E/O focal lesion is noted.

Uterus is ante/retro verted and normal in size, shape and echotexture with smooth outline. No E/O focal lesion is noted, endometrial echo appear normal. Cervical and vaginal shadows appear normal.

Right Ovary appears Enlarged / Normal in size, shape and echo texture.

Left Ovary appears Enlarged / Normal in size, shape and echo texture.

Impression : Normal study.

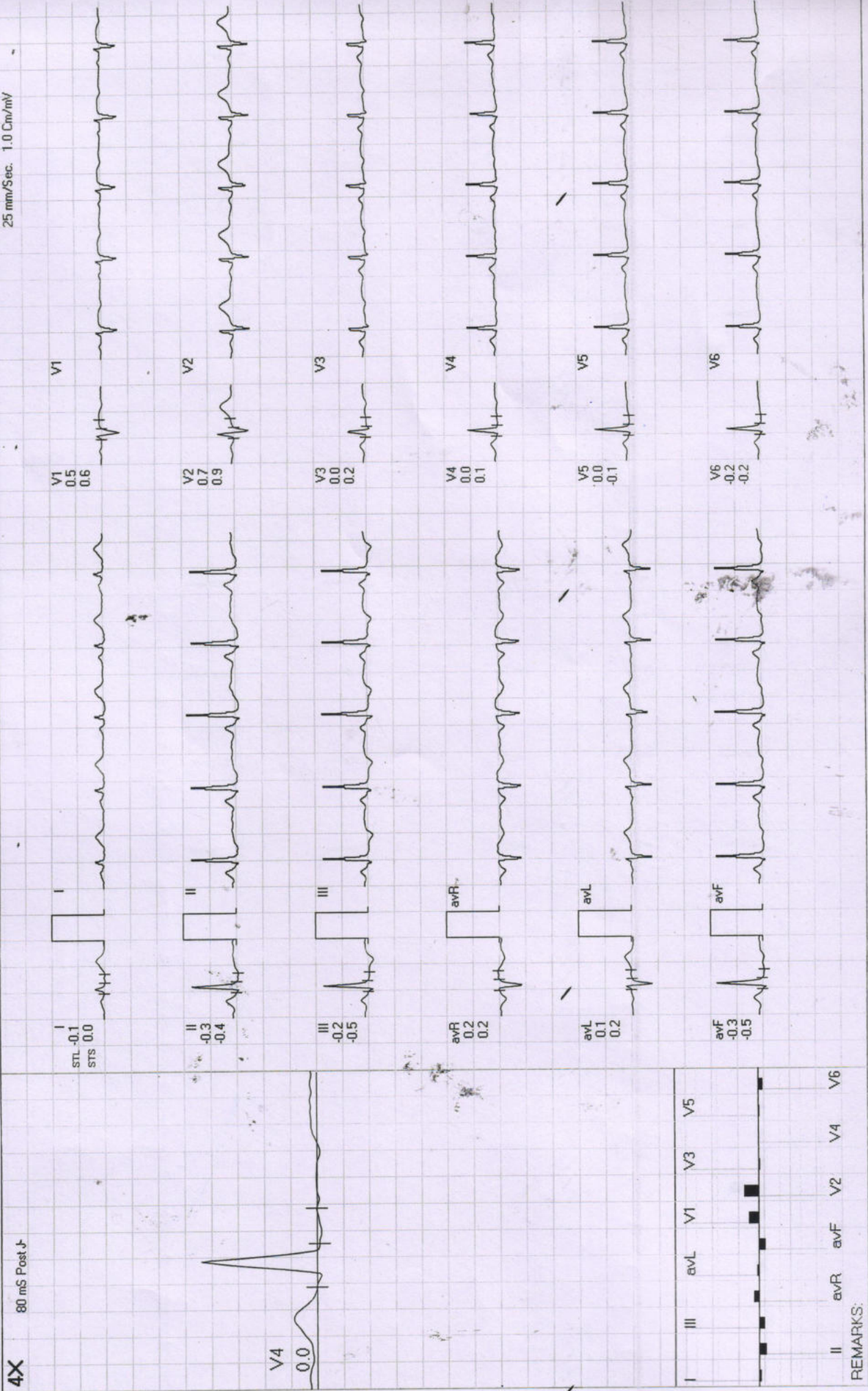
Advised clinical Correlation.

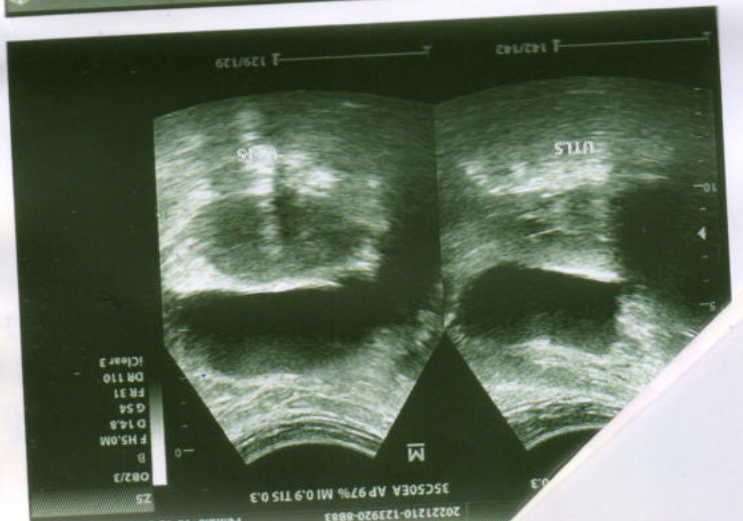
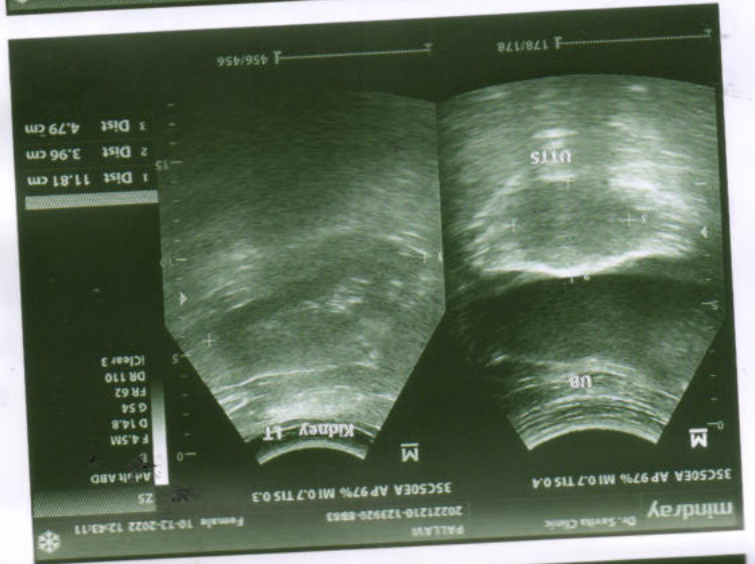
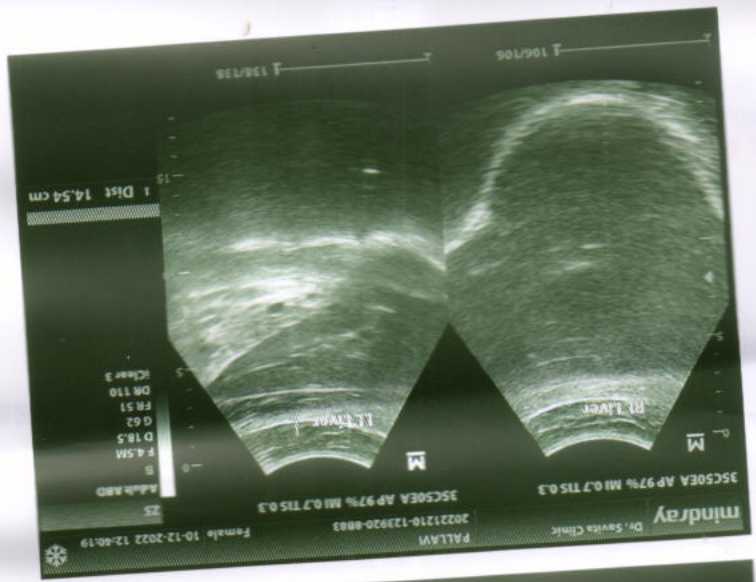
5 Oct



Date: 10-Dec-2022 11:09:17 AM METS: 1.0/ 87 bpm 47% of THR BP: 116/78 mmHg Raw ECG/BLC On/ Notch On/ HF 0.05 Hz/LF 20 Hz

ExTime: 00:23 0.0 mph, 0.0%  
25 mm/Sec. 1.0 Cm/mV





**SOUND REPORT**

and shape with smooth in outline. noted. No E/O focal lesion / IHBR appear normal.

collapsed. No E/O echogenic foci in pericholecystic collection. common

texture with smooth (seen due to gases) echo texture.

Corticomedullary differentiation is noted. No E/O hydronephrosis

PTO

Dr. Jayant Yadav, MD  
MBBS, MD (Radiologist) Reg. No. 4166  
रिडियोलॉजिस्ट

No. .... Date 10/12/2022  
Age ..... YRS./F

**दत्तानन्द**  
शाहपुरा मस्जिद के पास  
लॉजी, भोपाल - 462038  
9516333619  
392/Jun/2017  
DT/BPL/2017/206





STANDING

Diwakar Diagnostic Centre

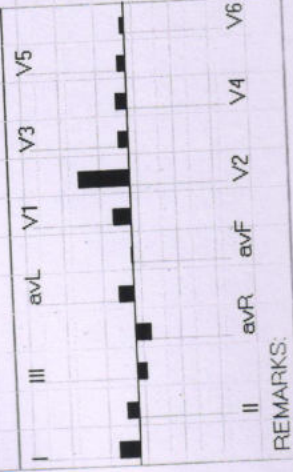
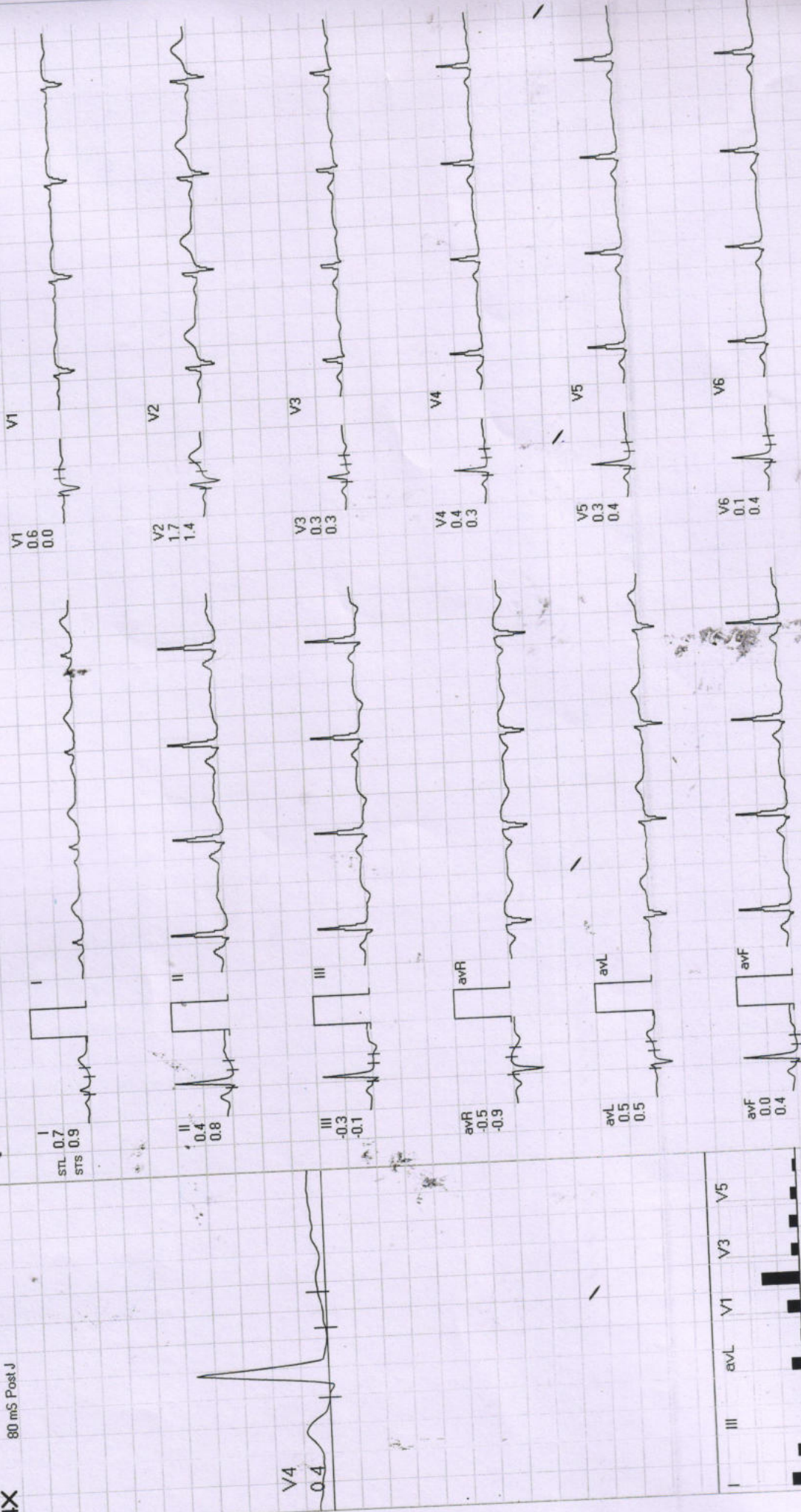
902 / PALLAVI TRIVEDI / 38 Yrs / F

ExTime: 00:34 0.0 mph, 0.0%

25 mm/Sec. 1.0 Cm/mV

Date: 10-Dec-2022 11:09:17 AM METS: 1.0/78 bpm 42% of THR BP: 116/78 mmHg Raw ECG/BLC On/ Natch On/ HF 0.05 Hz/LF 20 Hz

4X 80 mS Post J



REMARKS:



Pt Name :- Mrs. Pallavi Trivedi  
 Age :- 38/F  
 Lab. No. :- 03  
 Date :- 10/12/2022

### EXAMINATION OF BLOOD

TEST	RESULT	NORMAL VALUE
Haemoglobin	12.7gms%	Female 12-16gms%, Male 14-18gms%
Red Cell count	4.53	4.5-5.6 million /cumm
Platelet Count	3.17	1.5-5.6 Lac/cumm
Leucocytes per.cu.mm	7500/cumm	5000-11000/cumm
Neutrophils	65%	50-70%
Lymphocytes	28%	20-40%
Eosinophils	03%	0-7%
Monocytes	04%	2-8%
PCV	38.0	37-47
MCV	83.9	76-96
MCH	28.0	27-32
MCHC	33.4	31-35
ESR	14	Male 0-9, Female 0-20mm/FHR
Blood Group	"B" Positive	By slide method
Total Serum Cholesterol	155.0	100-250 mg%
Serum Triglyceride	125.0	Up to 150 mg%
Serum Cholesterol HDL	45.0	Up to 65 mg%
Serum Cholesterol LDL	85.0	Up to 125 mg%
LDL	25.0	Up to 30 mg%
S.Bilirubin(Total)	0.80	0.2-1.0mg/dl
Direct	0.40	0.0-0.25mg/dl
Indirect	0.40	
SGOT	19.0	5-35U/L
SGPT	21.0	8-40U/L
Alk Phosphatase	9.5	3-13 KA units
S. Protein(Total)	6.0	6.0-8.0mg%
Albumin	4.0	3.7-5.3mg%
Globulin	2.0	1.5 to 3.5 mg%
Blood Urea	21.9	Up to 40 mg%
S.Creatine	0.85	0.5-1.4mg/dl
S. Uric Acid	6.0	3.5-7.5mg%
GGTP	22.0	5-35 UL/dl
Fasting Blood Sugar	89.2	Up to 110 mg%
PP Blood Sugar	109.0	Up to 125 mg%
Glycosylated Hemoglobin	5.1	Below - 6.0 % -Non Diabetic control 6-7 % -Excellent control Above- 8 % -Poor control
HBA1c		
Thyrod Stimulating Hormone(TSH)	4.01	0.27-4.2

Pathologist

All test have technical limitation. Collaborative clinic pathological interpretation is mandatory. In case of disparity test may be repeated immediately. Typographical mistakes should be get correct instantly. This report is not valid for medico legal purpose

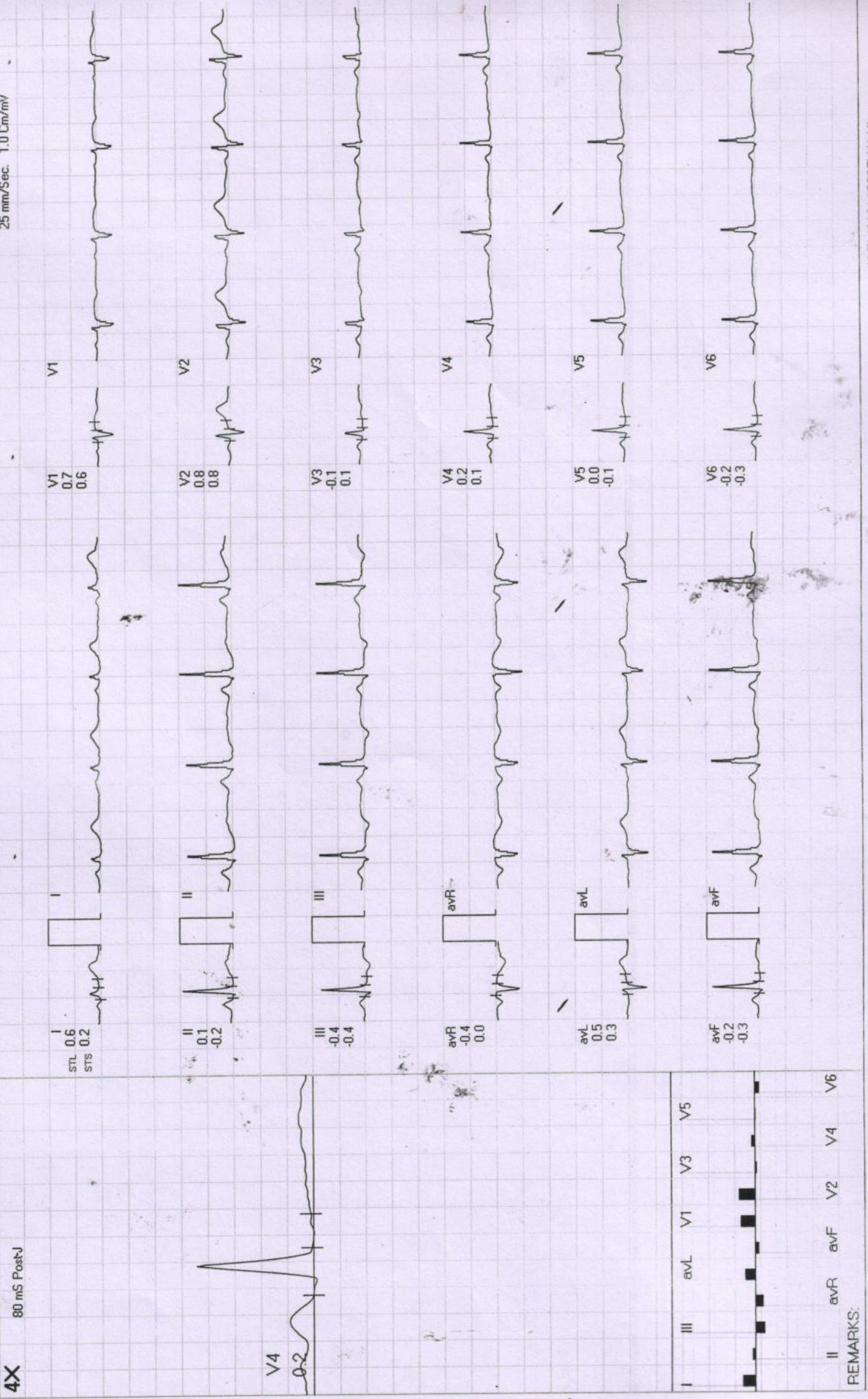


Dr. B. M. Agarwal  
 MBBS, DCP  
 Consultant Pathologist

Date: 10-Dec-2022 11:09:17 AM METS: 1.0/ 82 bpm 45% of TH-R BP: 116/78 mmHg Raw ECG/BLC On/ Notch On/ HF 0.05 Hz/LF 20 Hz

ExTime: 00:44 0.0 mph, 0.0%

25 mm/Sec. 1.0 Cm/mV



REMARKS:



Pt Name :- Mrs. Pallavi Trivedi  
 Age :- 38/F  
 Lab. No. :- 03  
 Date :- 10/12/2022

## URINE ANALYSIS

A. PHYSICAL EXAMINATION	
1. Colour	Pale Yellow
2. Appearance	Clear
3. Specific Gravity	Q.N.S.
B. CHEMICAL EXAMINATION	
1. Reaction	Acidic
2. Albumin	Nil
3. Sugar	Nil
4. Bile Salts	Absent
C. MICROSCOPIE EXAMINATION	
Pus Cells	1-2/HPF
R.B.C.	Nil
Epithelial Cell	occ
Cast	Nil
Crystals(Cal.Oxa)	Nil
Bacteria	Nil
Amorphous	Nil
T. Vaginitis	Nil

Dr. B. M. Agarwal  
 MBBS, DCP  
 Consultant Pathologist

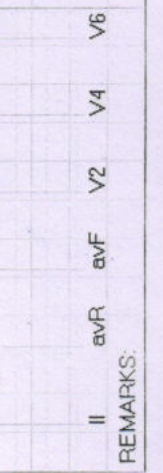
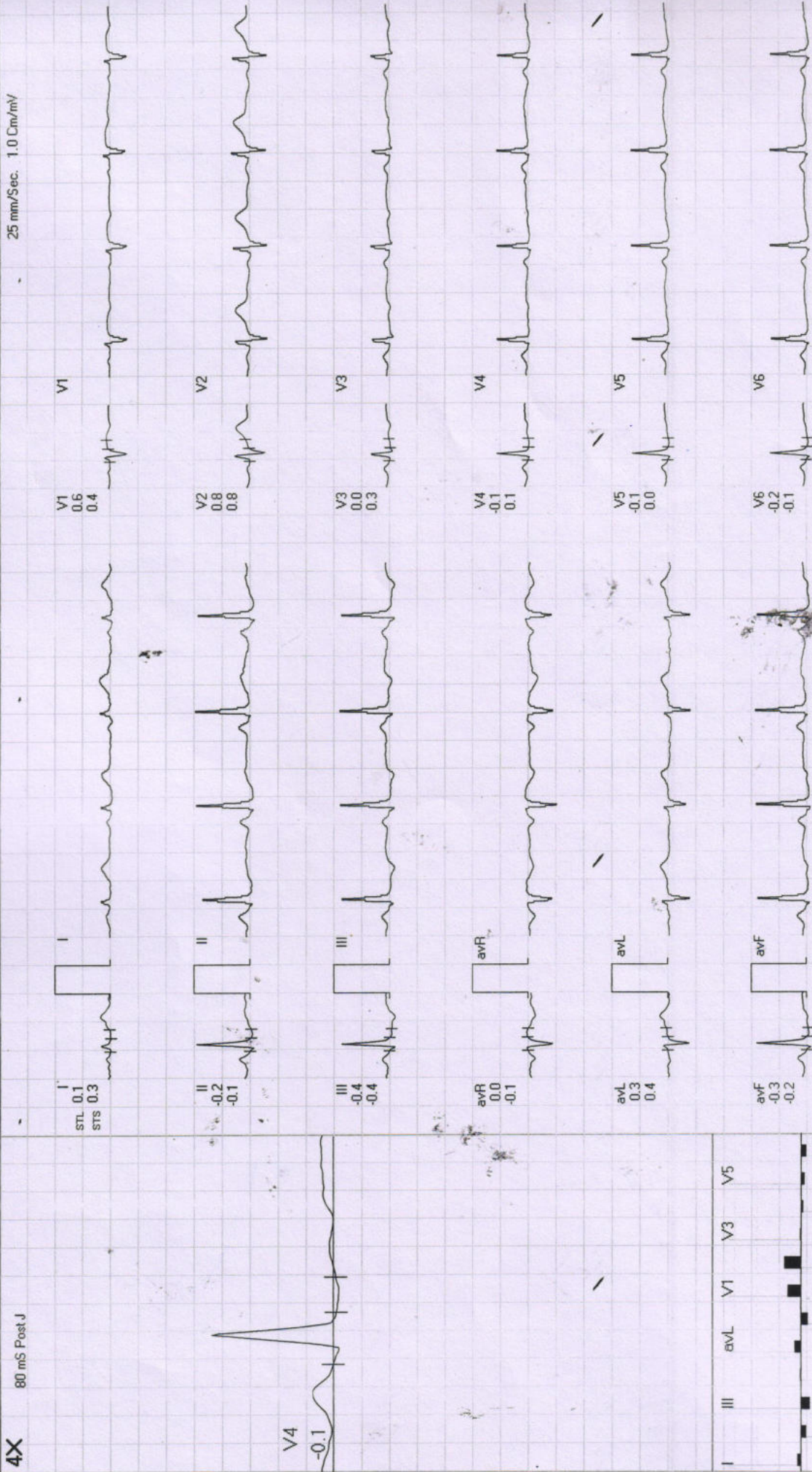
Pathologist





Date: 10-Dec-2022 11:09:17 AM METS: 1.0/78 bpm 42% of THR BP: 116/78 mmHg R<sub>aw</sub> ECG/BLC On/ Notch On/ HF 0.05 Hz/LF 20 Hz

ExTime: 00:57 1.0 mph, 0.0%  
25 mm/Sec. 1.0 Cm/mV



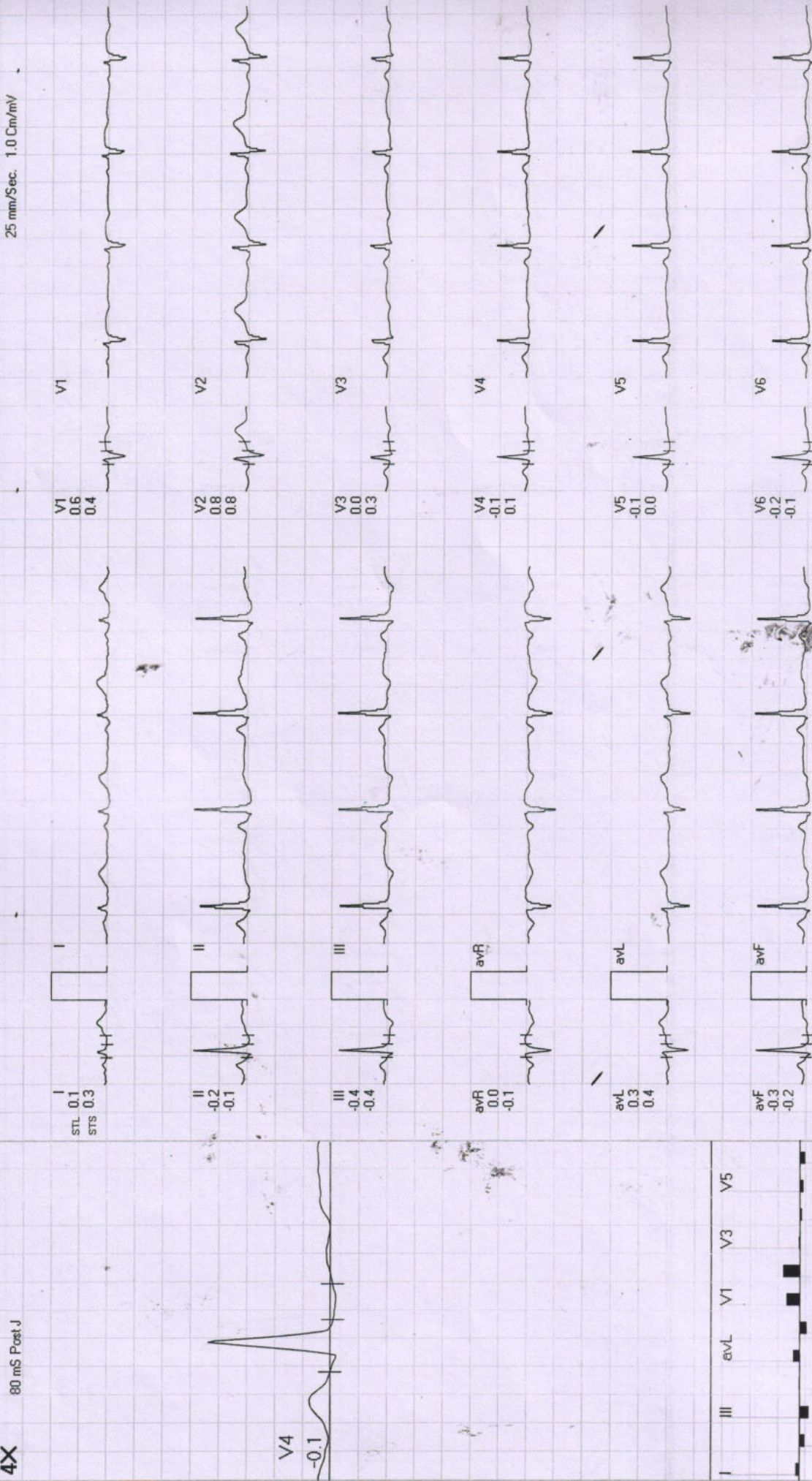
REMARKS:



Date: 10-Dec-2022 11:09:17 AM METS: 1.0/78 bpm 42% of THR BP: 116/78 mmHg Raw ECG/BLC On/ Notch On/ HF 0.05 Hz/LF 20 Hz

ExTime: 00:00 0.0 mph 0.0%

4X 80 mS Post J



REMARKS:

PTO

nonrelatv clinic beavda

Right Kidney is normal in size, shape and position. Corticomedullary differentiation (CMD) is well maintained. Normal cortical thickness is noted. No E/O hydronephrosis or calculus is noted.

Pancreas appear normal in size, shape and echo texture with smooth contour. No peripancreatic pathology seen. (Not seen due to gases) Spleen is normal / enlarged in size and normal in echo texture. IVC and aorta appear to be normal. No evidence of lymphadenopathy is noted. No evidence of free fluid is noted.

Liver appears normal / enlarged in size and shape with smooth in outline. Normal / increased parenchymal echogenicity is noted. No E/O focal lesion / IHBR dilatation is seen. Hepatic veins and portal veins appear normal. No E/O Subdiaphragmatic Collection.

Gall Bladder is physiologically well distended / collapsed. No E/O echogenic foci in GB lumen. GB wall is normal / thickened. No E/O pericholecystic collection. common duct reveals normal course and caliber.

### WHOLE ABDOMEN ULTRASOUND REPORT

Indication :

Name : Mrs. Pallavi Invele 38/F  
R/B Health check-up  
Date 10/12/2022  
Age YRS/IF

**डॉ. सविता रिडियोलॉजिक**  
34, भूतल, मोहिनी आर्टि आकड, शाहपुरा मस्जिद के पास  
भरत नगर रोड, ई-7/194, अररा कॉलोनी, भोपाल - 462038  
Mob : 8989649694, 9516333619  
Clinic Registration : CL/5392/Jun/2017  
PNDT Registration : MP/CPNDT/BPL/2017/206



Left Kidney is normal in size, shape and position. CMD is well maintained. Normal cortical thickness is noted. No E/O hydronephrosis or calculus is noted.

Urinary Bladder is well distended (physiological) / collapsed. Its contents are echo free. No E/O bladder wall thickening is noted. Post-void residue is insignificant.

Prostate is normal in size, shape and echo texture with smooth outline. No E/O focal lesion is noted.

Uterus is ante/retro verted and normal in size, shape and echotexture with smooth outline. No E/O focal lesion is noted, endometrial echo appear normal. Cervical and vaginal shadows appear normal.

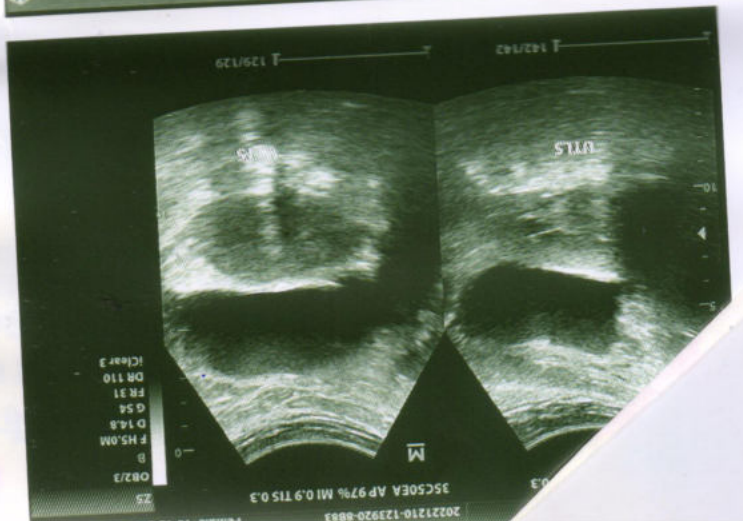
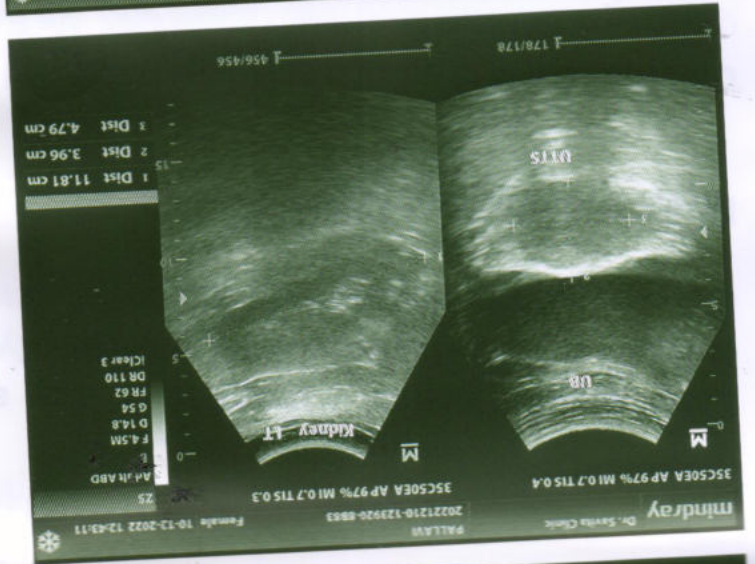
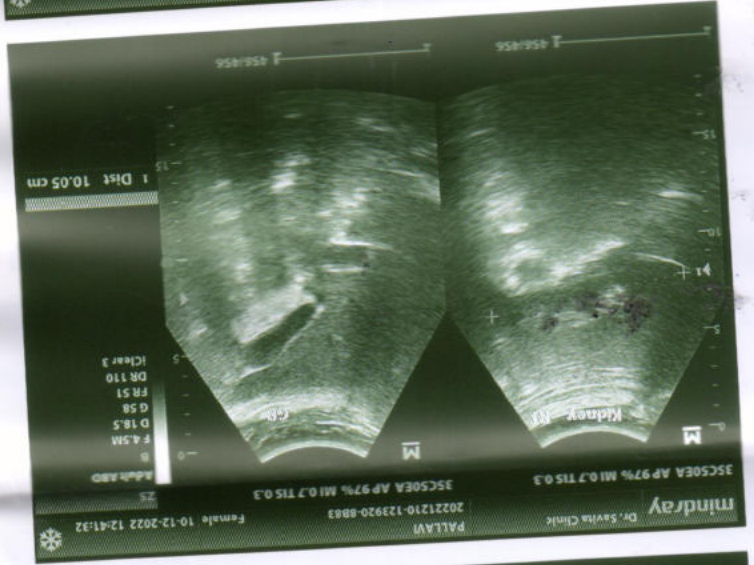
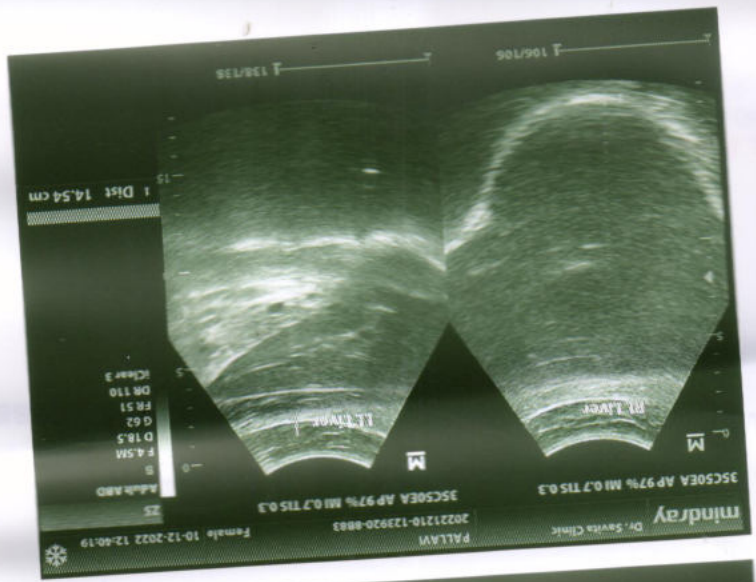
Right Ovary appears Enlarged / Normal in size, shape and echo texture.

Left Ovary appears Enlarged / Normal in size, shape and echo texture.

Impression : Normal study.

Advised clinical Correlation.

5 Oct



**SOUND REPORT**

kidney shape with smooth in outline. No E/O focal lesion / IHBR appear normal.

collapsed. No E/O echogenic foci in pericholecystic collection. common

texture with smooth (seen due to gases) echo texture.

Corticomedullary differentiation is noted. No E/O hydronephrosis

PTO

**Dr. Jayant Yadav, MD**  
MBBS, MD (Radiologist) Reg. No. 4166  
रिडियोलॉजिस्ट

**दत्तानन्द**  
शाहपुरा मस्जिद के पास  
लॉजी, भोपाल - 462038  
9516333619  
392/Jun/2017  
DT/BPL/2017/206



Age.....YRS./F  
Date.....10/12/2022



Pt Name :- Mrs. Pallavi Trivedi  
 Age :- 38/F  
 Lab. No. :- 03  
 Date :- 10/12/2022

### EXAMINATION OF BLOOD

TEST	RESULT	NORMAL VALUE
Haemoglobin	12.7gms%	Female 12-16gms%, Male 14-18gms%
Red Cell count	4.53	4.5-5.6 million /cumm
Platelet Count	3.17	1.5-5.6 Lac/cumm
Leucocytes per.cu.mm	7500/cumm	5000-11000/cumm
Neutrophils	65%	50-70%
Lymphocytes	28%	20-40%
Eosinophils	03%	0-7%
Monocytes	04%	2-8%
PCV	38.0	37-47
MCV	83.9	76-96
MCH	28.0	27-32
MCHC	33.4	31-35
ESR	14	Male 0-9, Female 0-20mm/FHR
Blood Group	"B" Positive	By slide method
Total Serum Cholesterol	155.0	100-250 mg%
Serum Triglyceride	125.0	Up to 150 mg%
Serum Cholesterol HDL	45.0	Up to 65 mg%
Serum Cholesterol LDL	85.0	Up to 125 mg%
LDL	25.0	Up to 30 mg%
S.Bilirubin(Total)	0.80	0.2-1.0mg/dl
Direct	0.40	0.0-0.25mg/dl
Indirect	0.40	
SGOT	19.0	5-35U/L
SGPT	21.0	8-40U/L
Alk Phosphatase	9.5	3-13 KA units
S. Protein(Total)	6.0	6.0-8.0mg%
Albumin	4.0	3.7-5.3mg%
Globulin	2.0	1.5 to 3.5 mg%
Blood Urea	21.9	Up to 40 mg%
S.Creatine	0.85	0.5-1.4mg/dl
S. Uric Acid	6.0	3.5-7.5mg%
GTP	22.0	5-35 UL/dl
Fasting Blood Sugar	89.2	Up to 110 mg%
PP Blood Sugar	109.0	Up to 125 mg%
Glycosylated Hemoglobin	5.1	Below - 6.0 % -Non Diabetic control 6-7 % -Excellent control Above- 8 % -Poor control
Thyrod Stimulating Hormone(TSH)	4.01	0.27-4.2

All test have technical limitation. Collaborative clinic pathological interpretation is mandatory. In case of disparity test may be repeated immediately. Typographical mistakes should be get correct instantly. This report is not valid for medico legal purpose



Dr. B. M. Agarwal  
 MBBS, DCP  
 Consultant Pathologist



Pt Name :- Mrs. Pallavi Trivedi  
 Age :- 38/F  
 Lab. No. :- 03  
 Date :- 10/12/2022

## URINE ANALYSIS

A. PHYSICAL EXAMINATION	
1. Colour	Pale Yellow
2. Appearance	Clear
3. Specific Gravity	Q.N.S.
B. CHEMICAL EXAMINATION	
1. Reaction	Acidic
2. Albumin	Nil
3. Sugar	Nil
4. Bile Salts	Absent
C. MICROSCOPIC EXAMINATION	
Pus Cells	1-2/HPF
R.B.C.	Nil
Epithelial Cell	occ
Cast	Nil
Crystals(Cal.Oxa)	Nil
Bacteria	Nil
Amorphous	Nil
T. Vaginitis	Nil

Pathologist

Dr. B. M. Agarwal  
 MBBS, DCP  
 Consultant Pathologist

