


Name : Mr. Raj Kishor Sharma	Age : 41 Y	UHID :CJPN.0000088652
Address : BLR	Sex : M	
Plan : ARCOFEMI MEDIWHEEL MALE AHC CREDIT PAN INDIA OP AGREEMENT		OP Number :CJPNOPV178999
		Bill No :CJPN-OCR-66666
		Date : 14.10.2023 08:33

Sno	Service Type/Service Name	Department
1	ARCOFEMI - MEDIWHEEL - FULL BODY ANNUAL PLUS ABOVE 50Y MALE - 2D ECHO - PAN INDIA - FY2324	
1	URINE GLUCOSE (FASTING)	
2	GAMMA GLUTAMYL TRANSFERASE (GGT)	
3	PROSTATIC SPECIFIC ANTIGEN (PSA TOTAL)	
4	HbA1c, GLYCATED HEMOGLOBIN	
5	2D ECHO	
6	LIVER FUNCTION TEST (LFT)	
7	X-RAY CHEST PA	
8	GLUCOSE, FASTING	
9	HEMOGRAM - PERIPHERAL SMEAR	
10	ENT CONSULTATION	
11	FITNESS BY GENERAL PHYSICIAN	
12	DIET CONSULTATION	
13	COMPLETE URINE EXAMINATION	
14	URINE GLUCOSE (POST PRANDIAL)	
15	PERIPHERAL SMEAR	
16	ECG	
17	BLOOD GROUP ABO AND RH FACTOR	
18	LIPID PROFILE	
19	BODY MASS INDEX (BMI)	
20	OPHTHAL BY GENERAL PHYSICIAN - 3	
21	RENAL PROFILE/RENAL FUNCTION TEST (RFT/KFT)	
22	ULTRASOUND - WHOLE ABDOMEN	
23	THYROID PROFILE (TOTAL T3, TOTAL T4, TSH)	
24	DENTAL CONSULTATION - 22	
25	GLUCOSE, POST PRANDIAL (PP), 2 HOURS (POST MEAL)	

Archie

Dental - 22
Ophthal - 03

weight = 80.0 kg
Height = 166 cm
waist = 97 cm
HIP = 102 cm
BP = 105/74 mmHg
PR = 66 bpm

9964508500

NAME: Mr. RAJ KISHOR S AGE: 41YRS/ M DATE: 14/10/2023 CJPN :88652

2D ECHO WITH COLOR DOPPLER

Ao Diam : 3.5 cm , LA Diam : 4.0 cm,
IVSd :0.9cm , IVSs 1.3 cm, LVIDd : 4.2 cm , LVIDs : 2.5 cm LVPWd :0.9 cm ,
LVPWS : 1.3 cm , EF – 65% , FS – 38% , RVIDd – 2.0cm

2D VALVES

MITRAL VALVE-----: NORMAL
TRICUSPID VALVE-----: NORMAL
AORTIC VALVE-----: NORMAL
PULMONARY VALVE-----: NORMAL

CHAMBERS

LEFT ATRIUM-----: NORMAL.
RIGHT ATRIUM-----: NORMAL
LEFT VENTRICULAR-----: NORMAL
RIGHT VENTRICULAR---:NORMAL

DOPPLER

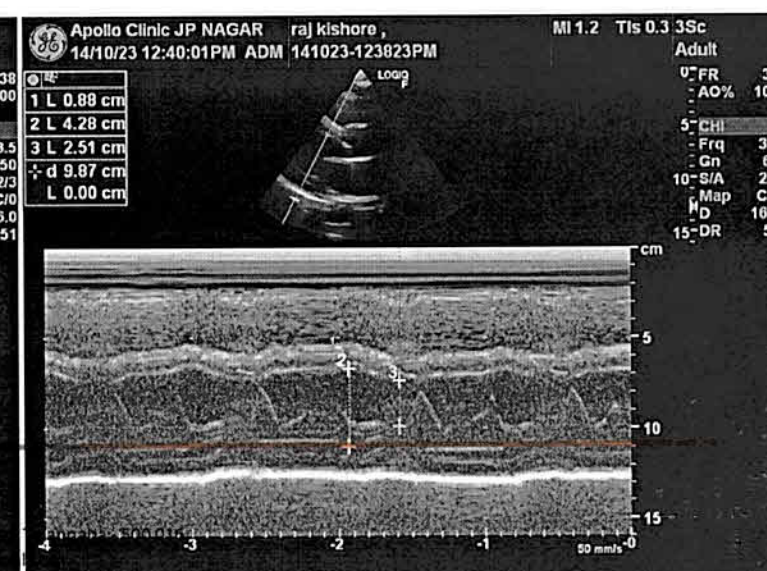
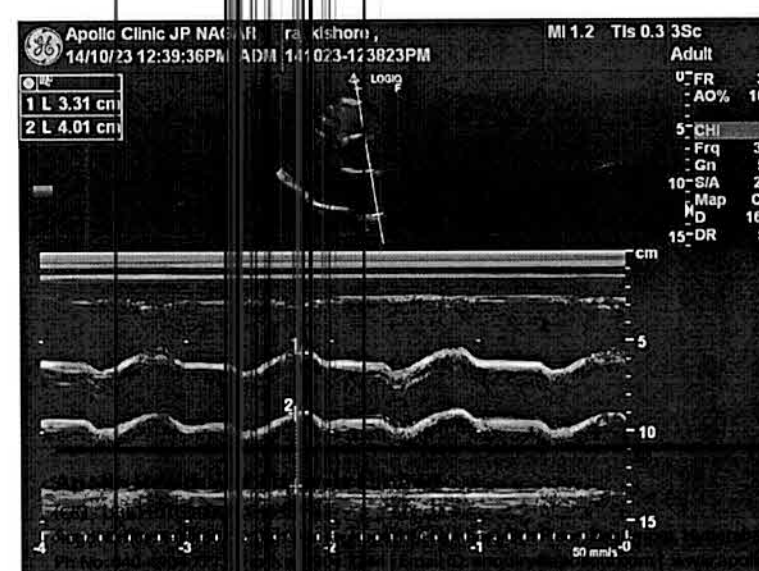
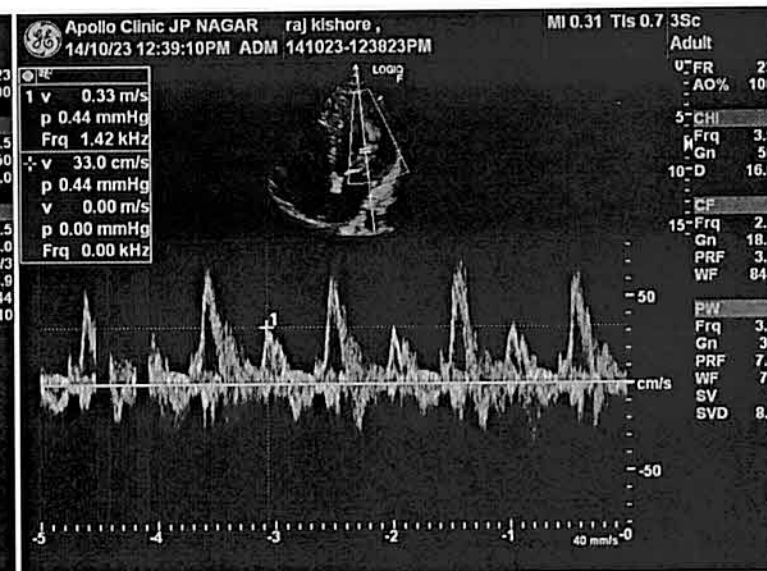
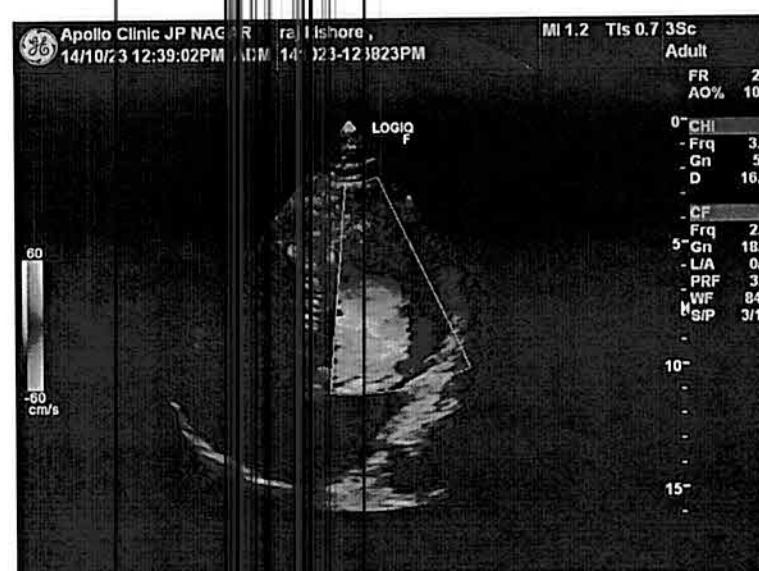
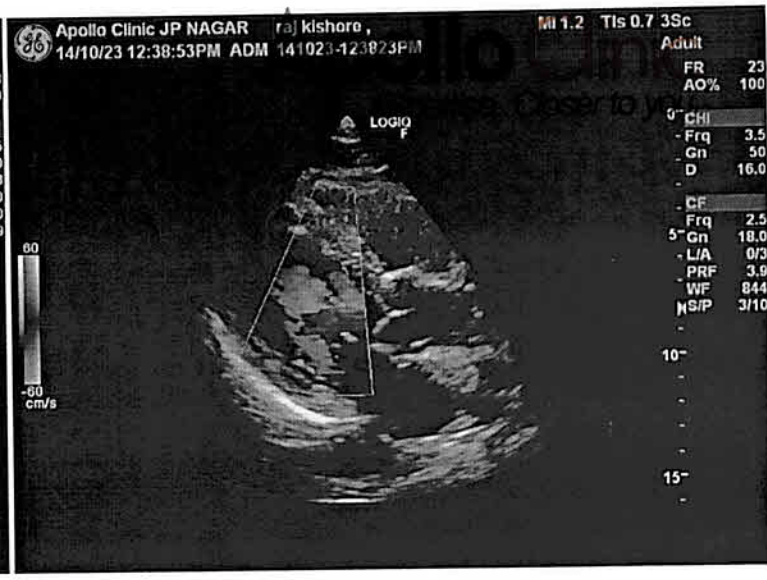
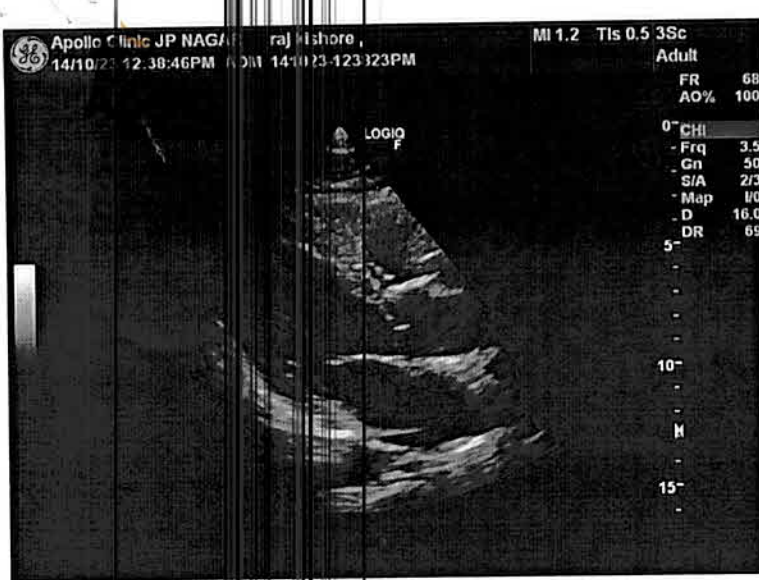
MV E Vel--- : 0.6 m/s , MV A Vel : 0.4 m/s
TRICUSPID VALVE : NORMAL
PERICARDIUM-----: NORMAL
CLOT/VEGETATION----- : NIL

IMPRESSION

NORMAL VALVES AND CHAMBERS
NORMAL LV SYSTOLIC FUNCTION
NO CLOT /VEGETATION/EFFUSION/PAH
NO REGIONAL WALL MOTION ABNORMALITIES



DR. NAGARAJA MOORTHY, MD,DM
CONSULTANT CARDIOLOGIST

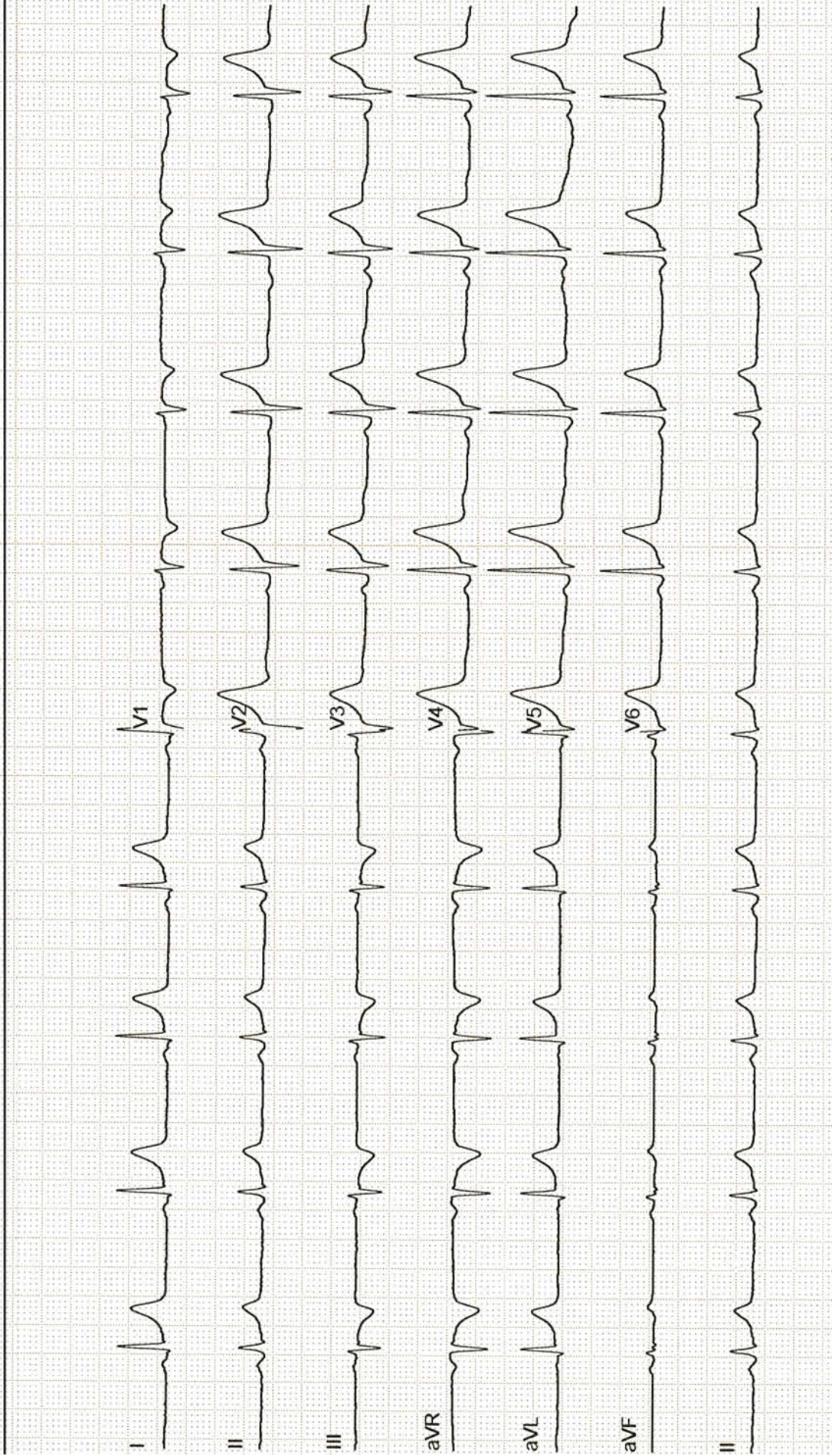


166 cm Male
80.0 kg

QRS : 82 ms
 QT / QTcBaz : 398 / 380 ms
 PR : 154 ms
 P : 110 ms
 RR / PP : 1082 / 1090 ms
 P / QRS / T : 53 / 4 / 6 degrees

Sinus bradycardia
 ST elevation, consider early repolarization, pericarditis, or injury
 Abnormal ECG

W.K.

Patient Name : Mr. Raj Kishor Sharma

Age/Gender : 41 Y/M

UHID/MR No. : CJPN.0000088652

OP Visit No : CJPNOPV178999

Sample Collected on :

Reported on : 14-10-2023 10:48

LRN# : RAD2125119

Specimen :

Ref Doctor : SELF

Emp/Auth/TPA ID : 9964508500

DEPARTMENT OF RADIOLOGY

ULTRASOUND - WHOLE ABDOMEN

LIVER : Normal in size and echotexture. No focal lesion seen.

No intra hepatic biliary / venous radicular dilation.

CBD and Main Portal vein appear normal.PV-10 mm.

GALL BLADDER : **Well distended. Multiple stones seen (around 4 to 5) measuring~7mm.. Wall Thickness is normal.**

SPLEEN : Normal in size and echotexture. No focal lesion was seen.

PANCREAS : Appeared normal to the visualized extent.

KIDNEYS : Both kidneys are normal in size, shape and outlines Cortico medullary delineation is maintained. No Hydronephrosis / No calculi.

Right kidney measures: 10.4 x 1.4 cm.

Left kidney measures :12.7 x 2.1 cm.

URINARY BLADDER : Well distended. Normal in internal contents. Wall thickness is normal.

PROSTATE: Normal in size and echotexture.

Prostate measures : 3.6 x 3.2 x 3.7cms. Volume-27 cc.

No free fluid is seen in the peritoneum. No lymphadenopathy.

IMPRESSION : MULTIPLE GALL STONES.

Rest of the abdomen is normal.

Please Note :No preparation done before scanning.



Patient Name : Mr. Raj Kishor Sharma

Age/Gender : 41 Y/M

(The sonography findings should always be considered in correlation with the clinical and other investigation finding where applicable.) It is only a professional opinion, Not valid for medico legal purpose.

Dr. KUSUMA JAYARAM
MBBS,DMRD
Radiology

DL No. : KA51 20230008523
NAME : RAJ KISHOR SHARMA
D.O.B : 26/06/1982
VALID TILL : 31/07/2033(NT)

DOI : 01/08/2023
B.G. :

FORM - T
[See Rule 16(2)]

VALID THROUGHOUT INDIA
COV : LMV 01/08/2023
: MCWG 01/08/2023

CDDI : 01 Aug 23



S/o : RAM UDAY SHARMA
ADDRESS : Flat - B - 1, Pushpagiri Residency, Jyothi Nagar,
Bohra Layout Near Vijaysahree Hospl
Bangalore South Bengaluru Karnataka 560083

Sign. Of Holder

Sign. Licencing Authority
ECITY-BANGALORE

14/10/2023	08:00-08:05	ARCOFEMI MEDIWHEEL MALE AHC CREDIT PAN INDIA OP AGREEMENT & ARCOFEMI - MEDIWHEEL - FULL BODY ANNUAL PLUS ABOVE 50Y MALE - 2D ECHO - PAN INDIA - FY2324	Raj Kishor Sharma
------------	-------------	--	-------------------

Name
Age/Gender

: Miss, MEGHANA



Patient Name : Mr. Raj Kishor Sharma

Age/Gender : 41 Y/M

UHID/MR No. : CJPN.0000088652

OP Visit No : CJPNOPV178999

Sample Collected on :

Reported on : 14-10-2023 10:00

LRN# : RAD2125119

Specimen :

Ref Doctor : SELF

Emp/Auth/TPA ID : 9964508500

DEPARTMENT OF RADIOLOGY

X-RAY CHEST PA

Both lung fields and hila are normal .

No obvious active pleuro-parenchymal lesion seen .

Both costophrenic and cardiophrenic angles are clear .

Both diaphragms are normal in position and contour .

Thoracic wall and soft tissues appear normal.

CONCLUSION :

No obvious abnormality seen.

Dr. KUSUMA JAYARAM

MBBS,DMRD

Radiology