

Name : Mr. S SHAILESHA

Age: 44 Y

UHID:CKOR.0000248322

Sex: M



Address : kml

Plan : ARCOFEMI MEDIWHEEL MALE AHC CREDIT PAN
INDIA OP AGREEMENT

OP Number:CKOROPV389802

Bill No :CKOR-OCR-79264

Date : 30.11.2023 10:22

Sno	Serive Type/ServiceName	Department
1	ARCOFEMI - MEDIWHEEL - FULL BODY ANNUAL PLUS ABOVE 50Y MALE - 2D ECHO - PAN INDIA - FY2324	
✓1	URINE GLUCOSE(FASTING)	
✓2	GAMMA GLUTAMYL TRANFERASE (GGT)	
✓3	PROSTATIC SPECIFIC ANTIGEN (PSA TOTAL)	
✓4	HbA1c, GLYCATED HEMOGLOBIN	
✓5	2D ECHO R10	
✓6	LIVER FUNCTION TEST (LFT)	
✓7	X-RAY CHEST PA R11	
✓8	GLUCOSE, FASTING R12	
✓9	HEMOGRAM + PERIPHERAL SMEAR	
✓10	ENT CONSULTATION	
11	FITNESS BY GENERAL PHYSICIAN	
12	DIET CONSULTATION	
✓13	COMPLETE URINE EXAMINATION	
✓14	URINE GLUCOSE(POST PRANDIAL)	
✓15	PERIPHERAL SMEAR	
✓16	ECC R-14	
✓17	BLOOD GROUP ABO AND RH FACTOR	
✓18	LIPID PROFILE	
19	BODY MASS INDEX (BMI)	
✓20	OPHTHAL BY GENERAL PHYSICIAN R20	
✓21	RENAL PROFILE/RENAL FUNCTION TEST (RFT/KFT)	
✓22	ULTRASOUND - WHOLE ABDOMEN R17	
✓23	THYROID PROFILE (TOTAL T3, TOTAL T4, TSH)	
✓24	DENTAL CONSULTATION R-15	
✓25	GLUCOSE, POST PRANDIAL (PP), 2 HOURS (POST MEAL)	

(15) Dental

(29) Physio

Wt - 62.8kg

Ht - 162cm

Pulse - 109/m

Bp - 120/79mmHg

Patient Name	: Mr. S SHAILESHA	Age	: 44 Y M
UHID	: CKOR.0000248322	OP Visit No	: CKOROPV389802
Reported on	: 30-11-2023 11:35	Printed on	: 30-11-2023 13:56
Adm/Consult Doctor	:	Ref Doctor	: SELF

DEPARTMENT OF RADIOLOGY

X-RAY CHEST PA

Both lungs fields appear normal.

Both hila are normal.

Both costophrenic and cardiophrenic angles are normal.

The cardiac and mediastinal shadows appear normal.

Bones and soft tissues appear normal.

IMPRESSION : NORMAL STUDY.


DR VINOD JOSEPH DNB,DMRD
RADIOLOGIST

Printed on:30-11-2023 11:35

---End of the Report---

NAME: MR. S SHAILESHA

AGE: 44Y

SEX: MALE

DATE: 30/11/2023

ECHOCARDIOGRAPHY REPORT

MEASUREMENT

AO -25(20 – 35)mm	LIVD d – 38(36-52)mm	IVS - 10 (06 - 11)mm
LA -28(19- 40)mm	LVID s – 25(23- 39)mm	PWD – 11(06- 11)mm
EF - 60% (>50%)	RVID-22	

VALVES

Mitral Valve : Normal
Aortic Valve : Normal
Tricuspid Valve : Normal
Pulmonary Valve : Normal

CHAMBERS

Left Atrium : Normal
Right Atrium : Normal
Left Ventricle : Normal
Right Ventricle : Normal

SEPTAE

IVS : Intact
IAS : Intact

GREAT ARTERIES

Aorta : Normal
Pulmonary Artery : Normal

DOPPLER DATA

Mitral : E < A
Aortic : Normal
Tricuspid : Normal
Pulmonary : Normal

WALL MOTION ABNORMALITIES : No RWMA

Pericardium : Normal

FINAL DIAGNOSIS

**NORMAL CHAMBERS AND VALVES
NORMAL BIVENTRICULAR FUNCTION
NO RWMA AT REST, LV EF -60%
GRADE I DIASTOLIC DYSFUNCTION**



**DR. MOHAN MURALI
CONSULTANT
CARDIOLOGIST**

Apollo Clinic

Consent Form

Patient Name: *Shivkumar D.S* Age: *44*

UHID Number: Company Name:

I Mr/Mrs/Miss: Employee of *DOB*

(Company) want to inform you that I am not getting the.....

Test which is a part of health check package.

Reason If any: *Not advised for mutation*

And I claim the above statement in my full consciousness.

Patient Signature: *[Signature]* Date: *20/11/23*

DR VIJAYA LAKSHMI M
M.B.B.S, D.L.O, D.N.B(ENT)
Phone No.9972044580,080-25633823/24/23

30/11/23

HEALTH CHECK- ENT

NAME: *Shalish D.S P*

AGE: *44*

EAR:

RE:

LE:

EXTERNAL EAR

MIDDLE EAR

INNER EAR (FN)

Normal

HEARING ASSESSMENT:

RE:

LE:

RHINNE

WEBER

ABC

Normal

NOSE

THROAT

AIRWAY

ORAL CAVITY

SEPTUM

OROPHARYNX

TURBINATES

PHARYNX

OTHERS

LARYNX

Normal

Normal

NECK

NECK NODES

OTHER

Normal

AUDIOMETRY

IMPRESSION

Normal

[Signature]
SIGNATURE:

DR. MAHABALESHWAR.M
MBBS.(MYS), MD(AIIMS DELHI)FICS
D.O (JIPMER)
REG.NO:KMC:9748

DATE: 30.11.25
OP NO:

THE APOLLO MEDICAL CENTER KORAMANGALA

NAME: Shankarha
AGE : 24
GENDER: M

OPHTHALMIC REPORT

RIGHT EYE

LEFT EYE

GENERAL APPEARANCE

VISION - DISTANCE

WITHOUT GLASS

WITH GLASS

GLASS POWER

6/6 | 6/6

NEAR

WITHOUT GLASS

WITH GLASS

GLASS POWER

no

no

COLOUR

ANTERIOR SEGMENT:-

FUNDUS 5:10

I.O.P: DIGITAL

no men
Brus +1


DOCTOR SIGNATURE

Male

MR S SHAIKESHAI

0000248322

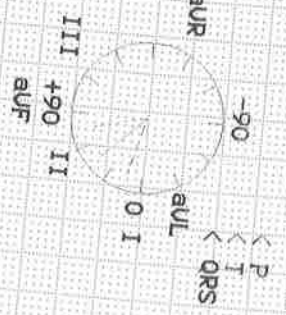
APOLLO MEDICAL CENTRE, KORAMANGALA

Arrow CE

AGE: 44

Measurement Results

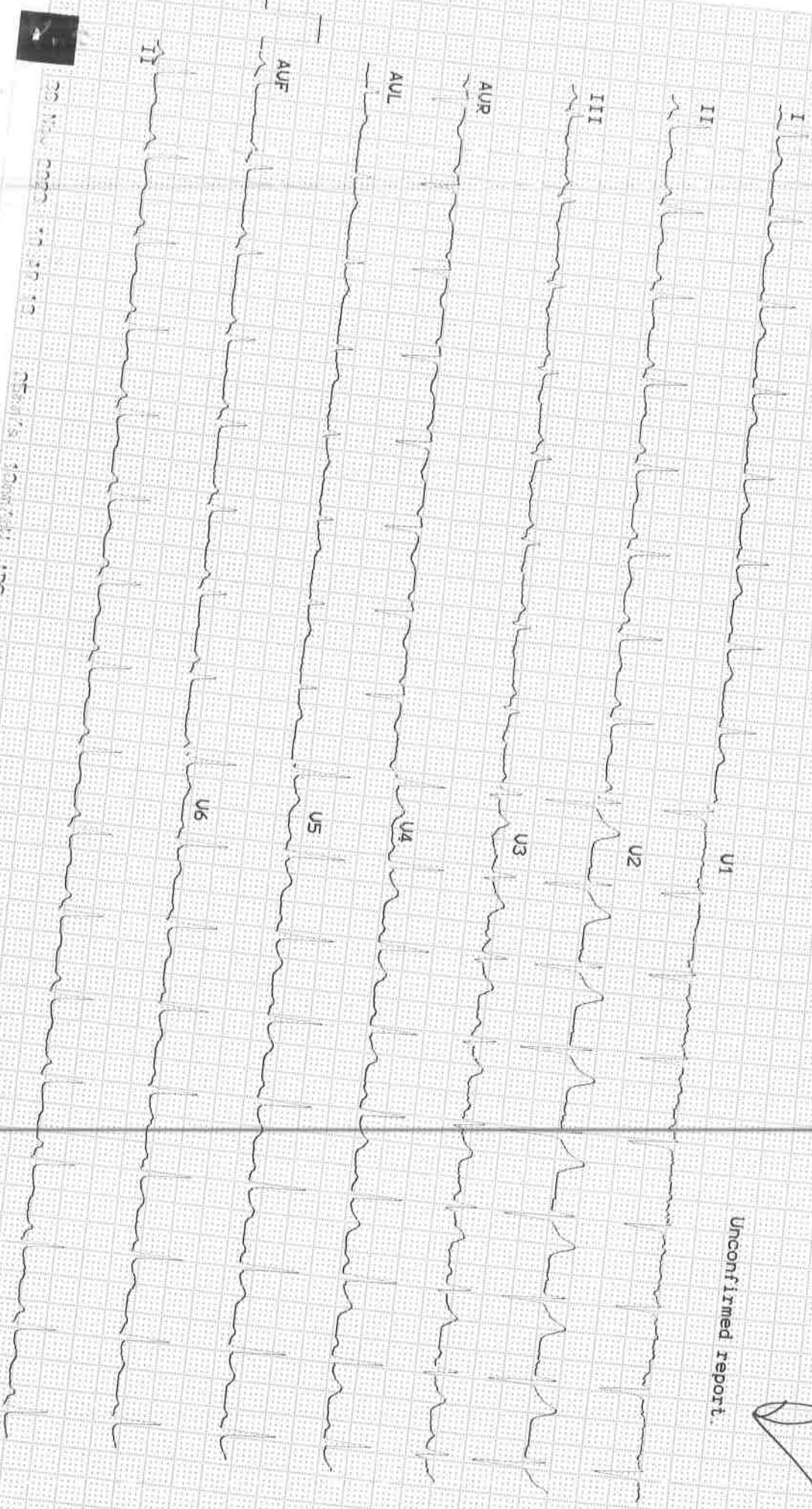
QT/QTcF	332 / 429 ms	84 ms
PR	128 ms	
P	90 ms	
RR/PP	598 / 590 ms	
P/ORS/T	75 / 45 / 15 degrees	
QTd/QTcBd	82 / 106 ms	
Sokolow	1.7 mV	
NK	15	



Interpretation:

HR 100 bpm

Unconfirmed report.



30 NEW 2023 11 10 13

NT/ST/TS 10mm/10mm 400 50mm/s 2.00 20mm

Patient Name	: Mr. S SHAILESHA	Age	: 44 Y/M
UHID	: CKOR.0000248322	OP Visit No	: CKOROPV389802
Reported By:	: Dr. RAJENDRA NARAYAN SHARMA	Conducted Date	: 30-11-2023 15:49
Referred By	: SELF		

ECG REPORT

Observation :-

1. Normal Sinus Rhythm.
2. Heart rate is 100beats per minutes.
3. No pathological Q wave or S-T,T changes seen.
4. Normal P,Q,R,S,T waves and axis.
5. No evidence of chamber, hypertrophy or enlargement seen

Impression:

NORMAL RESTING ECG.

Dr. RAJENDRA NARAYAN SHARMA
CONSULTANT

NOTE : KINDLY TAKE A PHOTOCOPY OF THE GRAPH
FOR FUTURE REFERENCE IF NEEDED.

----- END OF THE REPORT -----

Patient Name : Mr S Shailesha

Patient ID:248322

Age : 44Year(s)

Sex : Male

Referring Doctor : H/C

Date : 30.11.2023

ULTRASOUND ABDOMEN AND PELVIS

FINDINGS:

Liver is normal in size and shows increased echotexture. No biliary dilatation. No focal lesion
CBD is not dilated. **Portal vein** is normal in size, course and calibre.

Gall bladder is normal without evidence of calculi, wall thickening or pericholecystic fluid.

Pancreas to the extent visualized, appears normal in size, contour and echogenicity

Spleen is normal in size, shape, contour and echopattern. No evidence of mass or focal lesions.

Right Kidney is normal in size, position, shape and echopattern. Corticomedullary differentiation is maintained. No evidence of calculi or hydronephrosis.

Left Kidney is normal in size, position, shape and echopattern. Corticomedullary differentiation is maintained. No evidence of calculi or hydronephrosis.

Urinary Bladder is well distended. Wall thickness is normal. No evidence of calculi, mass or mural lesion.

Prostate: normal in size and echotexture. There is no ascites.

IMPRESSION: GRADE-I FATTY LIVER

**DR VINOD JOSEPH DNB,DMRD
RADIOLOGIST**