



# Shubham Imaging & ALC Diagnostic Center

ISO 9001:2015 Certified Center

(A Unit of P. K. Arogyam Health & Wellness Center)

E-95, P.C. Colony, Near Sai Netryalaya Transformer, Kankarbagh, Patna - 20

✉ : alcdiagnostics@gmail.com



www.pkarogyamhealthcheckup.com



7050037694, 9153988577

OPINION MUST BE CORRELATES WITH CLINICALLY & OTHER INVESTIGATION FOR FINAL DIAGNOSIS. NOT FOR MEDICO LEGAL PURPOSE

Pt. Name :- PRABHAKAR KUMAR

Date:- 16-Sep-24

Ref. By :- DR / MEDIWHEEL

Age / Sex - 32 Yrs. M.

## REAL TIME U.S.G. OF WHOLE ABDOMEN

Thanks for your kind referral

( Report.)

**LIVER** :- Measures 14.51 cm. Mild Enlarged in shape , size and echo texture fatty change seen in liver parenchyma .J.H.B.R. are not dilated. Hepatic veins are normal.  
No SOL seen.

G.BL. :- Lumen is echo free. Wall thickness appears normal.

C.B.D. :- Measures 3.3 mm in diameter with echo free lumen. No calculi or mass seen.

P.V. :- Measures 7.5 mm in diameter. Appears normal. No thrombus seen.

PANCREAS :- Normal in shape, size and echo texture. No calcification mass seen.

SPLEEN :- Measures 11.84 cm. Normal in shape, size and echo texture.  
No SOL seen.

KIDNEY :- Both kidney shows normal shape, size & echo texture. C.M.D.intact.  
P.C.S.is not dilated. No calculi, cyst or hydronephrosis seen on either side  
**Right Kidney :- Measures 9.50 X 3.50 cm.**  
**Left Kidney :- Measures 9.60 X 3.50 cm.**

URETER :- Not dilated .No apparent calculi seen.

U.BLADDER:- Shows normal in outline with echo free lumen. No calculi or mass seen.  
**Pre void - 310 ml. Post void - is in significant**

PROSTATE :- Normal in size, shape, and echo texture . No calcification , mass ,growth seen.  
capsule is intact.

R.I.F. :- Son graphically no appendicular mass or collection seen.

OTHERS :- No Ascites . no Lymph Adenopathy. No pleural effusion seen  
on either side .

## IMPRESSION

- **Mild Hepatomegaly With fatty liver G-I**
- **Adv:- Further work up other investigation**  
**Otherwise son graphically normal scan. of rest organs**

16/9/24

ESTB BY:-

Consultant Radiologist

**Dr. P. K. Tiwari**

MD, M.Sc (Radio Imaging)  
Ph.D (Alt Nuclear Medicine)  
Consultant Imagiologist

**Dr. S. Kumar**

MD, (Pat)  
Consultant Pathologist

**Dr. Abhishek Kumar**

MBBS, MD  
Consultant Neuropathology Physiologist

**Dr. Kumari Suman**

MBBS, DGO, MD  
Consultant (TVS & HSG Specialist)

**Dr. A. K. Singh**

MBBS, PGDMCH  
Consultant Radiologist & Sonologist

PRINTING MISTAKE SHOULD BE REPORTED BACK IMMEDIATELY / यहाँ जन्म से पहले भ्रूण का लिंग जाँच नहीं होता है।



# Shubham Imaging & ALC Diagnostic Center

ISO 9001:2015 Certified Center

(A Unit of P. K. Arogyam Health & Wellness Center)

E-95, P.C. Colony, Near Sai Netryalaya Transformer, Kankarbagh, Patna - 20

✉ : alcdiagnostics@gmail.com

🌐 : www.pkarogayamhealthcheckup.com

☎ : 7050037694, 9153988577

OPINION MUST BE CORRELATES WITH CLINICALLY & OTHER INVESTIGATION FOR FINAL DIAGNOSIS. NOT FOR MEDICO LEGAL PURPOSE

**Pt. Name :- PRABHASAKAR KUMAR**  
**Ref. By :- DR./ MEDIWHEEL**

**Date:- 16-Sep-24**  
**Age / Sex – 32 Yrs. M.**

Thanks for your kind referral

## X-RAYCHEST (P.A.VIEW)

The lungs on the either side show equal translucency.

The peripheral pulmonary vasculature is normal.

No focal lung lesion is seen.

The pleural spaces are normal.

Both hila are normal in size, have equal density and bear normal relationship.

The heart and trachea are central in position and no mediastinal abnormality is visible.

The cardiac size is normal.

The domes of the diaphragms are normal in position, and show smooth outline.

## IMPRESSION

- NO EVIDENCE OF PULMONARY OR CARDIAC PATHOLOGY IS NOTED.

*[Handwritten signature]*  
16/9/24

ESTB BY:-

Consultant Radiologist

**Dr. P. K. Tiwari**

MD, M.Sc (Radio Imaging)  
Ph.D (Alt Nuclear Medicine)  
Consultant Imagiologist

**Dr. S. Kumar**

MD, (Pat)  
Consultant Pathologist

**Dr. Abhishek Kumar**

MBBS, MD  
Consultant Neuropatho Physiologist

**Dr. Kumari Suman**

MBBS, DGO, MD  
Consultant (TVS & HSG Specialist)

**Dr. A. K. Singh**

MBBS, PGDMCH  
Consultant Radiologist & Sonologist

PRINTING MISTAKE SHOULD BE REPORTED BACK IMMEDIATELY / यहाँ जन्म से पहले भ्रुण का लिंग जाँच नहीं होता है।

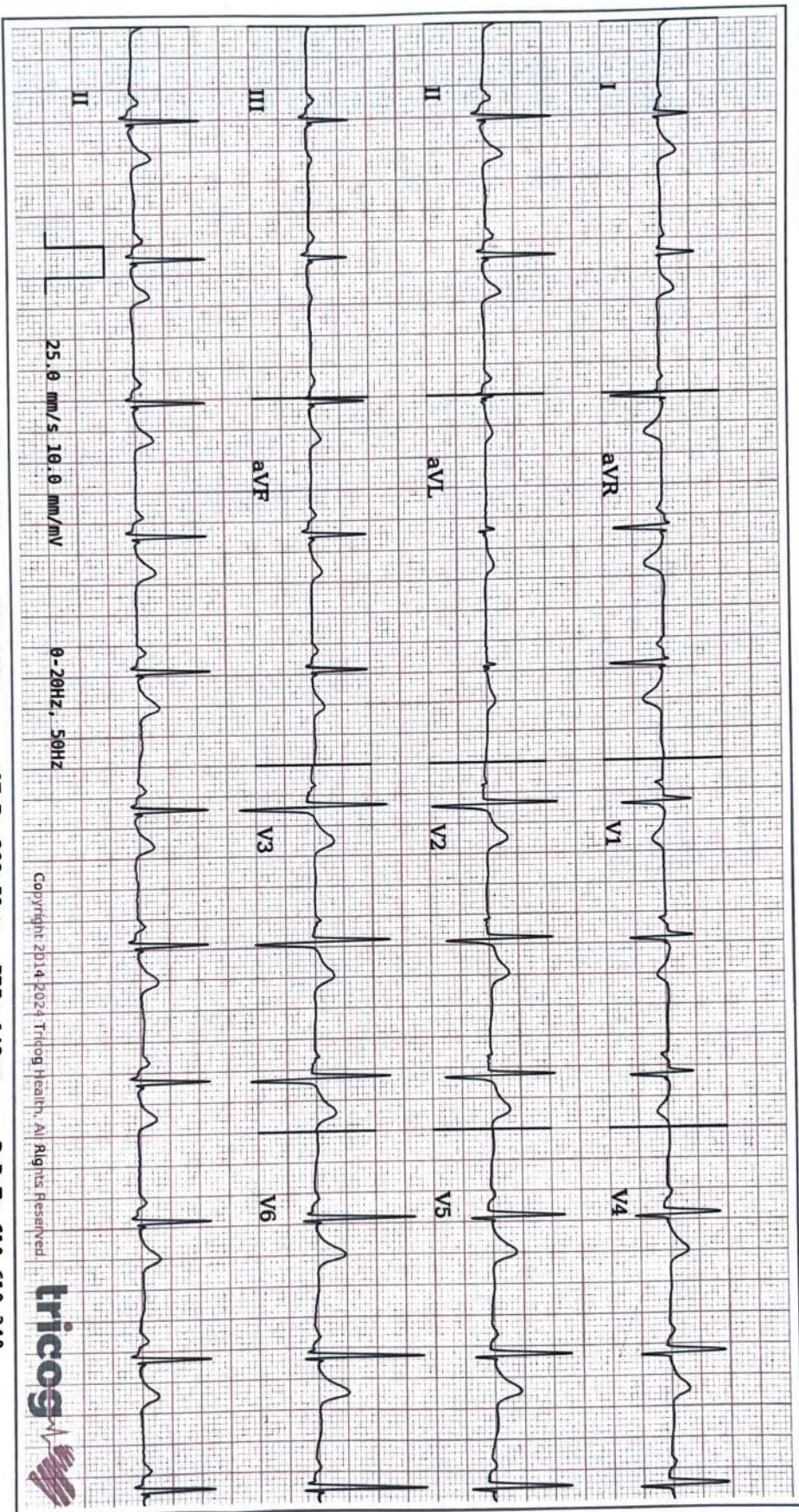




**P. K AROGYAM**

Date and Time: 16th Sep 24 11:29 AM

Age / Gender: 32 / Male  
Patient ID: 1182  
Patient Name: Prabhakar kumar



AR: 67bpm

VR: 67bpm

QRSD: 82ms

QT: 362ms

QTcB: 382.53ms

PRI: 142ms

P-R-T: 61° 61° 34°

Copyright: 2014-2024 Tricog Health, AI Rights Reserved



**ECG Within Normal Limits: Sinus Rhythm. Please correlate clinically.**

Disclaimer: Analysis in this report is based on ECG alone and should be used as an adjunct to clinical history, symptoms, and results of other invasive and non-invasive tests and must be interpreted by a qualified physician. Patient vital signs are as entered by the clinician and not derived from the ECG. This report is generated by an AI algorithm that processes and analyzes over millions of ECGs. However, algorithm interpretations are intended to only aid clinical decision making, and should always be overseen by qualified medical professionals and correlated clinically to arrive at a diagnosis.







# Shubham Imaging & ALC Diagnostic Center

ISO 9001:2015 Certified Center

(A Unit of P. K. Arogyam Health & Wellness Center)

E-95, P.C. Colony, Near Sai Netryalaya Transformer, Kankarbagh, Patna - 20

✉ : [alcdiagnostics@gmail.com](mailto:alcdiagnostics@gmail.com)

🌐 : [www.pkarogayamhealthcheckup.com](http://www.pkarogayamhealthcheckup.com)

☎ : 7050037694, 9153988577

OPINION MUST BE CORRELATES WITH CLINICALLY & OTHER INVESTIGATION FOR FINAL DIAGNOSIS. NOT FOR MEDICO LEGAL PURPOSE

PATIENT NAME : Mr. PRABHAKAR KUMAR

PATIENT ID : 1182

COL DATE : 16/09/2024 REPORTING DATE: 16/09/2024 AGE SEX : 32 YRS/M

REF.BY : DR. / MEDIWHEEL

TEST NAME	RESULT	Unit	REF.RANGE
BLOOD SUGAR ( F )	102.0 mg/dl		70 - 110 mg/dl
<b>LIPID PROFILE:-</b>			
TOTAL CHOLESTROL	166.0 mg/dl		130 -250 mg/dl
TRIGLYCERIDE	125.3 mg/dl		50 -160 mg/dl
HDL CHOLESTROL	41.0 mg/dl		30 - 60 mg/dl
LDL CHOLESTROL	100.0 mg/dl		80 -130 mg/dl
VLDL CHOLESTROL	25.0 mg/dl		15 - 40 mg/dl
T.CH./HDL RATIO	4.0 : 1		Upto 5 : 1
LDL /HDL RATIO	2.4 : 1		2 - 4 : 1

ESTB BY:-

  
Consultant Radiologist

**Dr. P. K. Tiwari**

MD, M.Sc (Radio Imaging)  
Ph.D (Alt Nuclear Medicine)  
Consultant Imagonologist

**Dr. S. Kumar**

MD, (Pat)  
Consultant Pathologist

**Dr. Abhishek Kumar**

MBBS, MD  
Consultant Neuropatho Physiologist

**Dr. Kumari Suman**

MBBS, DGO, MD  
Consultant (TVS & HSG Specialist)

**Dr. A. K. Singh**

MBBS, PGDMCH  
Consultant Radiologist & Sonologist

PRINTING MISTAKE SHOULD BE REPORTED BACK IMMEDIATELY / यहाँ जन्म से पहले भ्रूण का लिंग जाँच नहीं होता है।



# Shubham Imaging & ALC Diagnostic Center

ISO 9001:2015 Certified Center

(A Unit of P. K. Arogyam Health & Wellness Center)

E-95, P.C. Colony, Near Sai Netryalaya Transformer, Kankarbagh, Patna - 20

✉ : alcdiagnostics@gmail.com

🌐 : www.pkarogyamhealthcheckup.com

☎ : 7050037694, 9153988577

OPINION MUST BE CORRELATES WITH CLINICALLY & OTHER INVESTIGATION FOR FINAL DIAGNOSIS. NOT FOR MEDICO LEGAL PURPOSE

PATIENT NAME : Mr. PRABHAKAR KUMAR

PATIENT ID : 1182

COL DATE : 16/09/2024 REPORTING DATE: 16/09/2024 AGE SEX :- 32 YRS/F

REF.BY : DR. / MEDIWHEEL .

TEST NAME	RESULT	Unit	REF.RANGE
<b>LFT:-</b>			
SGPT	83.0	IU/L	5 - 40 IU/L
S G O T	46.0	IU/L	5 - 40 IU/L
ALKALINE PHOSPHATASE	124.3	IU/L	M - 53 - 165 IU/L F - 42 - 136 IU/L.
TOTAL PROTIN	7.1	g/dl	6.0 - 8.7 g/dl
SERUM ALBUMIN	4.3	g/dl	3.5 - 5.4 g/dl
SERIUM GLUBLINE	2.8	g/dl	2.3 - 3.6 g/dl
AG RATIO	1.5: 1		1.0 - 2.3 g/dl
BILIRUBIN			
TOTAL	0.59	mg/dl	0.1 - 1.1 mg/dl
DIRECT	0.22	mg/dl	0.0 - 0.32 mg/dl
INDIRECT	0.37	mg/dl	0.0 - 0.78 mg/dl
GGTP( GGT )	32.1	iu/L	8 - 38 iu/L
<b>KFT/RFT</b>			
URIC ACID	6.9	mg/dl	3.2 - 7.0 mg/dl
SERUM CREATNINE	1.0	mg/dl	0.6 - 1.5 mg/dl
BLOOD URIA	32.1	mg/dl	5 - 45 mg/dl
BLOOD URIA NITROZEN(BUN).	14.9	mg/dl	5 - 23 mg/dl

ESTB BY:-

Consultant Radiologist

**Dr. P. K. Tiwari**

MD, M.Sc (Radio Imaging)  
Ph.D (Alt Nuclear Medicine)  
Consultant Imagonologist

**Dr. S. Kumar**

MD, (Pat)  
Consultant Pathologist

**Dr. Abhishek Kumar**

MBBS, MD  
Consultant Neuropatho Physiologist

**Dr. Kumari Suman**

MBBS, DGO, MD  
Consultant (TVS & HSG Specialist)

**Dr. A. K. Singh**

MBBS, PGDMCH  
Consultant Radiologist & Sonologist

PRINTING MISTAKE SHOULD BE REPORTED BACK IMMEDIATELY / यहाँ जन्म से पहले भ्रूण का लिंग जाँच नहीं होता है।





# Shubham Imaging & ALC Diagnostic Center

ISO 9001:2015 Certified Center

(A Unit of P. K. Arogyam Health & Wellness Center)

E-95, P.C. Colony, Near Sai Netryalaya Transformer, Kankarbagh, Patna - 20

✉ : alcdiagnostics@gmail.com

🌐 : www.pkarogyamhealthcheckup.com

☎ : 7050037694, 9153988577

OPINION MUST BE CORRELATES WITH CLINICALLY & OTHER INVESTIGATION FOR FINAL DIAGNOSIS, NOT FOR MEDICO LEGAL PURPOSE

PATIENT NAME : Mr. PRABHAKAR KUMAR

PATIENT ID : 1182

COL DATE : 16/09/2024 REPORTING DATE: 16/09/2024 AGE SEX:- 32 YRS/F

REF.BY : DR. / MEDIWHEEL .

TEST NAME	RESULT	Unit	REF.RANGE
ESR	10 mm/hr		<20 mm/hr
<b>CBC</b>			
Total W.B.C. Count	4,900 /cumm		4,000 - 11,000 /cumm
R B C COUNT	4.19 Million/ CUmm		4 - 7 Million/ CUmm
Platelets count	1.51 Lakh/ cumm		1.5 - 5.0 Lakh/ cumm
<b>Differential Count of W.B.C.</b>			
Neutrophils	49 %		40 -70%
Lymphocytes	45 %		25 - 40%
Eosinophils	05 %		01 - 05%
Mnonocytes	01 %		00 - 02%
Basophiles	00 %		00 - 0%
HAEMOGLOBIN	12.0 gm/dl ( 82.1 % )		14.6 gm/dl = 100%
PCV	36.7 %		35 - 47 %
MCV	87.7 fl		76 - 96 fl
MCH	29.2 pg		29 - 35 pg
MCHC	33.6 %		30 - 38 %

ESTB BY:-

Consultant Radiologist

**Dr. P. K. Tiwari**

MD, M.Sc (Radio Imaging)  
Ph.D (Alt Nuclear Medicine)  
Consultant Imagonologist

**Dr. S. Kumar**

MD, (Pat)  
Consultant Pathologist

**Dr. Abhishek Kumar**

MBBS, MD  
Consultant Neuropatho Physiologist

**Dr. Kumari Suman**

MBBS, DGO, MD  
Consultant (TVS & HSG Specialist)

**Dr. A. K. Singh**

MBBS, PGDMCH  
Consultant Radiologist & Sonologist

PRINTING MISTAKE SHOULD BE REPORTED BACK IMMEDIATELY / यहाँ जन्म से पहले भ्रुण का लिंग जाँच नहीं होता है।



# Shubham Imaging & ALC Diagnostic Center

ISO 9001:2015 Certified Center

(A Unit of P. K. Arogyam Health & Wellness Center)

E-95, P.C. Colony, Near Sai Netryalaya Transformer, Kankarbagh, Patna - 20

✉ : alcdiagnostics@gmail.com

🌐 : www.pkarogayamhealthcheckup.com

☎ : 7050037694, 9153988577

OPINION MUST BE CORRELATES WITH CLINICALLY & OTHER INVESTIGATION FOR FINAL DIAGNOSIS. NOT FOR MEDICO LEGAL PURPOSE

PATIENT NAME : Mr. PRABHAKAR KUMAR

PATIENT ID : 1182

COL DATE : 16/09/2024 REPORTING DATE: 16/09/2024 AGE SEX : 32 YRS/M

REF.BY : DR./ MEDIWHEEL.

## GLYCOSYLATED HEMOGLOBIN

TEST NAME	RESULT	Unit	REF.RANGE
HbA1c	4.1 %		Below 5.7 % : Normal 5.7 – 6.4 % : Prediabetic > = 6.5 % : Diabetic
AVERAGE PLASMA GLUCOSE	97.0 mg/dl		90 – 120 mg/dl : Good Control 121 – 150 mg/dl : Fair Control 151- 180 mg/dl: Unsatisfactory Control >180 mg/dl : Poor Control

ESTB BY:-

Consultant Radiologist

**Dr. P. K. Tiwari**

MD, M.Sc (Radio Imaging)  
Ph.D (Alt Nuclear Medicine)  
Consultant Imaginationologist

**Dr. S. Kumar**

MD, (Pat)  
Consultant Pathologist

**Dr. Abhishek Kumar**

MBBS, MD  
Consultant Neuropatho Physiologist

**Dr. Kumari Suman**

MBBS, DGO, MD  
Consultant (TVS & HSG Specialist)

**Dr. A. K. Singh**

MBBS, PGDMCH  
Consultant Radiologist & Sonologist

PRINTING MISTAKE SHOULD BE REPORTED BACK IMMEDIATELY / यहाँ जन्म से पहले भ्रूण का लिंग जाँच नहीं होता है।





# Shubham Imaging & ALC Diagnostic Center

ISO 9001:2015 Certified Center

(A Unit of P. K. Arogyam Health & Wellness Center)

E-95, P.C. Colony, Near Sai Netryalaya Transformer, Kankarbagh, Patna - 20

✉ : alcdiagnostics@gmail.com



: www.pkarogayamhealthcheckup.com



: 7050037694, 9153988577

OPINION MUST BE CORRELATES WITH CLINICALLY & OTHER INVESTIGATION FOR FINAL DIAGNOSIS. NOT FOR MEDICO LEGAL PURPOSE

PATIENT NAME : Mr. PRABHAKAR KUMAR

PATIENT ID: 1182

COL DATE : 16/09/2024 REPORTING DATE: 16/09/2024 AGE SEX : 32 YRS/M

REF.BY : DR. / MEDIWHEEL.

TEST NAME	RESULT	Unit	REF.RANGE
-----------	--------	------	-----------

BLOOD GROUP : 'A'

Rh Typing : POSITIVE

Note: Do always cross – matching before blood transfusion

ESTB BY:-

  
Consultant Radiologist

**Dr. P. K. Tiwari**

MD, M.Sc (Radio Imaging)  
Ph.D (AI) Nuclear Medicine)  
Consultant Imaginationologist

**Dr. S. Kumar**

MD, (Pat)  
Consultant Pathologist

**Dr. Abhishek Kumar**

MBBS, MD  
Consultant Neuropatho Physiologist

**Dr. Kumari Suman**

MBBS, DGO, MD  
Consultant (TVS & HSG Specialist)

**Dr. A. K. Singh**

MBBS, PGDMCH  
Consultant Radiologist & Sonologist

PRINTING MISTAKE SHOULD BE REPORTED BACK IMMEDIATELY / यहाँ जन्म से पहले भ्रूण का लिंग जाँच नहीं होता है।





# Shubham Imaging & ALC Diagnostic Center

ISO 9001:2015 Certified Center

(A Unit of P. K. Arogyam Health & Wellness Center)

E-95, P.C. Colony, Near Sai Netryalaya Transformer, Kankarbagh, Patna - 20

✉ : alcdiagnostics@gmail.com

🌐 : www.pkarogyamhealthcheckup.com

☎ : 7050037694, 9153988577

OPINION MUST BE CORRELATES WITH CLINICALLY & OTHER INVESTIGATION FOR FINAL DIAGNOSIS. NOT FOR MEDICO LEGAL PURPOSE

PATIENT NAME : Mr. PRABHAKAR KUMAR PATIENT ID : 1182  
COL DATE : 16/09/2024 REPORTING DATE: 16/09/2024 AGE SEX : 32 YRS/M  
REF.BY : DR. / MEDIWHEEL.

Investigation	Result	Normal Range
Total Triiodothyronin T3	1.22 ng/mL	0.80 - 2.00 $\mu$ ng/mL
Total Thyroxin T4	7.69 ug/mL	5.10 - 14.10 ug/dL
Serum TSH	3.11 $\mu$ g/mL	0.27 - 4.20 $\mu$ g/mL

THYROID DISORDER (>: Increase: < Decrease: n Normal

1. T3(n) T4(n) TSH(n) :EUTHYROID STATE:
2. T3(>) T4(>) TSH(<): HYPERTHYROIDISM:
3. T3(<)T4(<) TSH(>): HYPOTHYROIDISM:
4. T3(n)T4(n) TSH(>) : SUB-CLINICAL HYPO-THYROIDISM:
5. T3(n)T4(n) TSH(<): SUB-CLINICAL HYPER-THYROIDISM:
6. T3(>) T4(n) TSH(<): T3 THYROTOXICOSIS:

Total T3/T4 level is dependent on Level:

So determination of free T3/T4is a better MARKER of Thyroid Function.

\*FREE T3/T4 ESTIMATION FACILITY IS AVAILABALE ON REQUEST.:

ESTB BY:-

**Dr. P. K. Tiwari**  
MD, M.Sc (Radio Imaging)  
Ph.D (Alt Nuclear Medicine)  
Consultant Imajonologist

**Dr. S. Kumar**  
MD, (Pat)  
Consultant Pathologist

**Dr. Abhishek Kumar**  
MBBS, MD  
Consultant Neuropatho Physiologist

**Dr. Kumari Suman**  
MBBS, DGO, MD  
Consultant (TVS & HSG Specialist)

**Dr. A. K. Singh**  
MBBS, PGDMCH  
Consultant Radiologist & Sonologist

*ASD*  
16/09/24

Consultant Radiologist

PRINTING MISTAKE SHOULD BE REPORTED BACK IMMEDIATELY / यहाँ जन्म से पहले भ्रूण का लिंग जाँच नहीं होता है।



# Shubham Imaging & ALC Diagnostic Center

ISO 9001:2015 Certified Center

(A Unit of P. K. Arogyam Health & Wellness Center)

E-95, P.C. Colony, Near Sai Netryalaya Transformer, Kankarbagh, Patna - 20

✉ : alcdiagnostics@gmail.com

🌐 : www.pkrogyamhealthcheckup.com

📞 : 7050037694, 9153988577

OPINION MUST BE CORRELATES WITH CLINICALLY & OTHER INVESTIGATION FOR FINAL DIAGNOSIS. NOT FOR MEDICO LEGAL PURPOSE

PATIENT NAME : Mr. PRABHAKAR KUMAR

PATIENT ID : 1182

COL DATE : 16/09/2024 REPORTING DATE: 16/09/2024 AGE SEX : 32 YRS/M

REF.BY : DR. / MEDIWHEEL..

ROUTINE EXAMINATION OF URINE

## PHYSICAL EXAMINATION

Quantity ....	20 ml	Colour....	Strow
Appearance...	Clear	Sediment ...	Nil
Specific gravity....	1.010		

## CHEMICAL EXAMINATION

Reaction ....	6.0	Nitrite.....	Not done
Sugar ....	Nil	Bile Pigment ...	Not done
Albumin ....	Nil	Urobilinogen....	Not done
Excess of Phosphate....	Nil	Chile.....	Not done
Bile Salt	Not Done	Acetone...	Not done

## MICROSCOPIC EXAMINATION

Erythrocytes....	Nil	Casts ....	Nil
Leucocytes ....	1- 4 / HPE	Crystals....	Nil
Epith. Cell ....	A, Few	Others ....	Nil

ESTB BY:-

  
Consultant Radiologist

**Dr. P. K. Tiwari**

MD, M.Sc (Radio Imaging)  
Ph.D (Alt Nuclear Medicine)  
Consultant Imagiologist

**Dr. S. Kumar**

MD, (Pat)  
Consultant Pathologist

**Dr. Abhishek Kumar**

MBBS, MD  
Consultant Neuropatho Physiologist

**Dr. Kumari Suman**

MBBS, DGO, MD  
Consultant (TVS & HSG Specialist)

**Dr. A. K. Singh**

MBBS, PGDMCH  
Consultant Radiologist & Sonologist

PRINTING MISTAKE SHOULD BE REPORTED BACK IMMEDIATELY / यहाँ जन्म से पहले भ्रुण का लिंग जाँच नहीं होता है।