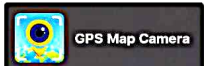


शकतो  
● विंग निदान करणा या डॉक्टरांना आणि ५ वर्षांचा वयच्या लक्षात नोंदणी रद्द होऊ शकते  
● गर्भ धारणा पूर्व परामर्श विभाग (निवडीस प्रतिबंध) १९२४ अधिनियम मुळा बंदी आहे कोणतीही व्यक्ती आढळल्यास त्या व्यक्तीस ५ लाख होऊ शकते  
पंचायतशाळा पर्यावरण विभाग व पर्यावरण शाळा  
हस्त्यालय क्रमांक - १६०१३६००  
महाराष्ट्र (विभाग) : www.amcham.org  
"मुलांना मुलांनी संभाला, तातडीतच शारीरिकद्वारा"  
या संदेशाचे माहितीय संपादकी हीय

SHRIHARIBHARATI BHARANAGAR (P) Ltd.  
M.H.S. PUPA PUSHTI CENTER IN MUMBAI  
Mumbai, Maharashtra, India - 400008



## Mumbai, Maharashtra, India

Nathani Height Belasid Road, Shop Number 41, Jehangir Boman Behram Rd, Opposite Mumbai Central Station, Marzban Parsi Colony, Dalal Estate, Mumbai Central, Mumbai, Maharashtra 400008, India

Lat 18.968773°

Long 72.819941°

25/09/21 10:40 AM





Medi wheel



भारत सरकार

Government of India



अभिषेक कुमार सिंह  
Abhishek Kumar Singh  
जन्म तिथि / DOB : 02/12/1988  
पुरुष / Male



8349 3026 9780

मेरा आधार, मेरी पहचान

*Abhishek*

DR. SHABLI ANI  
MEMBER, INDIAN ASSOCIATION OF POSTGRADUATE MEDICINE PROGRAM, PGDMLS  
FELLOW INTENSIVE CARE  
MMC REG. NO. - 91702

HEALTHCARE CENTRE  
'PAITHANI HEIGHTS', B-WING,  
42, MUMBAI CENTRAL (EAST)



भारतीय विशिष्ट पहचान आधिकारण

Unique Identification Authority of India

पता:  
आत्मज: अनिल कुमार सिंह, 29/1,  
गोंडवा पूर्वा, तहसील- संदिला, गोंडवा,  
हरदोई, टिकुन्नी, उत्तर प्रदेश,  
241203

Address:  
S/O: Anil Kumar Singh, 29/1,  
GONDWA PURWA, TEHSIL-  
SANDILA, Gondwa, Hardoi,  
Dhikunni, Uttar Pradesh, 241203

8349 3026 9780



1947



help@uidai.gov.in

www

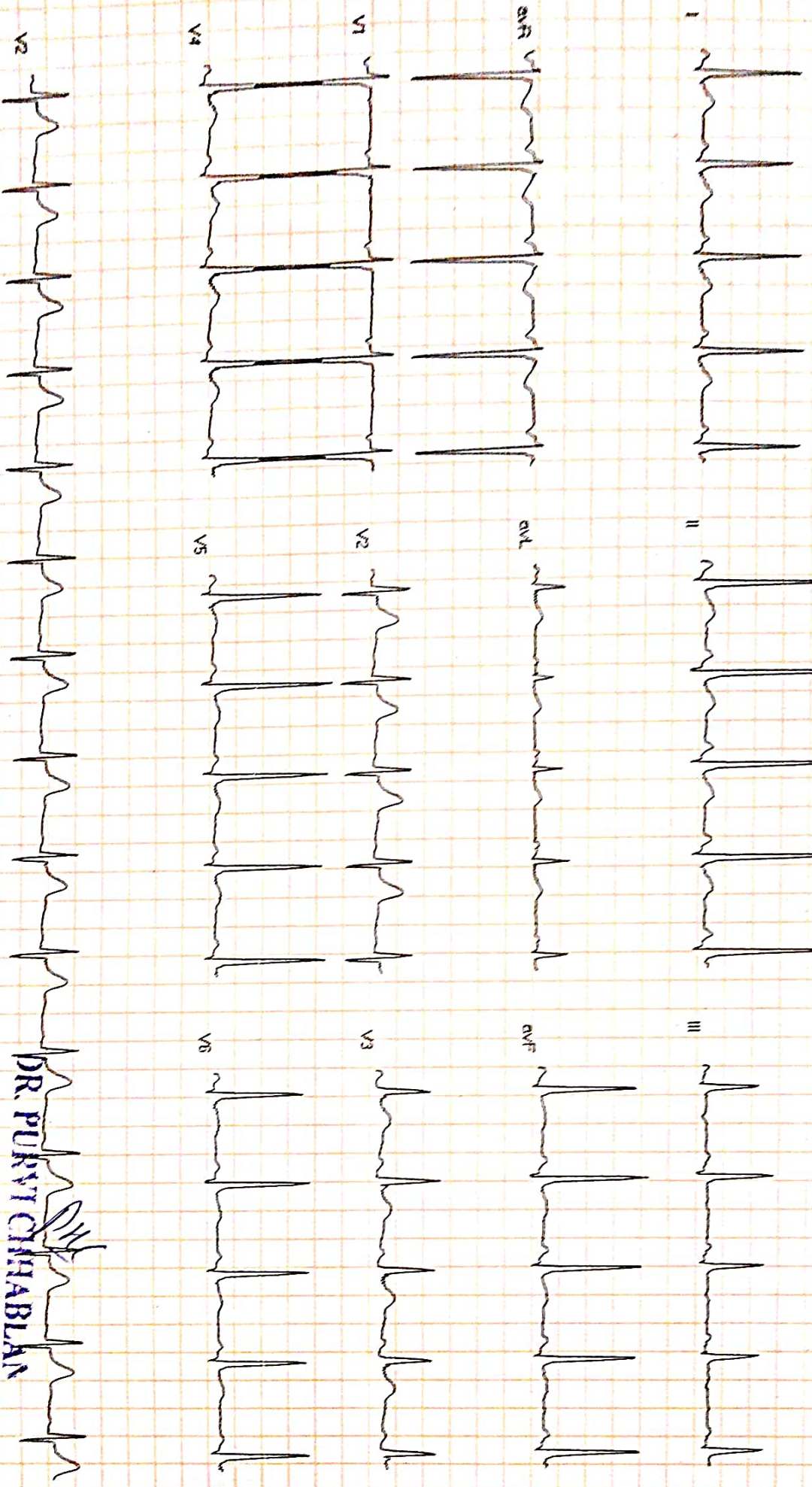
www.uidai.gov.in



**DR PLUS HEALTHCARE CENTRE- MUMBAI CENTRAL**

**ECG**

1091 /ASHISHK SINGH /32 YRS /M  
Heart Rate : 89 bpm /Tested On : 25-Sep-21 18:47:11 /HF 0.05 Hz - LF 100 Hz /Notch 50 Hz /Sn 1.00 Cm/mV /Sw 25 mm/s  
/Refd By: DR. HARI CHHABLANI



**DR. PLUS HEALTHCARE CENTRE**  
NATHAN HEIGHTS, B-W  
42, MUMBAI CENTRAL

*Mall*

**DR. PURVI CHHABLANI**

MBBS DNB (Medicine)  
Consultant Physician And Intensivist  
Reg No 77696  
Reported By: DR. PURVI CHHABLANI

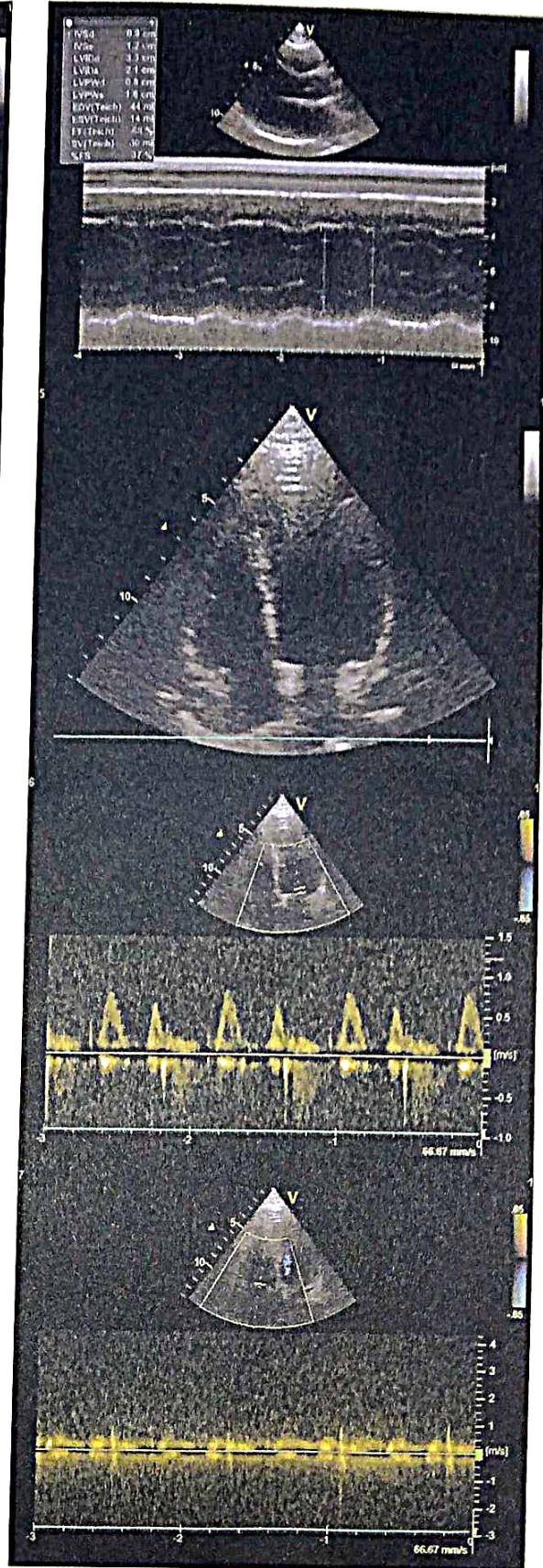
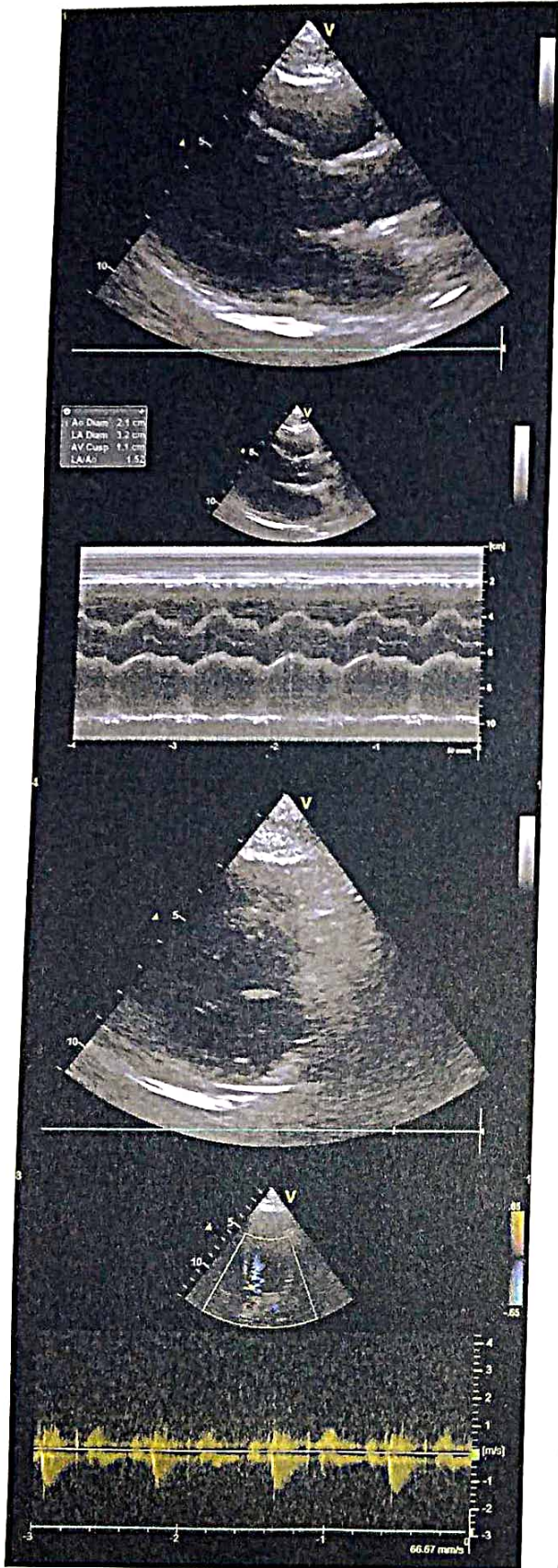


Name ABHISHEK SINGH

Sex Male

Age 32

Date 25/09/2021







NAME : ABHISHEK SINGH

32/M

DATE:25/09/2021

REF BY : DR. PURVI CHHABLANI

## 2D-ECHO. AND COLOR DOPPLER REPORT

- NORMAL CARDIAC VALVES WITH TRIVIAL TR.
- NORMAL CARDIAC CHAMBERS
- NO E/O REGIONAL WALL MOTION ABNORMALITY. WITH NORMAL LVEF OF 63%.
- NO E/O PULMONARY HYPERTENSION. PASP 32 mmHg by TR jet.
- NO E/O LEFT VENTRICULAR HYPERTROPHY.
- NO E/O DIASTOLIC DYSFUNCTION.
- NO E/O PERICARDIAL EFFUSION.
- NO E/O INTRACARDIAC CLOT OR VEGETATIONS.
- INTACT IAS/IVS
- CONVENTIONL DOPPLER :

E TO A RATIO IS MORE THAN ONE IN LV INFLOW.


THERE IS NO GRADIENT ACROSS AV, LVOT OR RVOT

PASP FROM TR JET IS .32 mm OF Hg.

- COLOUR DOPPLER:

TRIVIAL TR

EF Slope	113	mm/sec		
Opening Amplitude	19			
Posterior leaflet				
E.P.S.S	02	mm		
Mitral valve prolapse				
Vegetations				
<b>TRICUSPID VALVE</b>	<b>OBSERVED</b>	<b>NORMAL VALUES</b>		
<b>PULMONARY VALVE</b>	<b>OBSERVED</b>	<b>NORMAL VALUES</b>		
EF Slope				
'A' Wave				
Midsystolic notch				
Flutter				
Other Findings				
<b>AORTIC VALVE</b>	<b>OBSERVED</b>	<b>NORMAL VALUES</b>		
Cuspal opening	16	mm		
Closure line	Central			
Eccentricity index	1			
Other Findings				
<b>DIMENSIONS</b>	<b>OBSERVED</b>	<b>NORMAL VALUES</b>		
1. Lvd (Diastolic)	43	26-52		
2. Lvd (Systolic )	29	24-42mm		
3. RVD (Diastolic)	16	7-23mm		
4. IVST (Diastolic)	08	6-11mm		
5. IVST (Systolic )	15			
6. LVPWT (Diastolic)	09	6-11mm		
7. LVPWT (Systolic )	16			
8. Aortic root	21	22-37mm		
9. left Atrium	32	19-40mm		
	<b>STRUCTURE</b>	<b>REGURG GRADING</b>	<b>VELOCITY</b> m/sec	<b>STENOSIS GRADIENT</b> mm/Hg
			Max      mean	Peak mean
<b>MITRAL VALVE</b>	NORMAL	0/3	/	/
<b>TRICUSPID VALVE</b>	NORMAL	TRIVIAL	/	/
<b>PULMONARY VALVE</b>	NORMAL	0/4	/	/
<b>AORTIC VALVE</b>	NORMAL	0/4	/	/

  
**DR. P.H. CHHABLANI**  
**M.B.B.S, DNB.(MEDICINE)**  
**CONSULTANT PHYSICIAN AND CARDIOLOGIST.**

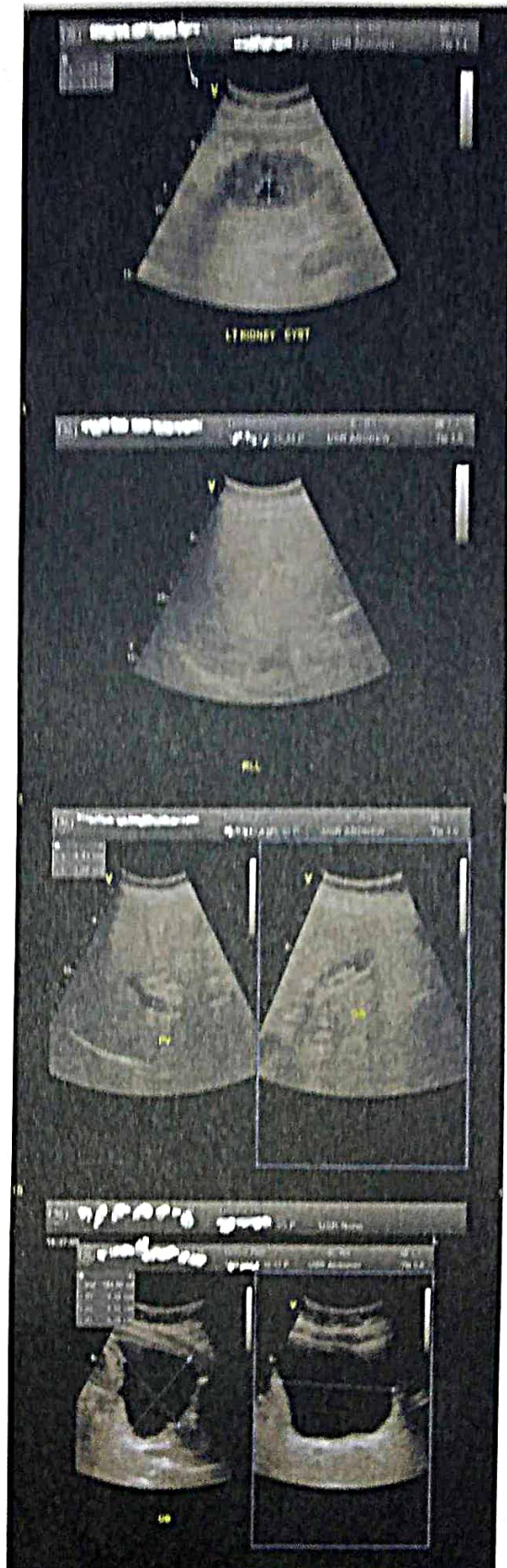
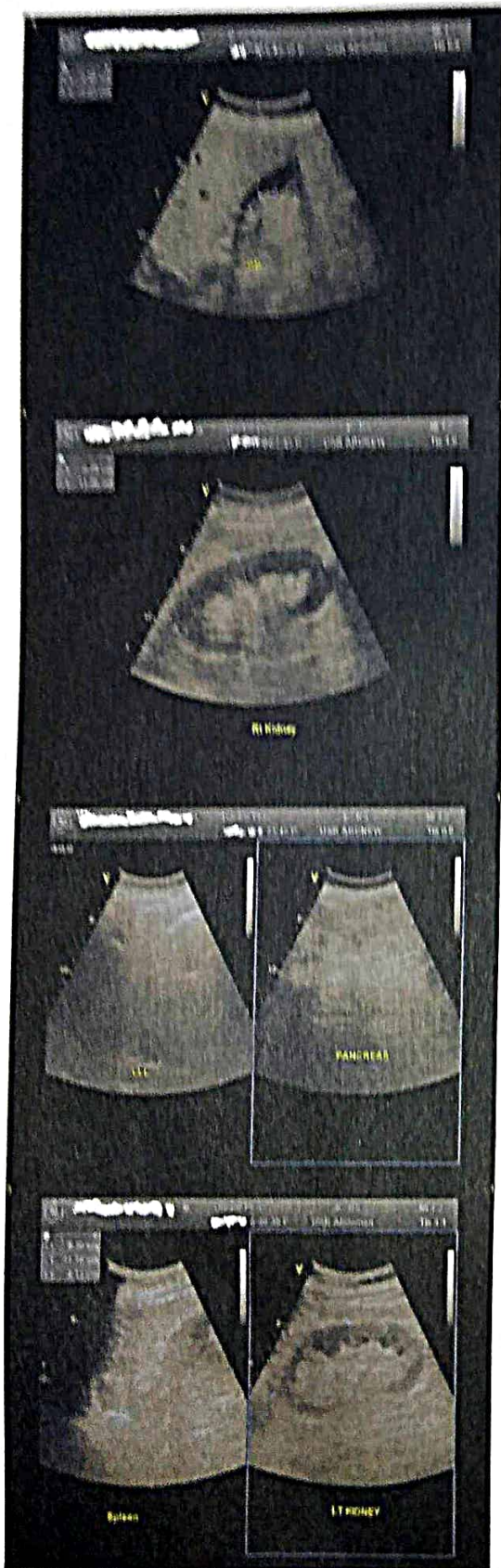
**DR. PURVI CHHABLANI**  
**M.B.B.S DNB (Medicine),**  
**Consultant Physician And Intensivist**  
**Reg No 77696**



Name ABHISHEK BINGH

Sex Male

Age 32







# Dr-Plus Healthcare Centre

NATHANI HEIGHTS, B-Wing, Shop No. 42, Ground Floor, Opp. Mumbai Central Station (East), Mumbai - 400 008.

Patient Name	:	ABHISHEK SINGH	Sex:	MALE
Doctor's Name	:	DR. H. CHHABLANI	Age:	32 YEARS
Date	:	25/09/2021		

## ULTRASONOGRAPHY OF THE ABDOMEN AND THE PELVIS:

The relevant sonographic findings include the following:

### HEPATOBIILIARY APPARATUS

The liver is normal in size and echogenicity. No obvious focal parenchymal lesion is seen.

Extrahepatic biliary radicals are not dilated.

The portal vein and the common bile duct are normal.

### GALL BLADDER

The gall bladder is adequately distended. The wall thickness is normal.

No echogenic contents are noted in its lumen. There is no pericholecystic collection noted.

### PANCREAS

The pancreas shows normal echogenicity and size. No focal or diffuse lesions are noted.

No evidence of calcification is noted.

### SPLEEN

The spleen appears normal in size and echogenicity. No focal or diffuse lesions are noted.

No evidence of calcification is noted.

### KIDNEYS

Right Kidney measure: 10.3 x 4.0 cm, Left kidney measure: 9.3 x 4.4 cm

Both the kidneys appear normal in size, shape and echogenicity. Both the pelvicalyceal system is normal and both corticomedullary differentiations are well maintained. There is no obvious focal or diffuse lesion noted. No evidence of any calculus seen in either kidney.

### PROSTATE

The Prostate appears normal and shows a normal echogenicity.

### URINARY BLADDER

The urinary bladder shows anechoic contents. Its wall thickness appears normal.

No evidence of calcification is seen.

There is no obvious evidence of abdominal or pelvic lymphadenopathy or ascites noted.

**IMPRESSION: No significant abnormality is detected.**

  
Dr. Parag Jhaveri  
MBBS (BOM), DMRE (BOM)  
Radio-Sonologist

"DR. PLUS HEALTHCARE CENTRE"  
NATHANI HEIGHTS', B-WING,  
42, MUMBAI CENTRAL (EAST)





# Dr-Plus Healthcare Centre

NATHANI HEIGHTS, B-Wing, Shop No. 42, Ground Floor, Opp. Mumbai Central Station (East), Mumbai - 400 008.

Patient's Name : ABHISHEK SINGH

Report Date : 25/09/2021

Referred By Dr. : DR. HARI CHHABLANI

Age : 32 Years

Sex : MALE

## X- RAY CHEST PA

BOTH THE LUNG FIELDS ARE CLEAR .

THE HILAR SHADOWS APPEAR NORMAL.

THE COSTO -PHRENIC ANGLES ARE CLEAR.

THE CARDIAC SHADOWS APPEAR NORMAL.

THE TRACHIA IS CENTRAL IN POSITION.

THE BONY CAGE APPEARS NORMAL.

  
Radiologist

DR. A. J. MAZUMDAR

MD. DMRE, MDRD

DR. PLUS HEALTHCARE CENTRE  
NATHANI HEIGHTS', B-WING,  
42, MUMBAI CENTRAL (EAST)

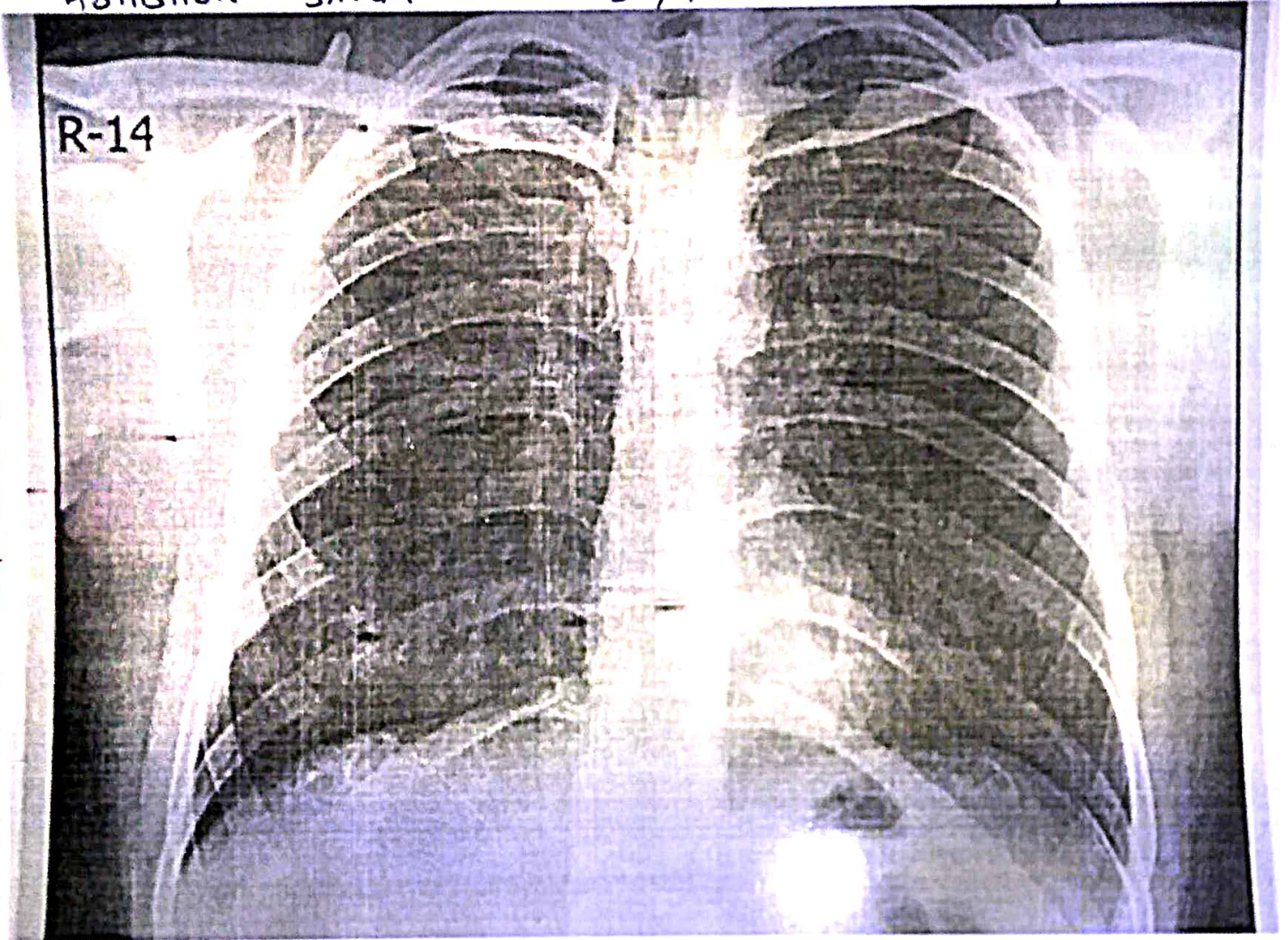


ABHISHEK SINGH

32/M

25/09/21

R-14







# Dr-Plus Healthcare Centre

NATHANI HEIGHTS, B-Wing, Shop No. 42, Ground Floor, Opp. Mumbai Central Station (East), Mumbai - 400 008.

Full Name

ABHISHEK SINGH

32/M

DATE:25/09/202

	Type of Test	Actual Reading	Normal Range
1	Fasting Blood Sugar	85	70-100 mg%
2	PPBS	115	110 TO 140 mg%
3	Total Cholesterol	178	120-200 mg%
4	VERY LOW DENSINTY LEVEL(VLDL)	20	10-30 mg/dl
5	High Density Lipid (HDL)	56	40-60 mg%
6	Low Density Lipid (LDL)	102	Upto 150
7	S. Triglycerides	132	50-150 mg%
8	CHOL/HDL	3.1	Upto 5
9	HDL/LDL	0.54	
10	S. Creatinine	0.9	0.5-1.2 mg%
11	Blood Urea Nitrogen (BUN)	17.7	7-21 mg%
12	BUN/CREAT RATIO	16.3	
13	S. Proteins	6.9	6.0-7.9 mg%
14	(a) Albumin	3.6	3.5-5.5 mg%
15	(b) Globulin	3.3	2.0-3.5 mg%
16	A/G RATIO	1.09	
17	S. Bilirubin	0.8	0.3-1.3mg%
18	(a) Direct	0.3	0.0-0.8 mg%
19	(b) Indirect	0.4	0.0-0.5 mg%
20	SGOT (AST)	26	05-34 IU
21	SGPT (ALT)	32	05-40 IU
22	GGTP (GGT)	40	05-50 IU
23	SGOT/SGPT	0.8	
24	HBA1C	5.5	UPTO 6.5
25	S. Alkaline Phosphatase	80	30-115 IU
26	T3	136	80-180ng/dl
27	T4	7.0	4.6-12 ug/dl
28	TSH	3.0	0.4-4.0 mIU/L
29	SERUM URIC ACID	5.5	2.5-7.2mg/dl
30	URINE SUGAR PP	ABSENT	
31	URINE SUGAR FASTING	ABSENT	
32	BLOOD GROUP	"O" POSITIVE"	

DR. RAKESH PATKAR  
M.D. (Pathology)  
Reg. No. 213 25/1860





# Dr-Plus Healthcare Centre

NATHANI HEIGHTS, B-Wing, Shop No. 42, Ground Floor, Opp. Mumbai Central Station (East), Mumbai - 400 008.

Full Name of life to be assured:

ABHISHEK SINGH

32/M

DATE:25/09/2021

## HAEMOGRAM

### Normal Range

1.	Red Blood Cell Count	4.9	[M : 4.5 - 5.6 / F : 3.5 - 5.5/cu.mm]		
2.	Hb%	15.1	[M: 14-18 / F : 11-16%]		
3.	Hematocrit	46	[M : 40-53 / F : 30-47 %]		
4.	Indices:				
(a)	MCV(Mean Corpuscular Volume)	91	[79-101 cu.mi.]		
(b)	MCH(Mean Corpuscular Hb)	30	[27-32 pg]		
(c)	MCHC(Mean Corpuscular Hb Concentration)	32	[32-38%]		
5.	Morphology				
	Macrocytes :	--	Microcytes:	--	Hypochromia: --
	Poikilocytosis:	--	Anisocytosis:	--	
6.	Target cells:	--			
	Spherocytes:	--	Elliptocytes:	--	
7.	<b>TOTAL W.B.C.Count</b>	7.300	{4000-11000/cu.mm}		
Differential Count					
a)	Neutrophils :	65	[45 - 70%]	c)	Eosinophils: 04 [01 - 06%]
b)	Lymphocytes :	25	[20 - 45%]	d)	Monocytes: 05 [00 - 08%]
e)	Basophils :	01	[00 - 01%]		
8.	<b>Platelets : 2.98</b>	1.5-4.5 Lacks/cu.mm			
9.	<b>Erythrocyte Sedimentation Rate:11</b>	20 mm at end of 1 hour			Method : Westergrens

## ROUTINE URINE EXAMINATION (RUA)

### 1. Physical Examination:

(i)	Colour:	PALE YELLOW	(ii)	Sediment:	CLEAR
(iii)	Transparency:	ABSENT	(iv)	Reaction:	ACIDIC
(v)	Specific gravity	1.010			

### 2. Chemical Examination:

(i)	Protein :	ABSENT	(ii)	Sugar:	ABSENT
(iii)	Bile salt:	ABSENT	(iv)	Bile pigment:	ABSENT

### 3. Microscopic Examination:

(i)	Red Blood Cells:	ABSENT	(ii)	Epithelial Cells:	ABSENT
(iii)	Crystals:	ABSENT	(iv)	Pus Cells:	02 TO 03/HPF
(v)	Casts:	ABSENT	(vi)	Deposits:	ABSENT
(vii)	Bacteria's :	ABSENT			

**DR. RAJESH PATKAR**  
M.D., D.N.B. (Pathology)  
Reg. No. 2013/05/1660





**Dr. Hari Chhablani**

Cardiometabolic Physician & Intensivist  
M.B.B.S., F.C.C.P. (RESP. MED.), PGDHHM,  
PGDMLS, FELLOW INTENSIVE CARE MED.

ATTACHED TO : Wockhardt Hospital • Saifee Hospital • Apollo Spectra Hospital

NATHANI HEIGHTS, B-Wing, Shop No. 42, Ground Floor, Opp. Mumbai Central Station (East),  
Mumbai - 400 008. • Cell : 98206 46163 • E : drharichhablani@gmail.com

## PHYSICIAN REPORT

25/09/2021

NAME : ABHISHEK SINGH

AGE/SEX: 32/M

PRESENTING COMPLAINS: NIL

PAST HISTORY: COVID +VE

TREATMENT HISTORY : NIL

FAMILY HISTORY: NOT SIGNIFICANT

ADDICTION: ALCOHOL +

P: 90/MIN

BP: 124/82

RS: CLEAR

CVS: S1,S2 REGULAR

PA: SOFT

CNS: CLINICALLY NAD

ECG: WNL

CXR: WNL

LABS: ATTACHED

EYE EXAMINATION B/E : NEAR VISION - BL N6 DISTANT VISION - 6/6 COLOUR VISION - NORMAL

IMPRESSION : FIT ON CLINICAL MEDICAL EXAMINATION .

DR. HARI CHHABLANI

**DR. HARI CHHABLANI**  
M.B.B.S., F.C.C.P. (RESP. MEDICINE) PGDHHM, PGDMLS  
FELLOW INTENSIVE CARE  
MMC REG. NO. - 91702