

Health Check up Booking Request(bobE1760),Package Code(PKG10000240),Beneficiary Code(71723)

1 message

Mediwheel <noreply@mediwheel.in>

13 July 2021 at 19:34

To: "vidhidiagnostics@gmail.com" <vidhidiagnostics@gmail.com>

Cc: Mediwheel CC <wellness@mediwheel.in>, Mediwheel CC <customercare@mediwheel.in>, Mediwheel CC <customercare@policywheel.com>, Mediwheel CC <santosh@policywheel.com>


Mediwheel
 ...Your wellness partner

011-41195959
Email:wellness@mediwheel.in

Dear Vidhi Diagnostics,
 City : Ahmedabad . Location : .New Wadaj,

We have received the following request for Health Check up from

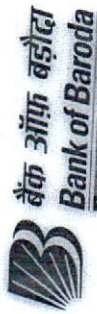Name : MR. PATEL MEHULKUMAR MANILAL
Age : 34
Gender : Male
Member Relations : Employee
Package Name : Metro Bob Full Body Health Checkup Male Below 40
Package Code : PKG10000240
User Location : Gujarat,MEHSANA,382810
Contact Details : 7600820323
Booking Date : 13-07-2021
Appointment Date : 21-07-2021

Member Information			
Booked Member Name	Age	Gender	Cost(In INR)
MR. PATEL MEHULKUMAR MANILAL	34	Male	Cashless
Total amount to be paid		Cashless	

Please login to your account to confirm the same. Also you mail us for confirmation

Package Name : Metro Bob Full Body Health Checkup Male Below 40 - Includes (37) Tests

Tests included in this Package : Ecg, TSH, X-ray Chest, Stress Test (tmt)/ 2d Echo, Blood Sugar Postprandial, A:g Ratio, Blood Group, Total Cholesterol, Triglycerides, Fasting Blood Sugar, Ultrasound Whole Abdomen , Glycosylated Haemoglobin (hba1c), Hdl, Vldl, Urine Analysis, LDL, Total Protine, General Consultation, HDL/ LDL ratio, GGT(Gamma-glutamyl Transferase), Eye Check-up consultation, ALP (ALKALINE PHOSPHATASE), Uric Acid, AST/ALT Ratio, Serum Protein, CBC with ESR, Stool Analysis, Urine Sugar Fasting, Urine Sugar PP, T3, T4, Cholesterol Total / HDL Ratio, BUN, BUN/Creatinine Ratio, Bilirubin Total & Direct and Indirect, Albumin, Globulin



नाम
Name
Mehulkumar Manilal Patel

कर्मचारी कूट क्र.
Employee Code No.
168684


जारीकर्ता प्राधिकारी
Issuing Authority




धारक के हस्ताक्षर
Signature of Holder



भारतीय विशिष्ट पहचान प्राधिकरण

भारत सरकार
Unique Identification Authority of India
Government of India

Enrollment No.: 1127/40066/01086

To
Patel Mehul Kumar
S/O: Manilal
Sokhada
Sokhada
Kukarwada
Vijapur Mahesana
Gujarat 382830

11/01/2014
98534053



MN985340537FT



आपका आधार क्रमांक / Your Aadhaar No. :

6422 8800 4974

आधार - आम आदमी का अधिकार



भारत सरकार
Government of India



Patel Mehul Kumar
DOB : 29/10/1986
Male



6422 8800 4974

आधार - आम आदमी का अधिकार

Dr. Dinesh S. Modh

M.D., D.M.R.E. (Radiodiagnosis)
Consultant Radiologist & Sonologist
Ex. Junior Lecturer, B.J. Medical College, Civil Hospital, A'bad.
Panel Doctor of L.I.C.



Mr. Mehul Kumar Marmik Patel
34 years / male

21-7-2021

Eye vision! - Eye vision normal
in both eye.
No night blindness.

Height! - 164 cm
Weight! - 69 kg
BP! - 128/84 mmHg
SpO2! - 98
Pulse! - 60 per min
T - normal
RS & CVS - normal

Asymptomatic

No H/O of DM, HIV, Thyroid & TB.

H/O Covid positive on March 2021.
14 days home quarantine now
he is healthy

H/O habit of alcohol since 4-5 yr
taking occasionally

Dr. Vidhi D. Modh
MBBS
Reg. No. G-74540

Advice

He is medically fit & normal eye vision in both eye.

ISO 9001:2015 Certified Diagnostics Center

Vidhi Imaging Center

L-86, Swatantra Senani Nagar, Opp. Akhbarnagar Petrol Pump, Nr. Akhbarnagar Circle, Nava-Vadaj, Ahmedabad - 380 013.

Phone : 079-2762 1406, Mobile : 98799 29406, 98250 09406, E-mail : vidhidiagnostics@gmail.com, Website : www.vidhidiagnostics.com

Time : Mon. to Sat. 9.00 am to 2.00 pm, 5.00 pm to 9.00 pm, Sunday 9.00 am to 12.00 Noon

EMPANELLED WITH HEALTH INDIA TPA & APOLLO HEALTH CHECK NETWORK

FACILITIES : Live 3D-4D Sonography | Colour Doppler | Echo Cardiography | Interventional Radiology | Fetal Medicine | Digital X-Ray
Digital Mammography | Digital OPG / TMJ | ECG / TMT / PFT / EEG / EMG | Pathology Laboratory | Health Check Up Plans | Pre Employment Check Up

Dr. Dinesh S. Modh

M.D., D.M.R.E. (Radiodiagnosis)

Consultant Radiologist & Sonologist

Ex. Junior Lecturer, B.J. Medical College, Civil Hospital, A'bad.

Panel Doctor of L.I.C.



Patient's name: MEHULKUMAR M PATEL

Reg. ID : R-3986-21

Referred by : Dr. MEDIWHEEL

Age/Sex : 34 Years/Male

Accession : 27677

Date : 21/07/2021

Report of ECG

Conclusion

- Normal sinus rhythm.
- HR - 60/per minute.
- Normal PR interval.
- Normal QRS interval.
- Normal QT interval.

Dr. Avinash Bhaskar
MBBS, MD, Cardio
Reg. No.: G-45946

DR.AVINASH BHASKAR

ISO 9001:2015 Certified Diagnostics Center

Vidhi Imaging Center

L-86, Swatantra Senani Nagar, Opp. Akhbarnagar Petrol Pump, Nr. Akhbarnagar Circle, Nava-Vadaj, Ahmedabad - 380 013.

Phone : 079-2762 1406, Mobile : 98799 29406, 98250 09406, E-mail : vidhidiagnostics@gmail.com, Website : www.vidhidiagnostics.com

Time : Mon. to Sat. 9.00 am to 2.00 pm, 5.00 pm to 9.00 pm, Sunday 9.00 am to 12.00 Noon

EMPANNELLED WITH HEALTH INDIA TPA & APOLLO HEALTH CHECK NETWORK

FACILITIES : Live 3D-4D Sonography | Colour Doppler | Echo Cardiography | Interventional Radiology | Fetal Medicine | Digital X-Ray
Digital Mammography | Digital OPG/TMJ | ECG/TMT/PFT/EEG/EMG | Pathology Laboratory | Health Check Up Plans | Pre Employment Check Up

HR : 60 bpm
 PR : 180 ms
 QRS : 108 ms
 QT/QTc : 378/378 ms
 P/QRS/T : 9/23/38 deg.

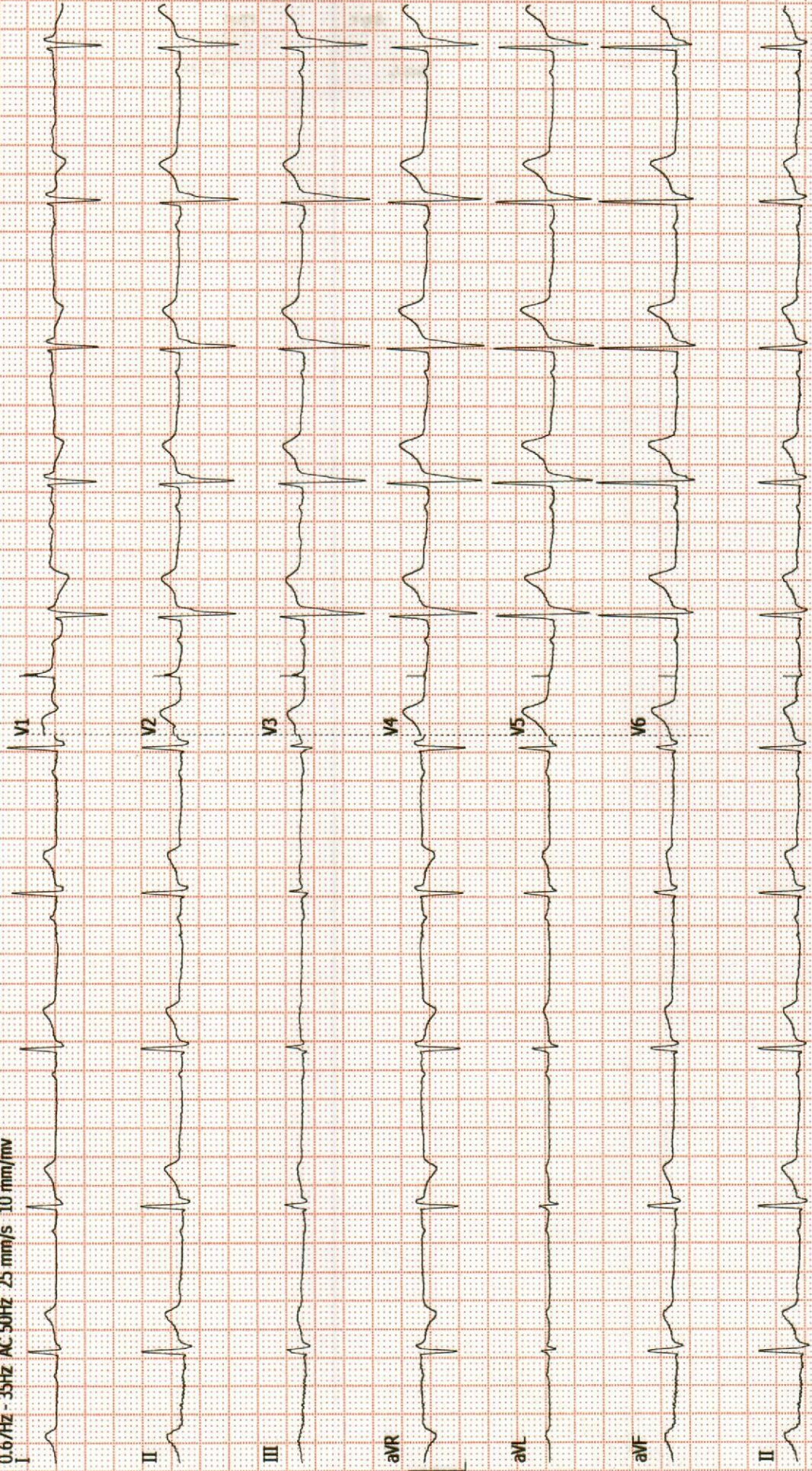
** normal ECG **
 Sinus rhythm

ID: 1876
 Name: mehul
 Age:
 Sex:

Hospital:
 Department:
 RV5/SV1: 0.995/-0.809 mv
 RV5+SV1: 1.804 mv

Need to be confirmed by doctor. Doctor Name: _____

0.67Hz - 35Hz AC 50Hz 25 mm/s 10 mm/mv



Dr. Dinesh S. Modh

M.D., D.M.R.E. (Radiodiagnosis)

Consultant Radiologist & Sonologist

Ex. Junior Lecturer, B.J. Medical College, Civil Hospital, A'bad.

Panel Doctor of L.I.C.



Patient's name: MEHULKUMAR M PATEL
Reg. ID : R-3986-21
Referred by : Dr. MEDIWHEEL

Age/Sex : 34 Years/Male
Accession : 27677
Date : 21/07/2021

USG ABDOMEN

LIVER:- Liver appears normal in size & echo texture. No evidence of focal lesion is seen. IHBR appear normal. Portal vein and CBD appear normal. No e/o calculus is seen in bile duct.

GALL BLADDER:- Gall bladder is distended & shows 2-3 small polyp measures 3-4mm. No evidence of calculus or cholecystitis is seen.

SPLEEN:- Spleen appears normal in size & shows normal echo texture. No evidence of diffuse or focal lesion is seen.

PANCREAS:- Pancreas appears normal size and echo pattern. No e/o diffuse or focal lesion is seen. Main pancreatic duct appears normal.

KIDNEY:- Both Kidneys appear normal in size & echo texture.

- No e/o calculus or hydronephrosis/ hydroureter is seen on both sides.

Cortico-medullary differentiation is maintained on both sides.

Both suprarenal regions appear normal.

No evidence of pre & para aortic lymphadenopathy is seen.

Both suprarenal regions appear normal.

No evidence of pre & para aortic lymphadenopathy is seen.

RIF & BOWEL LOOPS (By high frequency probe):- Normal.

No evidence of dilated or thickened bowel loops is seen.

No evidence of free fluid is seen in abdomen.

Urinary bladder:- appears normal. No e/o calculus or mass lesion is seen in bladder.

Prostate appears normal size and echopattern.

Thanks for reference.

DR DINESH S. MODH

M.D. DMRE(RADIODIAGNOSIS)

Dr. Dinesh S. Modh
MD DMRE (Radiodiagnosis)
G-23825

ISO 9001:2015 Certified Diagnostics Center

Vidhi Imaging Center

L-86, Swatantra Senani Nagar, Opp. Akhbarnagar Petrol Pump, Nr. Akhbarnagar Circle, Nava-Vadaj, Ahmedabad - 380 013.

Phone : 079-2762 1406, Mobile : 98799 29406, 98250 09406, E-mail : vidhidiagnostics@gmail.com, Website : www.vidhidiagnostics.com

Time : Mon. to Sat. 9.00 am to 2.00 pm, 5.00 pm to 9.00 pm, Sunday 9.00 am to 12.00 Noon

EMPANNELLED WITH HEALTH INDIA TPA & APOLLO HEALTH CHECK NETWORK

FACILITIES : Live 3D-4D Sonography | Colour Doppler | Echo Cardiography | Interventional Radiology | Fetal Medicine | Digital X-Ray
Digital Mammography | Digital OPG/TMJ | ECG/TMT/PFT/EEG/EMG | Pathology Laboratory | Health Check Up Plans | Pre Employment Check Up

Dr. Dinesh S. Modh

M.D., D.M.R.E. (Radiodiagnosis)

Consultant Radiologist & Sonologist

Ex. Junior Lecturer, B.J. Medical College, Civil Hospital, A'bad.

Panel Doctor of L.I.C.



Patient's name: MEHULKUMAR M PATEL

Reg. ID : R-3986-21

Referred by : Dr. MEDIWHEEL

Age/Sex : 34 Years/Male

Accession : 27677

Date : 21/07/2021

2D- ECHO REPORT

FINAL CONCLUSION:

LV IS NORMAL SIZE. GOOD LV SYSTOLIC FUNCTION.NO RWMA.

LVEF - 60%. NO CONCENTRIC LVH.

NORMAL LV COMPLANCE.

LA IS NORMAL SIZE. NO LA CLOT.

RV IS NORMAL SIZE. GOOD RV SYSTOLIC FUNCTION.

RA IS NORMAL SIZE.

MITRAL VALVE IS NORMAL. NO MS. MILD MR (15%). NO MVP.

AORTIC VALVE IS NORMAL. NO AS. NO AR.

TRICUSPID VALVE IS NORMAL. NO TR. RVSP-22 mmHg. NO PAH.

NO CLOT, NO VEGETATION, NO PERICARDIAL EFFUSION..

DIMENSIONS:

AORTA	2.6 C.M
LEFT ATRIUM	2.7 C.M
LVDD	4.1 C.M.
IVSD	1.0 C.M
PWD	1.0 C.M
LVDS	2.6 C.M.

COLOUR DOPPLER FINDING:

STRUCTURE	VELOCITY m/sec
	Max
PULMONARY VALVE	0.7
MITRAL VALVE	E : 0.7 A: 0.4
AORTIC VALVE	1.0

Dr. Avinash Bhaskar
MBBS. D Cardio
Reg. No.: G-45946

DR AVINASH BHASKAR

ISO 9001:2015 Certified Diagnostics Center

Vidhi Imaging Center

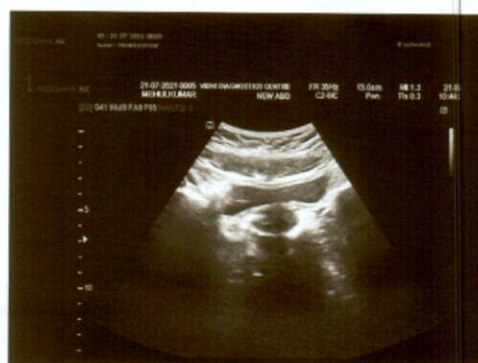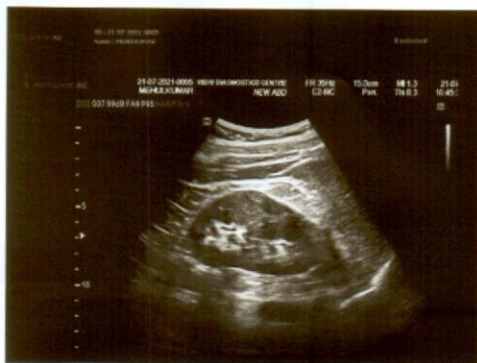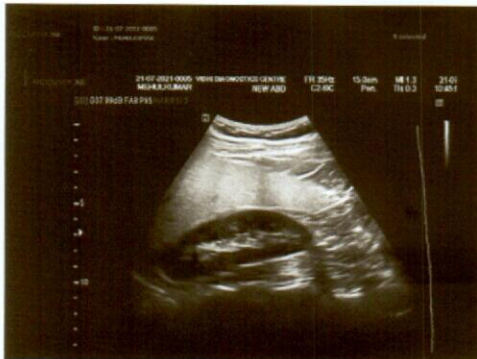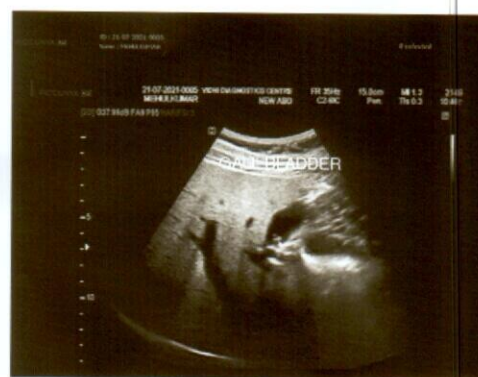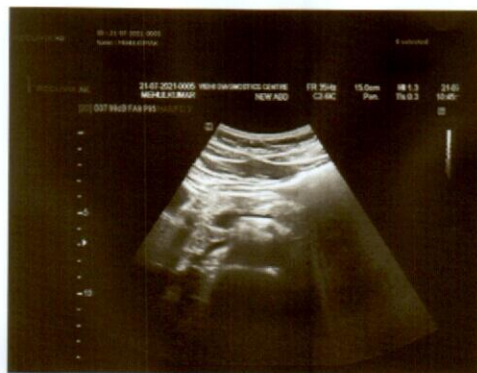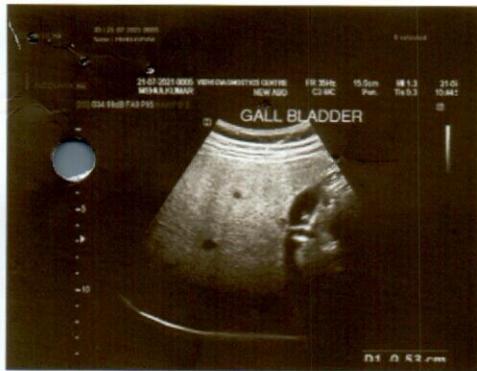
L-86, Swatantra Senani Nagar, Opp. Akhbarnagar Petrol Pump, Nr. Akhbarnagar Circle, Nava-Vadaj, Ahmedabad - 380 013.

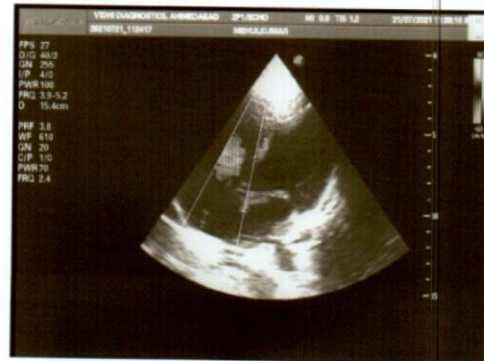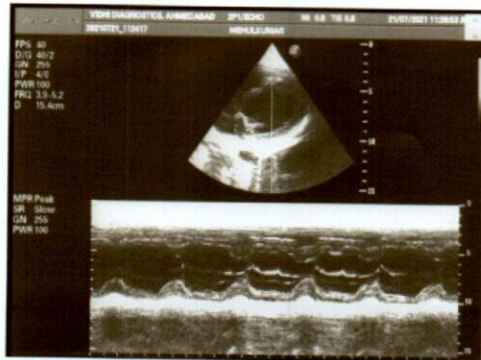
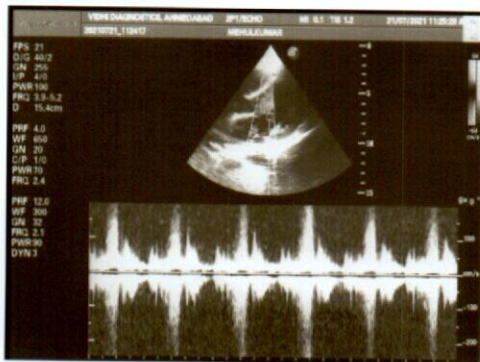
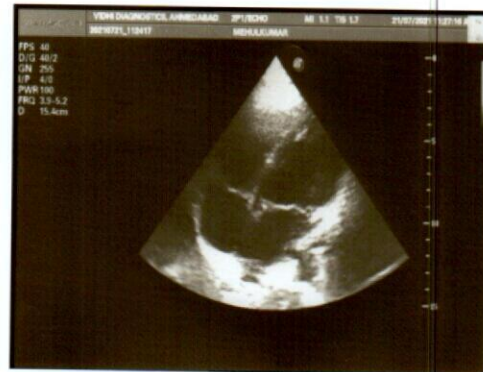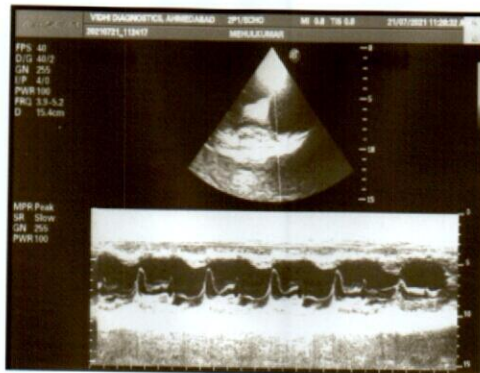
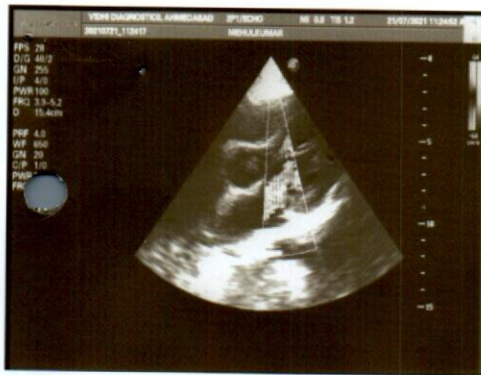Phone : 079-2762 1406, Mobile : 98799 29406, 98250 09406, E-mail : vidhidiagnostics@gmail.com, Website : www.vidhidiagnostics.com

Time : Mon. to Sat. 9.00 am to 2.00 pm, 5.00 pm to 9.00 pm, Sunday 9.00 am to 12.00 Noon

EMPANNELLED WITH HEALTH INDIA TPA & APOLLO HEALTH CHECK NETWORK

FACILITIES : Live 3D-4D Sonography | Colour Doppler | Echo Cardiography | Interventional Radiology | Fetal Medicine | Digital X-Ray
Digital Mammography | Digital OPG/TMJ | ECG/TMT/PFT/EEG/EMG | Pathology Laboratory | Health Check Up Plans | Pre Employment Check Up





Dr. Dinesh S. Modh

M.D., D.M.R.E. (Radiodiagnosis)

Consultant Radiologist & Sonologist

Ex. Junior Lecturer, B.J. Medical College, Civil Hospital, A'bad.

Panel Doctor of L.I.C.



Patient's name: MEHULKUMAR M PATEL

Reg. ID : R-3986-21

Referred by : Dr. MEDIWHEEL

Age/Sex : 34 Years/Male

Accession : 27677

Date : 21/07/2021

X-RAY CHEST (PA VIEW)

Both lung fields appear normal.
No e/o consolidation or cavitations is seen.
Both costo-phrenic angles appear clear.
Cardiac size is with in normal limits.
Both domes of diaphragm appear normal.
Bony thoracic cage appears normal.

Thanks for reference.

Dr. Dinesh S. Modh
MD DMRE (Radiodiagnosis)
G-23825

DR DINESH S. MODH

M.D. DMRE(RADIODIAGNOSIS)

ISO 9001:2015 Certified Diagnostics Center

Vidhi Imaging Center

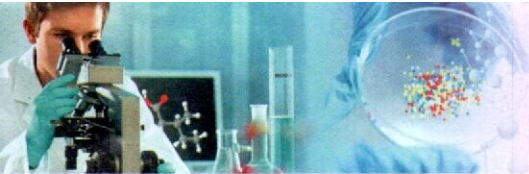L-86, Swatantra Senani Nagar, Opp. Akhbarnagar Petrol Pump, Nr. Akhbarnagar Circle, Nava-Vadaj, Ahmedabad - 380 013.

Phone : 079-2762 1406, Mobile : 98799 29406, 98250 09406, E-mail : vidhidiagnostics@gmail.com, Website : www.vidhidiagnostics.com

Time : Mon. to Sat. 9.00 am to 2.00 pm, 5.00 pm to 9.00 pm, Sunday 9.00 am to 12.00 Noon

EMPANNELLED WITH HEALTH INDIA TPA & APOLLO HEALTH CHECK NETWORK

FACILITIES : Live 3D-4D Sonography | Colour Doppler | Echo Cardiography | Interventional Radiology | Fetal Medicine | Digital X-Ray
Digital Mammography | Digital OPG / TMJ | ECG / TMT / PFT / EEG / EMG | Pathology Laboratory | Health Check Up Plans | Pre Employment Check Up



Creating Life in Samples

Patient's name : MEHULKUMAR M. PATEL
Age/Sex : 34 Years/Male
Referred by : -
Collection Time : 10:01

Reg. ID : P-2598-21
Accession : 27674
Order Dt/time : 21/07/2021 10:01

Complete Blood Count

Sample Type: EDTA

Test Name	Result	Units	Biological Reference Interval
-----------	--------	-------	-------------------------------

Blood Counts

Haemoglobin :	13.7	Gms%	13.5 - 18.0
Total R.B.C. :	4.40	mill/c.mm	4.7 - 6.0
Total W. B. C. :	6,800	/cu mm	4000 - 10500
Platelet Count :	3,08,000	/cu.mm	1,50,000 - 4,50,000

Differential Count

Neutrophils :	55	%	40 - 70
Lymphocytes :	40	%	20 - 40
Eosinophils :	03	%	1 - 4
Monocytes :	02	%	2 - 6
Basophils :	00	%	0 - 01

Blood Indices

P. C. V :	41.2	%	42 - 52
M. C. V. :	93.5	fl	78 - 100
M.C.H :	31.1	pg	27 - 31
M. C. H. C :	33.3	%	32 - 36
R.D.W :	13.2	%	11.5 - 14.0

E.S.R.(Westergren Method)

After one hour : 06 mm/hr 1 - 7

TESTS DONE ON FULLY AUTOMATED HEMATOLOGY ANALYZER.

Dr. Gayatri M. Mehta
M.D. (Pathology)
Reg. No. G-32215

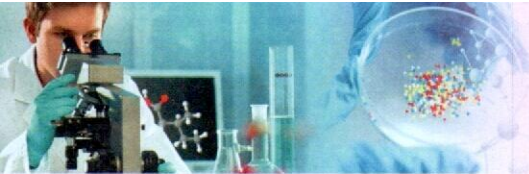DR GAYATRI MEHTA
MD(PATHOLOGY)

DR. ANAND D. PARIKH
MD(PATHOLOGY)

LAB USE ONLY (Entered by :AP Enter Date/Time:21/07/2021 12:55:00 PM) (Verify by :DM Verify Date/Time:21/07/2021 3:23:00 PM)

ISO 9001:2015 Certified Diagnostics Center
Vidhi Imaging Center

L-86, Swatantra Senani Nagar, Opp. Akhbarnagar Petrol Pump, Nr. Akhbarnagar Circle, Nava-Vadaj, Ahmedabad - 380 013.
Phone : 079-2762 1406, Mobile : 98799 29406, 98250 09406, E-mail : vidhidiagnostics@gmail.com, Website : www.vidhidiagnostics.com
Time : Mon. to Sat. 9.00 am to 2.00 pm, 5.00 pm to 9.00 pm, Sunday 9.00 am to 12.00 Noon



Creating Life in Science

Patient's name : MEHULKUMAR M. PATEL
Age/Sex : 34 Years/Male
Referred by : -
Collection Time : 10:01

Reg. ID : P-2598-21
Accession : 27674
Order Dt/time : 21/07/2021 10:01

Blood Glucose

Sample Type: Serum

Test Name	Result	Units	Biological Reference Interval
Fasting Blood Glucose :	99.56	mg/dl	70 - 110
Urine Sugar :	NIL		Absent
<i>GOD-POD Method.</i>			

Blood Glucose

Sample Type: Serum

Test Name	Result	Units	Biological Reference Interval
Post Prandial Blood Glucose After 2hr. :	S.N.R	mg/dl	80 - 140
<i>GOD-POD Method.</i>			

DR GAYATRI MEHTA
MD(PATHOLOGY)

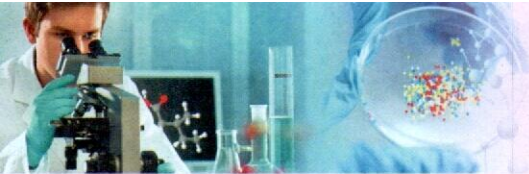Dr. Gayatri M. Mehta
M. D. (Pathology)
Reg. No. G-32215

DR. ANAND D. PARIKH
MD(PATHOLOGY)

LAB USE ONLY (Entered by :DM Enter Date/Time:21/07/2021 3:24:00 PM) (Verify by :DM Verify Date/Time:21/07/2021 3:24:00 PM)

ISO 9001:2015 Certified Diagnostics Center
Vidhi Imaging Center

L-86, Swatantra Senani Nagar, Opp. Akhbarnagar Petrol Pump, Nr. Akhbarnagar Circle, Nava-Vadaj, Ahmedabad - 380 013.
Phone : 079-2762 1406, Mobile : 98799 29406, 98250 09406, E-mail : vidhidiagnostics@gmail.com, Website : www.vidhidiagnostics.com
Time : Mon. to Sat. 9.00 am to 2.00 pm, 5.00 pm to 9.00 pm, Sunday 9.00 am to 12.00 Noon



Creating life in Samples

Patient's name : MEHULKUMAR M. PATEL
Age/Sex : 34 Years/Male
Referred by : -
Collection Time : 10:01

Reg. ID : P-2598-21
Accession : 27674
Order Dt/time : 21/07/2021 10:01

BIOCHEMISTRY

Sample type :Serum

Test Name	Result	Units	Biological Reference Interval
Urea , (Serum by GLDH method) :	25.67	mg/dl	10 - 50
S.Uric acid , (Serum by Uricase method) :	4.48	mg/dl	3.4 - 7.0
Bun :	12	mg/dl	6-20
Creatinine , (Serum by Jaffe reaction) :	1.11	mg/dl	0.5-1.2
S.G.P.T (ALT) : (Serum by IFCC method)	50.13	U/L	0 - 40
S.G.O.T (AST) : (Serum by IFCC method)	34.98	U/L	0 - 37
ALK.PHOSPHATASE : (Serum by PNP method)	84.49	U/L	40-129
G.G.T :	46.20	U/L	8 - 78
<u>BILIRUBIN</u>			
Total :	0.36	mg/dl	Up to 1.2
Direct :	0.12	mg/dl	0-0.7
Indirect :	0.24	mg/dl	0 - 0.5
<u>SERUM PROTEINS</u>			
Total Protein (Serum by Biuret method) :	7.00	gms/dl	6.6 - 8.7
Albumin (Serum by BCG method) :	4.39	gms/dl	3.97-4.94
Globulins :	2.61	gms/dl	2.3 - 3.5
A/G Ratio :	1.682		0.9 - 2.9

DR GAYATRI MEHTA
MD(PATHOLOGY)

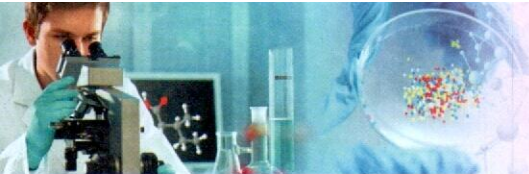Dr. Gayatri M. Mehta
M.D. (Pathology)
Rec. No. G-32215

DR. ANAND D. PARIKH
MD(PATHOLOGY)

LAB USE ONLY (Entered by: DM Enter Date/Time:21/07/2021 3:23:00 PM) (Verify by :DM Verify Date/Time:21/07/2021 3:23:00 PM)

ISO 9001:2015 Certified Diagnostics Center
Vidhi Imaging Center

L-86, Swatantra Senani Nagar, Opp. Akhbarnagar Petrol Pump, Nr. Akhbarnagar Circle, Nava-Vadaj, Ahmedabad - 380 013.
Phone : 079-2762 1406, Mobile : 98799 29406, 98250 09406, E-mail : vidhidiagnostics@gmail.com, Website : www.vidhidiagnostics.com
Time : Mon. to Sat. 9.00 am to 2.00 pm, 5.00 pm to 9.00 pm, Sunday 9.00 am to 12.00 Noon



Creating life in Samples

Patient's name : MEHULKUMAR M. PATEL
Age/Sex : 34 Years/Male
Referred by : -
Collection Time : 10:01

Reg. ID : P-2598-21
Accession : 27674
Order Dt/time : 21/07/2021 10:01

Blood Group

Sample Type: EDTA sample.

Test Name	Result
BG :	" O "
RH :	POSITIVE
Remarks	Done by forward grouping method.

Lipid Profile

Sample Type: Serum

Test Name	Result	Units	Biological Reference Interval
S. Cholesterol : Oxidase-esterase method.	<u>224.16</u>	mg/dl	0 - 200
S. Triglyceride : Enzymatic Colorimetry method	190.78	mg/dL	0 - 200
S. HDL - Cholesterol : Serum by Enzymatic method.	46.52	mg/dL	35 - 65
S. LDL - Cholesterol : Serum by Enzymatic method	<u>139.484</u>	mg/dL	0 - 130
S. VLDL - Cholesterol :	<u>38.16</u>	mg/dL	0 - 30
S. Chole/HDL.Ratio :	4.82		1 - 6
S. LDL / HDL Cholesterol Ratio :	3		0 - 3.5

DR GAYATRI MEHTA
MD(PATHOLOGY)

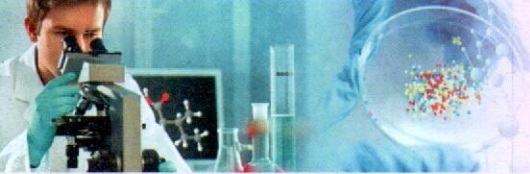Dr. Gayatri M. Mehta
M.D. (Pathology)
Reg. No. G-32215

DR. ANAND D. PARIKH
MD(PATHOLOGY)

LAB USE ONLY (Entered by :DM Enter Date/Time:21/07/2021 3:24:00 PM) (Verify by :DM Verify Date/Time:21/07/2021 3:24:00 PM)

ISO 9001:2015 Certified Diagnostics Center
Vidhi Imaging Center

L-86, Swatantra Senani Nagar, Opp. Akhbarnagar Petrol Pump, Nr. Akhbarnagar Circle, Nava-Vadaj, Ahmedabad - 380 013.
Phone : 079-2762 1406, Mobile : 98799 29406, 98250 09406, E-mail : vidhidiagnostics@gmail.com, Website : www.vidhidiagnostics.com
Time : Mon. to Sat. 9.00 am to 2.00 pm, 5.00 pm to 9.00 pm, Sunday 9.00 am to 12.00 Noon



Creating Life in Samples



Pathology Department

Patient's name : MEHULKUMAR M. PATEL
Age/Sex : 34 Years/Male
Referred by : -
Collection Time : 10:01

Reg. ID : P-2598-21
Accession : 27674
Order Dt/time : 21/07/2021 10:01

Thyroid Function Test

Sample Type: Serum

Test Name	Result	Units	Biological Reference Interval
TOTAL T3 :	1.65	ng/ml	0.84 - 2.0
TOTAL T4 :	6.02	ug/dl	5.1 - 14.0
TSH(Ultra sensitive) :	1.70	mIU/L	0.27 - 4.2

Method Electrochemiluminescence Immunoassay "ECLIA"

Test done on Roche Cobas e411 Immunoassay Analyser

Dr. Gayatri M. Mehta

DR GAYATRI MEHTA
MD(PATHOLOGY)

M.D. (Patho)

Reg. No. G-33213

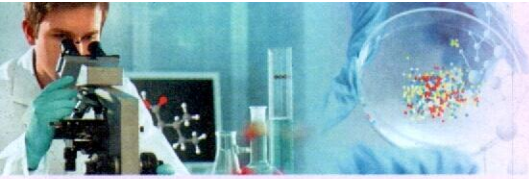DR. ANAND D. PARIKH
MD(PATHOLOGY)

LAB USE ONLY (Entered by :DM Enter Date/Time:21/07/2021 3:25:00 PM) (Verify by :DM Verify Date/Time:21/07/2021 3:25:00 PM)

ISO 9001:2015 Certified Diagnostics Center
Vidhi Imaging Center

L-86, Swatantra Senani Nagar, Opp. Akhbarnagar Petrol Pump, Nr. Akhbarnagar Circle, Nava-Vadaj, Ahmedabad - 380 013.
Phone : 079-2762 1406, Mobile : 98799 29406, 98250 09406, E-mail : vidhidiagnostics@gmail.com, Website : www.vidhidiagnostics.com
Time : Mon. to Sat. 9.00 am to 2.00 pm, 5.00 pm to 9.00 pm, Sunday 9.00 am to 12.00 Noon

Pathology means science behind medicine



Creating life in Samples



Pathology Department

Patient's name : MEHULKUMAR M. PATEL
Age/Sex : 34 Years/Male
Referred by : -
Collection Time : 10:01

Reg. ID : P-2598-21
Accession : 27674
Order Dt/time : 21/07/2021 10:01

HbA1C

Sample Type: Serum

Test Name	Result	Units	Biological Reference Interval
HbA1C :	5.8	%	Non-diabetic: 4.2-6.2 Pre-diabetic : 6.3-7.2 Diabetic : 7.3-8.2
Mean Blood Glucose of Last 03 months.	119.76	mg/dl	

Comment

*As per the new 2009 update of American Diabetes Association regarding HbA1C & Mean Blood Glucose relationship.

NOTE:

This test is used to monitor diabetic patients compliance with the therapeutic regimen and logo It's level is proportional to both the average blood glucose concentration and the life span of the red blood cells (RBC) in circulation. HbA1c values are free of day to day glucose fluctuations and are unaffected by exercise or recent food intake.

DR GAYATRI MEHTA
MD(PATHOLOGY)

Dr. Gayatri M. Mehta
M.D. (Patho)

Reg No G-3215

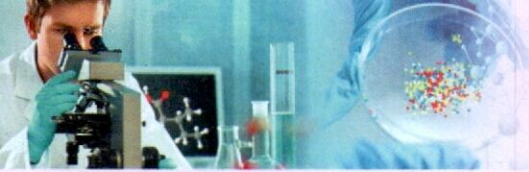DR. ANAND D. PARIKH
MD(PATHOLOGY)

LAB USE ONLY (Entered by :DM Enter Date/Time:21/07/2021 3:24:00 PM) (Verify by :DM Verify Date/Time:21/07/2021 3:24:00 PM)

ISO 9001:2015 Certified Diagnostics Center
Vidhi Imaging Center

L-86, Swatantra Senani Nagar, Opp. Akhbarnagar Petrol Pump, Nr. Akhbarnagar Circle, Nava-Vadaj, Ahmedabad - 380 013.
Phone : 079-2762 1406, Mobile : 98799 29406, 98250 09406, E-mail : vidhidiagnostics@gmail.com, Website : www.vidhidiagnostics.com
Time : Mon. to Sat. 9.00 am to 2.00 pm, 5.00 pm to 9.00 pm, Sunday 9.00 am to 12.00 Noon

Pathology means science behind medicine



Patient's name : MEHULKUMAR M. PATEL
 Age/Sex : 34 Years/Male
 Referred by : -
 Collection Time : 10:01

Reg. ID : P-2598-21
 Accession : 27674
 Order Dt/time : 21/07/2021 10:01

Urine Analysis

Sample Type: Urine

Test Name	Result	Units	Biological Reference Interval
<u>Physical Examination</u>			
Quantity :	20	ml	0 - 500 ml
Colour :	Pale Yellow		Pale Yellow
Transparency :	Slight Turbid.		Clear
Reaction :	Acidic		4.6 - 8.0
Specific Gravity :	1.020		1.016 - 1.022
Sediment :	Present		
<u>Chemical Examination</u>			
Albumin :	Absent		Absent
Sugar :	NIL		Absent
Acetone :	Absent		Absent
Bile Salts :	Absent		Absent
Bile Pigments :	Absent		Absent
Urobilogen :	Absent		Absent
Nitrites :	Absent		Absent
<u>Microscopic Examination</u>			
Red blood Cells :	2-3	/h.p.f	Absent
Pus Cells :	1-2	/h.p.f	Absent
Epithelial Cells :	1-2	/h.p.f	< 10.0
Amorphous :	Absent	/h.p.f	Absent
Bacteria :	Absent	/h.p.f	Absent
Crystals :	Absent	/h.p.f	Absent
Casts :	Absent	/h.p.f	Absent
Fungus :	Not seen	/h.p.f	Absent

DR GAYATRI MEHTA
 MD(PATHOLOGY)

Dr. Gayatri M. Mehta
 M.D. (Pathology)
 Reg No. G-32215

DR. ANAND D. PARIKH
 MD(PATHOLOGY)

LAB USE ONLY (Entered by :DM Enter Date/Time:21/07/2021 3:25:00 PM) (Verify by :DM Verify Date/Time:21/07/2021 3:25:00 PM)

ISO 9001:2015 Certified Diagnostics Center
 Vidhi Imaging Center

L-86, Swatantra Senani Nagar, Opp. Akhbarnagar Petrol Pump, Nr. Akhbarnagar Circle, Nava-Vadaj, Ahmedabad - 380 013.
 Phone : 079-2762 1406, Mobile : 98799 29406, 98250 09406, E-mail : vidhidiagnostics@gmail.com, Website : www.vidhidiagnostics.com
 Time : Mon. to Sat. 9.00 am to 2.00 pm, 5.00 pm to 9.00 pm, Sunday 9.00 am to 12.00 Noon