

Patient Name : Mrs. Bhavyashree N S

Age/Gender : 38 Y/F

UHID/MR No. : CMYS.0000059241

OP Visit No : CMYSOPV121327

Sample Collected on :

Reported on : 16-01-2024 10:57

LRN# : RAD2207691

Specimen :

Ref Doctor : SELF

Emp/Auth/TPA ID : 898942899820

DEPARTMENT OF RADIOLOGY

ULTRASOUND - WHOLE ABDOMEN

LIVER: It is normal in size and echotexture. No focal lesions seen. IHBR are not dilated. CBD and Portal vein are normal.

GALL BLADDER: It is well distended and normal. No calculi seen.

SPLEEN: It is normal in size, outline and echopattern. No e/o focal lesions.

PANCREAS: It is normal.

RIGHT KIDNEY: It measures 85x42mm with parenchymal thickness of 13 mm. It is normal in size, outline and echotexture. No e/o calculus or hydronephrosis seen.

LEFT KIDNEY: It measures 97x46 mm with parenchymal thickness of 14 mm. It is normal in size, outline and echotexture. No e/o calculus or hydronephrosis seen.

URINARY BLADDER: It is well distended. The UB wall is normal. No calculi seen.

UTERUS: It is anteverted and measures 65x45x56mm with ET= 9mm. It is normal in size, outline and echotexture. No mass lesion.

Rt. OVARY: It measures 31x28 mm. It is normal. No mass lesion seen.


Lt. OVARY: It measures 27x28 mm. It is normal. No mass lesion seen.

RIF: No evidence of focal collection or mass lesion seen. Appendix is not visualized.

OTHERS: No e/o free fluid in the abdomen. No e/o lymphadenopathy. No e/o gut wall thickening. No mass lesion seen in the abdomen.

IMPRESSION: NORMAL STUDY.

Pradeep Kumar C N, DNB
Consultant Radiologist.



Dr. PRADEEP KUMAR C N
MBBS DNB(RADIOLOGY)
Radiology

Date : 13-01-2024
MR NO : CMYS.0000059241
Name : Mrs. Bhavyashree N S
Age/ Gender : 38 Y / Female

Department : GENERAL
Doctor :
Registration No : Dr. Aravind Kumar K
Qualification :

Consultation Timing: 09:37

Height : 1.57	Weight : 54.7	BMI :	Waist Circum :
Temp :	Pulse :	Resp :	B.P : 120/70

General Examination /
Allergies History

Clinical Diagnosis & Management Plan

Came for regular health check

Ear Bilateral TM. Normal

nose. Nasal mucosa @

oral cavity & oropharynx @

neck @

to
breast

Follow up date :

Doctor Signature

Apollo Clinic
23, 1st Floor,
Kalidasa Road, Mysore - 02
Ph : 0821-4006040/41

Da
MI
Na
Ag
Co

Date : 13-01-2024
MR NO : CMYS.0000059241
Name : Mrs. Bhavyashree N S
Age/ Gender : 38 Y / Female

Department : GENERAL Dietetics
Doctor : Madhura . B. P
Registration No :
Qualification : M.Sc Nutrition & Dietetics
PhD

Consultation Timing: 09:37

TBW - 54kg

Height : 157	Weight : 57.7	BMI : 23.6 kg/m ²	Waist Circum : 120/72
Temp :	Pulse :	Resp :	B.P : 120/72

General Examination /
Allergies History

LPL - 117.87

Clinical Diagnosis & Management Plan

- ⇒ Advised Balanced diet with fiber rich foods.
- ⇒ Use skimmed / toned milk instead of whole fat milk
- ⇒ chart is given.

Follow up date :

Doctor Signature
B. P

13/01/2024

Apollo Clinic
23, 1st Floor,
Kaldasa Road, Mysore - 02
Ph : 0821-4006040/41

Da
MF
Na
Ag
Co

Date : 13-01-2024
MR NO : CMYS.0000059241
Name : Mrs. Bhavyashree N S
Age/ Gender : 38 Y / Female

Department : GENERAL
Doctor :
Registration No :
Qualification :

Consultation Timing: 09:37

Height : 157	Weight : 57.7	BMI :	Waist Circum :
Temp :	Pulse :	Resp :	B.P : 120 / 70

General Examination /
Allergies History

Clinical Diagnosis & Management Plan

PH → NS

PH → DM +, hypertension +
hypothyroid +.

slam - orfmal study.

PH → regular walk
imp → 19/12/23.

ole - ~~coronary~~

adv: regular walk/yoga.
avoid junk food.

ML → 15 yrs. Bal2
FTND8.
subclomised
8 yrs.
bauc.

Follow up date :

Amr

Doctor Signature

Apollo Clinic
23, 1st Floor,
Kalidasa Road, Mysore - 02
Ph : 0821-4006040/41

D
M
N
A
C

Date : 13-01-2024
MR NO : CMYS.0000059241
Name : Mrs. Bhavyashree N S
Age/ Gender : 38 Y / Female

Department : GENERAL
Doctor : ROHITH.H.K.
Registration No :
Qualification :

Consultation Timing: 09:37

Height : 157	Weight : 57.7	BMI :	Waist Circum :
Temp :	Pulse :	Resp :	B.P : 120/70

General Examination /
Allergies History

Clinical Diagnosis & Management Plan

Pt. came for Annual Health Checkup
No febrile complaints
No h/o DM, HTN.



Follow up date :

Doctor Signature
Apollo Clinic
23, 1st Floor,
Kallidasa Road, Mysore - 02
Ph : 0821-4006040/41

Date : 13-01-2024
R NO : CMYS.0000059241

Department : GENERAL
Doctor :

Name : Mrs. Bhavyashree N S
Age/ Gender : 38 Y / Female

Registration No :
Qualification :

Consultation Timing: 09:37

Height : 157	Weight : 57.3	BMI :	Waist Circum :
Temp :	Pulse :	Resp :	B.P : 120/70

General Examination /
Allergies History

Clinical Diagnosis & Management Plan

	<u>Rt eye</u>	<u>lf eye</u>
Near vism.	N6	? cataract blurred vims.
Distant vism.	6/6	blurred vims.
Colour vism.	(R)	(R)

Follow up date :

Doctor Signature

Apollo Clinic
23, 1st Floor,
Kalidasa Road, Mysore - 02
Ph : 0821-4006040/41

Patient's Name : Mrs Bhavyashree	Age & Sex; 38Yrs /Female
Date : 13.01.2024	UHID No:59241

2D ECHOCARDIOGRAPHY STUDY

Impression:

- > Normal chambers and valves
- > No regional wall motion abnormality
- > Normal left ventricular systolic function. EF 66 %
- > No clots. No pericardial effusion

Findings

Left Ventricle:	No RWMA
Right Ventricle	Normal
Left Atrium	Normal
Right Atrium	Normal
Aorta	Normal
Pulmonary Artery	Normal
IAS	Intact
IVS	Intact
Valves	Normal
Pericardium	Normal
Doppler	Normal

Apollo Health and Lifestyle Limited

(CIN: URS110TG2000PLC115819)

Regd. Office: 110/60-62, Ashoka Raghupathi Chambers, 5th Floor, Begumpet, Hyderabad, Telangana - 500 016


Ph. No: (040) 4904 7777 Fax No: 4904 7744 | Email ID: enquiry@apollohl.com | www.apollohl.com

APOLLO CLINICS NETWORK KARNATAKA

Bangalore | Basavanagudi | Bellandur | Electronic City | Fraser Town | HSR Layout | Indira Nagar | JP Nagar | Kundalahalli |
Koramangala | Sarjapur Road | **Mysore** | VV Mohalla |

Online appointments: www.apolloclinic.com

TO BOOK AN APPOINTMENT

 **1860 500 7788**



Apollo Clinic
Expertise. Closer to you.

Patient Name	: Mrs. Bhavyashree N S	Age	: 38 Y F
UHID	: CMYS.0000059241	OP Visit No	: CMYSOPV121327
Reported on	: 13-01-2024 16:43	Printed on	: 13-01-2024 16:53
Adm/Consult Doctor	:	Ref Doctor	: SELF

DEPARTMENT OF RADIOLOGY

X-RAY CHEST PA

Both lung fields and hila are normal .

No obvious active pleuro-parenchymal lesion seen .

Both costophrenic and cardiophrenic angles are clear .

Both diaphragms are normal in position and contour .

Thoracic wall and soft tissues appear normal.

IMPRESSION :NORMAL STUDY.

Pradeep

Printed on:13-01-2024 16:43

---End of the Report---

Dr. PRADEEP KUMAR C N
MBBS DNB(RADIOLOGY)
Radiology

Apollo Health and Lifestyle Limited

CIN: U65110TG2000PSE115819

Regd Office: 1-10-60-92, Kotha Raghupathi Chambers, 5th Floor, Begumpet, Hyderabad, Telangana - 500 016

Ph No: 040-4564 7777 Fax No: 4964 7744 | Email: enquiry@apolloh.com | www.apolloh.com

APOLLO CLINICS NETWORK KARNATAKA

Bangalore: Sarvejanika | Bellandur | Electronic City | Frazer Town | HSR Layout | Indira Nagar | JP Nagar | Kundalahalli

Koramangala | Sarjapur Road | Wysega | YV Mohalla

Online appointments: www.apolloclinic.com

TO BOOK AN APPOINTMENT

1860 500 7788

Scanned with CamScanner



Apollo Clinic
Expertise. Closer to you.

Patient Name	: Mrs. Bhavyashree N S	Age	: 38 Y F
UHID	: CMYS.0000059241	OP Visit No	: CMYSOPV121327
Reported on	: 13-01-2024 16:43	Printed on	: 13-01-2024 16:53
Adm/Consult Doctor	:	Ref Doctor	: SELF

DEPARTMENT OF RADIOLOGY

X-RAY CHEST PA

Both lung fields and hila are normal .

No obvious active pleuro-parenchymal lesion seen .

Both costophrenic and cardiophrenic angles are clear .

Both diaphragms are normal in position and contour .

Thoracic wall and soft tissues appear normal.

IMPRESSION :NORMAL STUDY.

Pradeep

Printed on:13-01-2024 16:43

---End of the Report---

Dr. PRADEEP KUMAR C N
MBBS DNB(RADIOLOGY)
Radiology

Apollo Health and Lifestyle Limited

ICPA URS110TG2000PLC1158191
Regd. Office: 11D-60-62, Ashoka Raghupathi Chambers, 5th Floor, Begumpet, Hyderabad, Telangana - 500 016
Ph. No: (041) 4904 7777 Fax No: 4904 7744 | Email ID: enquiry@apollohl.com | www.apollohl.com

APOLLO CLINICS NETWORK KARNATAKA

Bangalore | Basavanagudi | Bellandur | Electronic City | Fraser Town | HSR Layout | Indra Nagar | JP Nagar | Kundalahalli |
Koramangala | Sarjapur Road | **Mysore** | VV Mohalla

Online appointments: www.apolloclinic.com

TO BOOK AN APPOINTMENT

1860 500 7788

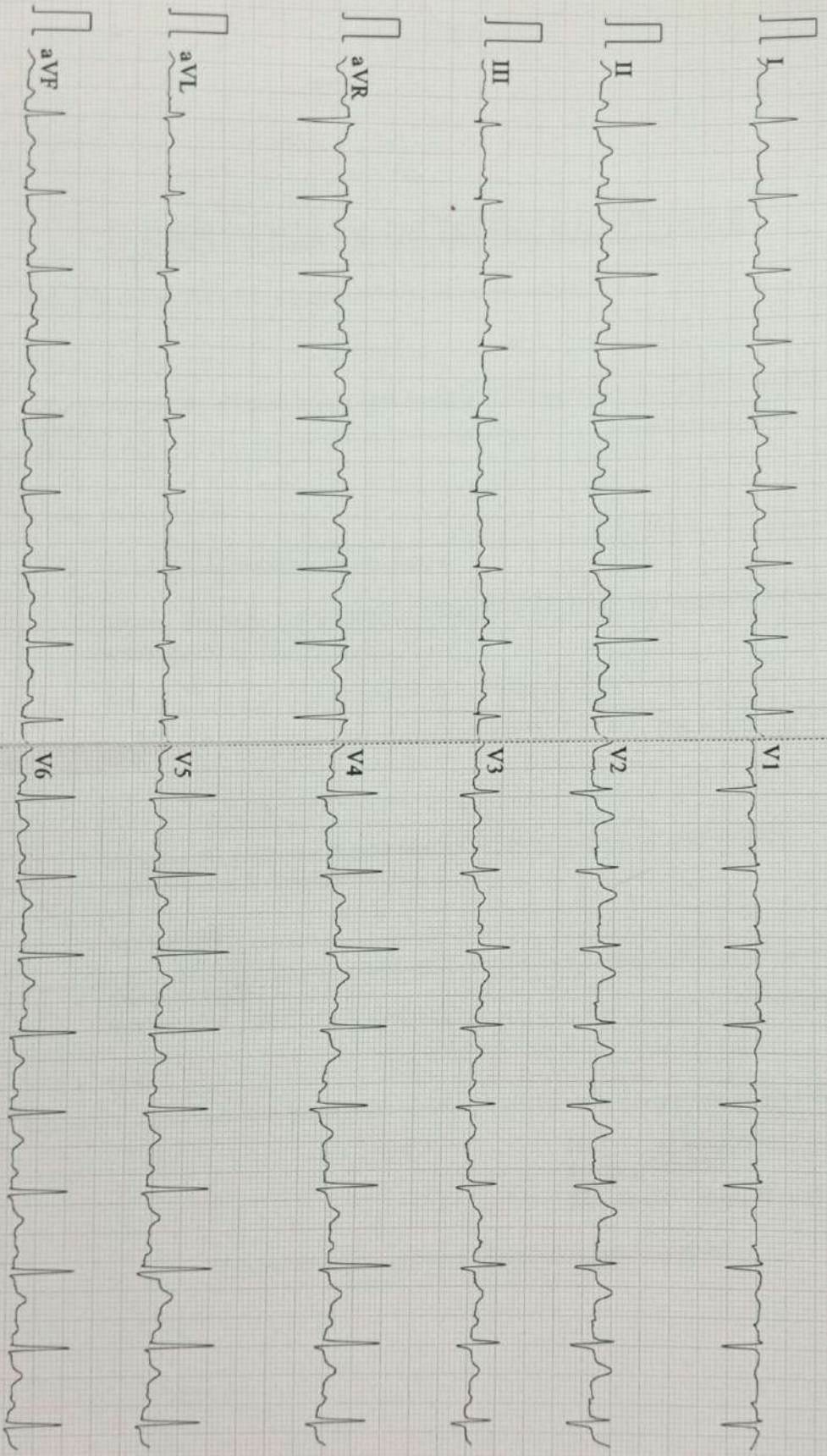
Scanned with CamScanner

ID: 59241
MRS BHAVYASHREE N S
Male 38Years
157cm 57kg 120/70 mmHg

13-01-2024 12:22:20 PM

Diagnosis Information:

Unconfirmed Report.



0.5-45Hz AC50 25mm/s 10mm/mV 2*5.0s 109 CARDIART

D V1.43 Glasgow V28.6.0 APOLLO CLINIC MYSURU


CERTIFICATE OF MEDICAL FITNESS

This is to certify that I have conducted the clinical examination

of _____ on _____

After reviewing the medical history and on clinical examination it has been found that he/she is

	Tick
<ul style="list-style-type: none"> • Medically Fit 	<input checked="" type="checkbox"/>
<ul style="list-style-type: none"> • Fit with restrictions/recommendations <p>Though following restrictions have been revealed, in my opinion, these are not impediments to the job.</p> <p>1.....</p> <p>2.....</p> <p>3.....</p> <p>However the employee should follow the advice/medication that has been communicated to him/her.</p> <p>Review after _____</p>	<input type="checkbox"/>
<ul style="list-style-type: none"> • Currently Unfit. <p>Review after _____ recommended</p>	<input type="checkbox"/>
<ul style="list-style-type: none"> • Unfit 	<input type="checkbox"/>

Dr. 
 Medical Officer
 The Apollo Clinic, Mysore.

This certificate is not meant for medico-legal purposes

Name-
Age-
Height-
Weight-
BMI-

HBW-


Department- Dietetics

Name- Madhura B P

Qualification- M.Sc Nutrition & Dietetic

PhD*

- ~~Advised~~
- Do not skip any of the meals, take small frequent meals.
- Include all variety of seasonal fruits, vegetables and green leafy vegetables on regular basis.
- Include nuts like Almond, Walnuts and dry-fruits like dried dates and raisins regularly.
- Include seeds like Flax seeds, Pumpkin seeds, Sunflower seeds, Sesame seeds and watermelon seeds- 1 teaspoon each and dry roasted.
- Avoid 5 white slow poisons like Sugar, Salt, Maida, Baking soda and creams.
- Cooking oil- ½ litre/person/month.
- Use combination of oils like Rice bran oil, Groundnut oil, Sesame oil, Mustard oil/ Coconut oil and Ghee. Change the oil every month or 2 months. But do not mix the oils.
- Drink at least 2-3 liters of water in a day.
- Skimmed or toned milk can be used on regular basis. Since it's a rich source of protein and low in calories.
- Avoid Butter, Vanaspati and Dalda.
- Avoid deep-fried foods, Biscuits, Cookies, Bakery products, Pastries, Papad, packed and processed foods, chocolates, Alcohol, caffeine and carbonated beverages.
- Avoid junk foods like Pizza and Burger.

Dietician signature  B-P
13/01/2024

Patient Name: Mrs. Bhavyashree N S	Date : 13.01.2024	Referring Doctor: Dr .Self
Age / Sex: 38 Yrs/Female	UHID NO: 59241	Location : OP
ULTRASONOGRAPHY- ABDOMEN & PELVIS		

LIVER: It is normal in size and echotexture. No focal lesions seen. IHBR are not dilated. CBD and Portal vein are normal.

GALL BLADDER: It is well distended and normal. No calculi seen.

SPLEEN: It is normal in size, outline and echopattern. No e/o focal lesions.

PANCREAS: It is normal.

RIGHT KIDNEY: It measures 85x42mm with parenchymal thickness of 13 mm. It is normal in size, outline and echotexture. No e/o calculus or hydronephrosis seen.

LEFT KIDNEY: It measures 97x46 mm with parenchymal thickness of 14 mm. It is normal in size, outline and echotexture. No e/o calculus or hydronephrosis seen.

URINARY BLADDER: It is well distended. The UB wall is normal. No calculi seen.

UTERUS: It is anteverted and measures 65x45x56mm with ET= 9mm. It is normal in size, outline and echotexture. No mass lesion.

Rt. OVARY: It measures 31x28 mm. It is normal. No mass lesion seen.

Lt. OVARY: It measures 27x28 mm. It is normal. No mass lesion seen.

RIF: No evidence of focal collection or mass lesion seen. Appendix is not visualized.

OTHERS: No e/o free fluid in the abdomen. No e/o lymphadenopathy. No e/o gut wall thickening. No mass lesion seen in the abdomen.

IMPRESSION: NORMAL STUDY.

Pradeep
Dr. Pradeep Kumar C N, DNB
Consultant Radiologist.

Patient Name : Mrs. Bhavyashree N S

Age/Gender : 38 Y/F

UHID/MR No. : CMYS.0000059241

OP Visit No : CMYSOPV121327

Sample Collected on :

Reported on : 13-01-2024 16:44

LRN# : RAD2207691

Specimen :

Ref Doctor : SELF

Emp/Auth/TPA ID : 898942899820

DEPARTMENT OF RADIOLOGY

X-RAY CHEST PA

Both lung fields and hila are normal .


No obvious active pleuro-parenchymal lesion seen .

Both costophrenic and cardiophrenic angles are clear .

Both diaphragms are normal in position and contour .

Thoracic wall and soft tissues appear normal.

IMPRESSION :NORMAL STUDY.



Dr. PRADEEP KUMAR C N
MBBS DNB(RADIOLOGY)
Radiology