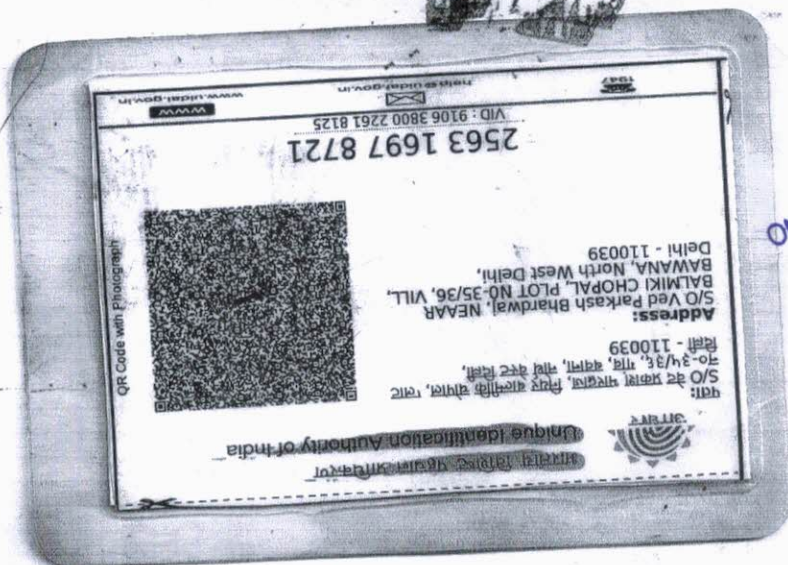


Vipul

Dr. NITIN AGARWAL
MBBS, MD
Regn. No. DMC-R-1436



ONEPLUS ULTRASOUND LAB
47, Harsh Vihar, Pitam Pura,
Delhi-110034
Ph. 011-42480101, 9559913051
E-mail: oneplusul@gmail.com



Dipul



Dr. NITIN AGARWAL
MBBS, MD
Regn. No. DMC-R-1436

ONEPLUS ULTRASOUND LAB
47, Harsh Vihar, Pitam Pura,
Delhi-110034
Ph. 011-42480101, 9599913051
E-mail: oneplusul@gmail.com

ONEPLUS ULTRASOUND LAB

47, HARSH VIHAR, PITAMPURA, DELHI- 110034

Mr. VIPUL

Age : 26/M
Ref. by : MEDIWHEEL
Indication1 :
Indication2 :
Indication3 :
COMMENTS :

ID : 2083

Ht/Wt : 166/72
Recorded : 25-1-2023 9:20
Medication1 :
Medication2 :
Medication3 :

BPM : 102
BP : 136/86
P Axis : 77 deg
QRS Axis : 85 deg
T Axis : 46 deg

P duration : 90 msec
PR duration : 150 msec
QRS duration : 106 msec
QT interval : 296 msec
QTc interval : 369 msec

Raw E.C.G.(Seq)

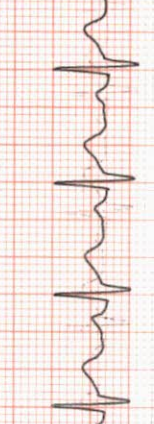
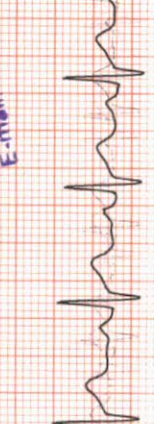
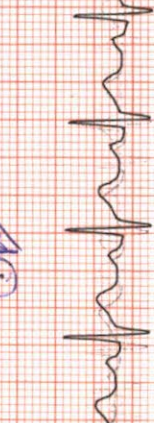
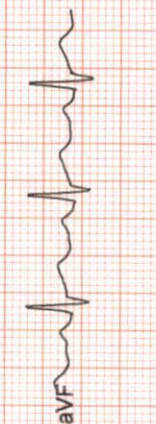
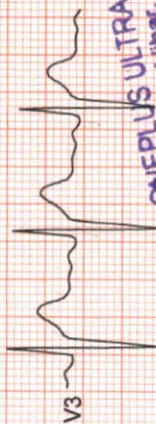
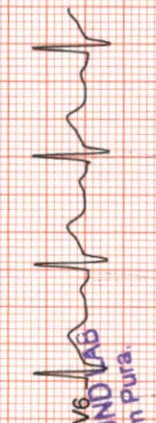
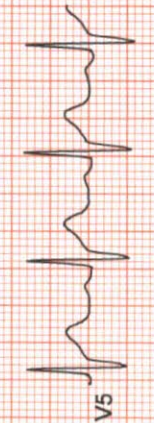
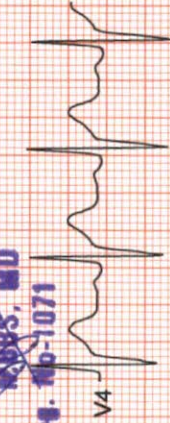
Unconfirmed Report Reviewed By:

Cardiologist

Dr. P. K. GUPTA

MBBS, MD

Reg. No-1071



ONEPLUS ULTRASOUND LAB
47, Harsh Vihar, Pitam Pura,
Delhi-110034
Ph. 011-42480101, 9599913051
E-mail: oneplusul@gmail.com

Filtered

25mm/sec 10mm/mV

CardiCom, INDIA

ONEPLUS ULTRASOUND LAB

47, HARSH VIHAR PITAMPURA DELHI 110034

Mr. VIPUL
Age/Sex : 26/M
Ref. by : MEDIWHEEL
Indication1 :
Indication2 :
Indication3 :

ID : 996
H/Wt : 166/72
Recorded : 25-1-2023 9:22

TREADMILL TEST SUMMARY REPORT
Protocol: BRUGE
History:
Medication1 :
Medication2 :
Medication3 :

PHASE	PHASE TIME	STAGE TIME	SPEED (Km./Hr.)	GRADE (%)	H.R. (BPM)	B.P. (mmHg)	RPP X100	II	ST LEVEL (mm) V2	V5	METS
STANDING SUPINE					103	136/86	140	1.7	1.8	2.1	
					103	136/86	140	1.7	1.8	2.1	
STAGE 1	2:59	2:59	2.70	10.00	130	136/86	176	2.3	1.4	3.3	4.80
STAGE 2	5:59	2:59	4.00	12.00	143	146/88	208	2.1	1.3	3.6	7.10
STAGE 3	8:14	2:14	5.40	14.00	168	160/90	268	2.7	1.6	4.3	9.27
PEAK EXER	8:14	2:14			168	160/90	268	2.6	1.6	4.2	9.27
RECOVERY	2:59	2:59	0.00	0.00	129	136/86	175	2.2	1.8	2.8	

RESULTS

Exercise Duration : 8:14 Minutes
Max Heart Rate : 168 bpm 86 % of target heart rate 194 bpm
Max Blood Pressure : 160/90 mmHg
Max Work Load : 9.27 METS
Reason of Termination :

Negative for ischemic change

IMPRESSIONS

ONEPLUS ULTRASOUND LAB
47, Harsh Vihar, Pitampura,
Delhi-110034
Ph. 011-42490101, 9599913051
E-mail: oneplusul@gmail.com

Dr. P. K. GUPTA
MBBS, MD
Reg. No. 1071

Cardiologist

ONEPLUS ULTRASOUND LAB

Mr. VIPUL
I.D. : 996
AGE/SEX : 26/M

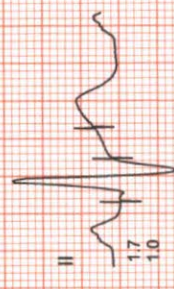
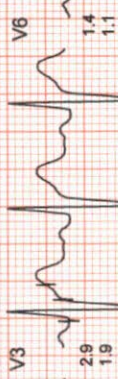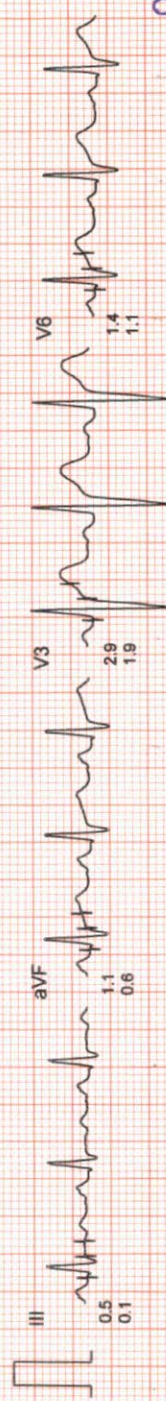
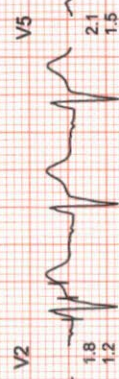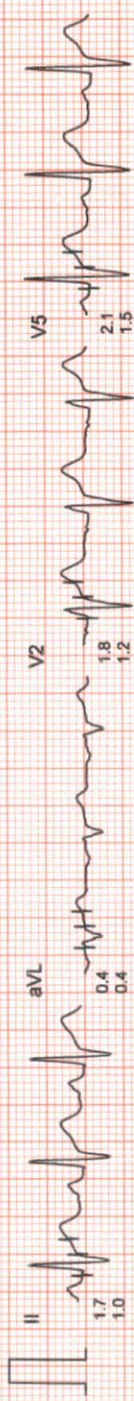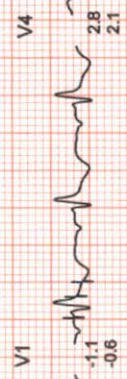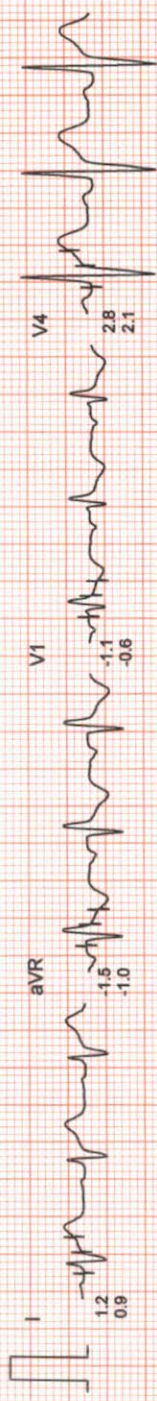
STANDING
PRETEST

ST @ 10mm/mV
80ms PostJ

RATE : 103 BPM
B.P. : 136/86 mmHg

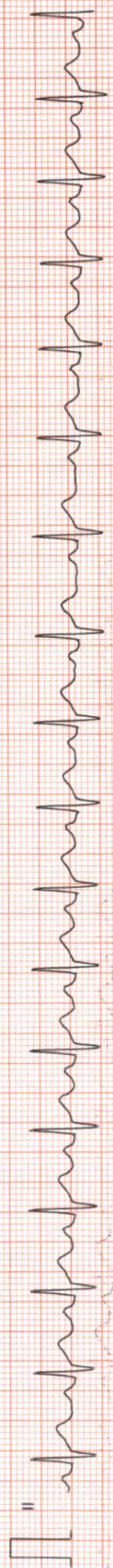RECORDED : 25-1-2023 9:22

LINKED MEDIAN



50mm/sec 20mm/mV

ONEPLUS ULTRASOUND LAB
47, Harsh Vihar, Pitam Pura,
Delhi-110034
Ph. 011-42480101, 9599913051
E-mail: oneplusul@gmail.com



Filtered

Computer Corrected Baseline

25mm/sec 10mm/mV

CardiCom, INDIA Ph.:091-731-2620740, TeleFax:091-731-2431214

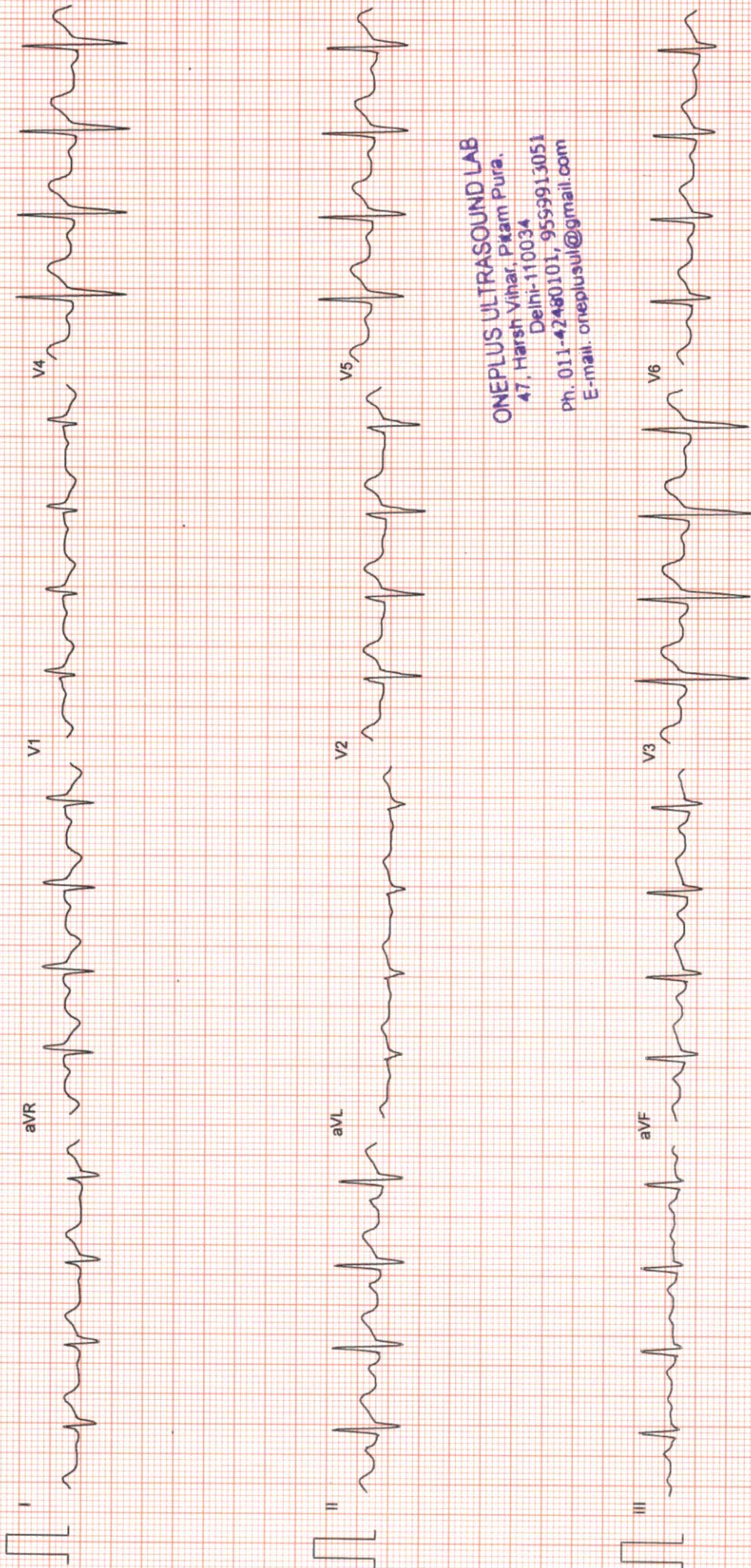
ONEPLUS ULTRASOUND LAB

ST @ 10mm/mV
80ms PostJ

SUPINE
PRETEST

Mr. VIPUL
I.D. : 996
AGE/SEX : 26/M
RECORDED : 25-1-2023 9:22
RATE : 103 BPM
B.P. : 136/86 mmHg

RAW E.C.G.



ONEPLUS ULTRASOUND LAB
47, Harsh Vihar, Pitam Pura,
Delhi-110034
Ph. 011-42480101, 9599913051
E-mail. oneplusul@gmail.com

ONEPLUS ULTRASOUND LAB

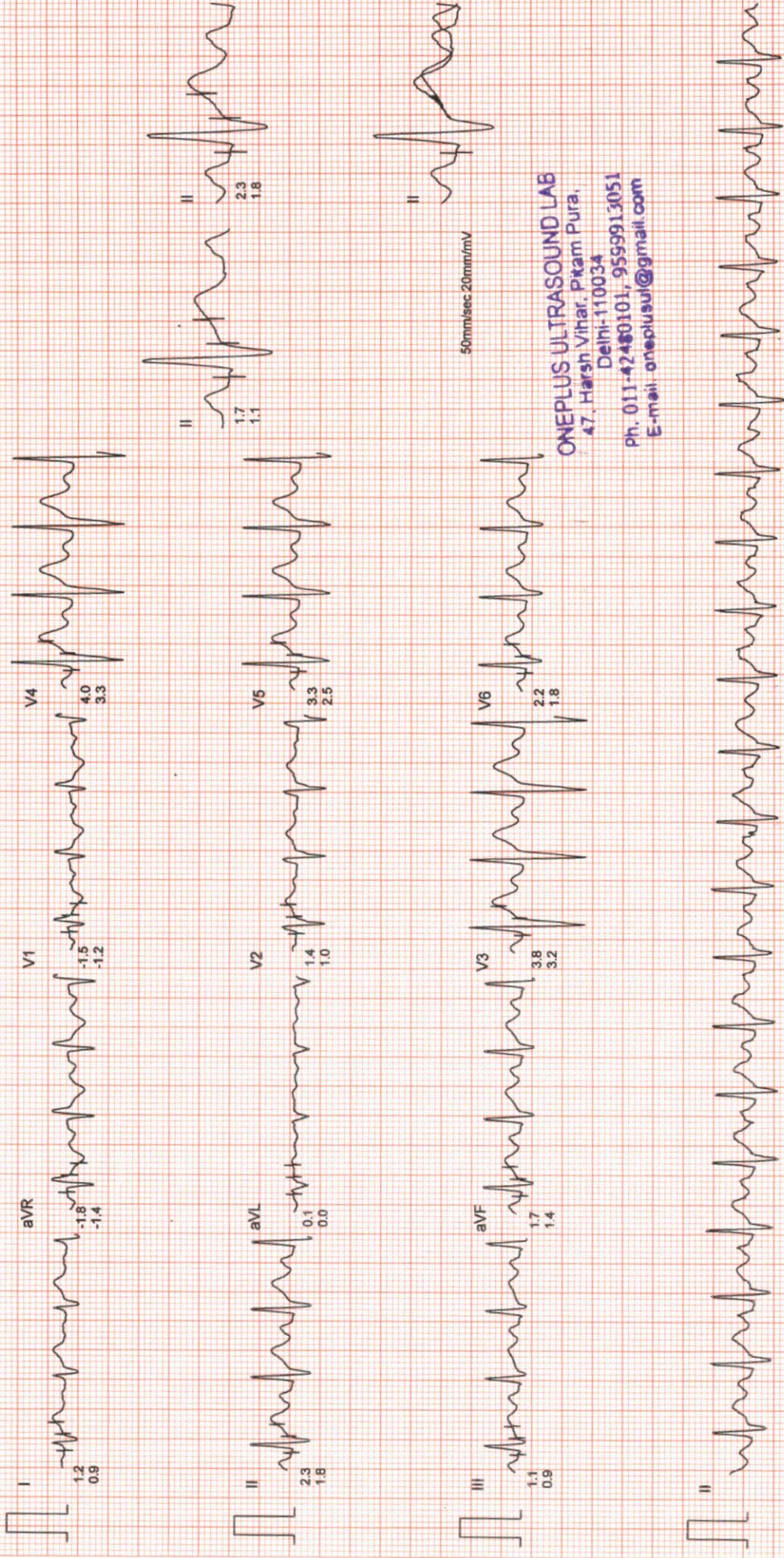
Mr. VIPUL
I.D. : 996
AGE/SEX : 26/M
RECORDED : 25-1-2023 9:22

RATE : 130 BPM
B.P. : 136/86 mmHg

ST @ 10mm/mV
80ms PostJ
SPEED : 2.7 Km./Hr.
GRADE : 10.0 %

BRUCE
EXERCISE 1
PHASE TIME : 2:59
STAGE TIME : 2:59

LINKED MEDIAN



50mm/sec 20mm/mV

ONEPLUS ULTRASOUND LAB
47, Harsh Vihar, Pitam Pura,
Delhi-110034
Ph. 011-4240101, 9599913051
E-mail: onepplusul@gmail.com

25mm/sec 10mm/mV

Computer Corrected Baseline

Filtered

ONEPLUS ULTRASOUND LAB

Mr. VIPUL
I.D. : 996

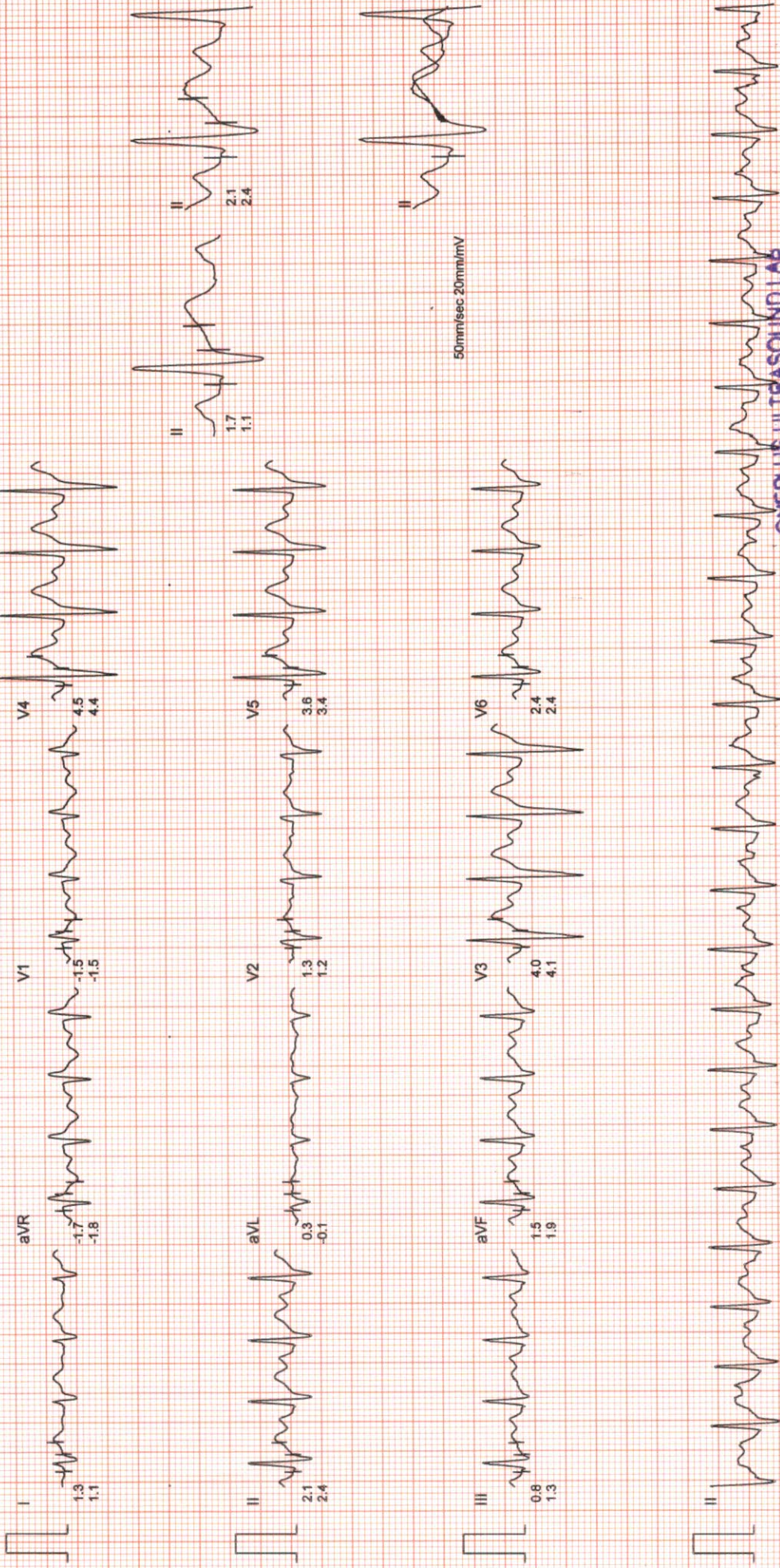
AGE/SEX : 26/M
RECORDED : 25-1-2023 9:22

RATE : 143 BPM
B.P. : 146/88 mmHg

BRUCE
EXERCISE 2
PHASE TIME : 5:59
STAGE TIME : 2:59

ST @ 10mm/mV
80ms PostJ
SPEED : 4.0 Km./Hr.
GRADE : 12.0 %

LINKED MEDIAN



ONEPLUS ULTRASOUND LAB
47, Hersh Vihar, Pitam Pura,
Delhi-110034
Ph. 011-42981101, 9559913051
E-mail: onepul@oneplusultrasound.com

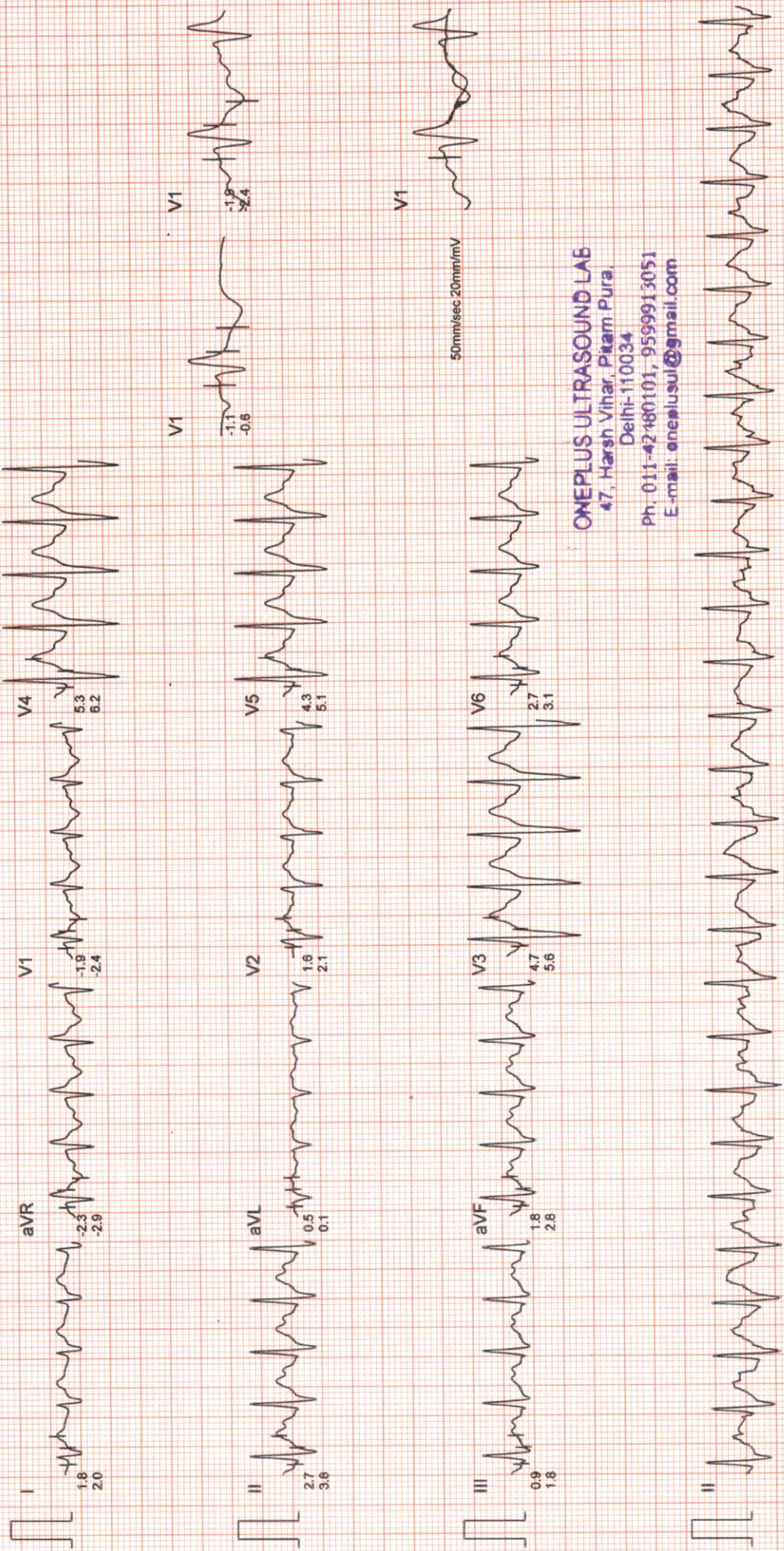
ONEPLUS ULTRASOUND LAB

Mr. VIPUL
I.D. : 996
AGE/SEX : 26/M
RECORDED : 25-1-2023 9:22

BRUCE
EXERCISE 3
PHASE TIME : 8:14
STAGE TIME : 2:14

RATE : 168 BPM
B.P. : 160/90 mmHg

ST @ 10mm/mV
80ms PostJ
SPEED : 5.4 Km./Hr.
GRADE : 14.0 %
LINKED MEDIAN



ONEPLUS ULTRASOUND LAB
47, Harsh Vihar, Pitam Pura,
Delhi-110034
Ph. 011-42480101, 9599913051
E-mail: oneplusul@gmail.com

ONEPLUS ULTRASOUND LAB

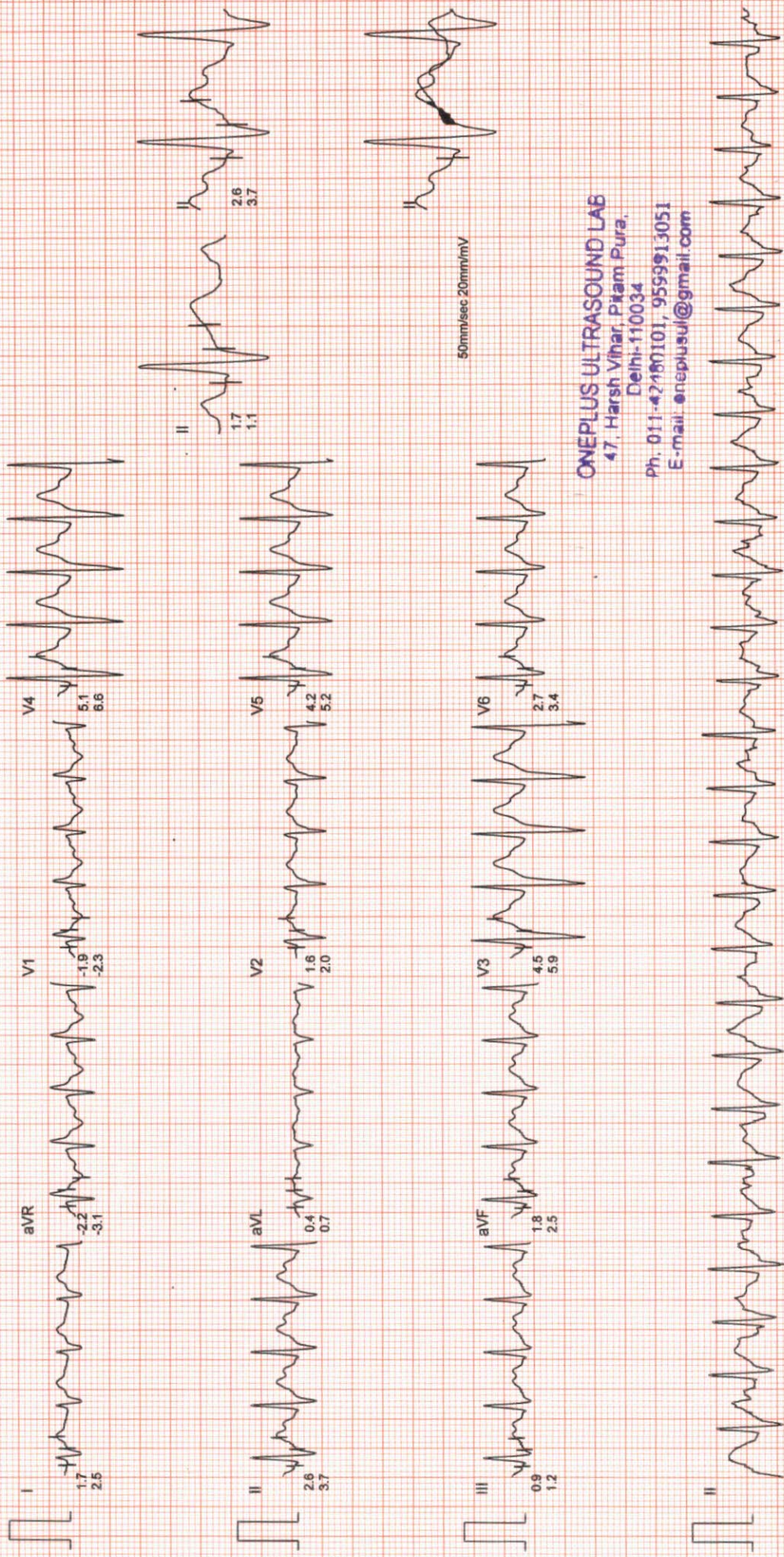
Mr. VIPUL
I.D. : 996
AGE/SEX : 26/M
RECORDED : 25-1-2023 9:22

BRUCE
PEAK EXER
PHASE TIME : 8:14
STAGE TIME : 2:14

RATE : 168 BPM
B.P. : 160/90 mmHg

ST @ 10mm/mV
80ms PostJ
SPEED : 5.4 Km./Hr.
GRADE : 14.0 %

LINKED MEDIAN



50mm/sec 20mm/mV

ONEPLUS ULTRASOUND LAB
47, Harsh Vihar, Pitam Pura,
Delhi-110034
Ph. 011-42190101, 9559913051
E-mail: oneplusul@gmail.com

ONEPLUS ULTRASOUND LAB

Mr. VIPUL
I.D. : 996

AGE/SEX : 26/M

RECORDED : 25-1-2023 9:22

RATE : 129 BPM

B.P. : 136/86 mmHg

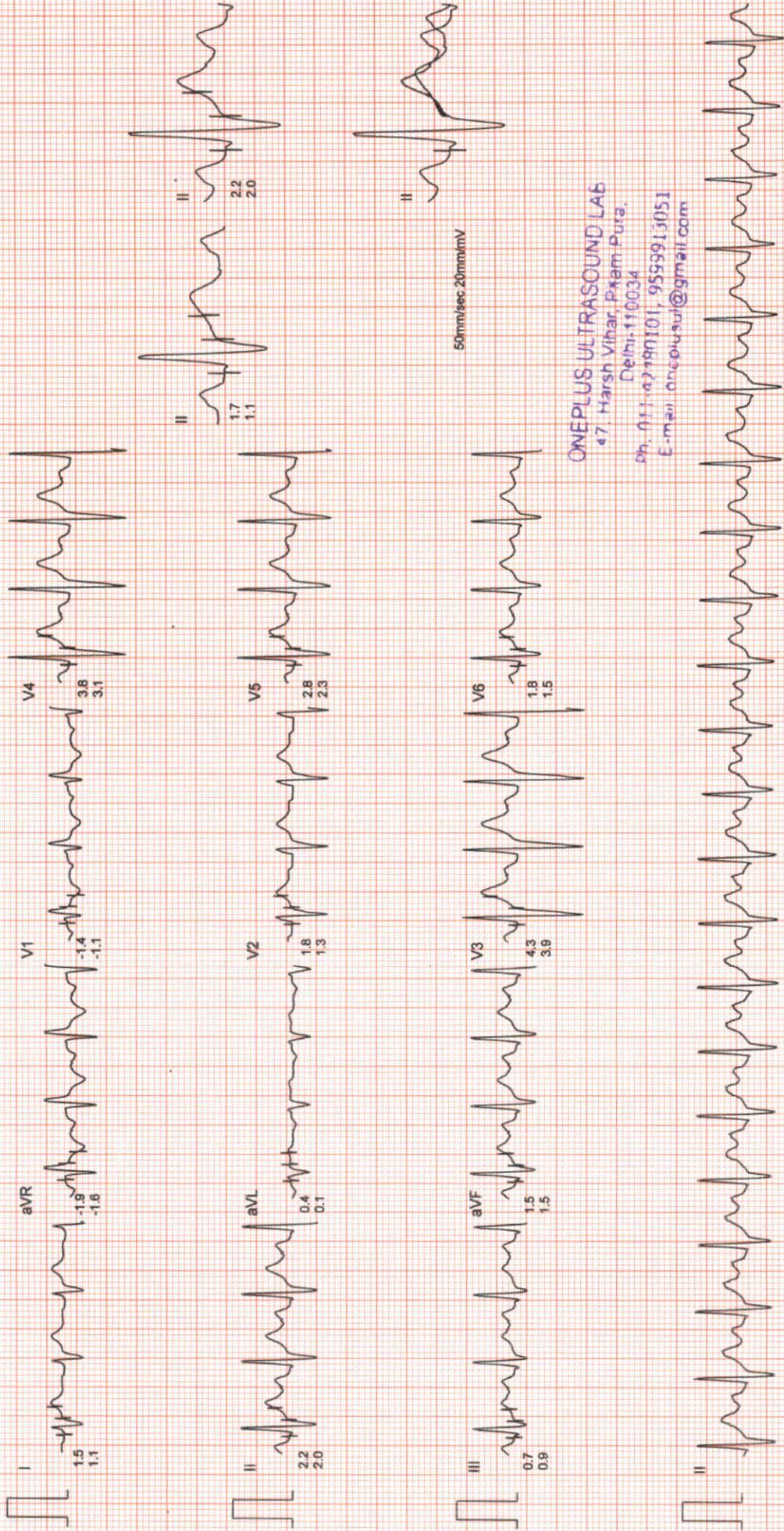
BRUCE
RECOVERY

PHASE TIME : 2:59

ST @ 10mm/mV
80ms PostJ

SPEED : 0.0 Km./Hr.
GRADE : 0.0 %

LINKED MEDIAN



ONEPLUS ULTRASOUND LAB
#7, Harsh Vihar, Patam Pura,
Delhi, 110034
Ph. 011-47780101, 9559913051
E-mail: oneplusul@gmail.com

ONEPLUS ULTRASOUND LAB

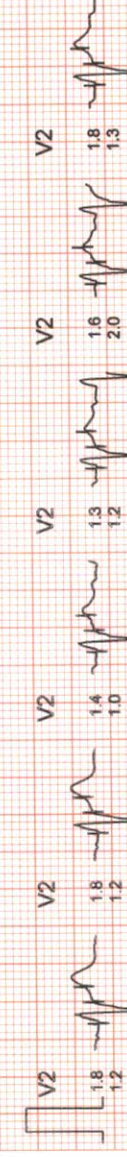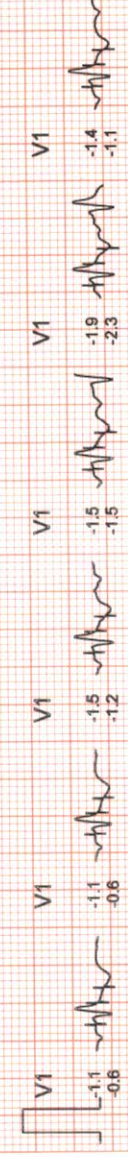
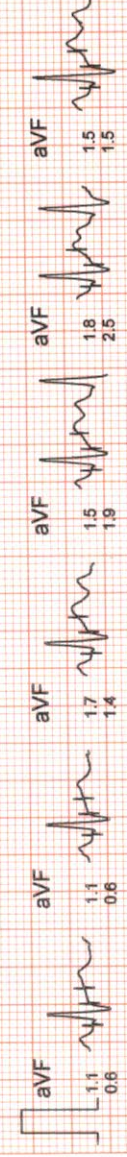
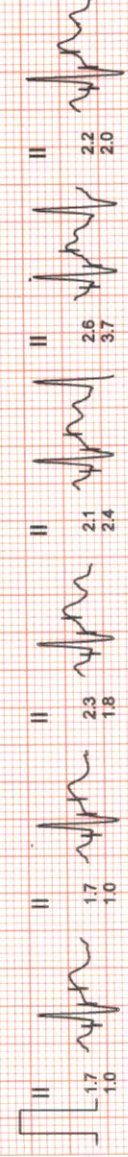
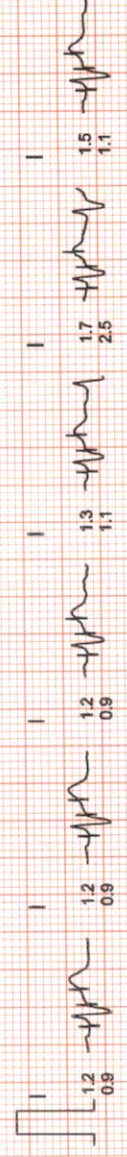
Mr. VIPUL I.D. : 996

AGE/SEX : 26/M

RECORDED : 25- 1-2023 9:22

AVG E.C.G.

STANDING	SUPINE	STAGE 1	STAGE 2	PEAK EXERCISE	RECOVERY
0.0Kmph 0.0% 103 bpm B.P. 136/86 80ms PostJ	0.0Kmph 0.0% 103 bpm B.P. 136/86 80ms PostJ	2.7Kmph 10.0% 130 bpm B.P. 136/86 80ms PostJ	4.0Kmph 12.0% 143 bpm B.P. 146/88 80ms PostJ	8:14 2:14 5.4Kmph 14.0% 168 bpm B.P. 160/90 80ms PostJ	2:59 0.0Kmph 0.0% 129 bpm B.P. 136/86 80ms PostJ



ONEPLUS ULTRASOUND LAB
 #7 HANSA Vihar, Pham pura,
 Delhi-110034
 Ph. no. : 92997101, 9559911157
 Email: oneplusultrasound@gmail.com

ONEPLUS ULTRASOUND LAB

Mr. VIFUL

I.D. : 996


AGE/SEX : 26/M

RECORDED : 25-1-2023 9:22

COMPARISON REPORT


SUPINE

0.0Kmph
0.0%
103 bpm
B.P. 135/86
80ms PostJ



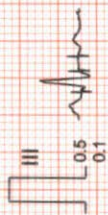
I

1.2
0.8




II

1.7
1.0




III

0.5
0.1




aVR

-1.5
-1.0



aVL

0.4
0.4



aVF

1.1
0.6

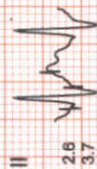PEAK EXERCISE

8:14
2:14
5.4Kmph
14.0%
168 bpm
B.P. 160/90
80ms PostJ



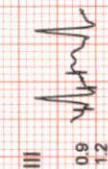
I

1.7
2.5



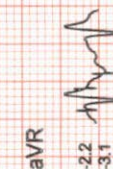
II

2.6
3.7



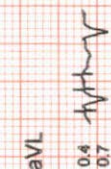
III

0.9
1.2



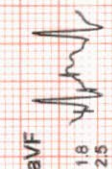
aVR

-2.2
-3.1



aVL

0.4
0.7




aVF

1.8
2.5


SUPINE

0.0Kmph
0.0%
103 bpm
B.P. 135/86
80ms PostJ



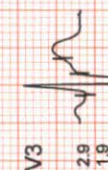V1

-1.1
-0.6



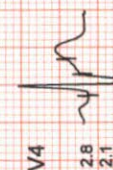V2

1.8
1.2



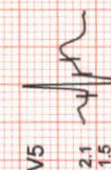V3

2.8
1.9



V4

2.8
2.1



V5

2.1
1.5



V6

1.4
1.1

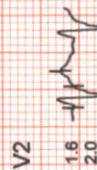
PEAK EXERCISE

8:14
2:14
5.4Kmph
14.0%
168 bpm
B.P. 160/90
80ms PostJ




V1

-1.9
-2.3




V2

1.8
2.0




V3

4.5
5.9



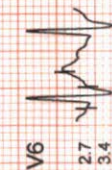V4

5.1
6.6



V5

4.2
5.2



V6

2.7
3.4

ONEPLUS ULTRASOUND LAB
47, Hrish Vihar, Pkham Pura,
Delhi-110034
Ph. 011-42880101, 9599913052
E-mail: onepplusul@gnmvt.com



OnePLUS
Ultrasound Lab

— QUALITY FIRST... ALWAYS! —

Dr. Nitin Agarwal

Pathologist & Director
Ex. Sr. Res. MAMC
& Lok Nayak Hospital
Ex. Chief of Lab Dr. Lal Path Labs.

Dr. Pooja (Garg) Agarwal

Radiologist & Director
MAMC & Lok Nayak Hospital



NAME	:Mr. VIPUL	Barcode No	:10136462
AGE/GENDER	:26 YRS/Male	SPECIMEN DATE	:25/Jan/2023 10:31AM
PATIENT ID	:108204	SPECIMEN RECEIVED	:25/Jan/2023 10:56AM
REFERRED BY	:Dr. MEDIWHEEL	REPORT DATE	:25/Jan/2023 03:36PM
CENTRE NAME	:ONEPLUS ULTRASOUND LAB	LAB NO.	:012301250029

Test Name	Result	Unit	Ref. Range
-----------	--------	------	------------

HAEMATOLOGY

Medi Wheel Health checkup 2 Female

Glycosylated Hemoglobin (HbA1c)	5.5	%	Non Diabetic adults <5.7 Prediabetic (at risk) 5.7-6.4 Diabetes >6.4
--	-----	---	--

Estimated average blood glucose (eag)	111
--	-----

Reference range (mg/dl):

90 - 120:Excellent control, 121 - 150:Good Control, 151 - 180:Average Control, 181 - 210:Action Suggested

>211:Panic value

BLOOD GROUP (ABO)	B
Rh typing	POSITIVE

NOTE :

- * Apart from major A,B,H antigens which are used for ABO grouping and Rh typing, many minor blood group antigens exist. Agglutination may also vary according to titre of antigen and antibody.
- * So before transfusion, reconfirmation of blood group as well as cross-matching is needed.
- * Presence of maternal antibodies in newborns, may interfere with blood grouping.
- * Auto agglutination (due to cold antibody, falciparum malaria, sepsis, internal malignancy etc.) may also cause erroneous result.

CBC

Haemoglobin	16.5	g/dl	13.0-17.0
Total Leucocyte Count	7600	/cumm	4000-10000
Differential leucocyte count			
Neutrophils	61	%	40-80
Lymphocyte	32.60	%	20-40
Monocytes	4.00	%	2-10
Eosinophils	2.0	%	1-6
Basophils	0.4	%	0-2
RBC Count	5.80	million/cumm	4.5 - 5.5

Checked By.

DR. NITIN AGARWAL
MBBS, MD (PATHOLOGIST)
DMC/R/01906

47, Harsh Vihar, Pitampura, New Delhi-110034 | Ph.: 011-42480101, 9599913051

E-mail: oneplusul@gmail.com | Web.: www.oneplusul.in

Page 1 of 5



OnePLUS Ultrasound Lab

— QUALITY FIRST... ALWAYS! —

Dr. Nitin Agarwal
Pathologist & Director
Ex. Sr. Res. MAMC
& Lok Nayak Hospital
Ex. Chief of Lab Dr. Lal Path Labs.

Dr. Pooja (Garg) Agarwal
Radiologist & Director
MAMC & Lok Nayak Hospital



NAME	:Mr. VIPUL	Barcode No	:10136462
AGE/GENDER	:26 YRS/Male	SPECIMEN DATE	:25/Jan/2023 10:31AM
PATIENT ID	:108204	SPECIMEN RECEIVED	:25/Jan/2023 10:56AM
REFERRED BY	:Dr. MEDIWHEEL	REPORT DATE	:25/Jan/2023 03:36PM
CENTRE NAME	:ONEPLUS ULTRASOUND LAB	LAB NO.	:012301250029

Test Name	Result	Unit	Ref. Range
PCV(Hematocrit)	52.7	%	40-50
MCV	90.2	fL	83-101
MCH	28.3	Pg	27-32
MCHC	31.3	G/dL	32-35
Platelet count	308000	/cumm	150000-450000
RDW-CV	13	%	11.4-14.0
ESR(WESTEGRENs METHOD)	15	mm in 1st hr	0-20

BIOCHEMISTRY

<u>Blood sugar fasting</u>	107	mg/dL	70-110
<u>Blood sugar pp</u>	122	mg/dL	70.0-140.0
<u>Uric acid, serum</u>	4.26	mg/dl	3.5-7.2

LFT(LIVER FUNCTION TEST)

Bilirubin Total	0.56	mg/dl	0.1-1.2
Bilirubin Conjugated	0.23	mg/dl	0-0.4
Bilirubin Unconjugated	0.33	mg/dl	up to 0.7
SGOT (AST)	20	U/L	0-46
SGPT (ALT)	41	U/L	0-49
Alkaline phosphatase	102	U/L	40-129
Gamma glutamyl transpeptidase	28	U/L	10-45
Total Protein	6.9	gm/dl	6.60 - 8.70
Albumin serum	3.9	g/dL	3.0-5.2
Globulin	3.00	gm/dl	1.8-3.4
Albumin/Globulin Ratio	1.30		1.10 - 2.50

LIPID PROFILE

Cholesterol	223	mg/dl	50-200
Triglycerides	78	mg/dL	25-150
HDL Cholesterol	45	mg/dL	40 - 60
LDL cholesterol	162	mg/dL	<130

Checked By.

Dr. NITIN AGARWAL
M B B S , MD (Path)
DMC/R/01436
DR. NITIN AGARWAL
MBBS,MD(PATHOLOGIST)

47, Harsh Vihar, Pitampura, New Delhi-110034 | Ph.: 011-42480101, 9599913051

E-mail: oneplusul@gmail.com | Web.: www.oneplusul.in

Page 2 of 5

Clinical correlation is essential for final diagnosis. • If test results are unsatisfactory please contact personally or on phone. • This report is for perusal of doctors only. • All disputes Subject to Delhi Jurisdiction only. • Not for medicolegal purposes. • All congenital anomalies in a foetus may not be diagnosed in routine obstetric ultrasound.



OnePLUS Ultrasound Lab

— QUALITY FIRST... ALWAYS! —

Dr. Nitin Agarwal
Pathologist & Director
Ex. Sr. Res. MAMC
& Lok Nayak Hospital
Ex. Chief of Lab Dr. Lal Path Labs.

Dr. Pooja (Garg) Agarwal
Radiologist & Director
MAMC & Lok Nayak Hospital



NAME	:Mr. VIPUL	Barcode No	:10136462
AGE/GENDER	:26 YRS/Male	SPECIMEN DATE	:25/Jan/2023 10:31AM
PATIENT ID	:108204	SPECIMEN RECEIVED	:25/Jan/2023 10:56AM
REFERRED BY	:Dr. MEDIWHEEL	REPORT DATE	:25/Jan/2023 03:36PM
CENTRE NAME	:ONEPLUS ULTRASOUND LAB	LAB NO.	:012301250029

Test Name	Result	Unit	Ref. Range
VLDL cholesterol	15.6	mg/dL	5-40
Cholesterol/HDL Ratio	5.0		Low Risk 3.3-4.97 Average Risk 4.4-7.1 Moderate Risk 7.1-11.0 High Risk >11.0
LDL/HDL Ratio	3.6		0 - 3.55

According to ATP III and NCEP guidelines

Parameter	Normal	Desirable	Borderline	High
Total cholesterol	<200		200-239	240
Triglycerides	<150	150-199	200-499	500
LDL	Optimal <100 Near Optimal 100-129	130-159	160-180	190
HDL	<40 : LOW 60 : HIGH			

ENDOCRINOLOGY

THYROID PROFILE(T3,T4,TSH)

Triiodothyronine total [t3]	1.50	ng/dl	0.52-1.9
Thyroxine total [t4]	5.80	µg/dl	4.4 - 10.8
TSH (Thyroid Stimulating Hormone)	0.90	µIU/ml	0.25-5.0

AGE WISE VARIATION IN TSH

AGE	TSH(µIU/ml)	AGE	TSH(µIU/ml)
1-4 weeks	1.00 - 19.0	16-20 yrs	0.25 - 5.0
1-12 mths	1.70 - 9.1	21 - 80 yrs	0.25 - 5.0
1-5 yrs	0.80 - 8.2	I st trimester	0.25 - 5.0
6-10 yrs	0.25 - 5.0	II nd trimester	0.50 - 5.0
11-15 yrs	0.25 - 5.0	II rd trimester	0.4 - 6.0

Checked By.

Dr. NITIN AGARWAL
MBBS, MD (Path)
DMC/R/01430
DR. NITIN AGARWAL
MBBS, MD (PATHOLOGIST)

47, Harsh Vihar, Pitampura, New Delhi-110034 | Ph.: 011-42480101, 9599913051
E-mail: oneplusul@gmail.com | Web.: www.oneplusul.in

Page 3 of 5

Clinical correlation is essential for final diagnosis. • If test results are unsatisfactory please contact personally or on phone. • This report is for perusal of doctors only.
• All disputes Subject to Delhi Jurisdiction only. • Not for medicolegal purposes. • All congenital anomalies in a foetus may not be diagnosed in routine obstetric ultrasound.



OnePLUS
Ultrasound Lab

QUALITY FIRST. ALWAYS!

Dr. Nitin Agarwal
Pathologist & Director
Ex. Sr. Res. MAMC
& Lok Nayak Hospital
Ex. Chief of Lab Dr. Lal Path Labs.

Dr. Pooja (Garg) Agarwal
Radiologist & Director
MAMC & Lok Nayak Hospital



NAME	:Mr. VIPUL	Barcode No	:10136462
AGE/GENDER	:26 YRS/Male	SPECIMEN DATE	:25/Jan/2023 10:31AM
PATIENT ID	:108204	SPECIMEN RECEIVED	:25/Jan/2023 10:56AM
REFERRED BY	:Dr. MEDIWHEEL	REPORT DATE	:25/Jan/2023 03:36PM
CENTRE NAME	:ONEPLUS ULTRASOUND LAB	LAB NO.	:012301250029

Test Name	Result	Unit	Ref. Range
-----------	--------	------	------------

Reference ranges - Interpretation of Diagnostic tests - (Jacques Wallach)

1. Primary hypothyroidism is accompanied by depressed serum T3 and T4 values and elevated serum TSH level.
2. Primary hyperthyroidism is accompanied by elevated serum T3 and T4 levels along with depressed TSH values.
3. Slightly elevated T3 levels may be found in pregnancy and estrogen therapy, while depressed levels may be encountered in severe illness, renal failure and during therapy with drugs like propranolol and propyl thiouracil.
4. Although elevated TSH levels are nearly always indicative of primary hypothyroidism, and may be seen in secondary thyrotoxicosis

CLINICAL PATHOLOGY

URINE ROUTINE

Physical examination

Quantity	25	ML
Colour	PALE YELLOW	
Transparency	CLEAR	CLEAR
Sp.gravity	1.010	1.010-1.030
pH	6.50	
Reaction	ACIDIC	ACIDIC

Chemical examination

Urine protein	NIL	NIL
Urine sugar	NIL	NIL
Bilirubin, urine	NEGATIVE	NEGATIVE
Urobilinogen	NORMAL	NORMAL
Ketones	NEGATIVE	NEGATIVE

Microscopic examination

Pus cells.	1-2	/HPF	0-2
Epithelial cells	0-1	/HPF	NIL
R.B.C.	NIL	/HPF	NIL
Casts	NIL	/HPF	NIL
Crystals	NIL	/HPF	NIL
Bacteria	NIL	/HPF	NIL
Others.	NIL	NIL	NIL

Checked By.

Dr. NITIN AGARWAL
MBBS, MD (Path)
DMC/R/01438
Dr. NITIN AGARWAL
MBBS, MD (PATHOLOGIST)

47, Harsh Vihar, Pitampura, New Delhi-110034 | Ph.: 011-42480101, 9599913051

E-mail: onepusul@gmail.com | Web.: www.oneplusul.in

Page 4 of 5



OnePLUS

Ultrasound Lab

QUALITY FIRST... ALWAYS!

Dr. Nitin Agarwal
 Pathologist & Director
 Ex. Sr. Res. MAMC
 & Lok Nayak Hospital
 Ex. Chief of Lab Dr. Lal Path Labs.

Dr. Pooja (Garg) Agarwal
 Radiologist & Director
 MAMC & Lok Nayak Hospital



NAME	:Mr. VIPUL	Barcode No	:10136462
AGE/GENDER	:26 YRS/Male	SPECIMEN DATE	:25/Jan/2023 10:31AM
PATIENT ID	:108204	SPECIMEN RECEIVED	:25/Jan/2023 10:56AM
REFERRED BY	:Dr. MEDIWHEEL	REPORT DATE	:25/Jan/2023 03:36PM
CENTRE NAME	:ONEPLUS ULTRASOUND LAB	LAB NO.	:012301250029

Test Name	Result	Unit	Ref. Range
STOOL ROUTINE			
Physical examination			
Colour	BROWNISH		
Consistency	SEMI LOOSE		Semi Formed
Blood	ABSENT		Absent
Mucus	ABSENT		Absent
Chemical examination, stool			
pH	6.50		
Microscopic examination			
Pus cells	0-1	/HPF	
R.B.C.	NIL	/HPF	NIL
Ova	NIL		NIL
Cysts	NIL		NIL
Bacteria	PRESENT	/HPF	NIL
Others	NIL		

*** End Of Report ***

Checked By.

Dr. NITIN AGARWAL
 MBBS, MD (Path)
 DMC/R/01436
 DR. NITIN AGARWAL
 MBBS, MD (PATHOLOGIST)

47, Harsh Vihar, Pitampura, New Delhi-110034 | Ph.: 011-42480101, 9599913051
 E-mail: oneplusul@gmail.com | Web.: www.oneplusul.in

Page 5 of 5

47, Harsh Vihar, Pitampura, New Delhi-110034 | Ph.: 011-42480101, 9599913051
E-mail: oneplusul@gmail.com | Web: www.oneplusul.in

Type By : Kusum

DR. POOJA GARG
RADIOLOGIST
REG NO-DMC/R/03398
DR. POOJA GARG
M.B.B.S., D.M.R.D
REG No. DMC/R/03398
Radiologist

Please correlate clinically

Note is made of fatty umbilical hernia.

No free fluid seen anywhere in abdomen.
No abnormal bowel wall thickening seen in right iliac fossa.

Prostate is normal in size, shape and echopattern.
Prostate measures 2.6 x 2.6 x 3.5 cm. Weight of prostate is 12.2 grams.

Urinary bladder is normal in shape and position. No evidence of intravesical stone or mass seen.

Pancreas is normal in size, outline and echotexture.

Spleen is normal in size and echotexture. No mass lesion seen.

Both kidneys are normal in size, shape, position, outline and echopattern. Corticomedullary differentiation is maintained. No pelvic/lycical dilation or mass lesion is seen.

Gall bladder is well distended with anechoic lumen. Wall thickness is normal.

Liver is normal in size (12.5 cm) and normal in outline with normal echopattern. Intrahepatic biliary radicles are not dilated. No abscess or mass lesion seen. Hepatic veins, portal vein, IVC and aorta are normal. CBD is normal (6.8 mm) in caliber.

ULTRASOUND EXAMINATION---WHOLE ABDOMEN

Name	: Mr. VIPUL
Ref. By	: DR. MEDIWHEEL
Date	: 25-Jan-2023
Age/Sex	: 26 YRS/Male
Lab No	: 012301250029
Patient ID	: LSHH1108204

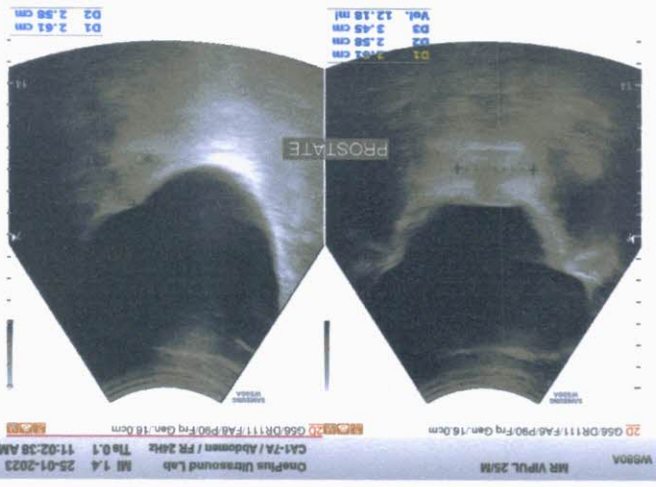
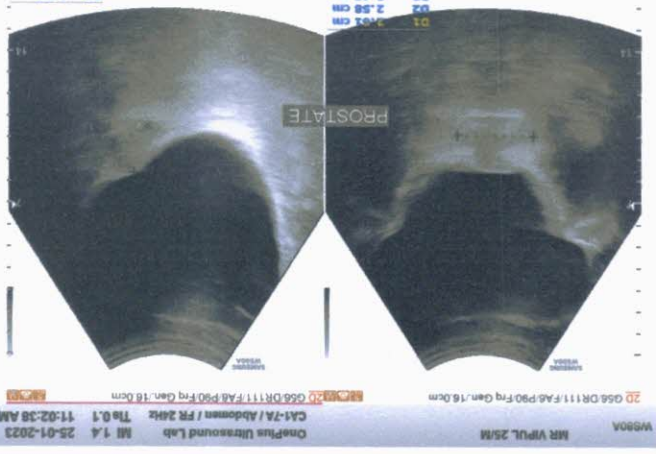

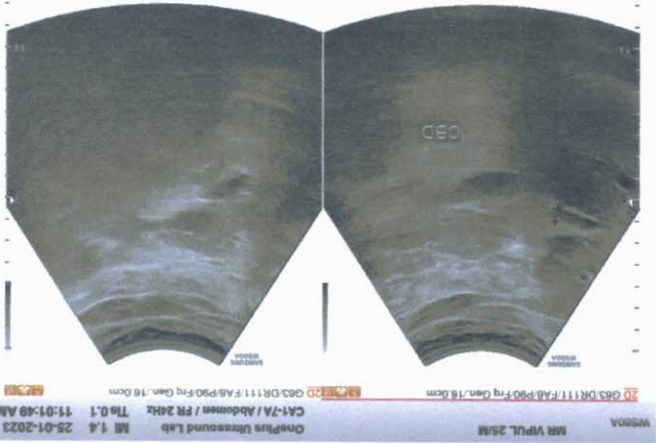
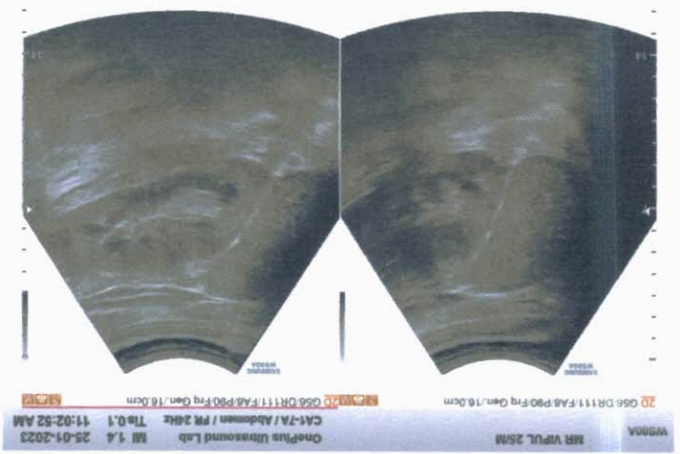
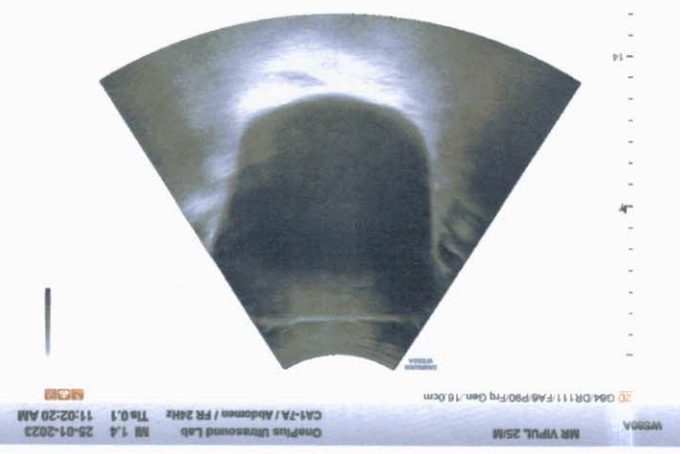
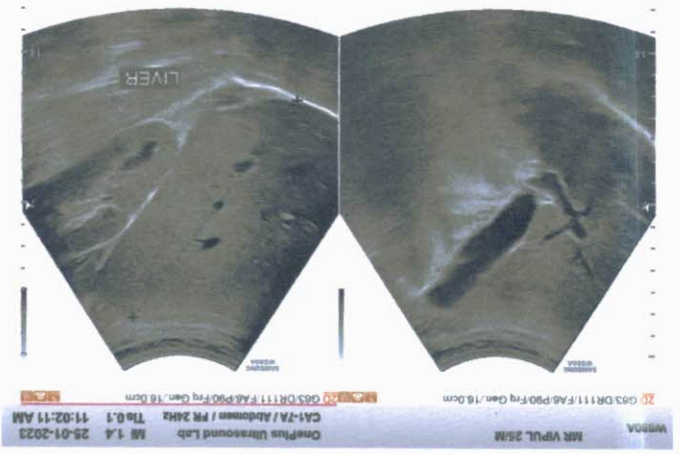
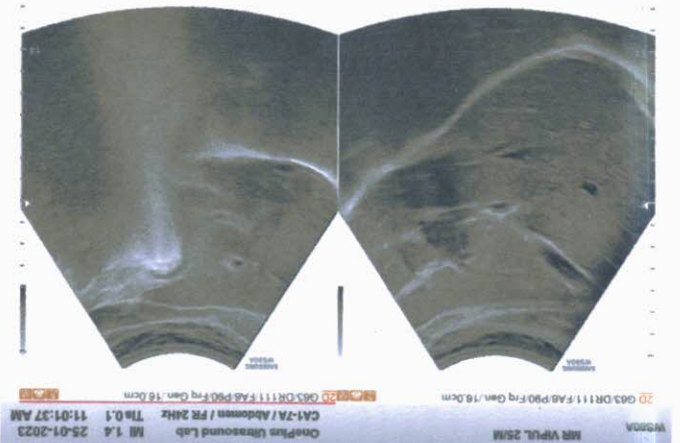
— QUALITY FIRST... ALWAYS! —
Ultrasound Lab
OnePLUS



Dr. Nitin Agarwal | Pathologist & Director
Ex. Sr. Res. MAMC & Lok Nayak Hospital
Ex. Chief of Lab Dr. Lal Path Labs.

Dr. Pooja (Garg) Agarwal | Radiologist & Director
MAMC & Lok Nayak Hospital

Ultrasound Image Report



Vol. 12.18 ml
D1 2.91 cm
D2 2.58 cm
D3 2.45 cm
D4 2.58 cm

Ultrasound Image Report

Page 1 of 1

0505-15-22 3.7 98 0505-15-22 3.7 98
MA 05-15-22 7.0 97 0505-15-22 3.7 98
0505-15-22 3.7 98



0505-15-22

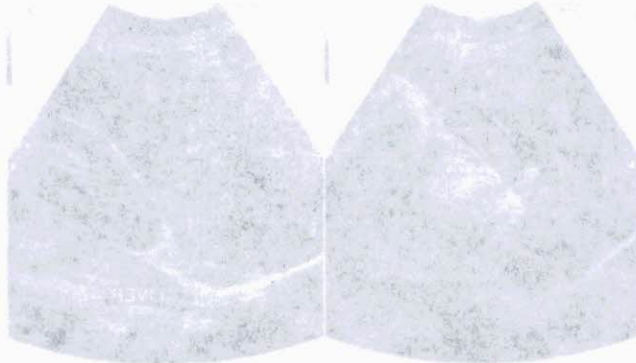
0505-15-22 3.7 98 0505-15-22 3.7 98
MA 05-15-22 7.0 97 0505-15-22 3.7 98
0505-15-22 3.7 98



0505-15-22 3.7 98 0505-15-22 3.7 98
MA 05-15-22 7.0 97 0505-15-22 3.7 98
0505-15-22 3.7 98



0505-15-22 3.7 98 0505-15-22 3.7 98
MA 05-15-22 7.0 97 0505-15-22 3.7 98
0505-15-22 3.7 98



0505-15-22

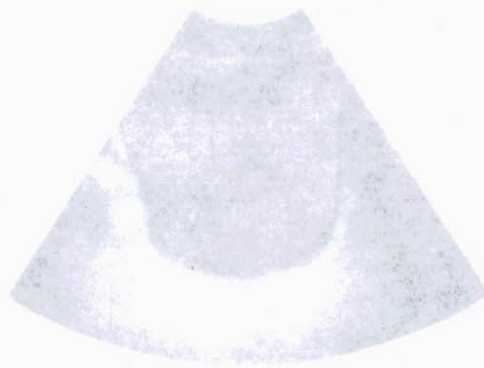0505-15-22 3.7 98 0505-15-22 3.7 98
MA 05-15-22 7.0 97 0505-15-22 3.7 98
0505-15-22 3.7 98



0505-15-22

0505-15-22

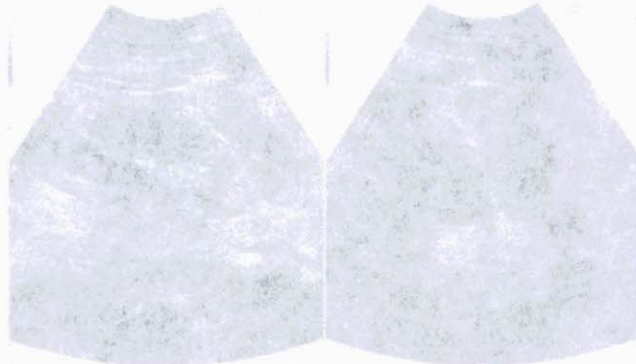0505-15-22 3.7 98 0505-15-22 3.7 98
MA 05-15-22 7.0 97 0505-15-22 3.7 98
0505-15-22 3.7 98



0505-15-22 3.7 98 0505-15-22 3.7 98
MA 05-15-22 7.0 97 0505-15-22 3.7 98
0505-15-22 3.7 98



0505-15-22 3.7 98 0505-15-22 3.7 98
MA 05-15-22 7.0 97 0505-15-22 3.7 98
0505-15-22 3.7 98



47, Harsh Vihar, Pitampura, New Delhi-110034 | Ph.: 011-42480101, 9599913051
E-mail: onepiusul@gmail.com | Web.: www.onepiusul.in

DR. POOJA GARG
RADIOLOGIST
REG NO- DMC/R/03398
DR. POOJA GARG
M.B.B.S., D.M.R.D
Reg No. DMC/R/03398
Radiologist

IMPRESSION: Normal Study.

Bony cage and soft tissues are normal.
Cardiothoracic ratio is normal.
Mediastinum is normal.
Both hila are normal.
Both costophrenic angles are clear.
Both domes of diaphragm are normal.
Lung fields are clear. No parenchymal lesion seen.

X-ray-Chest PA view

Name	: Mr. VIPUL
Ref. By	: Dr. MEDIWHEEL
Date	: 25-Jan-2023
Age/Sex	: 26 YRS/Male
Lab No	: 012301250029
Patient ID	: LSHH1108204

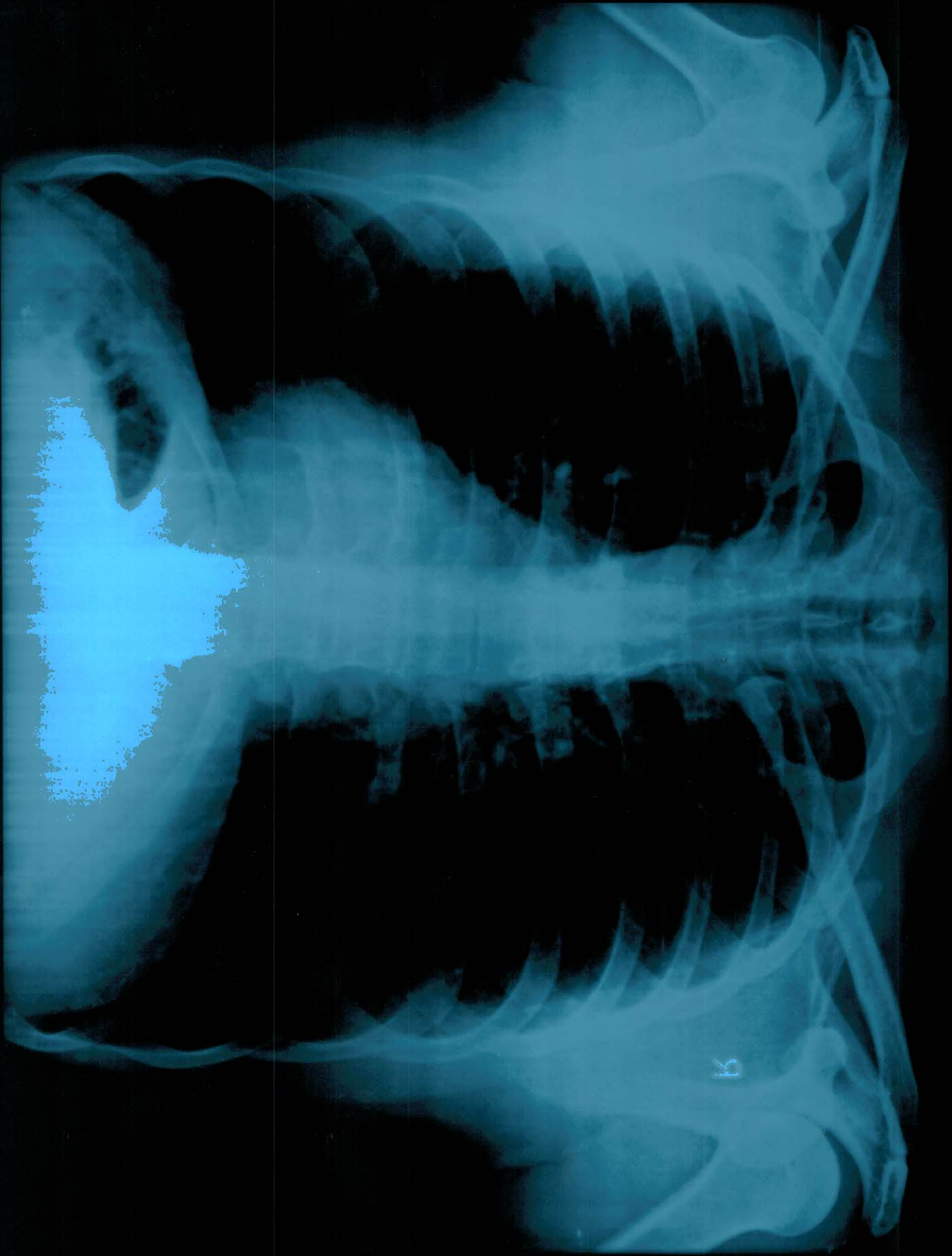
— QUALITY FIRST... ALWAYS! —
OnePLUS
Ultrasound Lab



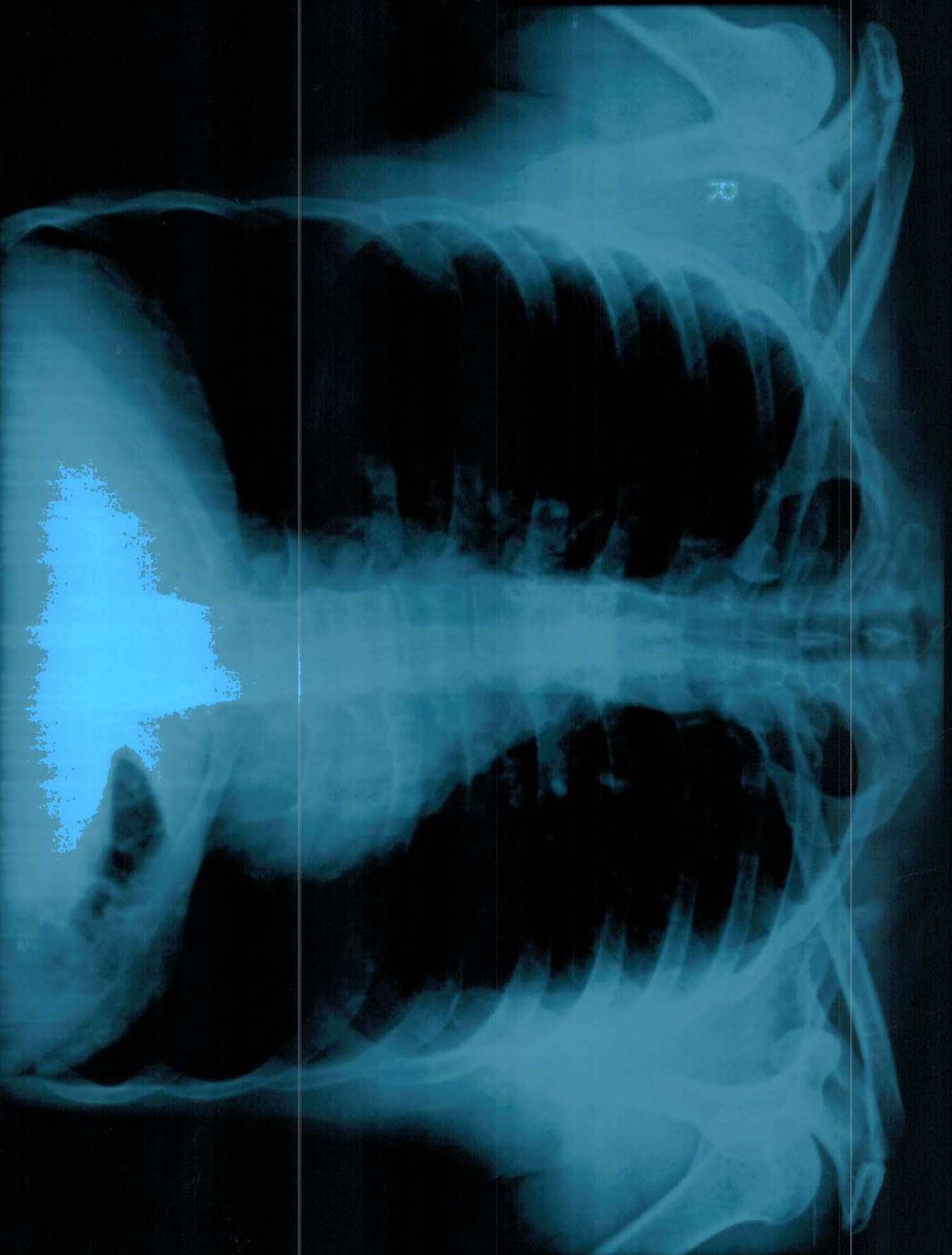
Dr. Nitin Agarwal | Pathologist & Director
Ex. Sr. Res. MAMC
& Lok Nayak Hospital
Ex. Chief of Lab Dr. Lal Path Labs.

Dr. Pooja (Garg) Agarwal | Radiologist & Director
MAMC & Lok Nayak Hospital

ОИЕБГОС ОУТРАГОУИД ГАВ 47 НАРЗН ВНАР ПІТАМЬУБА
МР'АІРІГ ЗЕ УБЗ 52-01-5053 М СЕШТ ПА ВІЕМ 115215053



К



MR VIPUL 26 YRS 25-01-2023 M CHEST PA VIEW 1/25/2023
ONEPLUS ULTRASOUND LAB 47 HARSH VIHAR PITAMPURA