



Savita

Superspeciality Hospital
(A Unit of Solace Healthcare Pvt. Ltd.)

Parivar Char Rasta, Waghodia-Dabhoi Ring Road, Vadodara-390019

☎ 0265-2578844 / 2578849 ✉ mh@savitahospital.com 🌐 savitahospital.com

EXAMINATION BY DENTAL

Name :	AJIT SINGH	Age/Sex:	51/MALE
Reg No :	<u>20230308950</u>	DOE:	11/03/2023

Presenting Complaint :	NO RELEVANT COMPLAIN
-------------------------------	-----------------------------

Medical History :	NAD
--------------------------	------------

Examination :	CALCULES ++ STAIN +
----------------------	--------------------------------------

Impression :	NAD
---------------------	------------

Advice :	SCALING
-----------------	----------------

DR RUSDA MAHEK





PHYSICIAN EXAMINATION

Name :	AJIT SINGH	Age :	51/MALE
Reg.No :	20230308950	DOE :	11/03/2023

Physical Examination:

Height:	177CM	Weight:	60 KG	PULSE:	68	Temperature:	NORMAL
----------------	--------------	----------------	------------------	---------------	-----------	---------------------	---------------

BMI :	19.15	BP :	106/66	SPO2	98%
--------------	--------------	-------------	---------------	-------------	------------

Chief Complaint :	
Past History :	
General Examination :	
Systemic Examination :	
INVESTIGATION :	
ADVICE :	

(PATIENT PERSONALLY REFUSED CONSULTATION)

DR. SAURABH JAIN





Savita

Superspeciality Hospital
(A Unit of Solace Healthcare Pvt. Ltd.)

Parivar Char Rasta, Waghodia-Dabhoi Ring Road, Vadodara-390019

☎ 0265-2578844 / 2578849 ✉ mh@savitahospital.com 🌐 savitahospital.com

Examination By Ophthalmologist

Name :	AJIT SINGH	Age :	51/MALE
Reg.No :	20230308950	DOE :	11/03/2023
Present Complaints :			
Medical History :			
Examination Of Eye :			
External Examination :			
Ati Seg Examination :			
Schiotz Tonometry IOP :			
Fundus :			
Without Glass	Distant Vision :		
	Near Vision :		
With Glass	Distant Vision :		
	Near Vision :		
Colour Vision (With Ishihara Chart) :			
Advice :			

(PATIENT PERSONALLY REFUSED CONSULTATION)

DR CHETAN CHAUHAN





2D ECHO & COLOUR DOPPLER REPORT

Name : AJIT SINGH Age/sex:51 /male Date :11/3/23

Ref by: Dr SAURABH JAIN

Observations :

Normal LV size & normal systolic function. LVEF 60% (Visual)

No RWMA.

No LV diastolic dysfunction.

Mild MR. No MS.

Mild AR. No AS.

Mild TR. Mild PAH. Pasp = 39 mmHg.

Normal sized LA, RA & RV with normal RV systolic function.

Normal MPA. Intact IAS & IVS.

No intracardiac clot & vegetation.

No PDA & Coarctation.

Normal pericardium, no pericardial effusion.

IVC normal.

AO: 25mm LA: 38mm IVS:11/15 mm PW:10/15 mm LVID:41/27 mm

Conclusion :

Normal LV & RV systolic function. LVEF 60 % (visual)

No RWMA.

Mild MR. Mild PAH.



Dr Chirag Sheth

MD, DM. (CARDIOLOGY)

Dr. Krishnakant Sharma

MD, DNB. (CARDIOLOGY)

Dr. Nirav Bhalani.

MD, DNB. (CARDIOLOGY)

51 Years

Rate 66

PR 144

QRSD 96

QT 376

QTc 394

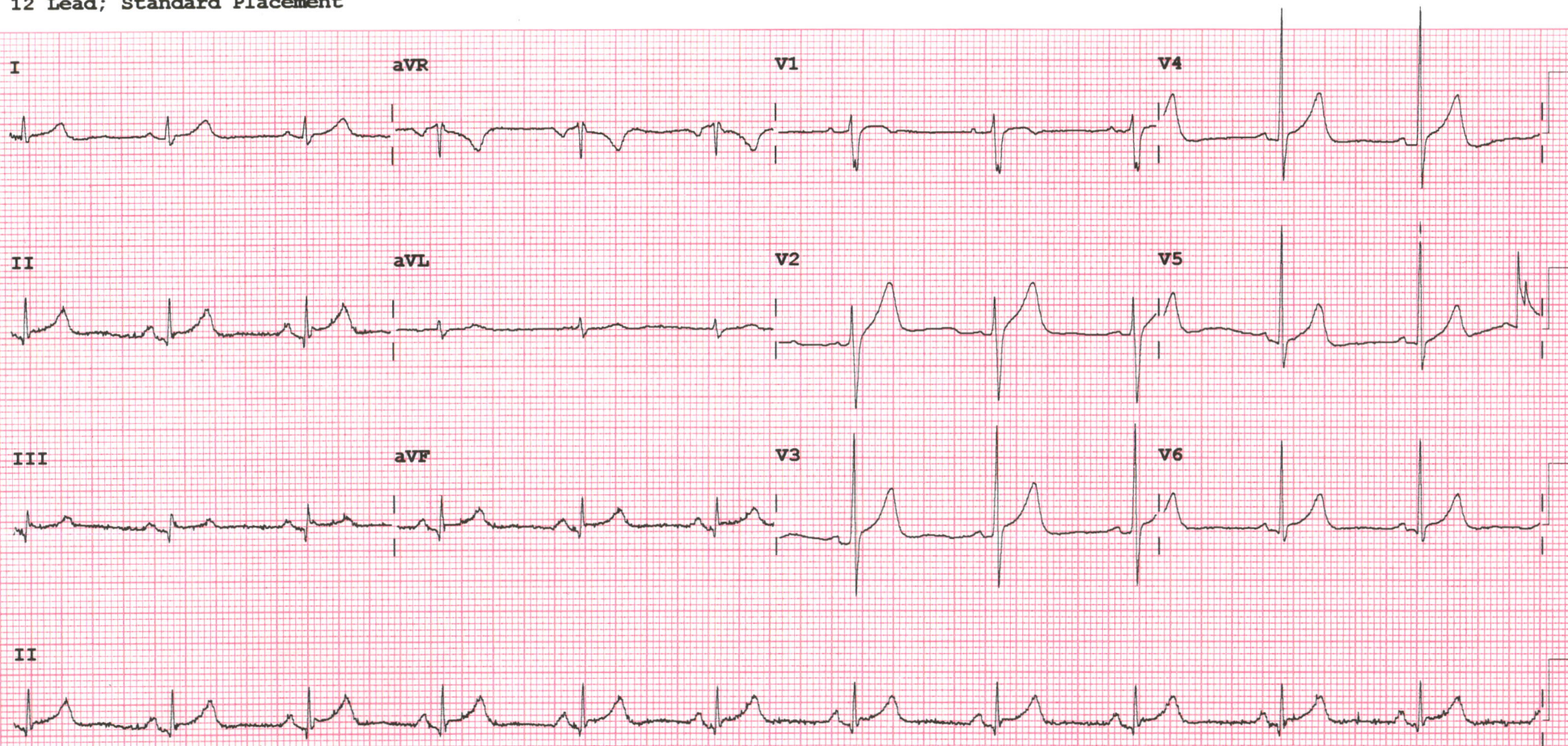
--AXIS--

P 70

QRS 71

T 46

12 Lead; Standard Placement



Device:

Speed: 25 mm/sec

Limb: 10 mm/mV

Chest: 10.0 mm/mV

F 50~ 0.50-150 Hz W

PH09

P?



Unipath Specialty Laboratory (Baroda) LLP - Platinum Complex, Opp. HDFC Bank, Nr. Radha Krishna char rasta, Akota, Vadodara - 390020
Mobile: 7228800500 / 8155028222 | Email: info.baroda@unipathllp.in



TEST REPORT

Reg. No. : 30301006011 Reg. Date : 11-Mar-2023 12:09 Collected On : 11-Mar-2023 12:09
Name : Mr. AJIT SINGH Approved On : 11-Mar-2023 13:27
Age : 51 Years Gender : Male Ref. No. : Dispatch At :
Ref. By : Tele No. :
Location : SAVITA SUPERSPECIALTY HOSPITAL @ WAGHODIYA ROAD

Test Name	Results	Units	Bio. Ref. Interval
THYROID FUNCTION TEST			
T3 (triiodothyronine) <i>Method:CLIA</i>	1.18	ng/mL	0.6 - 1.81
T4 (Thyroxine) <i>Method:CLIA</i>	9.80	µg/dL	4.5 - 12.6
TSH (ultra sensitive) <i>Method:CLIA</i>	3.251	µIU/mL	0.55 - 4.78
Sample Type:Serum			

Comments:

Thyroid stimulating hormone (TSH) is synthesized and secreted by the anterior pituitary in response to a negative feedback mechanism involving concentrations of FT3 (free T3) and FT4 (free T4). Additionally, the hypothalamic tripeptide, thyrotropin-releasing hormone (TRH), directly stimulates TSH production. TSH stimulates thyroid cell production and hypertrophy, also stimulate the thyroid gland to synthesize and secrete T3 and T4. Quantification of TSH is significant to differentiate primary (thyroid) from secondary (pituitary) and tertiary (hypothalamus) hypothyroidism. In primary hypothyroidism, TSH levels are significantly elevated, while in secondary and tertiary hypothyroidism, TSH levels are low.

TSH levels During Pregnancy :

- First Trimester : 0.1 to 2.5 µIU/mL
- Second Trimester : 0.2 to 3.0 µIU/mL
- Third trimester : 0.3 to 3.0 µIU/mL

Reference : Carl A.Burtis,Edward R.Ashwood,David E.Bruns. Tietz Textbook of Clinical Chemistry and Molecular Diagnostics. 5th Edition. Philadelphia: WB Saunders,2012:2170

----- End Of Report -----

This is an electronically authenticated report.

Test done from collected sample.

Printed On: 11-Mar-2023 13:29

Dr. Vishal Jhaveri
M.B.B.S, D.C.P
Reg. G-13041

We are open 24 x 7 & 365 days

Page 1 of 1
LLP Identification Number: AAN-893



Patient Name : Ajit . Singh

Sample No. : 20230316105



Patient ID : 20230308950

Visit No. : OPD20230326838

Age / Sex : 51y/Male

Coll. Date : 11/03/2023 08:42

Consultant : DR SAURABH JAIN

S. Coll. Date : 11/03/2023 12:56

Ward : -


Report Date : 11/03/2023 16:23

Urine R/M

Investigation	Result	Normal Value
Quantity - :	20 ml	
Colour - :	Pale Yellow	
Reaction (pH) :	6.0	4.6-8.0
Turbidity :	Clear	
Deposit :	Absent	Absent
Sp.Gravity :	1.020	1.005-1.010
Protein :	Absent	Absent
Glucose :	Absent	Absent
Bile Salts :	Absent	Absent
Bile pigments :	Absent	Absent
Ketones :	Absent	Absent
Urobilinogen :	Absent	
Blood :	Absent	Absent
Pus Cells :	Absent /hpf	0-5/hpf
Red Blood Cells :	Absent /hpf	Absent
Epithelial Cells :	0-1 /hpf	

Dr.Mehul Desai
M.B.D.C.P
Reg.No.G-9521



Patient Name :	Ajit . Singh	Sample No. :	20230316105 
Patient ID :	20230308950	Visit No. :	OPD20230326838
Age / Sex :	51y/Male	Coll. Date :	11/03/2023 08:42
Consultant :	DR SAURABH JAIN	S. Coll. Date :	11/03/2023 12:56
Ward :	-	Report Date :	11/03/2023 16:23

Lipid Profile

Investigation	Result	Normal Value
Sample :	Fasting	
Sample Type :	Normal	
Cholesterol (Chol) :	212 mg/dl [H]	Low risk : < 200 Moderate risk : 200 - 239 High risk : > or = 240
Triglyceride :	71 mg/dl	Normal : < 200.0 High : 200 - 499 Very High : > or = 500
HDL Cholesterol :	69 mg/dl	Low risk : >or = 60 mg/dL High risk : Up to 35 mg/dL
LDL :	128.8 mg/dl [L]	131.0 to 159.0(N) < 130.0(L) > 159.0(H)
VLDL :	14.2 mg/dl	Up to 0 to 34 mg/dl
LDL/HDL Ratio :	1.87	Low risk : 0.5 to 3.0 Moderate risk : 3.0 to 6.0 Elevted level high > 6.0
Total Chol / HDL Ratio :	3.07	Low Risk : 3.3 to 4.4 Average Risk : 4.4 to 7.1 Moderate Risk : 7.1 to 11.0 High Risk : > 11.0
Total Lipids :	652 mg/dl	400 to 700 mg/dl

Note :- Lipemic samples give high triglyceride value and falsely low LDL value.

Dr. Mehul Desai
M.B.D.C.P
Reg.No.G-9521




Savita

Superspeciality Hospital

(A Unit of Solace Healthcare Pvt. Ltd.)

Parivar Char Rasta, Waghodia-Dabhoi Ring Road, Vadodara-390019

0265-2578844 / 2578849 ✉ mh@savitahospital.com 🌐 savitahospital.com

Patient Name :	Ajit . Singh	Sample No. :	20230316105 
Patient ID :	20230308950	Visit No. :	OPD20230326838
Age / Sex :	51y/Male	Coll. Date :	11/03/2023 08:42
Consultant :	DR SAURABH JAIN	S. Coll. Date :	11/03/2023 12:56
Ward :	-	Report Date :	11/03/2023 16:23


LFT (Liver Function Test)

Investigation	Result	Normal Value
Total Bilirubin :	0.7 mg/dl	0.2 to 1.0 mg/dl
Direct Bilirubin :	0.2 mg/dl	0.0 to 0.2 mg/dl
Indirect Bilirubin :	0.5 mg/dl	0.0 to 0.8 mg/dl
AST (SGOT) :	30 U/L	5 to 34 U/L
ALT (SGPT) :	82 U/L [H]	0 to 55 U/L
Total Protein (TP) :	7.2 g/dL	6.4 to 8.3, g/dl
Albumin (ALB) :	4.2 g/dl	3.5 to 5.2 g/dl
Globulin :	3 g/dl	2.3 to 3.5 g/dl
A/G Ratio :	1.4	
Alkaline Phosphatase (ALP) :	110 U/L	40 to 150 U/L
GAMMA GT. :	31 U/L	7 to 35 U/L



Dr.Mehul Desai
M.B.D.C.P
Reg.No.G-9521



Patient Name :	Ajit . Singh	Sample No. :	20230316105 
Patient ID :	20230308950	Visit No. :	OPD20230326838
Age / Sex :	51y/Male	Coll. Date :	11/03/2023 08:42
Consultant :	DR SAURABH JAIN	S. Coll. Date :	11/03/2023 12:56
Ward :	-	Report Date :	11/03/2023 16:23


RENAL FUNCTION TEST

Investigation	Result	Normal Value
Creatinine :	0.8 mg/dl	0.6 - 1.4 mg/dl
Urea :	27 mg/ dl	13 - 45 mg/dl
Uric Acid :	3.9 mg/dl	3.5 - 7.2 mg/dl
Calcium :	8 mg/dl	8.5 - 10.5
Phosphorus :	3.2 mg/dl	1.5 - 6.8



Dr.Mehul Desai
M.B.D.C.P
Reg.No.G-9521



Patient Name : Ajit . Singh	Sample No. : 20230316105
Patient ID : 20230308950	
Age / Sex : 51y/Male	Visit No. : OPD20230326838
Consultant : DR SAURABH JAIN	Coll. Date : 11/03/2023 08:42
Ward : -	S. Coll. Date : 11/03/2023 12:56
	Report Date : 11/03/2023 16:23

Blood Group

Investigation	Result	Normal Value
BLOOD GROUP :		
ABO	AB	
Rh	Positive	

FBS & PPBS

Investigation	Result	Normal Value
Blood Sugar (FBS) :	111 mg/dl [H]	74 - 100 mg/dl
Urine Sugar (FUS) :	Nil	
Blood Sugar (PP2BS) :	80 mg/dl	70 to 120 mg/dl
Urine Sugar (PP2US) :	Nil	


HBA1C

Investigation	Result	Normal Value
Glycosylated Hb :	5.7 %	Near Normal Glycemia : 6 to 7 Excellent Control : 7 to 8 Good Control : 8 to 9 Fair Control : 9 to 10 Poor Control : > 10
Average Plasma Glucose of Last 3 Months :	116.89	



Dr. Mehul Desai
M.B.D.C.P
Reg.No.G-9521



Patient Name :	Ajit . Singh	Sample No. :	20230316105 
Patient ID :	20230308950	Visit No. :	OPD20230326838
Age / Sex :	51y/Male	Coll. Date :	11/03/2023 08:42
Consultant :	DR SAURABH JAIN	S. Coll. Date :	11/03/2023 12:56
Ward :	-	Report Date :	11/03/2023 16:23

CBC, ESR

Investigation	Result	Normal Value
Hemoglobin :	15.2 gm/dl	13.5 to 18.0 gm/dl
P.C.V. :	46 %	42.0 to 52.0 %
M.C.V. :	86.3 fL	78 to 100 fL
M.C.H. :	28.5 pg	27 to 31 pg
M.C.H.C. :	33 g/dl	32 to 36 g/dl
RDW :	12.2 %	11.5 to 14.0 %
RBC Count :	5.33 X 10 ⁶ / cumm	4.7 to 6.0 X 10 ⁶ / cumm
Polymorphs :	63 %	38 to 70 %
Lymphocytes :	31 %	15 to 48 %
Eosinophils :	2 %	0 to 6 %
Monocytes :	4 %	3 to 11 %
Basophils :	0 %	0.0 to 1.0 %
Total :	100	< 100 > 100
WBC Count :	5400 /cmm	4000 to 10000 /cmm
Platelets Count :	110000 /cmm	1,50,000 to 4,50,000 /cmm
ESR - After One Hour :	8 mm/hr	1 to 13 mm/hr



Dr.Mehul Desai
M.B.D.C.P
Reg.No.G-9521



Patient name	AJIT SINGH
Age / Sex	51Y/M
Date	Saturday, 11 March 2023

ULTRASOUND OF ABDOMEN

LIVER appears normal in size (11.2 cm) and shows normal parenchymal echogenicity. No evidence of focal lesion. No evidence of dilated IHBR or portal vein. CBD appears normal.

GALL BLADDER is distended. No e/o wall thickening or calculus within.

VISUALIZED PART OF PANCREAS appears normal. MPD is WNL

SPLEEN appears normal in size (6.5 cm) and shows normal parenchymal echogenicity. No evidence of focal lesion.

BOTH KIDNEYS appear normal in size (RK: 9.8 cm & LK: 8.5 cm) and position. Show normal cortical echogenicity. Corticomedullary differentiation is maintained. No calculus or hydronephrosis on either side.

URINARY BLADDER is full (Pre-void: 100 cc & Post-void: <10 cc). No e/o wall thickening or calculus within.

PROSTATE appears enlarged in size (36.1 cc). No evidence of focal lesion noted.

BOWEL LOOPS appear normal and show normal peristalsis
No evidence of LYMPHADENOPATHY noted.
No evidence of ASCITES or PLEURAL EFFUSION noted.

IMPRESSION:

- Grade I Prostatomegaly with insignificant post-void volume.



DR SHARAD RUNGTA
MD RADIOLOGY

Not all pathologies can be detected on radiograph. Further radiographic evaluation is suggested if required.



NAME: AJIT SINGH	AGE/SEX: 51 YRS/M
DATE: Saturday, March 11, 2023	

CHEST XRAY (PA)

Both lung fields appear normal.

Both hila appear normal

Bilateral costo-phrenic angles appear grossly clear

Mediastinum and cardiac shadow appear normal

Bony thorax appears unremarkable

No evidence of free gas under domes of diaphragm

IMPRESSION:

- **NO SIGNIFICANT ABNORMALITY NOTED IN LUNG FIELDS**
- **NORMAL CARDIAC SHADOW**



DR SHARAD RUNGTA
MD RADIOLOGY

Not all pathologies can be detected on radiograph. Further radiographic evaluation is suggested if required.