

**B** बैंक ऑफ बड़ोदा  
Bank of Baroda

नाम: **DEEPAK KALA**

सर्वकारी फूट नं. **174584**  
C. No.

*[Handwritten Signature]*

अधिकृत अधिकारी, राय, एम. ए. - III, पूर्व विभाग  
Authorizing Authority: AGM, DRM, DMR-III, N.D.

*[Circular Stamp: Bank of Baroda, DMR-III]*

*[Handwritten Signature]*

होल्डर का हस्ताक्षर  
Signature of Holder

*[Handwritten Signature]*



*[Handwritten Signature]*

**Dr. NITIN AGARWAL**  
MBBS, MD  
Regn. No. DMC-R-1436

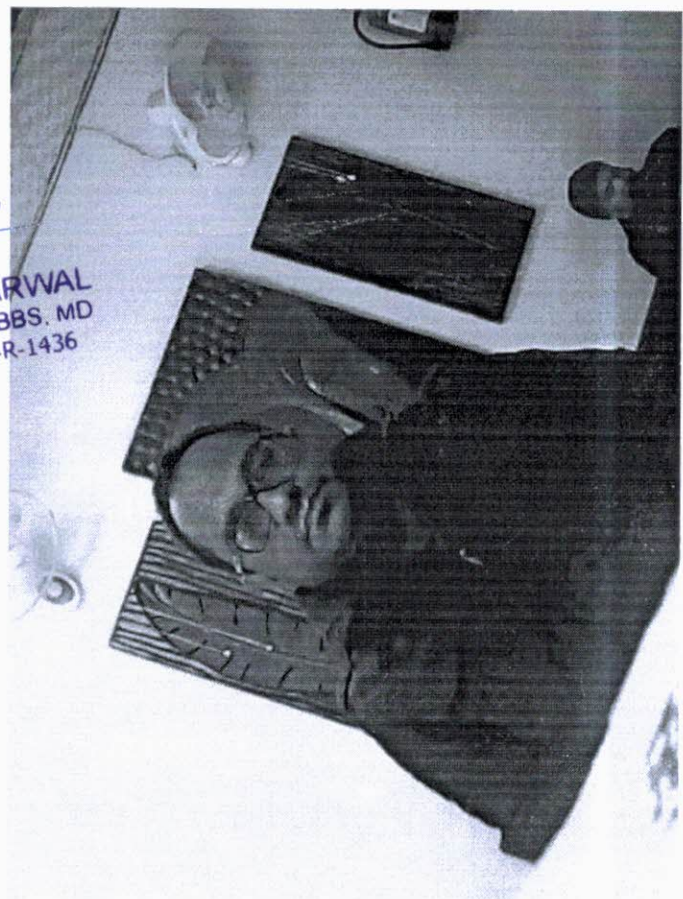
**ONEPLUS ULTRASOUND LAB**  
47, Hareh Vihar, Pitam Pura,  
Delhi-110034  
Ph. 011-42480101, 9599913051  
E-mail: oneplusul@gmail.com



*Nitin*

*NT*  
**Dr. NITIN AGARWAL**  
MBBS, MD  
Regn. No. DMC-R-1436

**ONEPLUS ULTRASOUND LAB**  
47, Harsh Vihar, Pitam Pura,  
Delhi-110034  
Ph. 011-42480101, 9599913051  
E-mail: [oneplusul@gmail.com](mailto:oneplusul@gmail.com)



# ONE PLUS ULTRASOUND LAB

47, HARSH VIHAR, PITAMPURA

Mr. DEEPAK KALA  
Age : 29/M  
Ref. by : MEDIWHEEL  
Indication 1 :  
Indication 2 :  
Indication 3 :  
COMMENTS :

ID : 6  
H/Wt : 154/74  
Recorded : 27-12-2021 10:17  
Medication 1 :  
Medication 2 :  
Medication 3 :

BPM : 93  
BP : 126/74  
P Axis : 0 deg  
QRS Axis : 0 deg  
T Axis : 0 deg

P duration : 0 msec  
PR duration : 0 msec  
QRS duration : 0 msec  
QT Interval : 0 msec  
QTc Interval : 0 msec

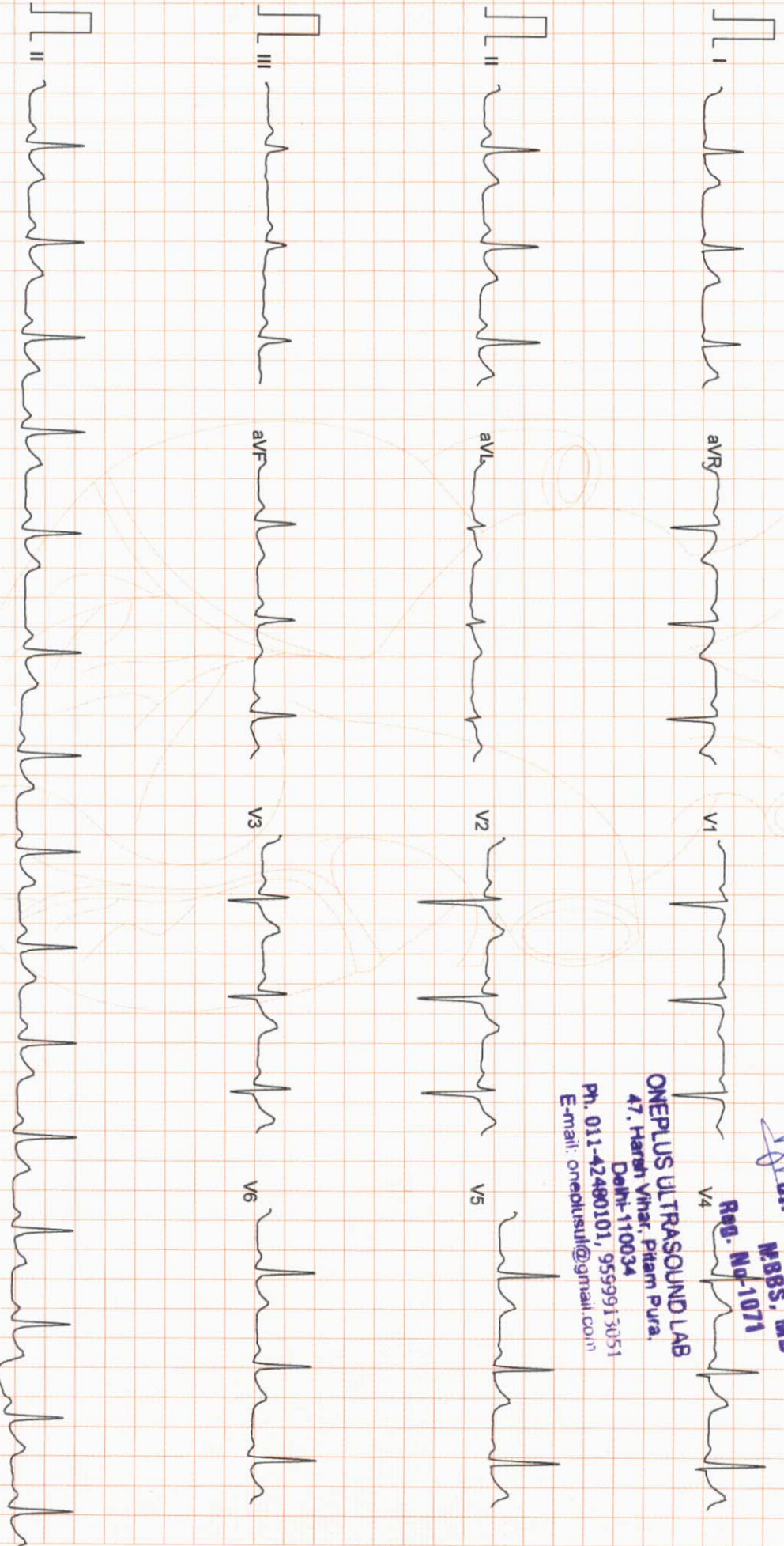
Raw E.C.G.

Unconfirmed Report Reviewed By:

Cardiologist

**Dr. P.K. GUPIA**  
**MBBS, MD**  
**Reg. No-1071**

**ONEPLUS ULTRASOUND LAB**  
47, Harsh Vihar, Pitam Pura,  
Delhi-110034  
Ph. 011-42480101, 9559913051  
E-mail: oneplusul@gmail.com



Filtered

25mm/sec 10mm/mV

Aspirin

CardiCom, INDIA

# ONE PLUS ULTRASOUND LAB

47, HARSH VIHAR, PITAMPURA

MR. DEEPAK KALA  
Age/Sex : 29/M  
Ref. by : MEDWHEEL

ID : 18  
HWT : 154/74  
Recorded : 27-12-2021 10:19

TREADMILL TEST SUMMARY REPORT  
Protocol: BRUCE

Indication1 :  
Indication2 :  
Indication3 :

Medication1 :  
Medication2 :  
Medication3 :

PHASE	PHASE TIME	STAGE TIME	SPEED (Km./Hr.)	GRADE (%)	H.R. (BPM)	B.P. (mmHg)	RPP X100	II	ST LEVEL (mm) V2	V5	METS
SUPINE					92	126/74	115	1.2	1.3	1.0	
STANDING					92	126/74	115	1.2	1.3	0.9	
STAGE 1	2:59	2:59	2.70	10.00	125	140/78	175	1.2	2.0	1.1	4.80
STAGE 2	5:59	2:59	4.00	12.00	146	156/84	227	1.0	2.3	0.9	7.10
STAGE 3	7:59	1:59	5.40	14.00	168	170/90	285	0.5	2.6	0.7	9.03
PEAK EXER	8:03	2:03			171	170/90	290	0.5	2.8	0.7	9.09

**RESULTS**  
 Exercise Duration : 8:03 Minutes  
 Max Heart Rate : 171 bpm 89 % of target heart rate 191 bpm  
 Max Blood Pressure : 170/90 mmHg  
 Max Work Load : 9.09 METS  
 Reason of Termination :  
**IMPRESSIONS** : *Negative for ischemia*

*[Signature]*  
**DR. P.K. GUPTA**  
 MBBS, MD  
 Cardiologist  
 Reg. No-1071

*[Signature]*

**ONEPLUS ULTRASOUND LAB**  
 47, Harsh Vihar, Pitampura,  
 Delhi-110034  
 Ph. 011-42460101, 9559913051  
 E-mail: oneplusul@gmail.com

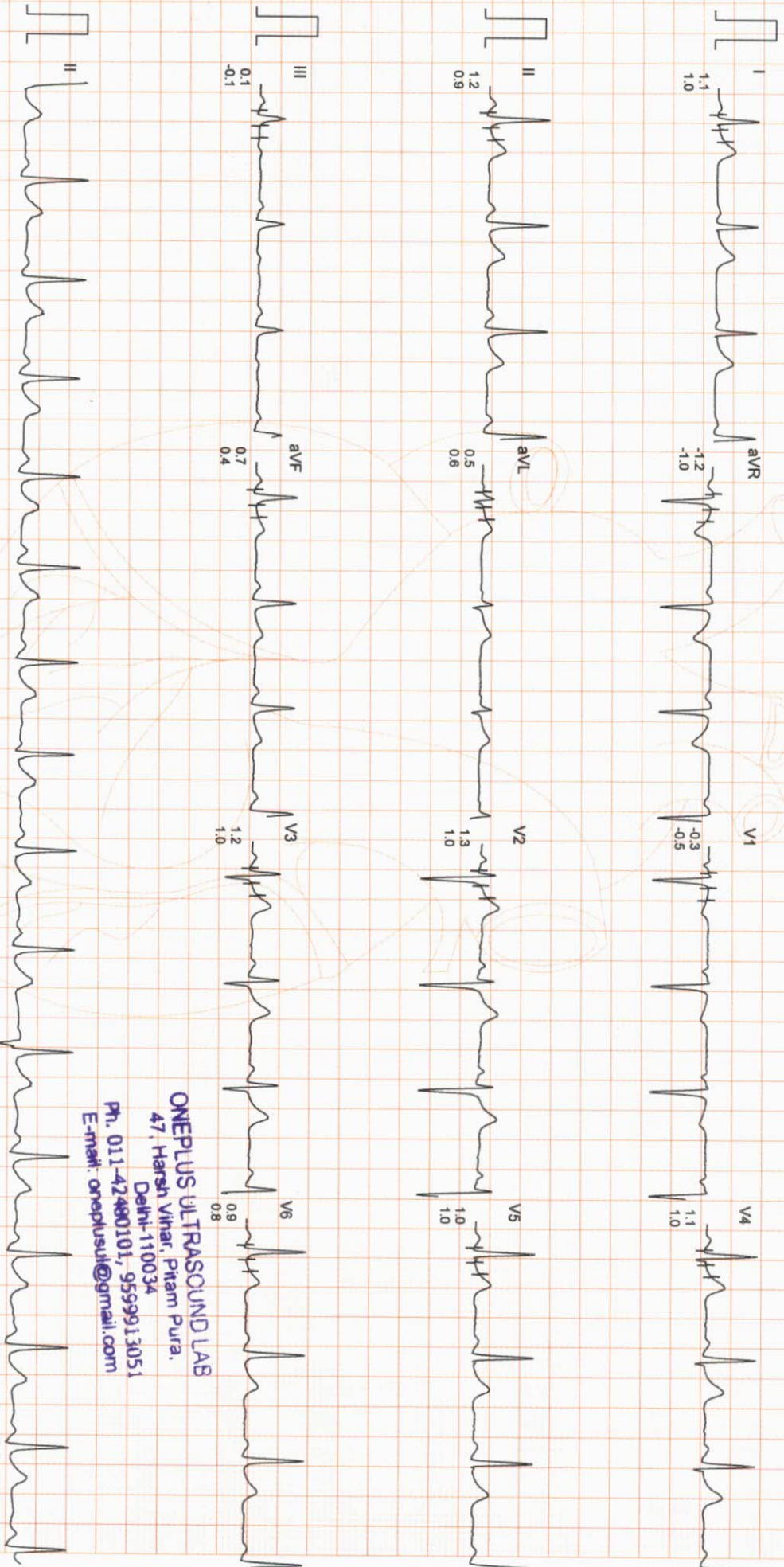
# ONE PLUS ULTRASOUND LAB

SUPINE  
PRETEST

ST @ 10mm/mV  
80ms PostJ

M. DEEPAK KALA  
I.D. : 18  
AGE/SEX : 29/M  
RECORDED : 27-12-2021 10:19  
RATE : 92 BPM  
B.P. : 126/74 mmHg

LINKED MEDIAN



ONEPLUS ULTRASOUND LAB  
47, Harsh Vihar, Pitam Pura,  
Delhi-110034  
Ph. 011-42480101, 9559913051  
E-mail: oneplusult@gmail.com

Filtered

Computer Corrected Baseline

25mm/sec 10mm/mV

CardiCom, INDIA

ASST

Handwritten notes or a small diagram, possibly a signature or initials, located in the upper left quadrant of the page. The text is illegible due to blurriness and fading.

# ONE PLUS ULTRASOUND LAB

STANDING  
PRETEST

ST @ 10mm/mV  
80ms PostJ

MR. DEEPAK KALA

ID. : 18

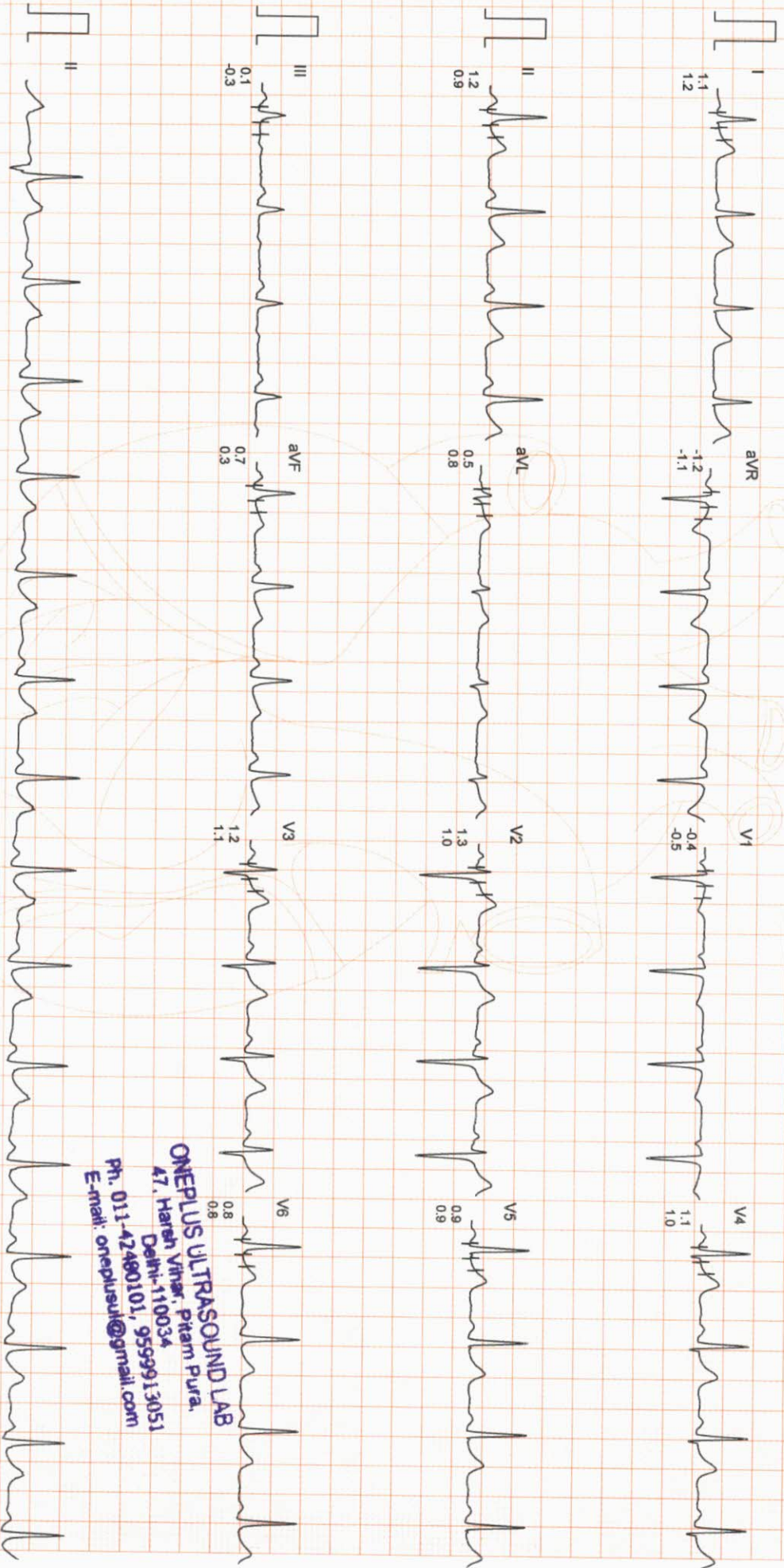
AGE/SEX : 29/M

RECORDED : 27-12-2021 10:19

RATE : 92 BPM

B.P. : 126/74 mmHg

LINKED MEDIAN



**ONEPLUS ULTRASOUND LAB**  
47, Harsh Vihar, Pitam Pura,  
Delhi-110034  
Ph. 011-42460101, 9599913051  
E-mail: oneplusul@gmail.com

Filtered

Computer Corrected Baseline

25mm/sec 10mm/mV

CardiCom, INDIA





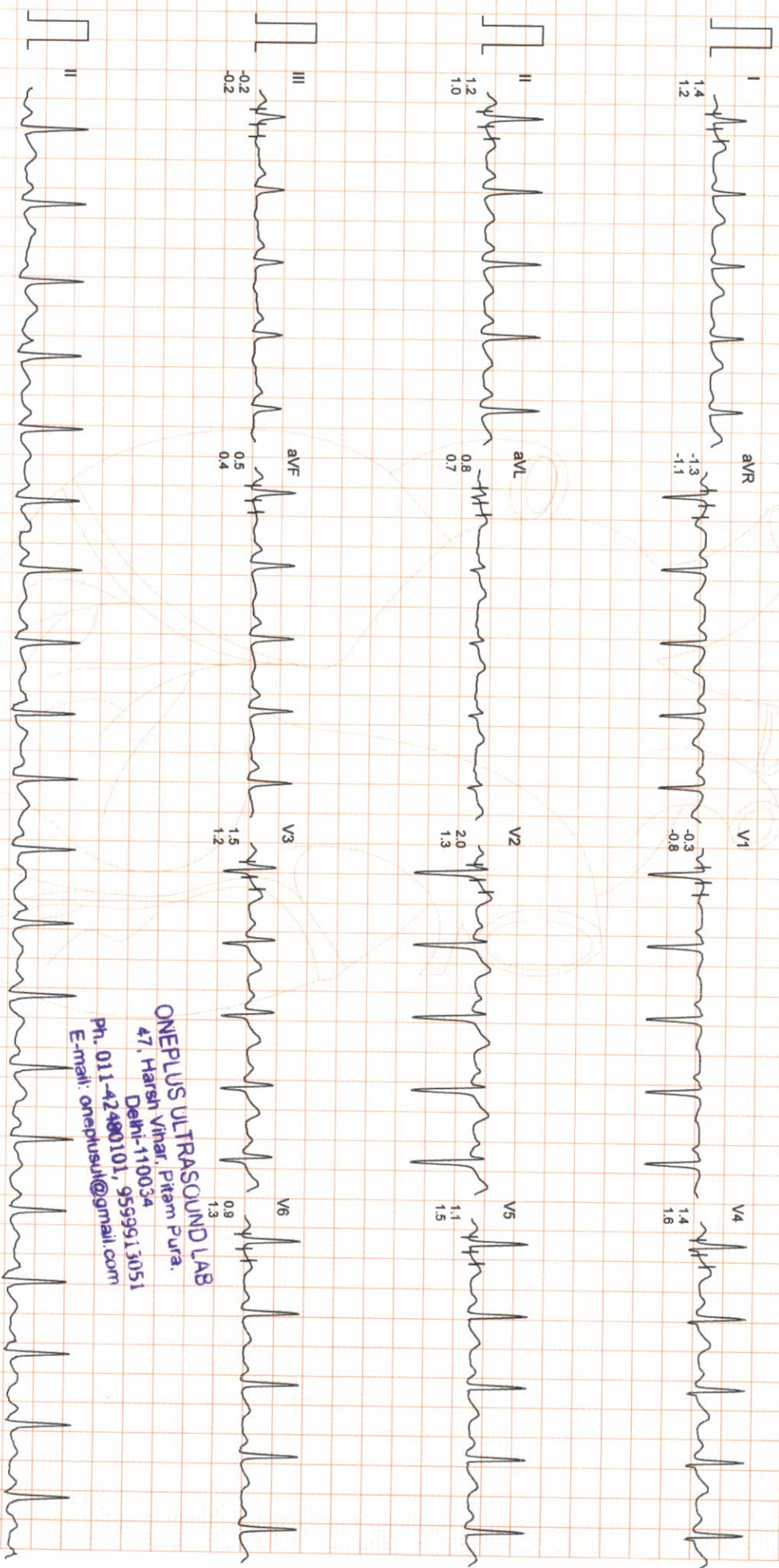
# ONE PLUS ULTRASOUND LAB

Mr. DEEPAK KALA  
I.D. : 18  
AGE/SEX : 29/M  
RECORDED : 27-12-2021 10:19

BRUCE  
EXERCISE 1  
PHASE TIME : 2:59  
STAGE TIME : 2:59

ST @ 10mm/mV  
80ms PostJ  
SPEED : 2.7 Km./Hr.  
GRADE : 10.0 %

LINKED MEDIAN



ONEPLUS ULTRASOUND LAB  
47, Harsh Vihar, Pitam Pura,  
Delhi-110034  
Ph. 011-42480101, 9559513051  
E-mail: onepiusul@gmail.com

Handwritten text, possibly a signature or date, located in the upper left quadrant of the page.

Mr. DEEPAK KALA  
I.D. : 18  
AGE/SEX : 29/M  
RECORDED : 27-12-2021 10:19

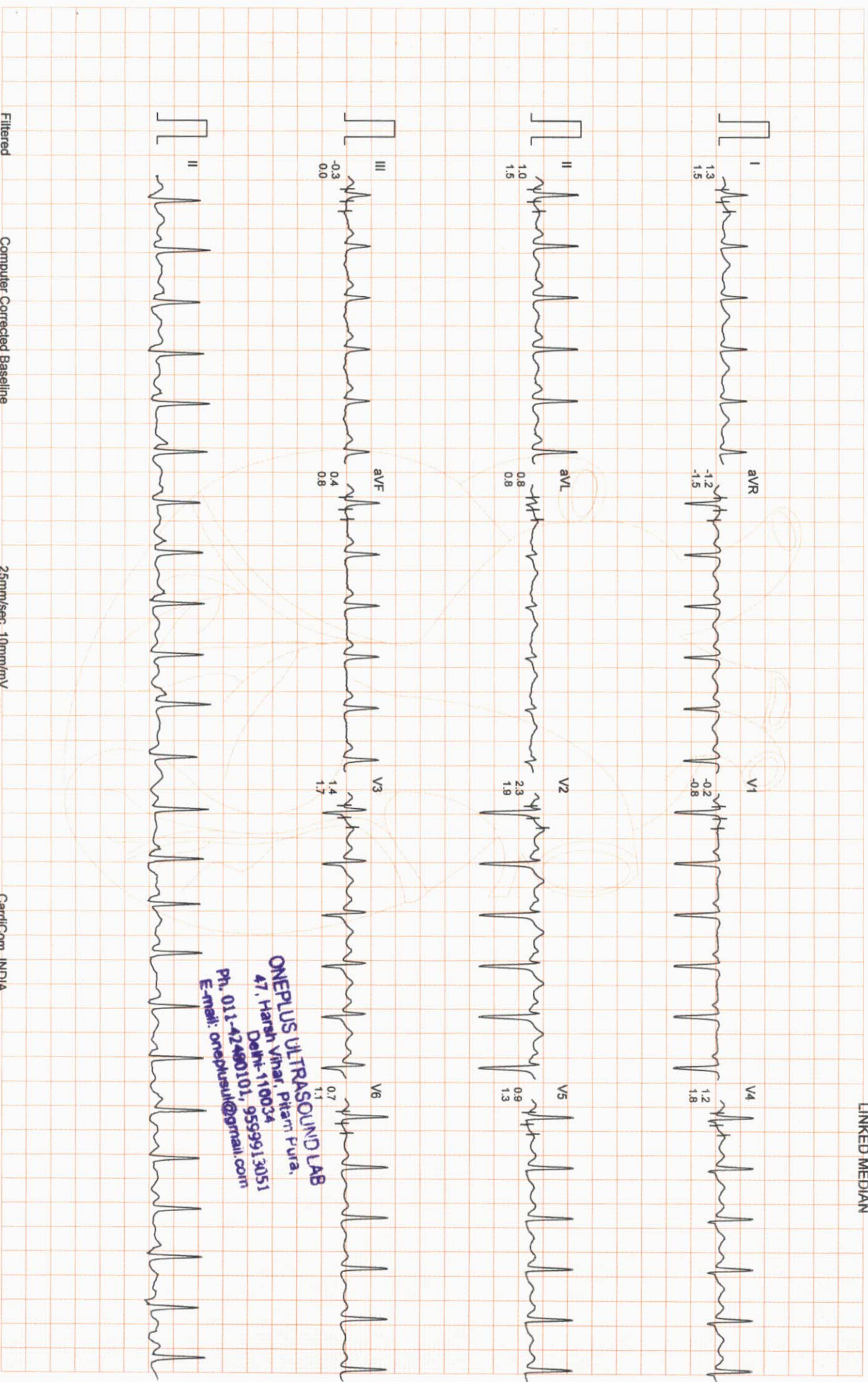
RATE : 146 BPM  
B.P. : 156/84 mmHg

BRUCE  
EXERCISE 2  
PHASE TIME : 5:59  
STAGE TIME : 2:59

ST @ 10mm/mV  
80ms PostJ  
SPEED : 4.0 Km./Hr.  
GRADE : 12.0 %

ONE PLUS ULTRASOUND LAB

LINKED MEDIAN





# ONE PLUS ULTRASOUND LAB

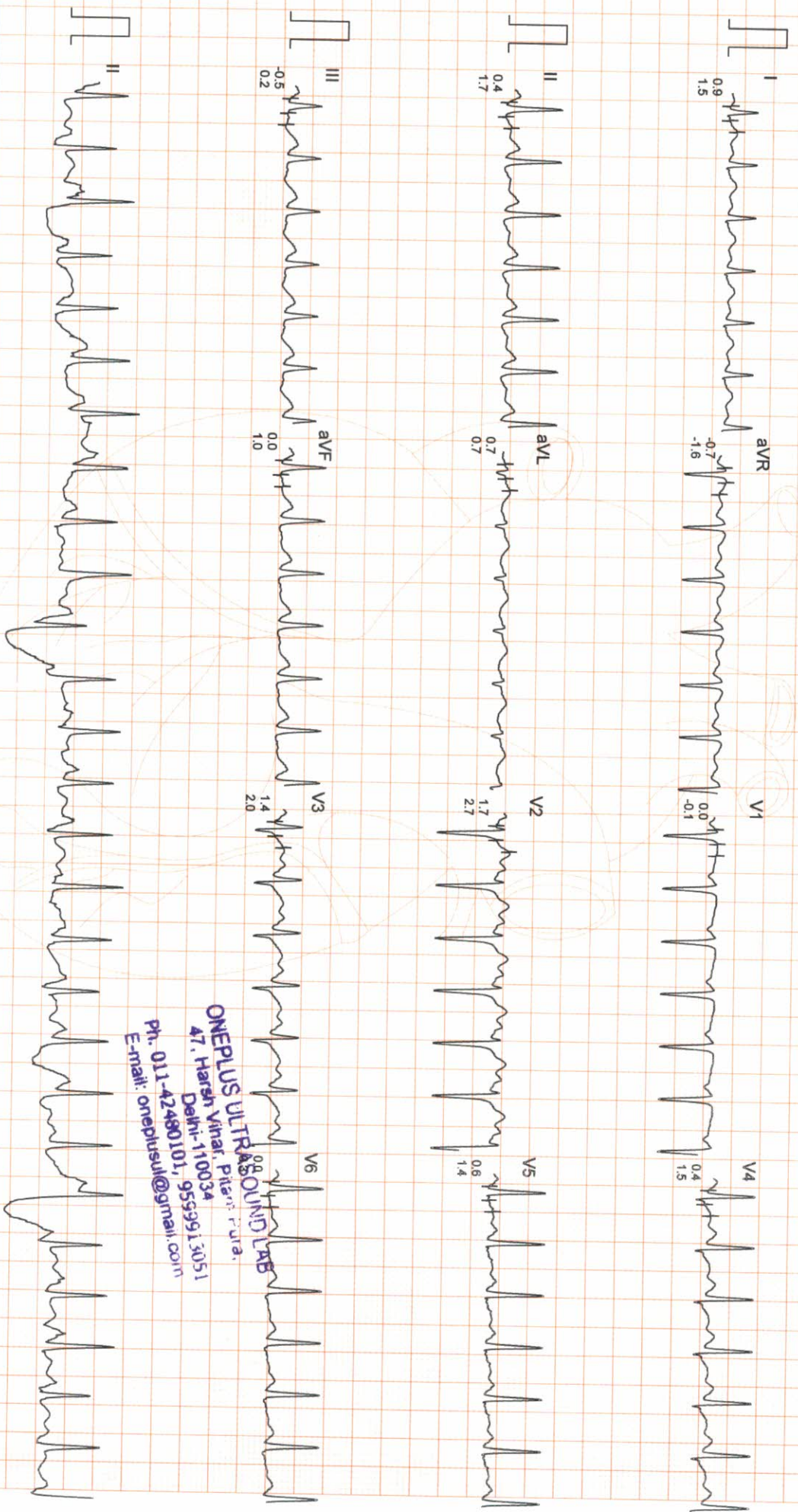
Mr. DEEPAK KALA  
I.D. : 18  
AGE/SEX : 29/M  
RECORDED : 27-12-2021 10:19

RATE : 167 BPM  
B.P. : 156/84 mmHg

BRUCE  
EXERCISE 3  
PHASE TIME : 7:29  
STAGE TIME : 1:29

ST @ 10mm/mV  
80ms PostJ  
SPEED : 5.4 Km./Hr.  
GRADE : 14.0 %

LINKED MEDIAN



**ONEPLUS ULTRASOUND LAB**  
Pitambar Puri,  
47, Harsh Vihar, Pitambar Puri,  
Delhi-110034  
Ph. 011-42480101, 9539913051  
E-mail: oneplusul@gmail.com

Filtered

Computer Corrected Baseline

25mm/sec 10mm/mV



CardiCom, INDIA

# ONE PLUS ULTRASOUND LAB

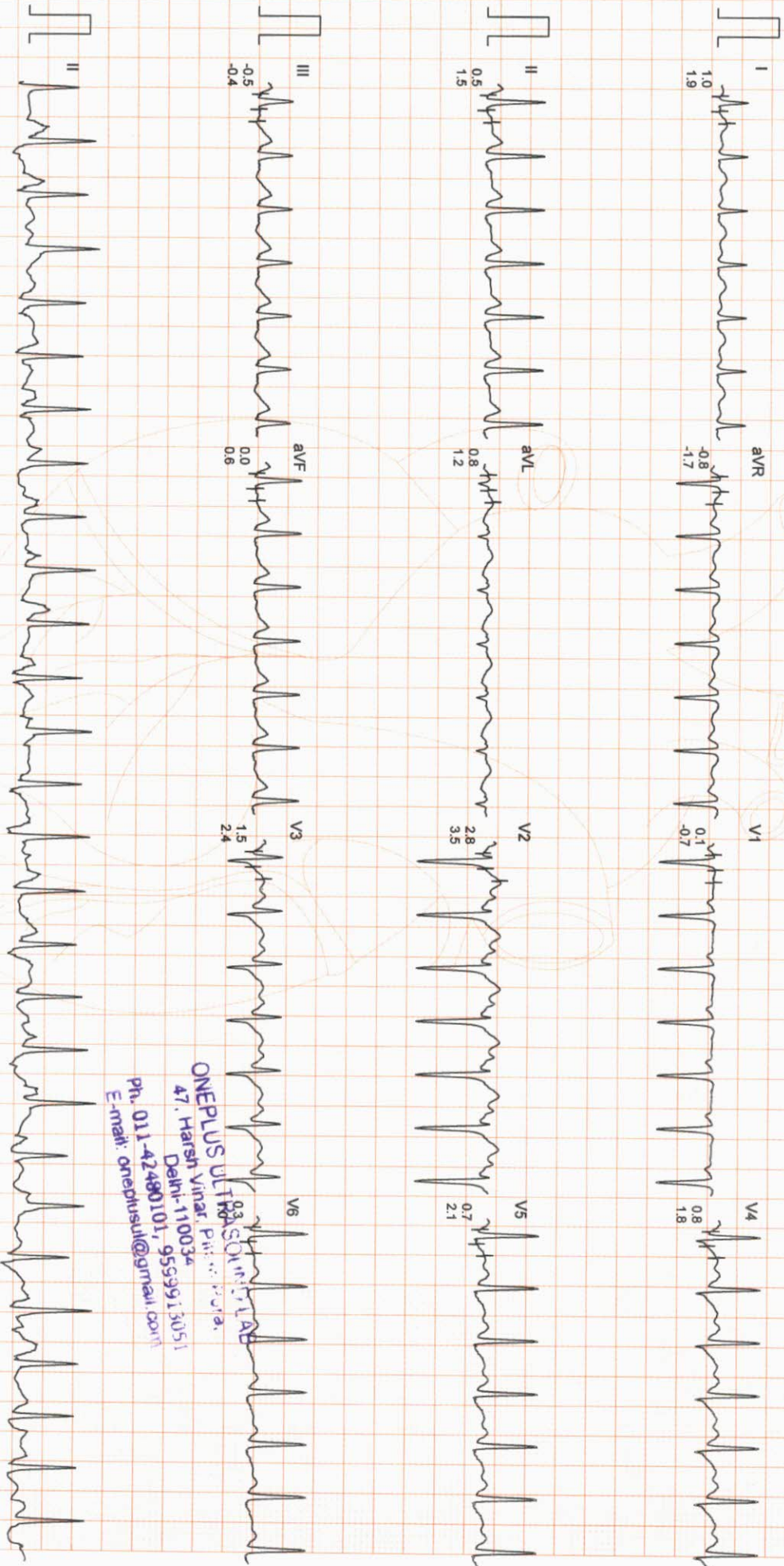
M. DEEPAK KALA  
I.D. : 18  
AGE/SEX : 29/M  
RECORDED : 27-12-2021 10:19

RATE : 171 BPM  
B.P. : 170/90 mmHg

BRUCE  
PEAK EXER  
PHASE TIME : 8:03  
STAGE TIME : 2:03

ST @ 10mm/mV  
80ms PostJ  
SPEED : 5.4 Km./Hr.  
GRADE : 14.0 %

LINKED MEDIAN



ONEPLUS ULTRASOUND LAB  
47, Harsh Vihar, Patna, Bihar.  
Delhi-110034  
Ph. 011-42480101, 9559913051  
E-mail: oneplusul@gmail.com

Filtered

Computer Corrected Baseline

25mm/sec 10mm/mV

CardiCom, INDIA



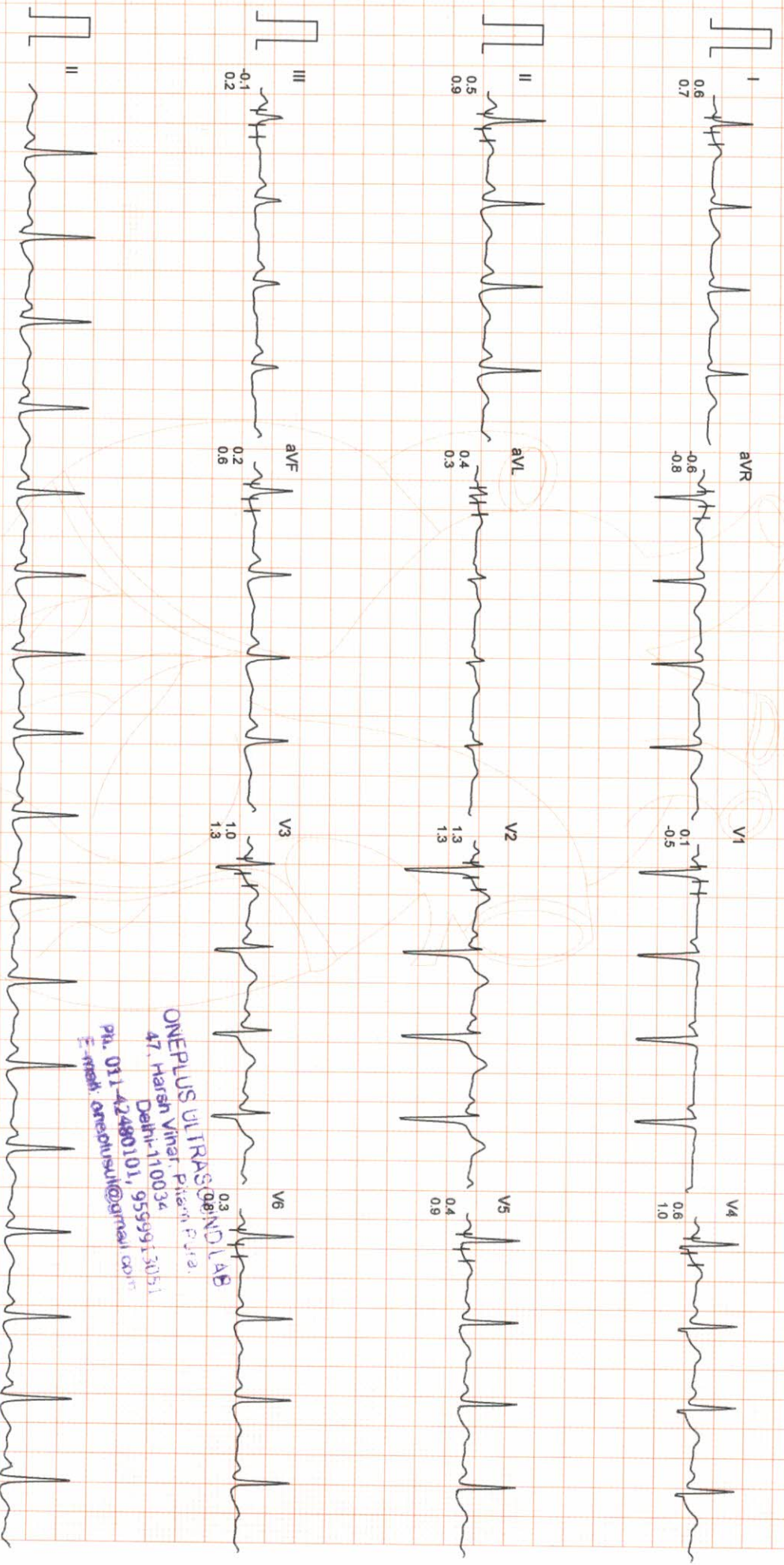
Mr. DEEPAK KALA  
I.D. : 18  
AGE/SEX : 29/M  
RECORDED : 27-12-2021 10:19

BRUCE  
RECOVERY  
PHASE TIME : 2:59

ST @ 10mm/mV  
80ms PostJ  
SPEED : 0.0 Km./Hr.  
GRADE : 0.0 %

ONE PLUS ULTRASOUND LAB

LINKED MEDIAN



ONEPLUS ULTRASOUND LAB  
47, Harsh Vihar, Pitam P. G. S.  
Delhi-110034  
Ph. 011-42480101, 9559913051  
E-mail: oneplusul@gmail.com

Filtered

Computer Corrected Baseline

25mm/sec 10mm/mV

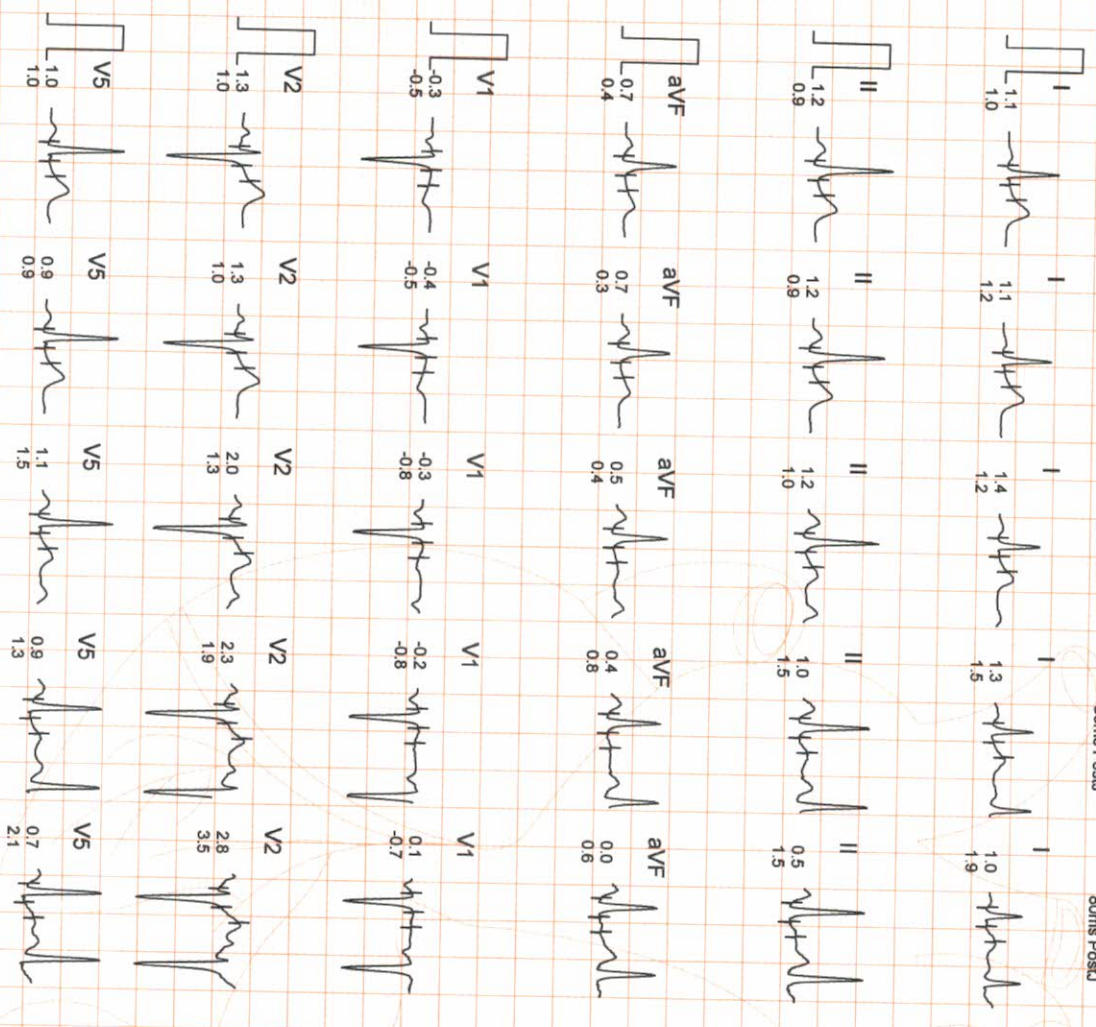
CardiCom, INDIA

Aravind

Handwritten text, possibly a signature or initials, located in the upper left quadrant of the page.









STAGE	HR	BP	SpO2
SUPINE	92 bpm	126/74	80ms Postu
STANDING	82 bpm	126/74	80ms Postu
STAGE 1	102 bpm	140/78	80ms Postu
STAGE 2	146 bpm	156/84	80ms Postu
PEAK EXERCISE	171 bpm	170/90	80ms Postu



**ONEPLUS ULTRASOUND LAB**  
 47, Harsh Vihar, Pitam Pura,  
 Delhi-110034  
 Ph. 011-42460101, 9599913051  
 E-mail: oneplusul@gmail.com







STANDING

0.0Kmph  
0.0%  
92 bpm  
B.P. 126/74  
80ms PostU



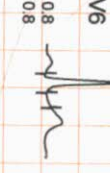




PEAK EXERCISE  
8:03

2:03  
5.4Kmph  
14.0%  
171 bpm  
B.P. 170/90  
80ms PostU





STANDING

0.0Kmph  
0.0%  
92 bpm  
B.P. 126/74  
80ms PostU



PEAK EXERCISE  
8:03

2:03  
5.4Kmph  
14.0%  
171 bpm  
B.P. 170/90  
80ms PostU



ONEPLUS ULTRASOUND LAB  
47, Harsh Vihar, Pitam Pura,  
Delhi-110034  
Ph. 011-42480101, 9539913051  
E-mail: oneplusul@gmail.com



**OnePLUS**  
Ultrasound Lab  
— QUALITY FIRST... ALWAYS! —

**Dr. Nitin Agarwal**

Pathologist & Director  
Ex. Sr. Res. MAMC  
& Lok Nayak Hospital  
Ex. Chief of Lab Dr. Lal Path Labs.

**Dr. Pooja (Garg) Agarwal**


Radiologist & Director  
MAMC & Lok Nayak Hospital

Name	: Mr. DEEPAK KALA	Age/Sex	: 30 YRS/Male
Ref. By	: Dr. MEDIWHEEL	Lab No	: 012112270003
Date	: 27-Dec-2021	Patient ID	: LSHHI89154

### X-ray-Chest PA view

Bony cage and soft tissues are normal.  
Cardiothoracic ratio is normal.  
Mediastinum is normal.  
Both hila are normal.  
Both costophrenic angles are clear.  
Both domes of diaphragm are normal.  
Lung fields are clear. No parenchymal lesion seen.

**IMPRESSION: Normal Study.**

  
DR. POOJA GARG  
RADIOLOGIST  
REG NO- DMC/R/03398

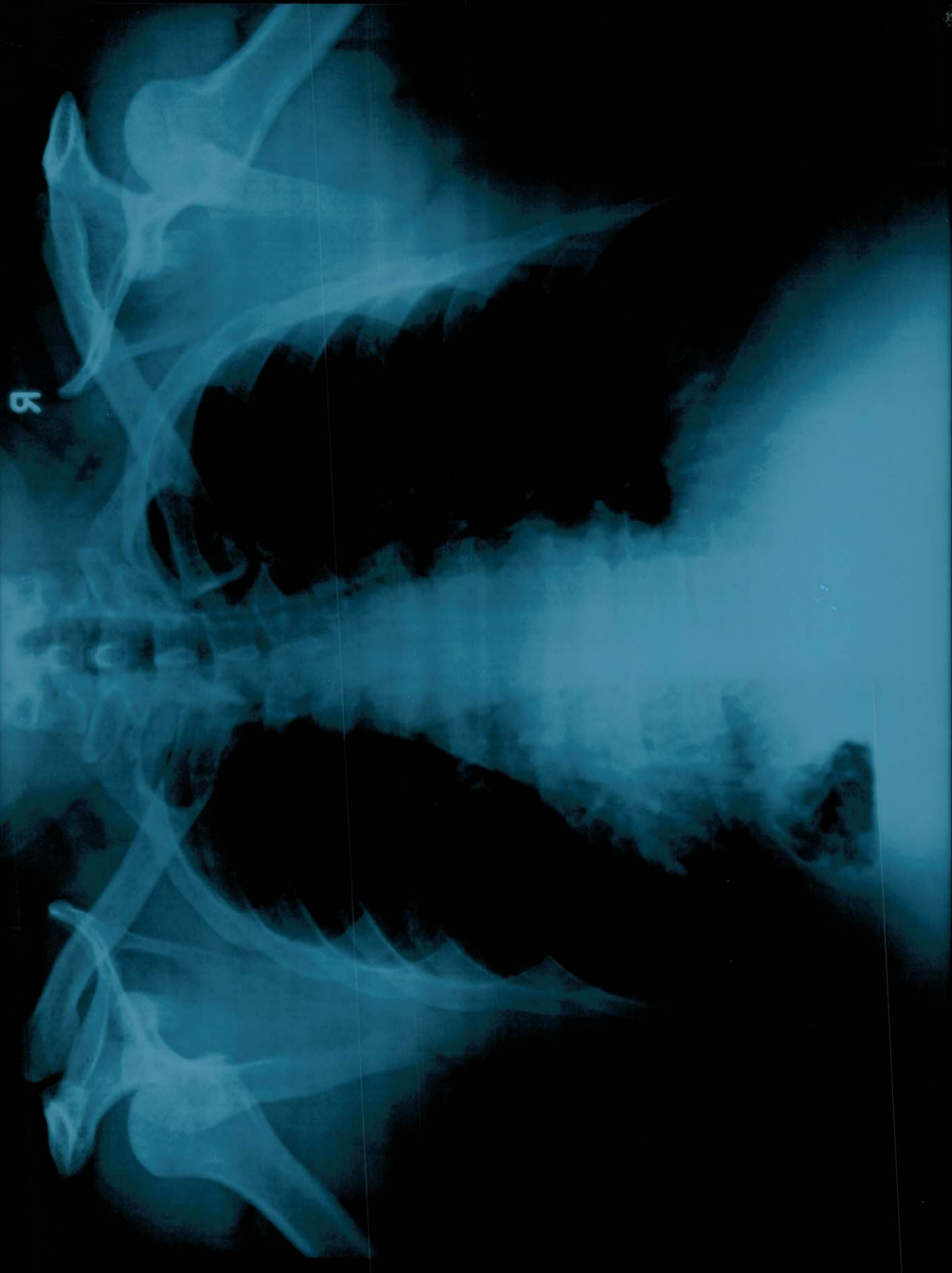
Dr. POOJA GARG  
M.B.B.S., D.M.R.D  
Reg No. DMC/R/03398  
Radiologist

Type By : pooja

47, Harsh Vihar, Pitampura, New Delhi-110034 | Ph.: 011-42480101, 9599913051  
E-mail: [oneplusul@gmail.com](mailto:oneplusul@gmail.com) | Web.: [www.oneplusul.in](http://www.oneplusul.in)

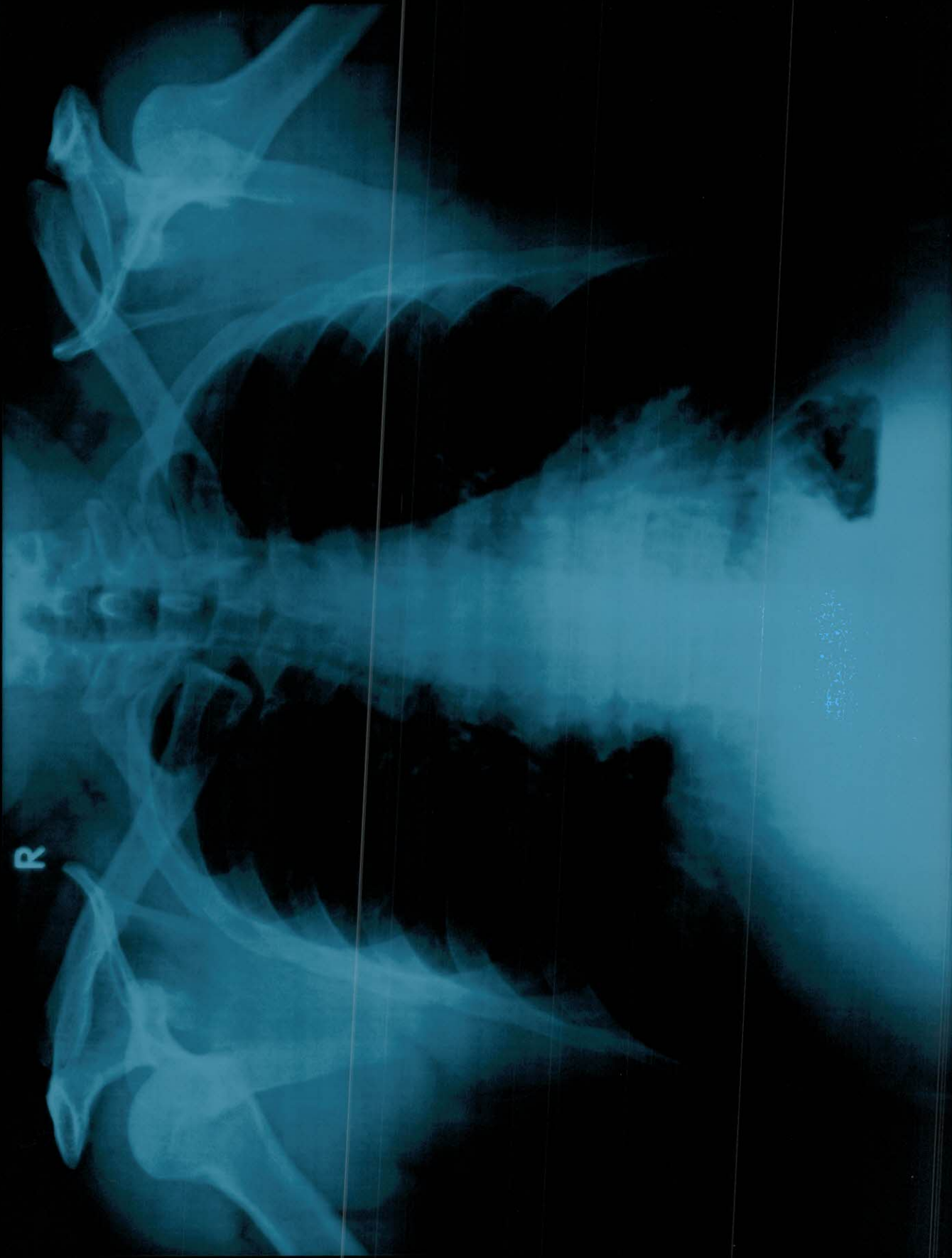

ONEPLUS ULTRASOUND LAB 43-HARSH NIVAR PITAMPURA  
MR DEEPAK KALTA AGE 58 YRS 51-15-5051 M CHEST PA VIEW 15/51/5051



R

R



MR DEEPAK KALA AGE 29 YRS 27-12-2021 M CHEST PA VIEW 12/27/2021

ONEPLUS ULTRASOUND LAB.47-HARSH VIHAR,PITAMPURA



**OnePLUS**  
Ultrasound Lab

— QUALITY FIRST... ALWAYS! —

**Dr. Nitin Agarwal**

Pathologist & Director  
Ex. Sr. Res. MAMC  
& Lok Nayak Hospital  
Ex. Chief of Lab Dr. Lal Path Labs.

**Dr. Pooja (Garg) Agarwal**

Radiologist & Director  
MAMC & Lok Nayak Hospital

<b>Name</b>	: Mr. DEEPAK KALA	<b>Age/Sex</b>	: 30 YRS/Male
<b>Ref. By</b>	: Dr. MEDIWHEEL	<b>Lab No</b>	: 012112270003
<b>Date</b>	: 27-Dec-2021	<b>Patient ID</b>	: LSHHI89154

**ULTRASOUND EXAMINATION---WHOLE ABDOMEN**

**Liver** is normal in size (14.5 cm) and normal in outline with **altered echopattern. Diffuse increase in echogenicity of liver parenchyma is noted, suggestive of fatty infiltration (grade I). Intrahepatic biliary radicles are not dilated.** No abscess or mass lesion seen. Hepatic veins, portal vein, IVC and aorta are normal. CBD is normal in caliber.

**Gall bladder** is well distended with anechoic lumen. Wall thickness is normal.

Both kidneys are normal in size, shape, position, outline and echopattern. Corticomedullary differentiation is maintained. No pelvicalyceal dilation or mass lesion is seen.

**Spleen** is normal in size and echotexture. No mass lesion seen.

**Pancreas** is normal in size, outline and echotexture.

**Urinary bladder** is normal in shape and position. No evidence of intravesical stone or mass seen.

**Prostate** is normal in size, shape and echopattern.

**Prostate measures** 3.5 x 2.6 x 3.9 cm. **Weight of prostate is 18.1 grams.**

No abnormal bowel wall thickening seen in right iliac fossa.  
No free fluid seen anywhere in abdomen.

**IMPRESSION:**

- **Fatty infiltration of liver (grade I) with no hepatomegaly.**

  
DR. POOJA GARG  
RADIOLOGIST  
REG NO- DMC/R/03398

Dr. POOJA GARG  
M.B.B.S., D.M.R.D  
Reg No. DMC/R/03398  
Radiologist

Type By : pooja

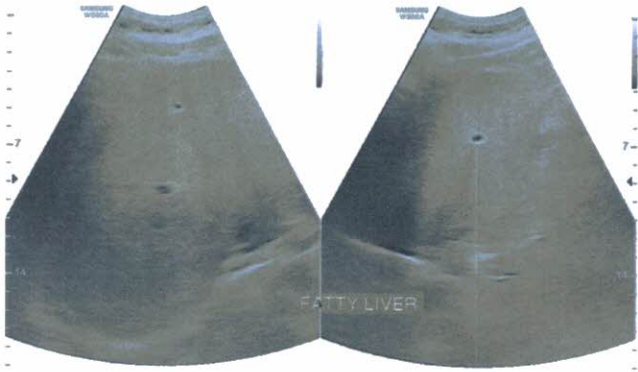47, Harsh Vihar, Pitampura, New Delhi-110034 | Ph.: 011-42480101, 9599913051  
E-mail: [oneplusul@gmail.com](mailto:oneplusul@gmail.com) | Web.: [www.oneplusul.in](http://www.oneplusul.in)





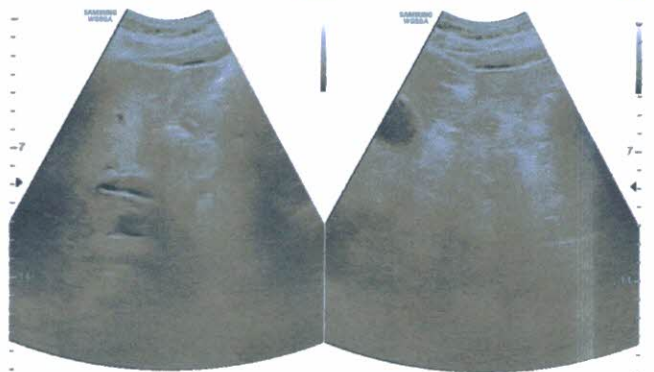WSSDA MR DEEPAK 29/M OnePlus Ultrasound Lab MI 1.5 27-12-2021  
CA1-7A / Abdomen / FR 21Hz Tib0.1 10:52:03 AM

20 G70-DR130-FA11/P100-Frq Pen./19.0cm



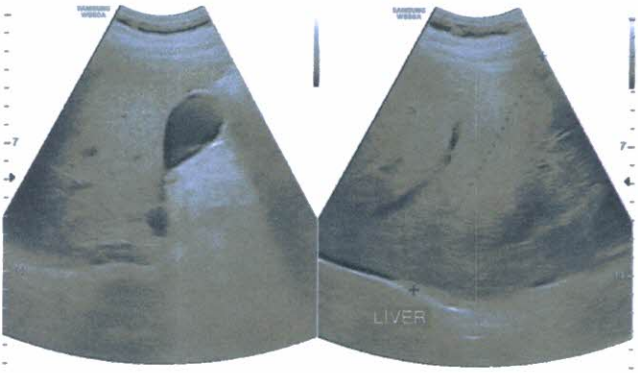
WSSDA MR DEEPAK 29/M OnePlus Ultrasound Lab MI 1.5 27-12-2021  
CA1-7A / Abdomen / FR 21Hz Tib0.1 10:52:06 AM

20 G70-DR130-FA11/P100-Frq Pen./19.0cm



WSSDA MR DEEPAK 29/M OnePlus Ultrasound Lab MI 1.5 27-12-2021  
CA1-7A / Abdomen / FR 21Hz Tib0.1 10:52:26 AM

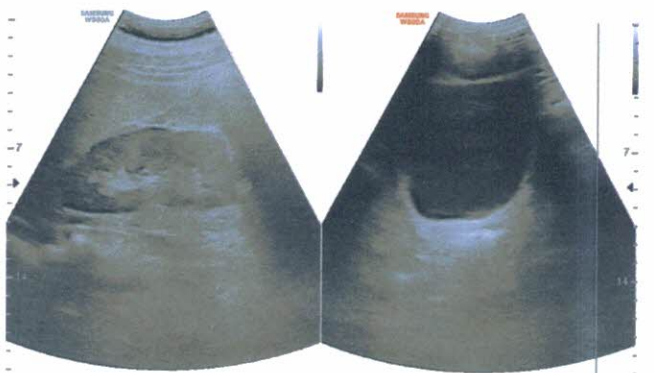
20 G70-DR130-FA11/P100-Frq Pen./19.0cm



D1 14.52 cm

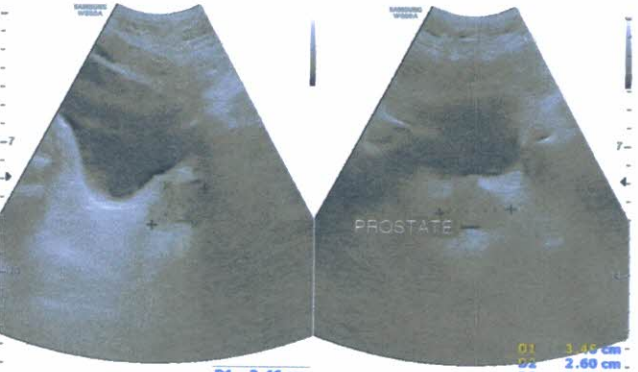WSSDA MR DEEPAK 29/M OnePlus Ultrasound Lab MI 1.5 27-12-2021  
CA1-7A / Abdomen / FR 21Hz Tib0.1 10:52:41 AM

20 G95-DR130-FA11/P100-Frq Pen./19.0cm



WSSDA MR DEEPAK 29/M OnePlus Ultrasound Lab MI 1.5 27-12-2021  
CA1-7A / Abdomen / FR 21Hz Tib0.1 10:53:01 AM

20 G68-DR130-FA11/P100-Frq Pen./19.0cm

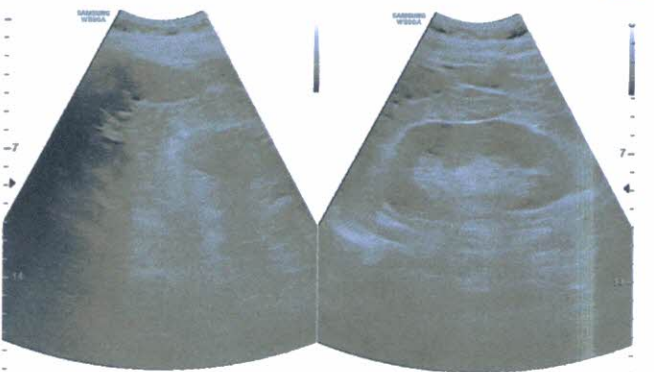


D1 3.46 cm  
D2 2.60 cm

D3 3.85 cm  
Vol. 18.14 ml

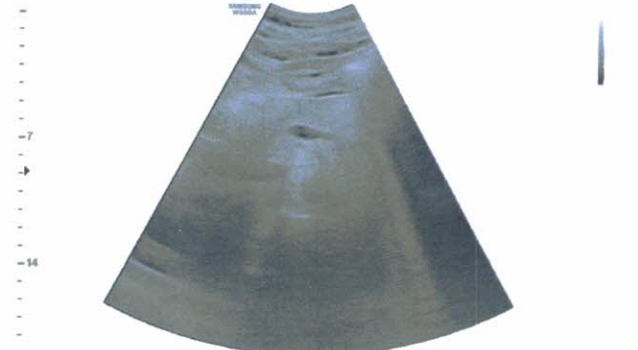WSSDA MR DEEPAK 29/M OnePlus Ultrasound Lab MI 1.5 27-12-2021  
CA1-7A / Abdomen / FR 21Hz Tib0.1 10:53:14 AM

20 G68-DR130-FA11/P100-Frq Pen./19.0cm



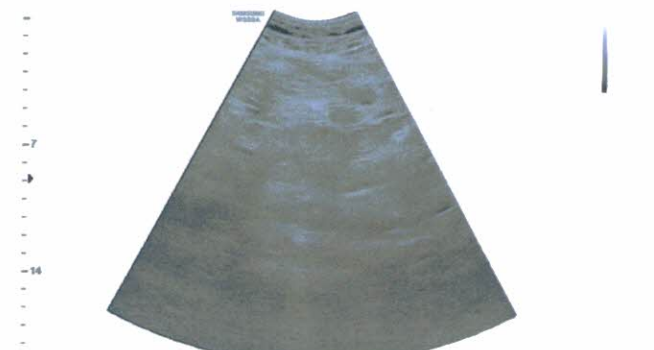WSSDA MR DEEPAK 29/M OnePlus Ultrasound Lab MI 1.5 27-12-2021  
CA1-7A / Abdomen / FR 21Hz Tib0.1 10:53:27 AM

20 G62-DR130-FA11/P100-Frq Pen./19.0cm



WSSDA MR DEEPAK 29/M OnePlus Ultrasound Lab MI 1.5 27-12-2021  
CA1-7A / Abdomen / FR 21Hz Tib0.1 10:54:13 AM

20 G59-DR130-FA11/P100-Frq Pen./19.0cm





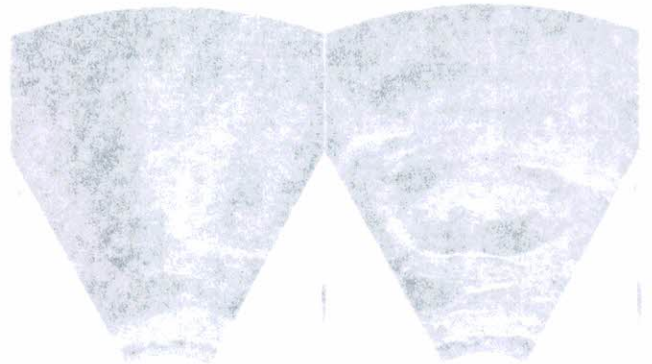
1-01  
 DATE OF COLLECTION: 15-SEP-2014  
 TIME: 11:00  
 LOCATION: ...



1-02  
 DATE OF COLLECTION: 15-SEP-2014  
 TIME: 11:05  
 LOCATION: ...



1-03  
 DATE OF COLLECTION: 15-SEP-2014  
 TIME: 11:10  
 LOCATION: ...



1-04  
 DATE OF COLLECTION: 15-SEP-2014  
 TIME: 11:15  
 LOCATION: ...



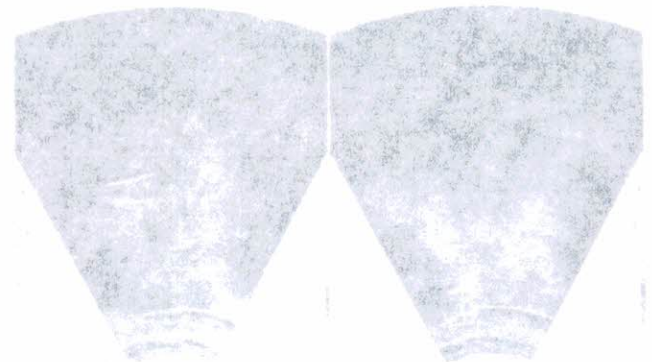
1-05  
 DATE OF COLLECTION: 15-SEP-2014  
 TIME: 11:20  
 LOCATION: ...



1-06  
 DATE OF COLLECTION: 15-SEP-2014  
 TIME: 11:25  
 LOCATION: ...



1-07  
 DATE OF COLLECTION: 15-SEP-2014  
 TIME: 11:30  
 LOCATION: ...



1-08  
 DATE OF COLLECTION: 15-SEP-2014  
 TIME: 11:35  
 LOCATION: ...



# OnePLUS

## Ultrasound Lab

**Dr. Nitin Agarwal**

Pathologist & Director  
Ex. Sr. Res. MAMC  
& Lok Nayak Hospital  
Ex. Chief of Lab Dr. Lal Path Labs.

**Dr. Pooja (Garg) Agarwal**

Radiologist & Director  
MAMC & Lok Nayak Hospital



QUALITY FIRST... ALWAYS!		Barcode No	:10110765
NAME	:Mr. DEEPAK KALA	SPECIMEN DATE	:27/Dec/2021 08:50AM
AGE/GENDER	:30 YRS/Male	SPECIMEN RECEIVED	:27/Dec/2021 01:38PM
PATIENT ID	:89154	REPORT DATE	:27/Dec/2021 04:01PM
REFERRED BY	:Dr. MEDIWHEEL	LAB NO.	:012112270003
CENTRE NAME	:ONEPLUS ULTRASOUND LAB		

Test Name	Result	Unit	Ref. Range
-----------	--------	------	------------

### HAEMATOLOGY

#### Health checkup 2 Male

**Glycosylated Hemoglobin (HbA1c)** 5.0 % Non Diabetic adults <5.7  
Prediabetic (at risk) 5.7-6.4  
Diabetes >6.4

**Estimated average blood glucose (eag)** 97

#### Reference range (mg/dl):

90 - 120:Excellent control, 121 - 150:Good Control, 151 - 180:Average Control, 181 - 210:Action Suggested

>211:Panic value

**BLOOD GROUP (ABO)** A  
**Rh typing** POSITIVE

#### NOTE :

- \* Apart from major A,B,H antigens which are used for ABO grouping and Rh typing, many minor blood group antigens exist. Agglutination may also vary according to titre of antigen and antibody.
- \* So before transfusion, reconfirmation of blood group as well as cross-matching is needed.
- \* Presence of maternal antibodies in newborns, may interfere with blood grouping.
- \* Auto agglutination (due to cold antibody, falciparum malaria, sepsis, internal malignancy etc.) may also cause erroneous result.

### CBC

Haemoglobin	13.6	g/dl	13.0-17.0
Total Leucocyte Count	9480	/cumm	4000-10000
<b>Differential leucocyte count</b>			
Neutrophils	62.3	%	40-80
Lymphocyte	26.90	%	20-40
Monocytes	6.00	%	2-10
Eosinophils	4.5	%	1-6
Basophils	0.3	%	0-2
RBC Count	4.87	million/cumm	4.5 - 5.5

Checked By.

DR. NITIN AGARWAL  
MBBS,MD(PATHOLOGIST)

Dr NITIN AGARWAL  
M B B S , MD (Path)  
DMC/R/01436

Page 1 of 6

47, Harsh Vihar, Pitampura, New Delhi-110034 | Ph.: 011-42480101, 9599913051  
E-mail: oneplusul@gmail.com | Web.: www.oneplusul.in



# OnePLUS Ultrasound Lab

**Dr. Nitin Agarwal**  
Pathologist & Director  
Ex. Sr. Res. MAMC  
& Lok Nayak Hospital  
Ex. Chief of Lab Dr. Lal Path Labs.

**Dr. Pooja (Garg) Agarwal**  
Radiologist & Director  
MAMC & Lok Nayak Hospital



QUALITY FIRST... ALWAYS!		Barcode No	:10110765
NAME	:MR. DEEPAK KALA	SPECIMEN DATE	:27/Dec/2021 08:50AM
AGE/GENDER	:30 YRS/Male	SPECIMEN RECEIVED	:27/Dec/2021 01:38PM
PATIENT ID	:89154	REPORT DATE	:27/Dec/2021 04:01PM
REFERRED BY	:Dr. MEDIWHEEL	LAB NO.	:012112270003
CENTRE NAME	:ONEPLUS ULTRASOUND LAB		

Test Name	Result	Unit	Ref. Range
PCV(Hematocrit)	43.8	%	40-50
MCV	89.9	fL	83-101
MCH	27.9	Pg	27-32
MCHC	31	G/dL	32-35
Platelet count	316000	/cumm	150000-450000
RDW-CV	13.9	%	11.4-14.0
ESR(WESTEGRENs METHOD)	10	mm in 1st hr	0-20

### BIOCHEMISTRY

<u>Blood sugar fasting</u>	93	mg/dL	70-110
<u>Blood sugar pp</u>	153	mg/dL	70.0-140.0
<u>Bun (blood urea nitrogen )</u>	13.50	mg/dl	8.9-21.6
<u>Uric acid, serum</u>	4.3	mg/dl	3.4-7.0
<u>Creatinine, serum</u>	0.8	mg/dl	0.60-1.1


### LFT(LIVER FUNCTION TEST)

Bilirubin Total	0.65	mg/dl	0.1-1.2
Bilirubin Conjugated	0.25	mg/dl	0-0.4
Bilirubin Unconjugated	0.4	mg/dl	up to 0.7
SGOT (AST)	22	U/L	0-35
SGPT (ALT)	24	U/L	<45.0
Alkaline phosphatase	102	U/L	40-129
Gamma glutamyl transpeptidase	28	U/L	<66
Total Protein	6.9	gm/dl	6.60 - 8.70
Albumin	3.9	g/dL	3.8-5.1
Globulin	3.00	gm/dl	1.8-3.4
Albumin/Globulin Ratio	1.30		1.10 - 2.50

### LIPID PROFILE

Cholesterol	162	mg/dl	50-200
Triglycerides	164	mg/dL	25-150

Checked By.

  
DR. NITIN AGARWAL  
MBBS,MD(PATHOLOGIST)

Dr NITIN AGARWAL  
M B B S , MD (Path)  
DMC/R/01436

Page 2 of 6

47, Harsh Vihar, Pitampura, New Delhi-110034 | Ph.: 011-42480101, 9599913051  
E-mail: [oneplusul@gmail.com](mailto:oneplusul@gmail.com) | Web.: [www.oneplusul.in](http://www.oneplusul.in)

Clinical correlation is essential for final diagnosis. • If test results are unsatisfactory please contact personally or on phone. • This report is for perusal of doctors only.  
• All disputes Subject to Delhi Jurisdiction only. • Not for medicolegal purposes. • All congenital anomalies in a foetus may not be diagnosed in routine obstetric ultrasound.



# OnePLUS

## Ultrasound Lab

**Dr. Nitin Agarwal**  
Pathologist & Director  
Ex. Sr. Res. MAMC  
& Lok Nayak Hospital  
Ex. Chief of Lab Dr. Lal Path Labs.

**Dr. Pooja (Garg) Agarwal**  
Radiologist & Director  
MAMC & Lok Nayak Hospital



NAME	QUALITY FIRST... ALWAYS! :Mr. DEEPAK KALA	Barcode No	:10110765
AGE/GENDER	:30 YRS/Male	SPECIMEN DATE	:27/Dec/2021 08:50AM
PATIENT ID	:89154	SPECIMEN RECEIVED	:27/Dec/2021 01:38PM
REFERRED BY	:Dr. MEDIWHEEL	REPORT DATE	:27/Dec/2021 04:01PM
CENTRE NAME	:ONEPLUS ULTRASOUND LAB	LAB NO.	:012112270003

Test Name	Result	Unit	Ref. Range
HDL Cholesterol	45	mg/dL	30-70
LDL cholesterol	84	mg/dL	<130
VLDL cholesterol	32.8	mg/dL	5-40
Cholesterol/HDL Ratio	3.6		Low Risk 3.3-4.97 Average Risk 4.4-7.1 Moderate Risk 7.1-11.0 High Risk >11.0
LDL/HDL Ratio	1.9		0 - 3.55

According to ATP III and NCEP guidelines

Parameter	Normal	Desirable	Borderline	High
Total cholesterol	<200	200-239		240
Triglycerides	<150	150-199	200-499	500
LDL	Optimal <100 Near Optimal 100-129	130-159	160-180	190
HDL	<40 : LOW 60 : HIGH			

### ENDOCRINOLOGY

#### PSA TOTAL

Prostatic specific antigen, Total 1.20 ng/ml <4.0

< 40 years	0.21 to 1.72 ng/ml
40 - 49	0.27 to 2.19 ng/ml
50 - 59	0.27 to 3.42 ng/ml
60 - 69	0.22 to 6.16 ng/ml
> 69	0.21 to 6.77 ng/ml

#### Notes:

PSA is principally produced by the glandular epithelium of the prostate, and is secreted in the seminal fluid. PSA is also present in

Checked By.

DR. NITIN AGARWAL  
MBBS, MD(PATHOLOGIST)

Dr NITIN AGARWAL  
M B B S , MD (Path)  
DMC/R/01436

Page 3 of 6

47, Harsh Vihar, Pitampura, New Delhi-110034 | Ph.: 011-42480101, 9599913051  
E-mail: oneplusul@gmail.com | Web.: www.oneplusul.in



# OnePLUS

## Ultrasound Lab

**Dr. Nitin Agarwal**  
Pathologist & Director  
Ex. Sr. Res. MAMC  
& Lok Nayak Hospital  
Ex. Chief of Lab Dr. Lal Path Labs.

**Dr. Pooja (Garg) Agarwal**  
Radiologist & Director  
MAMC & Lok Nayak Hospital



NAME	QUALITY FIRST... ALWAYS! : <b>MR. DEEPAK KALA</b>	Barcode No	: <b>10110765</b>
AGE/GENDER	: 30 YRS/Male	SPECIMEN DATE	: 27/Dec/2021 08:50AM
PATIENT ID	: 89154	SPECIMEN RECEIVED	: 27/Dec/2021 01:38PM
REFERRED BY	: Dr. MEDIWHEEL	REPORT DATE	: 27/Dec/2021 04:01PM
CENTRE NAME	: ONEPLUS ULTRASOUND LAB	LAB NO.	: 012112270003

Test Name	Result	Unit	Ref. Range
urine and blood. PSA acts on seminal fluid to fluidify and increase sperm mobility. PSA levels rise in prostatic pathologies such as benign prostatic hyperplasia (BPH) or prostate cancer.			

### THYROID PROFILE(T3,T4,TSH)

Triiodothyronine total [t3]	0.89	ng/dl	0.52-1.9
Thyroxine total [t4]	8.50	µg/dl	4.4 - 10.8
TSH (Thyroid Stimulating Hormone)	3.60	µU/ml	0.25-5.0

### AGE WISE VARIATION IN TSH

AGE	TSH(µU/ml)	AGE	TSH(µU/ml)
1-4 weeks	1.00 - 19.0	16-20 yrs	0.25 - 5.0
1-12 mths	1.70 - 9.1	21 - 80 yrs	0.25 - 5.0
1-5 yrs	0.80 - 8.2	I <sup>st</sup> trimester	0.25 - 5.0
6-10 yrs	0.25 - 5.0	II <sup>nd</sup> trimester	0.50 - 5.0
11-15 yrs	0.25 - 5.0	II <sup>rd</sup> trimester	0.4 - 6.0

### Reference ranges - Interpretation of Diagnostic tests - (Jacques Wallach)

1. Primary hypothyroidism is accompanied by depressed serum T3 and T4 values and elevated serum TSH level.
2. Primary hyperthyroidism is accompanied by elevated serum T3 and T4 levels along with depressed TSH values.
3. Slightly elevated T3 levels may be found in pregnancy and estrogen therapy, while depressed levels may be encountered in severe illness, renal failure and during therapy with drugs like propranolol and propyl thiouracil.
4. Although elevated TSH levels are nearly always indicative of primary hypothyroidism, and may be seen in secondary thyrotoxicosis

### CLINICAL PATHOLOGY

#### URINE ROUTINE

#### Physical examination

Quantity	30	ML
Colour	PALE YELLOW	
Transparency	CLEAR	CLEAR
Sp.gravity	1.015	1.010-1.030
pH	6.00	
Reaction	ACIDIC	ACIDIC

Checked By.

DR. NITIN AGARWAL  
MBBS, MD(PATHOLOGIST)

Dr NITIN AGARWAL  
M B B S , MD (Path)  
DMC/R/01436

Page 4 of 6

47, Harsh Vihar, Pitampura, New Delhi-110034 | Ph.: 011-42480101, 9599913051  
E-mail: oneplusul@gmail.com | Web.: www.oneplusul.in



# OnePLUS Ultrasound Lab

**Dr. Nitin Agarwal**  
Pathologist & Director  
Ex. Sr. Res. MAMC  
& Lok Nayak Hospital  
Ex. Chief of Lab Dr. Lal Path Labs.

**Dr. Pooja (Garg) Agarwal**  
Radiologist & Director  
MAMC & Lok Nayak Hospital



NAME	MR. DEEPAK KALA	Barcode No	:10110765
AGE/GENDER	:30 YRS/Male	SPECIMEN DATE	:27/Dec/2021 08:50AM
PATIENT ID	:89154	SPECIMEN RECEIVED	:27/Dec/2021 01:38PM
REFERRED BY	:Dr. MEDIWHEEL	REPORT DATE	:27/Dec/2021 04:01PM
CENTRE NAME	:ONEPLUS ULTRASOUND LAB	LAB NO.	:012112270003

Test Name	Result	Unit	Ref. Range
<b><u>Chemical examination</u></b>			
Urine protein	NIL		NIL
Urine sugar	NIL		NIL
Bilirubin, urine	NEGATIVE		NEGATIVE
Urobilinogen	NORMAL		NORMAL
Ketones	NEGATIVE		NEGATIVE
<b><u>Microscopic examination</u></b>			
<b>Pus cells.</b>	1-2	/HPF	0-2
Epithelial cells	1-2	/HPF	NIL
R.B.C.	NIL	/HPF	NIL
Casts	NIL	/HPF	NIL
Crystals	NIL	/HPF	NIL
Bacteria	NIL	/HPF	NIL
Others.	NIL	NIL	NIL
<b>STOOL ROUTINE</b>			
<b><u>Physical examination</u></b>			
Colour	BROWNISH		
Consistency	SEMI FORMED		Semi Formed
Blood	ABSENT		Absent
Mucus	ABSENT		Absent
<b><u>Chemical examination, stool</u></b>			
pH	6.00		
<b><u>Microscopic examination</u></b>			
Pus cells	NIL	/HPF	NIL
Red blood cells	NIL	/HPF	NIL
Ova	NIL		NIL
Cysts	NIL		NIL
Bacteria	NIL	/HPF	NIL
Others	NIL		

Checked By.

DR. NITIN AGARWAL  
MBBS, MD (PATHOLOGIST)

Dr NITIN AGARWAL  
M B B S , MD (Path)  
DMC/R/01436

Page 5 of 6

47, Harsh Vihar, Pitampura, New Delhi-110034 | Ph.: 011-42480101, 9599913051  
E-mail: oneplusul@gmail.com | Web.: www.oneplusul.in

Clinical correlation is essential for final diagnosis. • If test results are unsatisfactory please contact personally or on phone. • This report is for perusal of doctors only.  
• All disputes Subject to Delhi Jurisdiction only. • Not for medicolegal purposes. • All congenital anomalies in a foetus may not be diagnosed in routine obstetric ultrasound.



# OnePLUS Ultrasound Lab

**Dr. Nitin Agarwal**

Pathologist & Director  
Ex. Sr. Res. MAMC  
& Lok Nayak Hospital  
Ex. Chief of Lab Dr. Lal Path Labs.

**Dr. Pooja (Garg) Agarwal**

Radiologist & Director  
MAMC & Lok Nayak Hospital




QUALITY FIRST... ALWAYS!			
NAME	: Mr. DEEPAK KALA	Barcode No	: 10110765
AGE/GENDER	: 30 YRS/Male	SPECIMEN DATE	: 27/Dec/2021 08:50AM
PATIENT ID	: 89154	SPECIMEN RECEIVED	: 27/Dec/2021 01:38PM
REFERRED BY	: Dr. MEDIWHEEL	REPORT DATE	: 27/Dec/2021 04:01PM
CENTRE NAME	: ONEPLUS ULTRASOUND LAB	LAB NO.	: 012112270003

Test Name	Result	Unit	Ref. Range
-----------	--------	------	------------

\*\*\* End Of Report \*\*\*

Checked By.

  
DR. NITIN AGARWAL  
MBBS, MD(PATHOLOGIST)

Dr NITIN AGARWAL  
M B B S , MD (Path)  
DMC/R/01436

Page 6 of 6

47, Harsh Vihar, Pitampura, New Delhi-110034 | Ph.: 011-42480101, 9599913051  
E-mail: [oneplusul@gmail.com](mailto:oneplusul@gmail.com) | Web.: [www.oneplusul.in](http://www.oneplusul.in)

Clinical correlation is essential for final diagnosis. • If test results are unsatisfactory please contact personally or on phone. • This report is for perusal of doctors only.  
• All disputes Subject to Delhi Jurisdiction only. • Not for medicolegal purposes. • All congenital anomalies in a foetus may not be diagnosed in routine obstetric ultrasound.