



Summary

Ref. By :
Medication :
Objective :

Protocol : BRUCE
History :

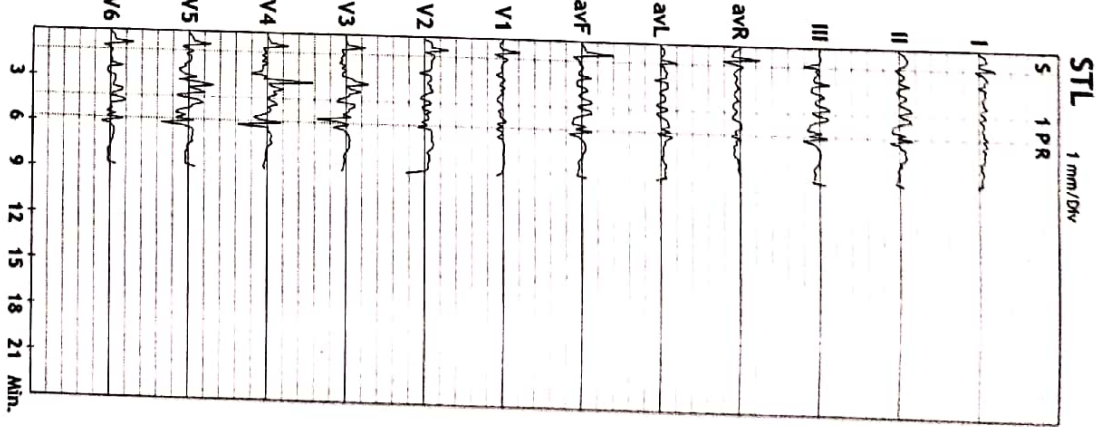
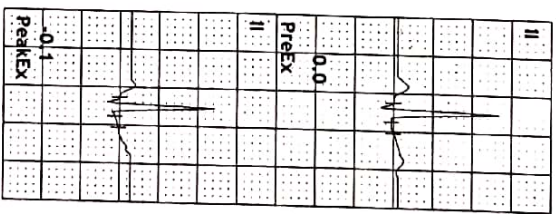
KSHIPRA SCANS & LABS
ZB COURT CHOURAHA UDAIPUR
2208102559/MRS RINKU MALI 31 Yrs/Female 0 Kg/0 Cms
Date: 27-Aug-2022 01:01:43 PM

Stage	StageTime (Min:Sec)	PhaseTime (Min:Sec)	Speed (mph)	Grade (%)	METS	H.R. (bpm)	B.P. (mmHg)	R.P.P. x100	PVC	Comments
Supine					1.0	88	120/80	105	-	
Standing					1.0	92	120/80	110	-	
ExStart					1.0	117	120/80	140	-	
Stage 1	3:00	3:01	1.7	10.0	4.7	138	130/90	179	-	
PeakEx	1:29	4:30	2.1	12.0	5.4	154	130/90	200	-	
Recovery	1:00		0.0	0.0	1.0	110	130/90	143	-	
Recovery	3:00		0.0	0.0	1.0	93	120/80	111	-	
Recovery					0.0	0	---/---	0	-	

Findings :

Exercise Time : 4:30 minutes
 Max HR attained : 154 bpm 81% of Max Predictable HR 189
 Max BP : 130/90(mmHg)
 Workload attained : 5.4 (Fair Effort Tolerance)
 No significant ST segment changes noted during exercise or recovery.
 No Angina/Arrhythmia/S3/murmur
 Final Impression : Test is negative for inducible ischaemia.
 Maximum Depression: 4:30

Advice/Comments:





12 Lead + Median

4X 60 mS Post J

2208102559/MRS RINKU MARLB8 bpm
31 Yrs/Female METS: 1.0
0 Kg/0 Cms BP: 120/80
Date: 27-Aug-2022 01:03:43 PM

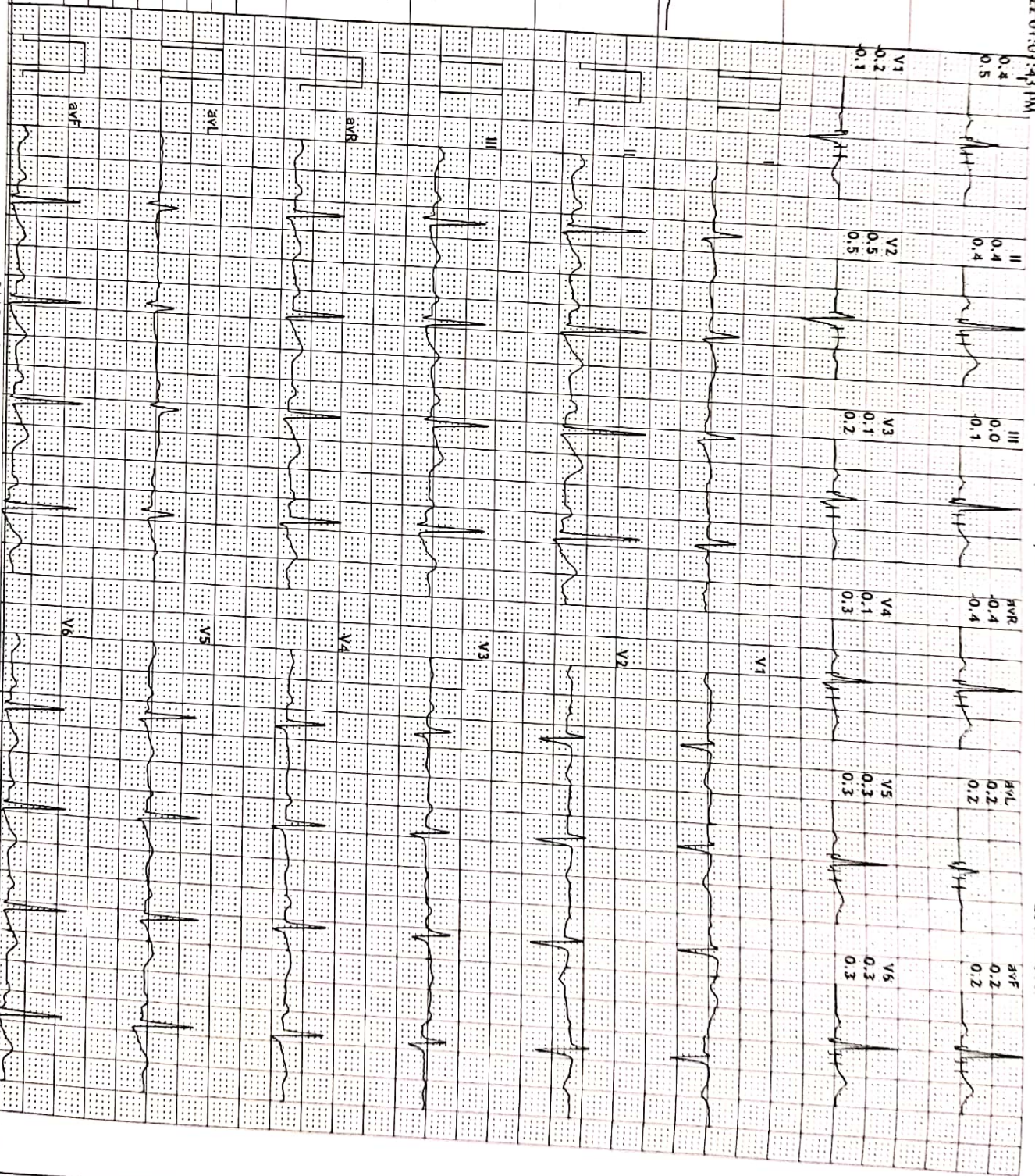
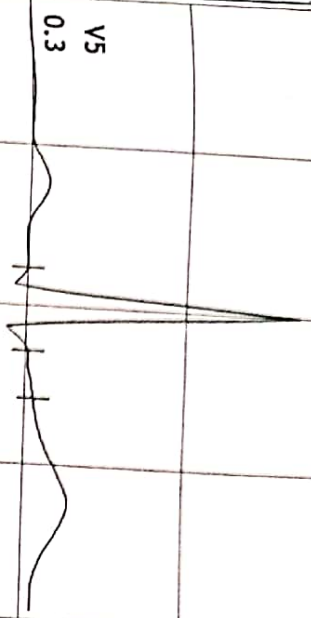
MPHR: 46% of 189
Speed: 1.1 mph
Grade: 0.0%

KSHIPRA SCANS & LABS

2B COURT CHOURAHA UDAPUR

Raw ECG RRUC
(1.0-100)HZ
Ex Time 00:30
BLC: On
Notch: On

Supine
10.0 mm/mV
25 mm/Sec.





12 Lead + Median

2208102559/MRS RINKU N/A P2 bpm
31 Yrs/Female
0 Kg/0 Cms
Date: 27-Aug-2022 01:01:43 PM
BP: 120/80

MPHR: 40% of 189
Speed: 0.0 mph
Grade: 0.0%

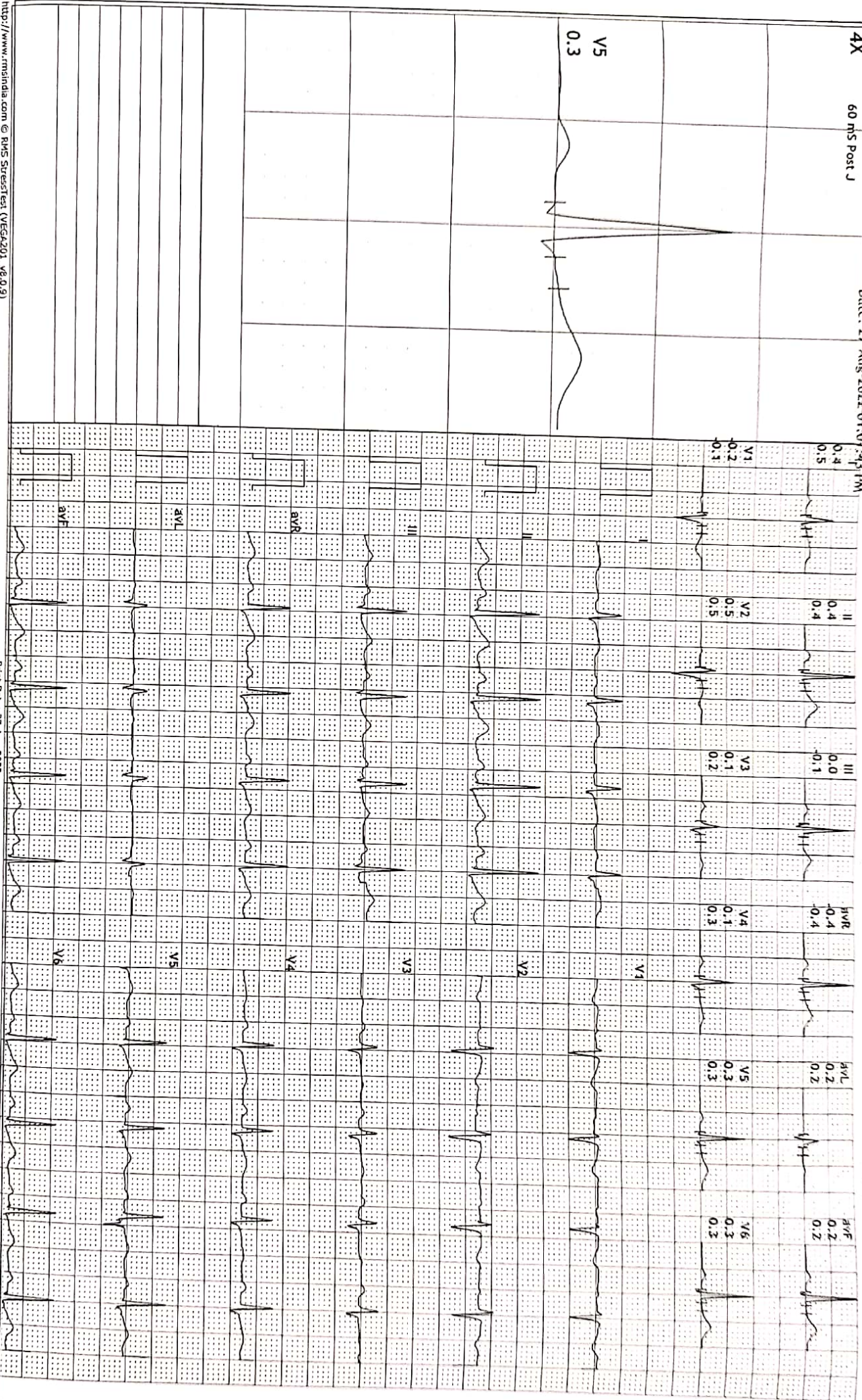
Raw ECG
HRUCE
(1.0-100)HZ

Ex Time 00:36
RLC : On
Notch : On

Standing
10.0 mm/mV
25 mm/Sec.

4X 60 ms Post J

V5
0.3





12 Lead + Median

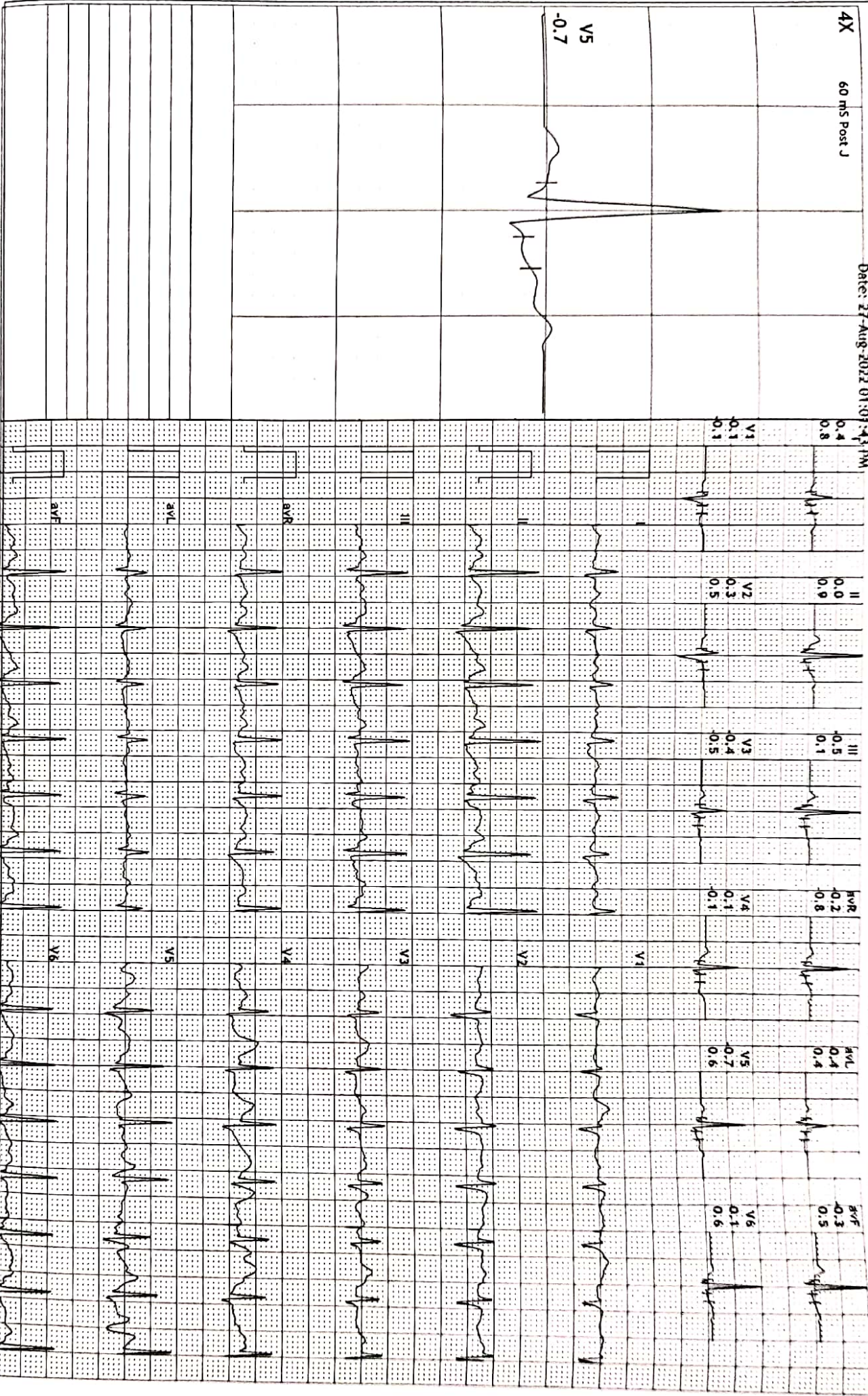
2208102559/MRS RINKU MALHAR 38 bpm
31 Yrs/Female METS: 4.7
0 Kg/0 Cms BP: 130/90
Date: 27-Aug-2022 01:07:43 PM

MPHR: 73% of 189
Speed: 1.7 mph
Grade: 10.0%

Raw ECG
BRUCE
(1.0-100)Hz

Ex Time 03:00
BLC: On
Notch: On

BRUCE: Stage 1 (3:00)
10.0 mm/mV
25 mm/Sec.





12 Lead + Median

2208102559/MRS RINKU MALI 54 bpm
31 Yrs/Female
0 Kg/0 Cms
BP: 130/90
Date: 27-Aug-2022 01:01:43 PM

MPHR: 81% of 189
Speed: 2.1 mph
Grade: 12.0%

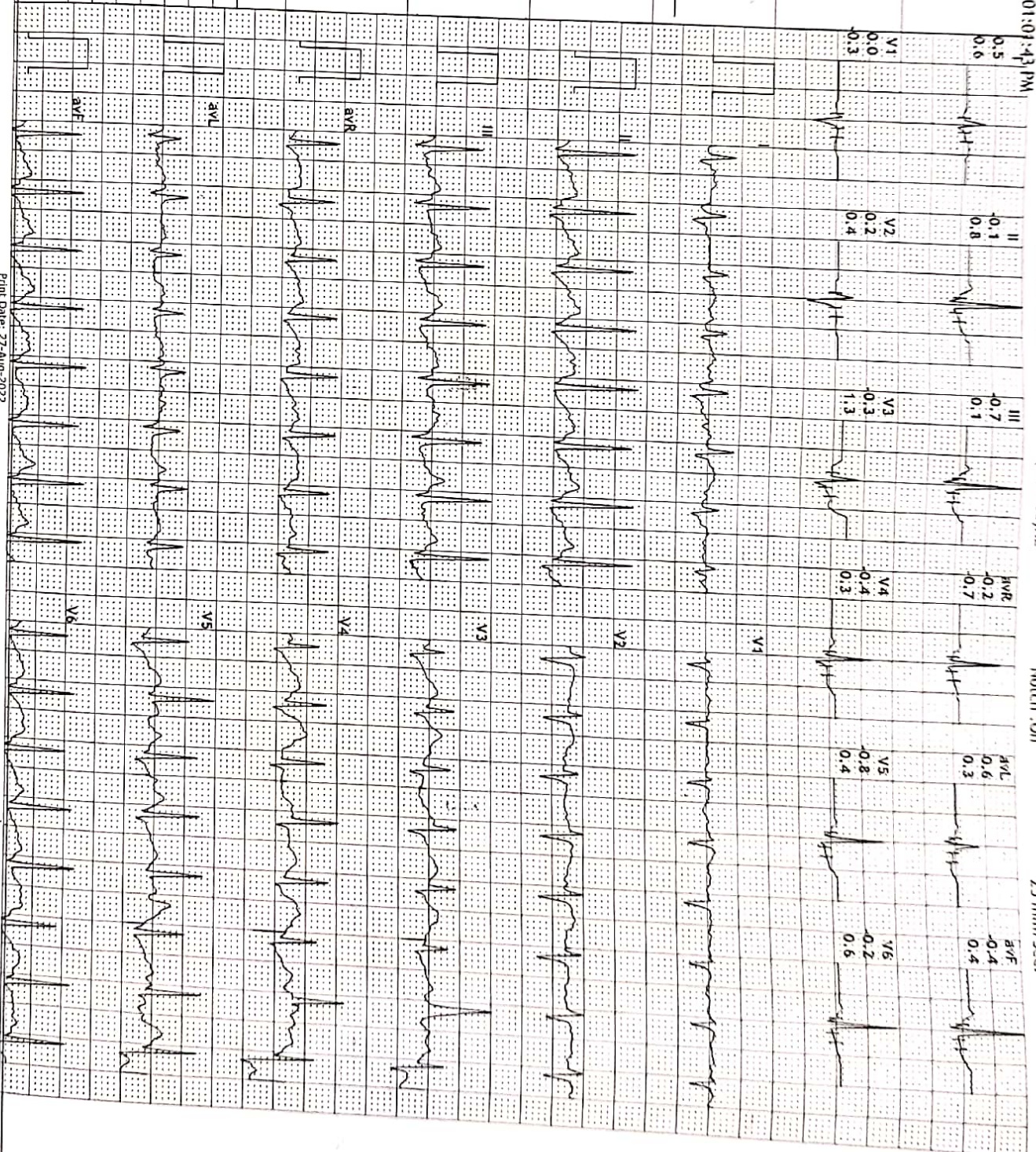
Raw ECG
BRUCE
(1.0-100)Hz

Ex Time 04:29
BLC : On
Hitch : On

BRUCE: PeakEx(1:29)
10.0 mm/mV
25 mm/Sec.

4X 60 ms Post J

V5
-0.8





12 Lead + Median

22081025559/MRS RINKU NMA II 10 bpm
31 Yrs/Female METS: 1.0
0 Kg/0 Cms BP: 130/90
Date: 27-Aug-2022 01:01:43 PM

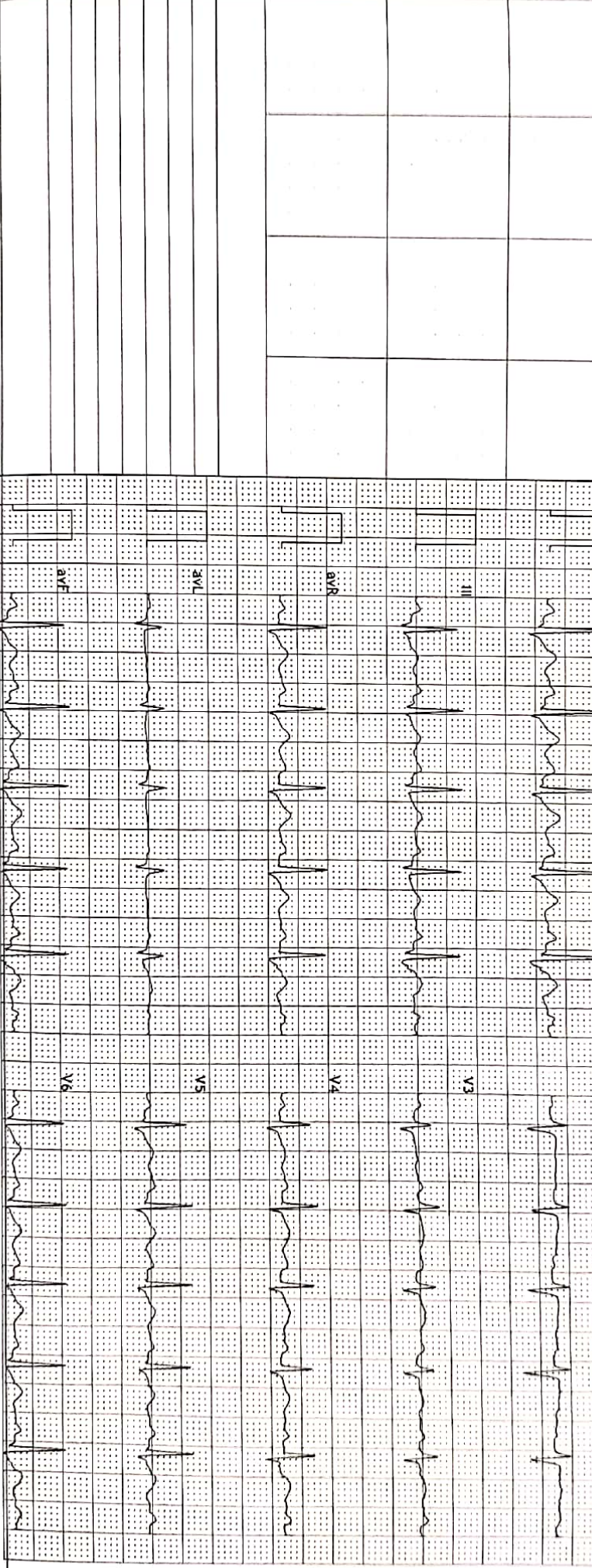
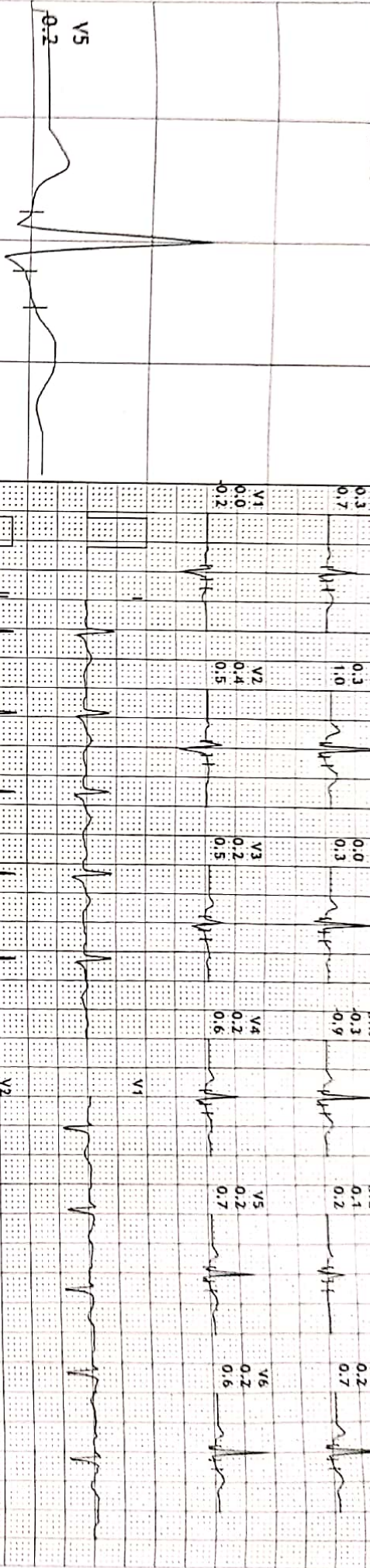
MPHR: 58% of 189
Speed: 0.0 m/s
Grade: 0.0%

KSHIPRA SCANS & LABS
2B COURT CHOURAHA UDALPUR

Raw ECG
BRUCE
(1.0-100)HZ
Ex Time 04:30
BLC : On
Notch : On

Recovery(1:00)
10.0 mm/mV
25 mm/Sec.

4X 60 ms Post J





12 Lead + Median

22081025559/MRS RINKU NMI B3 bpm
31 Yrs/Female
0 Kg/0 Cms
Date: 27-Aug-2022 01:01:43 PM

MPHR: 49% of 189
Speed: 0.0 mph
Grade: 0.0%

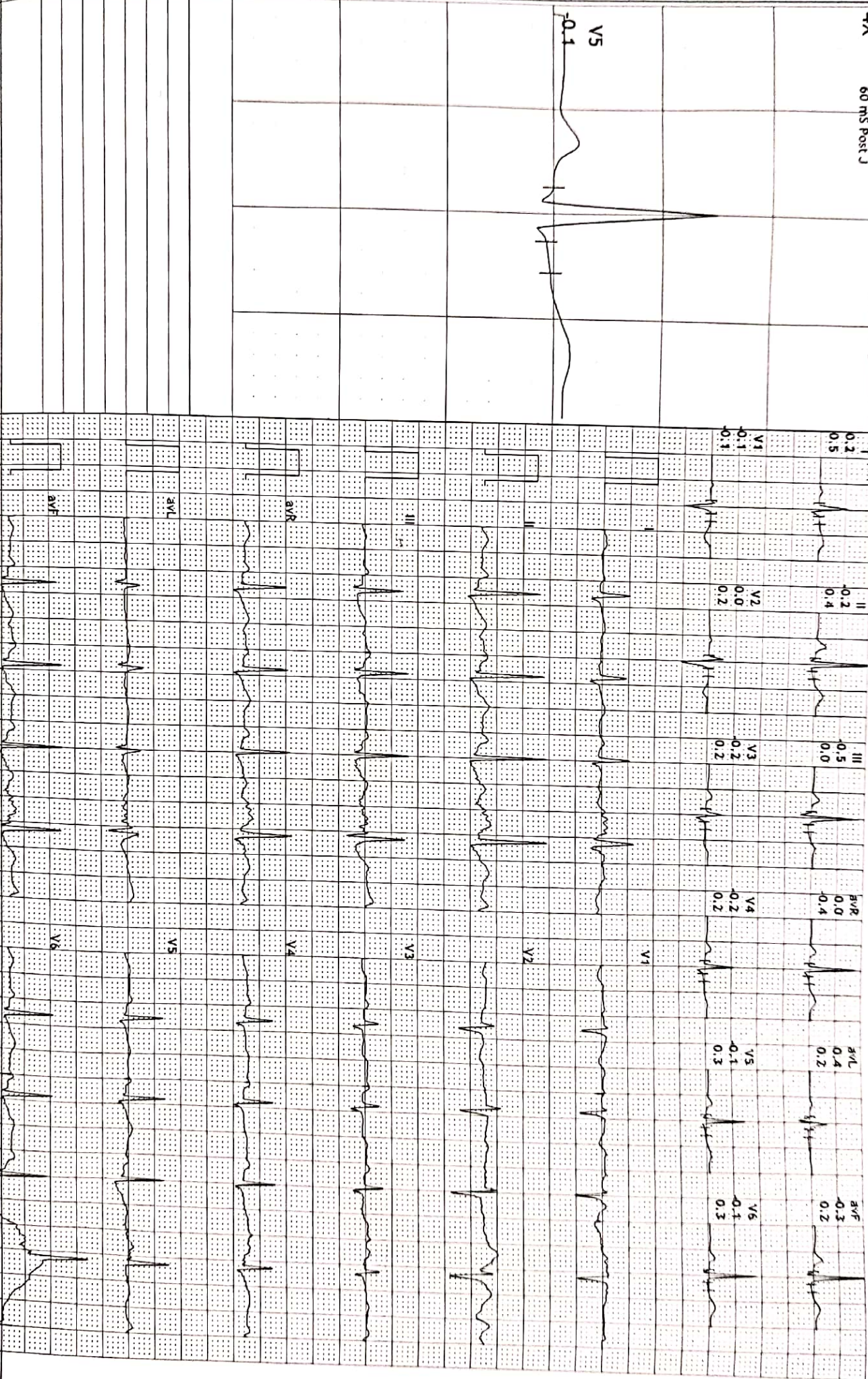
KSHIPRA SCANS & LABS

2B COURT CHOURAHA UDAIPUR

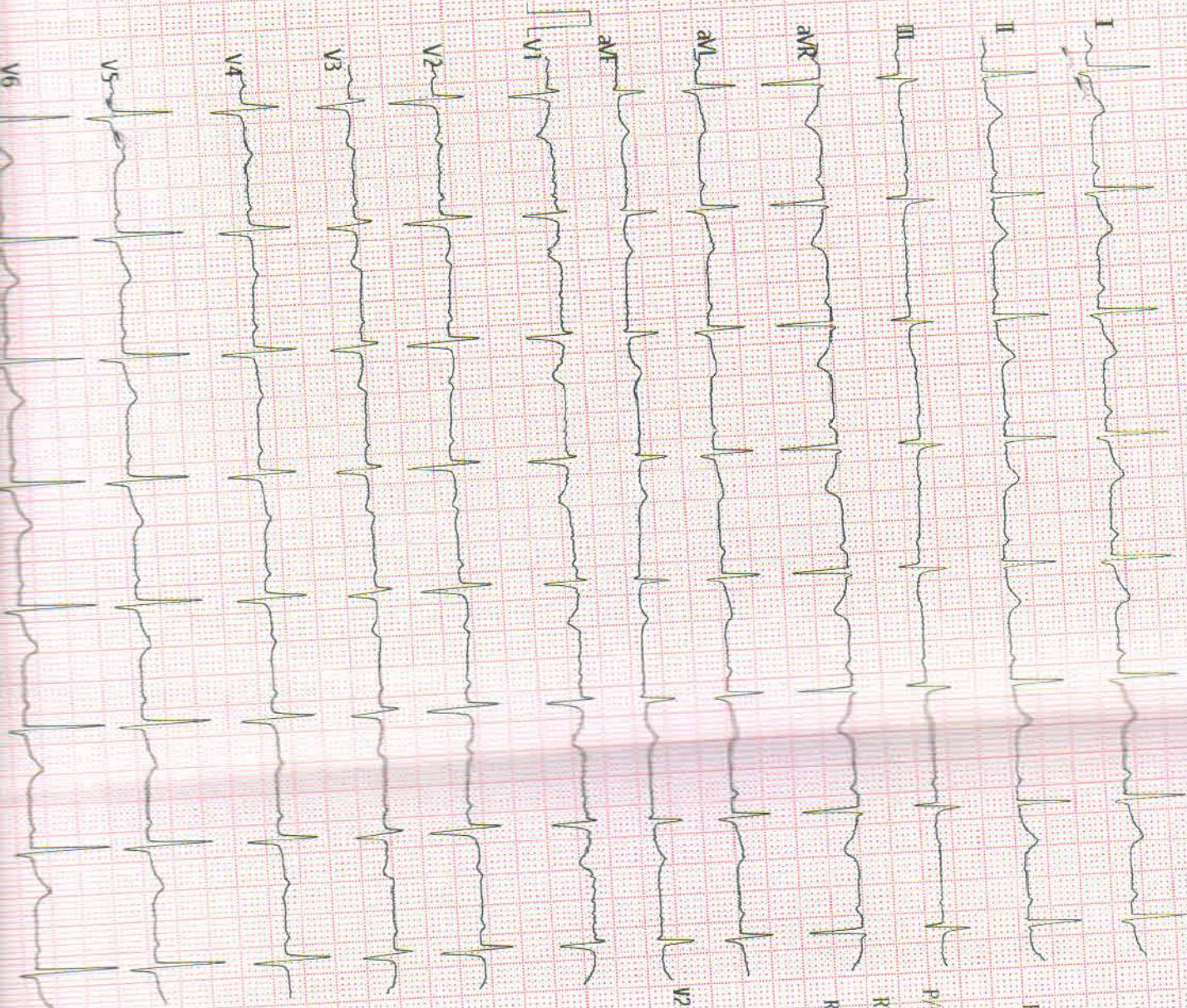
Raw ECG
BRUCE
(1.0-100)HZ
Ex Time 04:30
BLC : On
Notch : On

Recovery(3:00)
10.0 mm/mV
25 mm/Sec.

4X 60 MS Post J



10mm/mV



Vent. Rate(BPM) : 73

PR Int.(ms) : 153

P/QRS/T Int.(ms) : 104 98 200

QT/QTc Int.(ms) : 406 451

P/QRS/T Axis(Deg) : 40 39 44

RV1/SV5 Amp.(mV) : 0.16 0.38

RV5/SV1 Amp.(mV) : 1.04 0.57

V2-33 Technician

<ECG Analysis Result>

8000 Normal Sinus Rhythm

*** Normal ECG ***

Note: Unconfirmed Report Need to Review

ST LEVEL (mV)

	I	II	III	aVR	aVL	aVF
I						
II	+0.04	+0.02	-0.01	-0.03	+0.02	+0.00
III						
aVR						
aVL						
aVF						
V1	+0.00	+0.06	+0.00	+0.02	+0.01	+0.01
V2						
V3						
V4						
V5						
V6						

Name	:	Rinku mali	Age	:	31 Yrs. / F
Thanks To	:	Mediwheel wellness	Date	:	27-08-2022

X-RAY CHEST (PA VIEW)

Both lung fields appear normal.

No e/o Koch's lesion or consolidation seen.

Both CP angles appear clear.

Both domes of diaphragm appear normal.

Heart size and aorta are within normal limits.

Bony thorax under vision appears normal.

Both hila appear normal.


Consultant Radiologist

(This report is not valid for any Medico-legal purpose)

Name	:	Rinku mali	Age	:	31Yrs. / F
Thanks To	:	Mediwheel wellness	Date	:	27-08-2022

ULTRASOUND STUDY OF WHOLE ABDOMEN

LIVER:

Liver is normal in size, shape & **bright echotexture**. No focal mass lesion is seen. Intra hepatic biliary radicles are normal. Portal vein is normal in caliber.

GALL BLADDER :

Gall bladder is well distended. The wall thickness appears normal. No evidence of calculus or mass lesion is seen. C.B.D. appears normal.

PANCREAS :

Pancreas is normal in size, shape & echotexture. No focal mass lesion is seen.

SPLEEN :

Spleen is normal in size, shape & echotexture. No focal mass lesion is seen.

BOTH KIDNEYS :

Both kidneys are normal in size, shape & echotexture. Renal parenchyma appears normal. No evidence of hydronephrosis, calculus or cortical scarring is seen in either kidney.

Right kidney measures : 11.0 x 4.5 cms.

Left kidney measures : 10.7 x 4.9 cms.

URINARY BLADDER :

Urinary bladder is well distended and appears normal in contour. The wall thickness appears normal.

UTERUS :

Uterus is AVAF, normal in size, shape and echotexture. It measures 6.5 x 5.2 x 3.8 cms. Endometrial appears normal and measures 8.5mm.

BOTH OVARIES :

Both ovaries are normal in size, shape and echotexture.

Right ovary measures: 2.9 x 1.8 cms.

Left ovary measures: 3.4 x 2.1 cms.

No obvious abdominal lymphadenopathy is seen.

No free fluid is seen in peritoneal cavity.

OPINION:

- **Fatty liver Grade-I**



Dr Bharat Jain

MD (Radio-Diagnosis)

Consultant Radiologist

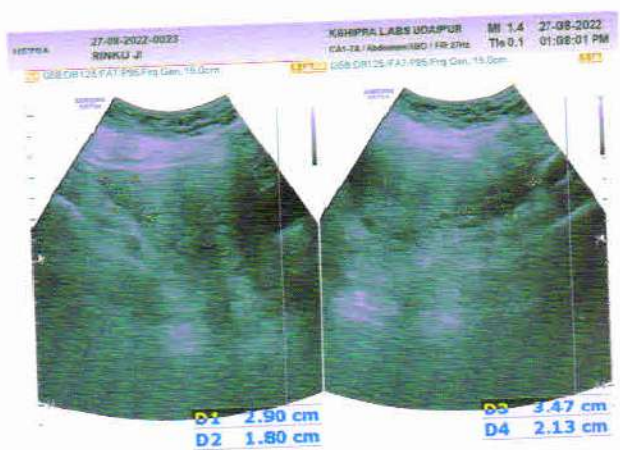
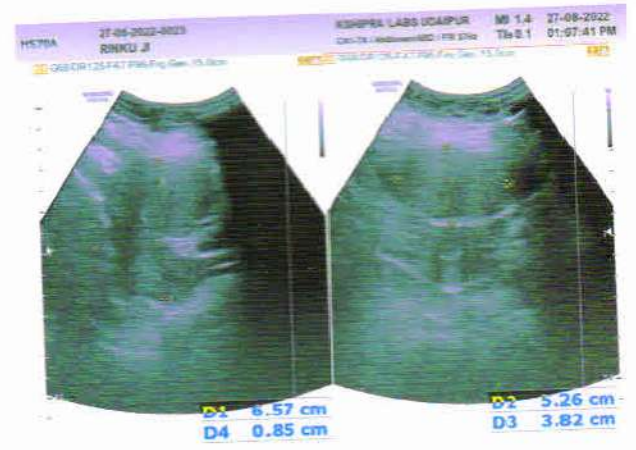
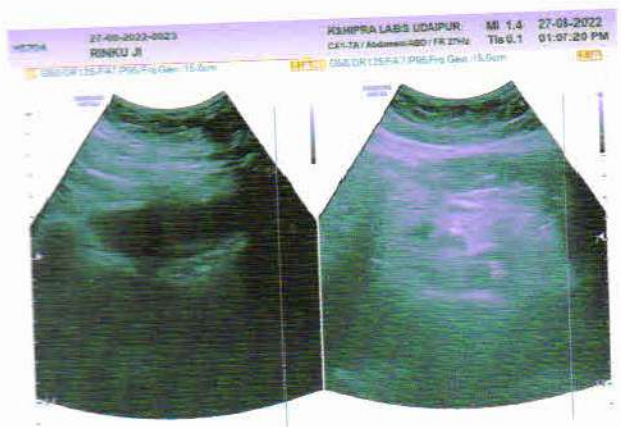
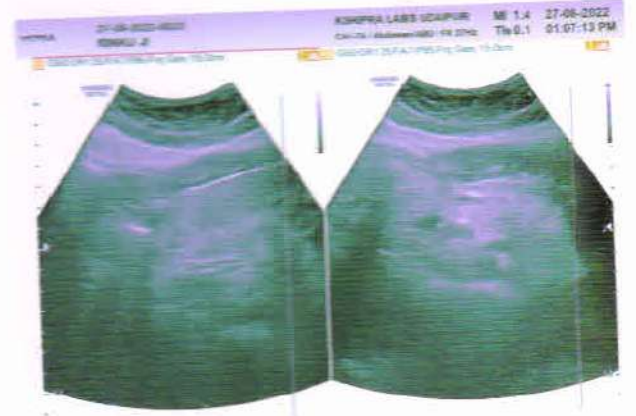
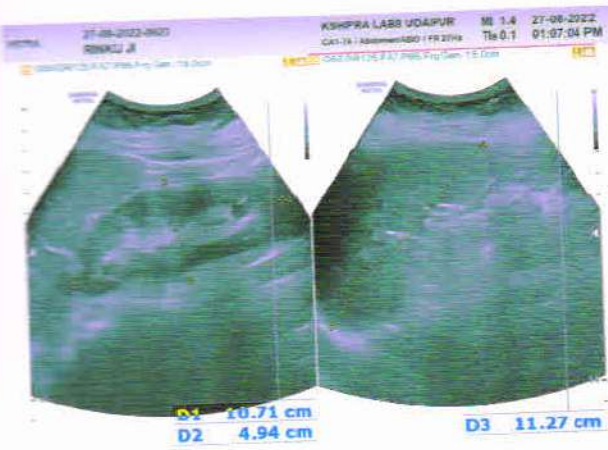
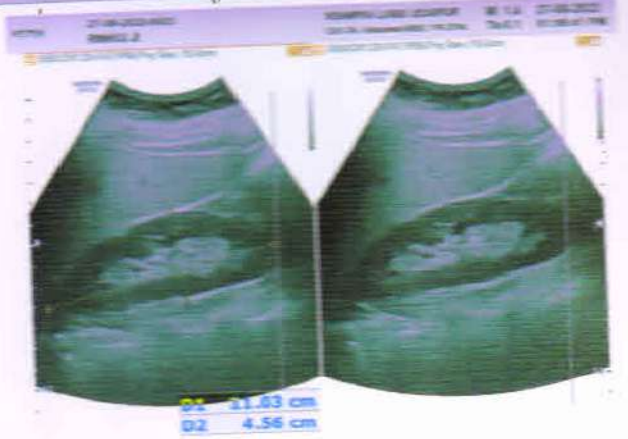
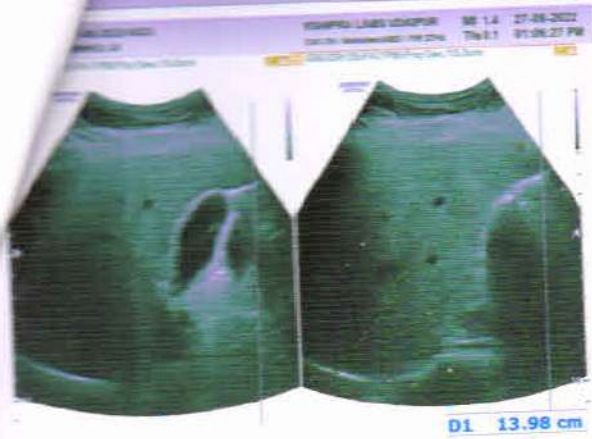(This report is not valid for any Medico-legal purpose)

ENCL:- PCPNDT Registration Certificate is printed on the back side of this report.

2-B Ground Floor, Court Choraha, Main Road Tehsil ke Samne, Udaipur 313001 (Raj.),

Mob. : 7229961115, 7229970005, 7229901188

(24 x 7 Customer Service) Email : kshipralabsudaipur@gmail.com



MER- MEDICAL EXAMINATION REPORT

Date of Examination	27/08/2022		
NAME	Rinku mali		
AGE	31	Gender	F
HEIGHT(cm)	5	WEIGHT (kg)	67 kg
B.P.	120/90		
ECG	Normal		
X Ray	Normal		
Vision Checkup	Normal		
Present Ailments			
Details of Past ailments (If Any)			
Comments / Advice : She /He is Physically Fit	fit		

Dr. BHARAT JAI
CONSULTANT
RMC NO. 1

Signature with Stamp of Medical Examiner

MRS. RinKu Mali

31/F

27/08/22

clo for Eye check up.

DVA < 6/6
6/6

NVA < N/6
N/6

colours vision - (N)

Sharva

Dr. SHARVA PANDYA

M.B.B.S., M.S. (Ophth.)

Jai Drishti Eye Hospital
Udaipur (Raj)

Cosmetology Partner :



www.vibraclinic.com
9168046591