

# GAURAV MULTI SPECIALITY HOSPITAL TIKHAMPUR= BALLIA

PATIENT. AMRENDRA KUMAR  
REFERED BY DR SELF

DATE 30/03/2023  
AGE 32/M

## ECHOCARDIOGRAPHY & COLOR DOPPLER REPORT

Quality of Imaging : Fair.

MEASUREMENT/DIMENSIONS	ABSOLUTE VALUE	NORMAL ( Adult )
Aortic Root Diameter	24.2 mm.	20 – 37 mm. < 22 mm/ m2
Aortic Valve Opening	19.7 mm.	15 – 26 mm.
Left Atrial Dimension	37.6 mm.	19 - 40 mm. < 22 mm/ m2
RV Dimension	21 mm.	07 – 26 mm.
RV Thickness	8.8 mm.	03 – 09 mm.
LV ED Dimension	39.2 mm.	37 - 56 mm. < 32 mm/ m2
LV ES Dimension	26.7 mm.	22 - 40 mm.
IVS Thickness	9.1 mm.	09 – 11 mm.
LVPW Thickness	10.3 mm.	05 – 11 mm.
Mitral Valve Area	5.75 cm2	> 6 cm2 .
Tricuspid Valve Area	6.49 cm2	> 7 cm2 .
IVSeD / IV SeS	06 – 10 mm	06 – 12 mm.

MORPHOLOGICAL					
Mitral Valve	Normal	Right Ventricle	Normal	Inter Atrial Septum	Normal
Tricuspid Valve	Normal	Left Ventricle	Normal	I.Ventricular Septum	Normal
Aortic Valve	Normal	Right Atrium	Normal	Aorta	Normal
Pulmonary Valve	Normal	Left Atrium	Normal	Pulmonary Artery	Normal

### 2 D IMAGING :

LV/ RV/ LA/ RA. Are all normal sized.

Mitral & Aortic Valves are almost normal.

Tricuspid & Pulmonary valve are normal.

I.V. Systolic function : Good.

I.V. Diastolic function : Good.

M.R./A.R./ & T.R./P.R. : Not Audible.

LV Ejection Fraction = 59%.

RV Function : Normal.

Dr. Seema Pandey (Radiologist)  
M.B.B.S., M.D.  
Reg. No. 38790  
Continued Pg. 2.

**GAURAV MULTI SPECIALITY HOSPITAL**  
**TIKHAMPUR= BALLIA**  
**ULTRA SOUND REPORT**

**PATIENT. AMRENDRA KUMAR**  
**REFERD BY DR SELF**

**DATE 30/03/2023**  
**AGE 32/M**

**LIVER**

Liver normal in shape and size & size is 14.4 Cm. Intrahepatic biliary radicals, portal veins and hepatic veins are not dilated. Echodensity is normal. No mass seen in liver.

**GALL BLADDER.**

Gall bladder normal in shape and size in 2.1mm. no stone or mass seen in gallbladder wall thickness normal.

**C.B.D. : Normal in caliber.**

**PANCREAS.**

Pancreas is normal in shape, size and echo pattern.

**SPLEEN.**

Spleen is normal in shape and size & size is 8.6 cm.

**KIDNEYS**

Rt kidney is normal in shape and size. Lt kidney is also normal in shape and size. Cortico-medullary differentiation is normal and no evidence of hydronephrosis or nephrolethiasis seen..

**URINARY BLADDER**

Normal in shape, size inner mucosal thickening. Echopattern is normal. No calculi / Mass / Lesion is seen.

**PROSTATE**

It is normal in size, measures Capsules are normal & Intact. It's volume is about 21 cc./Gms.

**IMPRESSION**

1. LIVER NORMAL.
2. GALL BLADDER NORMAL.
3. CBD NORMAL.
4. BOTH KIDNEYS NORMAL.
5. SPLEEN NORMAL.
6. URINARY BLADDER NORMAL
7. PROSTATE NORMAL.
8. GASEOUS BOWEL'S LOOPS.

Dr. Seema Pandey  
M.B.B.S., M.D.  
Reg. No.-38790  
SONOLOGIST

**GAURAV MULTI SPECIALITY HOSPITAL  
TIKHAMPUR= BALLIA**

PATIENT AMRENDRA KUMAR  
REFERD BY DR .....D.RAI...(M.D).....

DATE 30/03/2023  
AGE 32/M

**CHEST X-RAY PA**

**INVESTIGATION: X Ray Chest PA View**

- Both the lungs field are equally translucent
- Cardiac out line are normal
- The Costo-phernic angle are clear

Heart size and Cardiac out line are Normal

- No hilar Meditational mass is seen
- No obvious Skeletal abnormality Seen

**EMPRESSION : normal chest x ray .**

Dr. Seema Pandey (Radiologist)  
M.B.B.S., M.D.  
Reg. No.-38790

**SIGNATURE**

**GAURAV MULTI SPECIALITY HOSPITAL  
TIKHAMPUR= BALLIA**

PATIENT AMRENDRA KUMAR  
REFERD BY DR .....D.RAI...(M.D).....

DATE 30/03/2023  
AGE 32/M

**CHEST X-RAY PA**

**INVESTIGATION: X Ray Chest PA View**

- Both the lungs field are equally translucent
- Cardiac out line are normal
- The Costo-phernic angle are clear

Heart size and Cardiac out line are Normal

- No hilar Meditational mass is seen
- No obvious Skeletal abnormality Seen

**EMPRESSION : normal chest x ray .**

Dr. Seema Pandey (Radiologist)  
M.B.B.S., M.D.  
Reg. No.-38790

**SIGNATURE**



# GAURAV MULTI SPECIALITY HOSPITAL TIKHAMPUR= BALLIA

PATIENT. AMRENDRA KUMAR  
REFERED BY DR SELF

DATE 30/03/2023  
AGE 32/M

## ECHOCARDIOGRAPHY & COLOR DOPPLER REPORT

Page : 2.

Regional Wall Motion Abnormality ( RWMA ): Normal at Rest.

Sinus Rhythm with H.R.:- 84 BpM.

### DOPPLER STUDY :

MR 0/4 ; TR 0/4 ; / AR 0/4 ; PR 0/4. ( Normal Value 0-1 / 4 ).

PA Pressure : Normal.

### COLOR FLOW MAPPING :

No Regurgitation Audible at TR, MR, / AR, PR.

### FINAL IMPRESSION :

1. SINUS RHYTHM WITH NORMAL VENTRICLES ( LV & RV ).
2. NORMAL LV EJECTION FRACTION ; LVEF = 59 %.
3. MITRAL & AORTIC VALVES ARE NORMAL.
4. GOOD LV, S & D FUNTION & GOOD RV, S & D FUNTION.
5. NO RWMA ; NO CARDIOMAYOPATHY / CARDIOME GALY.
6. SINUS RYTHM IS IS APPARENT.

Dr. Seema Paliy (Radiologist)  
M.B.B.S., M.D.  
Reg. No. 38790  
CARDIOLOGIST



Ph: 05498-241635

# Gaurav Multispeciality Hospital

Near Chhaya Cinema, Tikhampur, Ballia (U.P.)

## Pathology & Radiology

Regn. No.: 10791

Patient Name: Shri AMRENDRAKUMAR

Address:

Referred By: Dr. D. RAI MD

Date: 30-03-2023

Age: 32 Years Sex: Male

### Liver Profile

Serum Total Bilirubin	00.89 mg%	(0.2-1mg%)
Serum Direct Bilirubin	00.51 mg%	(0-0.2mg%)
Serum Indirect Bilirubin	00.38 mg%	(0-0.8mg%)
SGPT	51.50 unit	(5-35unit)
SGOT	44.46 unit	(5-45unit)
Serum Alkaline Phosphatase	149.10 IU/L	

Normal Range:- Male: 50 - 126 (20-50 years), 57 - 111 (&gt;60 years)

Normal Range:- Female: 37 - 103 (20 - 50 years), 50 - 143 (&gt;60 years)

Higher Value Seen in growing children

### HAEMATOLOGICAL REPORT

Blood Group	"B"	
RH Type	Positive	
E.S.R. (Windrops)	18 mm/hr.	(Male: 0-9mm/hr.) (Female: 0-20mm/hr.)

### BIO CHEMISTRY

Fasting Plasma Glucose	82.23 mg%	(70-110mg%)
Post Prandial Glucose	116.99 mg%	(70-140mg%)
(Afte 2 Hrs. of taking meal)		
Serum Calcium	10.23 mg%	(9-11mg%)
Total Serum Protien	06.50 gm%	(6-8gm%)
Serum Albumin	04.10 gm%	(3-5gm%)

**DR. CHALNA**  
 Pathologist, M.D., D.C.P.  
 M.D. (Pathology), D.M. (Pathology)  
 Regd. No.-59481 (KMC)  
 Gaurav Multispeciality Hospital  
 Tikhampur, Ballia

Note.: We use sterilized disposable syringe & needle for every patient.  
 This report not valid for medico-legal purpose. It is to help clinician better patient management.  
 Discrepancies due to technical or typing error should be reported immediately within 24 hours for correction.



# Gaurav Multispeciality Hospital

Ph: 05498-241635

Near Chhaya Cinema, Tikhampur, Ballia (U.P.)

## Pathology & Radiology

Regn. No.: 10791

Patient Name: Shri AMRENDRAKUMAR

Address:

Referred By: Dr. D. RAI MD

Date: 30-03-2023

Age: 32 Years Sex: Male

### BIO CHEMISTRY

Seum Glubolin 02.40 gm% (1.5-3.5gm%)

Serum Uric Acid 04.21 mg% (3-7mg%)

### SEROLOGICAL REPORT

Serum T3 (Rai Method) 127.00 ng/dl (70-190ng/dl)

Serum T4 (Rai Method) 04.78 ug/dl (5-12.5ug/dl)

Serum TSH (Rai Method) 02.34 YU/ml (0.3-6.5YU/ml)

\*\*End of Report\*\*

**DR. CHALNA**  
M.B.B.S., D.C.P.  
Mishra Pathology Centre  
DNB (Path.)  
Regd. No.-59481 (KMC)  
Gaurav Multispeciality Hospital  
Tikhampur, Ballia

Note.: We use sterilized disposable syringe & needle for every patient.  
This report not valid for medico-legal purpose. It is to help clinician better patient management.  
Discrepancies due to technical or typing error should be reported immediately within 24 hours for correction.





# Gaurav Multispeciality Hospital

Near Chhaya Cinema, Tikhampur, Ballia (U.P.)

## Pathology & Radiology

Regn. No.: 10791

Date : 30-03-2023

Patient Name: Shri AMRENDRAKUMAR

Age: 32 Years Sex: Male

Address:

Referred By: Dr . D. RAI MD

### CBC

Haemoglobin 12.6 g/dl (Male: 13.5-18.0g/dl)

Total Leucocyte Count 4900 /cumm (4000-11000/cumm)

### Differential Leucocyte Count

Nutrophils	51 %	(50-70%)
Eosinophils	05 %	(1-4%)
Basophils	00 %	(0-1%)
Lymphocytes	43 %	(20-30%)
Monocytes	01 %	(1-3%)
Blast Cells	00 %	(0-1%)
Toxic/Bend Cells	00 %	(0-1%)

Platelets Count 00.68 Lacs/cumm (1.5-4Lacs/cumm)

Total RBCs Count 04.32 mill/cumm (Male: 3.8-5.3mill/cumm)

M.C.V. 86.7 fl (80-100fl)

M.C.H. 29.3 Pg (27-32Pg)

M.C.H.C. 33.7 g /dl (32-36g /dl)

### Kidney Profile

Serum Urea 36.10 mg/dl (13-45mg/dl)

Serum Creatinine 00.89 mg/dl (Male: 0.7-1.4mg/dl)

Serum Sodium 140.30 mmol/Liter (135-155mmol/Liter)

Serum Potassium 04.16 mmol/Liter (3.5-5.5mmol/Liter)

Serum Chloride 78.30 mmol/Liter (89-111mmol/Liter)

**Dr. CHALNA**  
**M.B.B.S., M.C.P.D. Rai**  
**DNB (Path.) PGD Pathologist**  
 Regd. No.-594  
 Gaurav Multispeciality Hospital  
 Tikhampur, Ballia

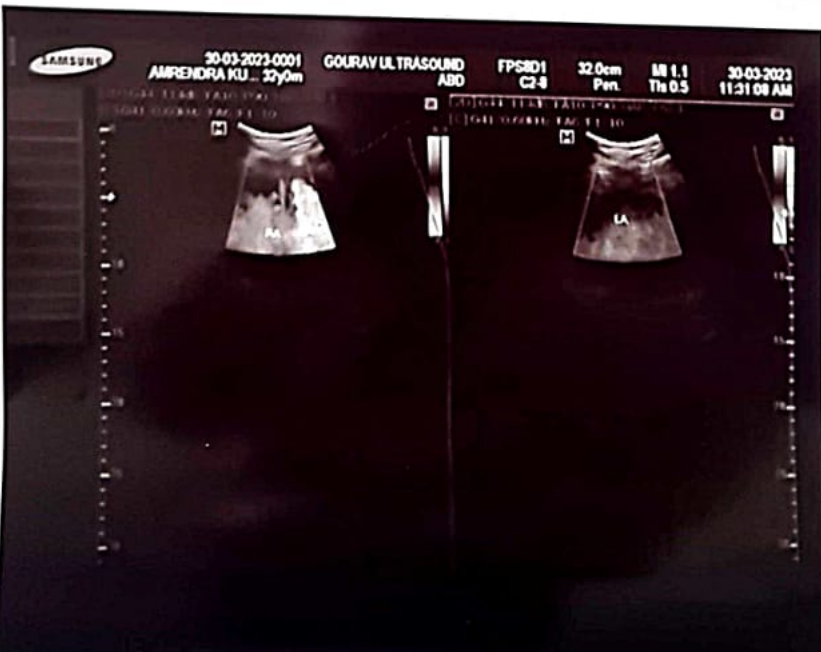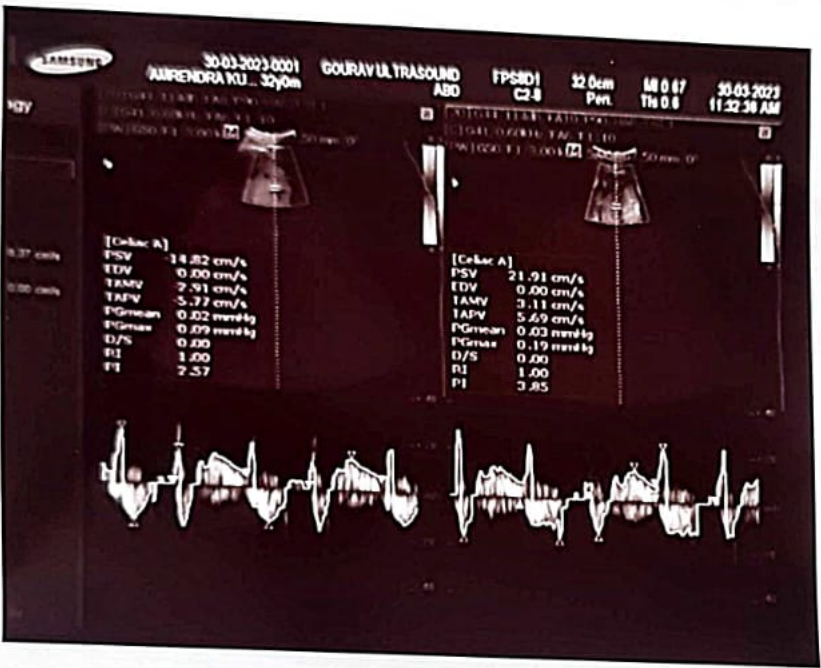
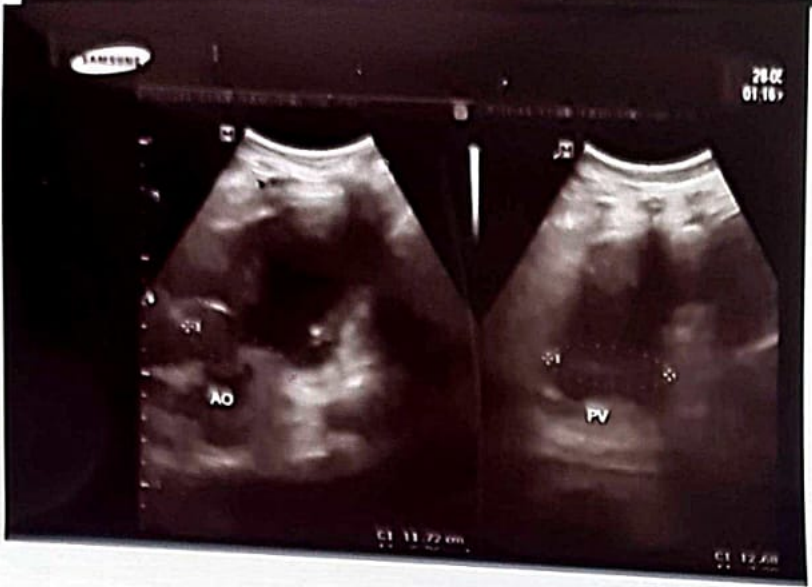**Note:** We use sterilized disposable syringe & needle for every patient.  
 This report not valid for medico-legal purpose. It is to help clinician better patient management.  
 Discrepancies due to technical or typing error should be reported immediately within 24 hours for correction.



Test Name	Result	Units	Normal Range
-----------	--------	-------	--------------

HBA1C	5.70		(4-6%)
-------	------	--	--------

Note.: We use sterilized disposable syringe & needle for every patient.  
This report not valid for medico-legal purpose. It is to help clinician better patient management.  
Discrepancies due to technical or typing error should be reported immediately within 24 hours for correction.





Ph: 05498-241635

# Gaurav Multispeciality Hospital

Near Chhaya Cinema, Tikhampur, Ballia (U.P.)

## Pathology & Radiology

Regn. No.: 10794

Patient Name: Shri AMRENDRA KUMAR

Address:

Referred By: Dr . D. RAI MD

Date : 30-03-2023

Age: 32 Years Sex: Male

### URINE ANALYSIS

#### Urine Routine Analysis

#### Macroscopic Finding

Quantity	Sufficient
Colour	YELLOW
Appearance	Transparent
Sediment	NIL
Reaction	7.0
Sp. Gravity	1.030

#### Microscopic Finding

Pus Cells	4-6 /HPF
RBCs	Not Seen /HPF
Epith. Cells	2-4 /HPF
Bacteria	Not Seen /HPF
Casts	Not Seen /HPF
Crystals	Not Seen /HPF
Spermatazoa	Not Seen /HPF
Parasites	Not Seen /HPF

#### Chemical Finding

Glucose	Trace
Protien	NIL

REMARK Fresh Urine Sample is Examined


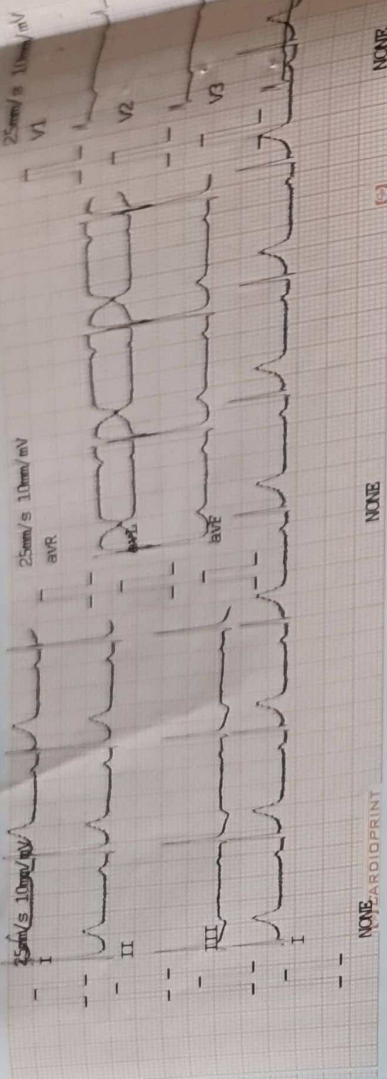
\*\*End of Report\*\*

### BIOCHEMISTRY TEST

**DR. SHALNA**  
Pathologist/Technician  
M.B.B.S, D.C.P.  
Mishra Pathological Centre  
DNB (Path.) PGDCH  
Regd. No.-59481 (KMC)  
Gaurav Multispeciality Hos.  
Tikhampur, Ballia

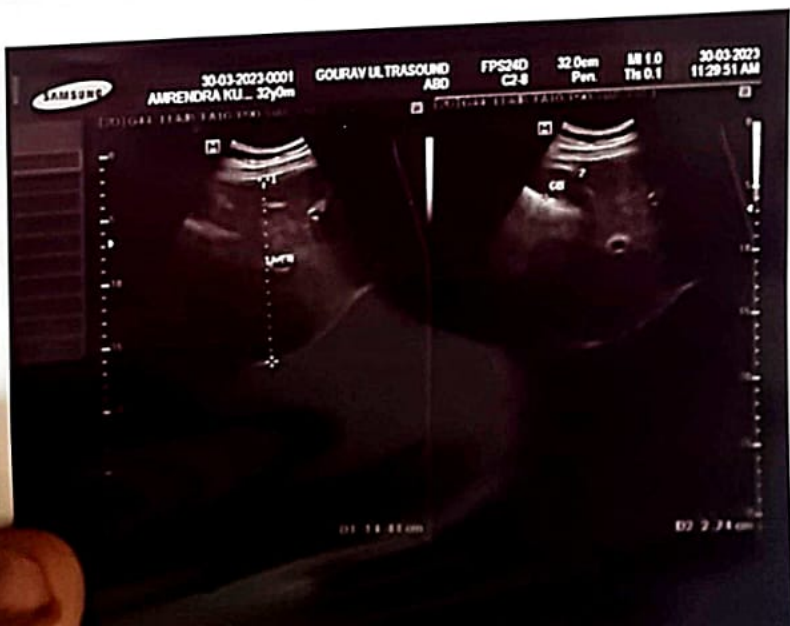
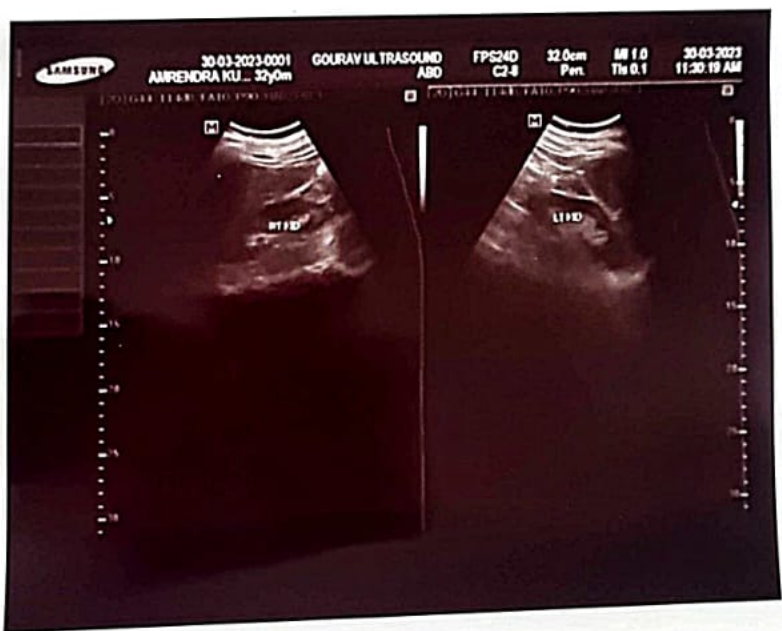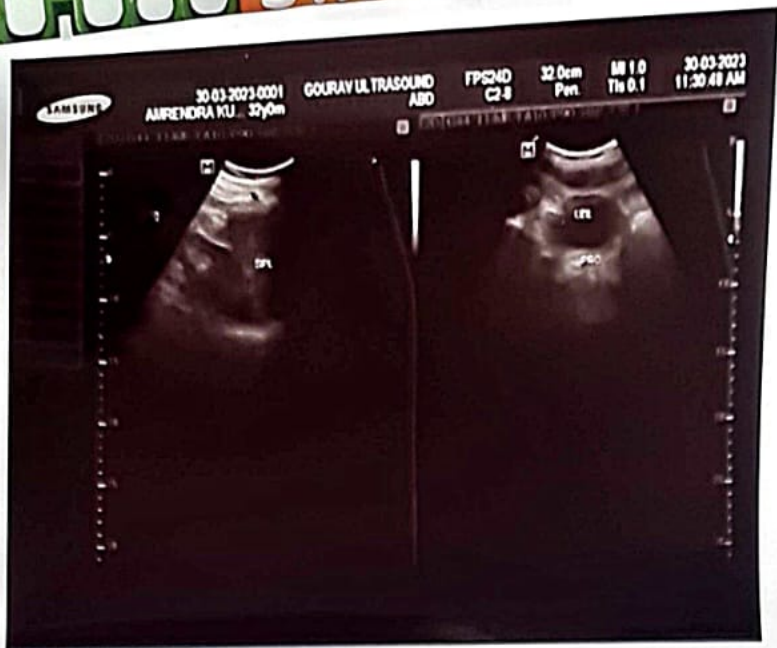Note.: We use sterilized disposable syringe & needle for every patient.  
This report not valid for medico-legal purpose. It is to help clinician better patient management.  
Discrepancies due to technical or typing error should be reported immediately within 24 hours for correction.





Dr. P. K. Das  
Cardiologist  
JAIHIN NURSING HOME  
TIKHAMPUK BALLIA  
800 N

USM - MCG





Ph: 05498-241635

# Gaurav Multispeciality Hospital

Near Chhaya Cinema, Tikhampur, Ballia (U.P.)

*Dr. D. Rai*

M.B.B.S (Hons.)  
M.D. (General Medicine).IMS BHU  
Cardiologist & General Physician  
Member  
Association of Physician of India

**Consultation Time**

7am to 10am  
11am to 7pm

MR. AMRENDRA KUMAR 32M  
S/O SATYENDRA PRASAD

30/03/2023

Wt - 73 Kg  
BP = 120/80  
Pulse = 68  
Temp = 97.6  
O2 = 98

CHEST PAIN - None  
USG - None  
2 DEW - None  
Blood PNAF - None

- Azc investigation None

30/3/2023

DR. D. RAI MD (MED)  
Physician  
Gaurav Nursing Home  
Ballia (U.P.)  
Reg. No: 29811 (MCI)

**विशेष सुविधायें:**

◆ 24 घण्टे इमरजेन्सी एवम् एम्बुलेन्स सेवा, कम्प्यूटर द्वारा फेफड़े की जाँच, वेन्टिलेटर तथा कार्डियक मानिटर से सुसज्जित आई.सी.सी.यू., वातानुकूलित प्राइवेट वार्ड, जनरल वार्ड, हृदय रोग, न्यूरोलॉजी, पेट, उदर, श्वास, छाती रोग, मधुमेह तथा रक्तचाप, सभी प्रकार की सर्जरी, प्लास्टिक सर्जरी, नार्मल डिलेवरी, सिजेरियम, इको टी.एम.टी., डिजिटल एक्सरे, अल्ट्रासाउण्ड, पैथोलॉजी तथा मेडिकल स्टोर, आयुष्मान कार्ड धारक एवं मृतपूर्य सैनिक (ECHS) के मरीजों का नि:शुल्क इलाज की सुविधा तथा हड्डी के मरीजों का सम्पूर्ण इलाज तथा आपरेशन की सुविधा उपलब्ध है।

**नोट-यह पर्ची केवल दस दिनों हेतु मान्य है।**



R

Ph: 05498-241638

# Multispeciality Hospital

a Cinema Tikri, Ballia (U.P.)

### Consultation Time

7am to 10am

11am to 7pm

ANDRA

RENDRA

pm. Non

- M

cho r a

d pna

cc. 12/12/2022

20/03/20

73 kg

120/80

10-68

10-98

30/3/2022

DR. D. RAI MD (MED)  
Physician  
Gaurav Nursing Home  
Ballia (U.P.)  
Reg No. 29811 (MCU)


**भारत सरकार**  
**Government of India**



**अमरेन्द्र कुमार**  
**Amrendra Kumar**  
**जन्म तिथि/DOB: 10/01/1991**  
**पुरुष/ MALE**

**2817 3257 0713**  
VID: 9189 6757 0814 2879

**मेरा आधार, मेरी पहचान**


*अमरेन्द्र कुमार*

**DR. D. RAI MD (MED)**  
 Physician  
 Gaurav Nursing Home  
 Ballia (U.P.)  
 Reg. No. 29811 (MCI)


**आधिकारण**  
**Unique Identification Authority of India**

**पता:**  
**S/O: सत्येन्द्र प्रसाद, मसाद पी.ओ जागीरदारी,**  
**जहानाबाद, जहानाबाद,**  
**बिहार - 804432**

**Address:**  
**S/O: Satyendra Prasad, Mashar P.O**  
**Jagirdar, Jehanabad, Jehanabad,**  
**Bihar - 804432**


QR Code with Photograph

**2817 3257 0713**  
VID: 9189 6757 0814 2879

10-7