


Print Date: 24/01/2022

भारतीय पहिचान प्राधिकरण
Unique Identification Authority of India
AADHAAR

पता: आत्मान: अजीत कुमार जैन, वर्धमान नगर,
जिल्हा, करौली, राजस्थान, 322230
Address: S/O: Ajeet Kumar Jain, vardhman
nagar, Hindaun, Karauli, Rajasthan, 322230

1947 help@uidai.gov.in www.uidai.gov.in

3841 6488 3760




Dr. NITIN AGARWAL
MBBS, MD
Regn. No. DMC-R-1436



ONEPLUS ULTRASOUND L...
47, Harsh Vihar, Pitam...
Delhi-110034
Ph. 011-42480101, 95...
E-mail: oneplusul@...@gmail.com


भारत सरकार Government of India

अमन जैन
Aman Jain
जन्म तिथि / DOB : 31/05/1994
पुरुष / Male


3841 6488 3760

मेरा आधार, मेरी पहचान


भारतीय पहिचान प्राधिकरण



Issue Date: 30/01/2016






Dr. NITIN AGARWAL
MBBS, MD
Regn. No. DMC-R-1436



ONEPLUS ULTRASOUND LAB
47, Harsh Vihar, Pitam Pura,
Delhi-110034
Ph. 011-42480101, 9599913051
E-mail: oneplusul@gmail.com

ONEPLUS ULTRASOUND LAB

47, HARSH VIHAR, PITAMPURA, DELHI- 110034

Mr. AMAN JAIN

Age : 28/M
 Ref. by : MEDIWHEEL
 Indication1 :
 Indication2 :
 Indication3 :
 COMMENTS : Normal ECG.

ID : 2037
 H/W : 170/82
 Recorded : 8-11-2022 11:57
 Medication1 :
 Medication2 :
 Medication3 :

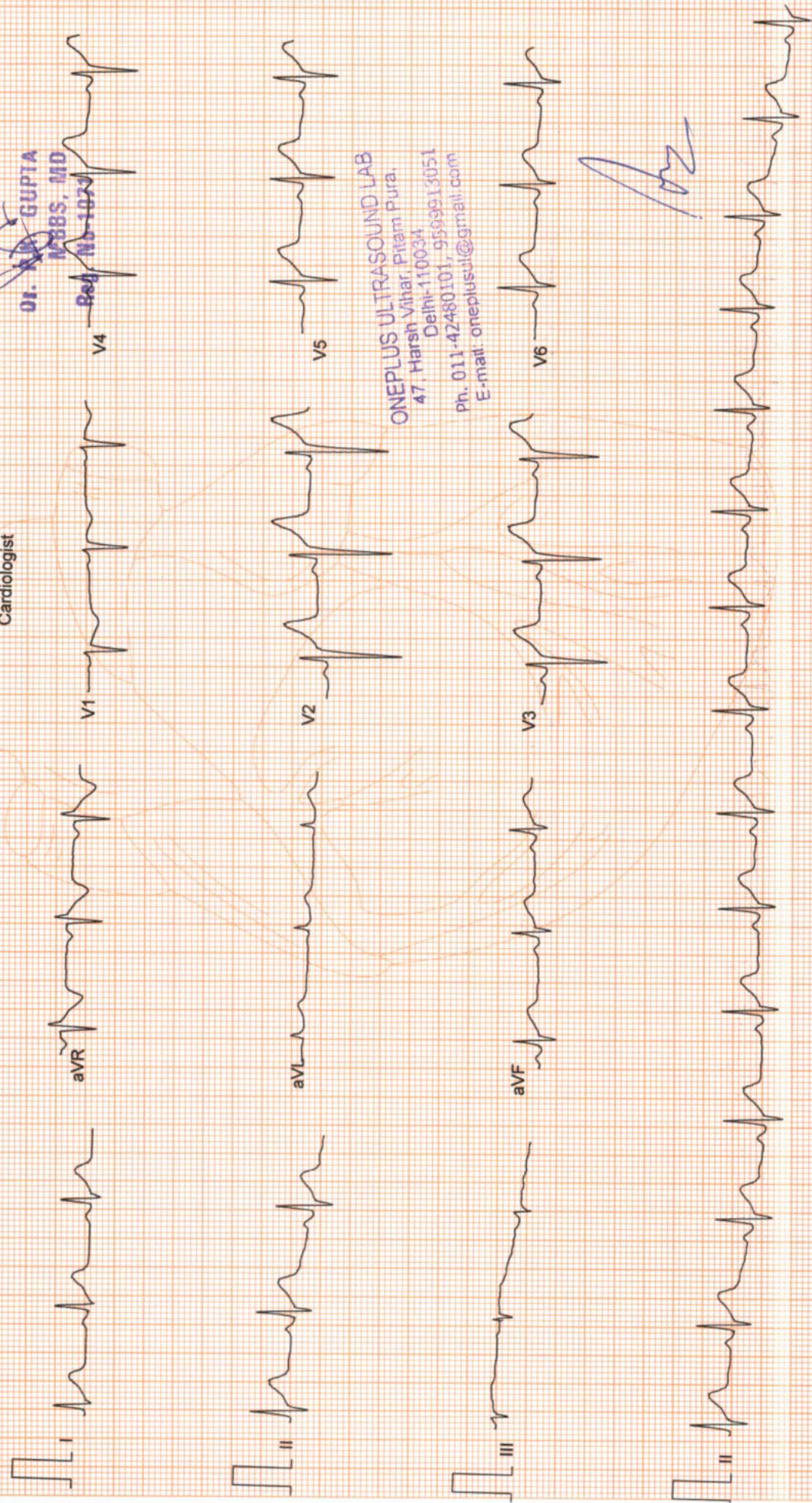
BPM : 88
 BP : 136/86
 P Axis : 53 deg
 QRS Axis : 34 deg
 T Axis : 46 deg

Raw E.C.G.(Seq)

Unconfirmed Report Reviewed By:

Cardiologist

Dr. A.K. GUPTA
Dr. A.K. GUPTA
MBBS, MD
Reg No-1073



ONEPLUS ULTRASOUND LAB
 47, Harsh Vihar, Pitam Pura,
 Delhi-110034
 Ph. 011-42480101, 9599913051
 E-mail: oneplusul@gmail.com

AK

Filtered

25mm/sec 10mm/mV

CardiCom INDIA

ONEPLUS ULTRASOUND LAB

47, HARSH VIHAR PITAMPURA DELHI 110034

Mr. AMAN JAIN
 Age/Sex : 28/M
 Ref. by : MEDIWHEEL
 Indication1 :
 Indication2 :
 Indication3 :

ID : 999
 H/Wt : 170/82
 Recorded : 8-11-2022 12:02

TREADMILL TEST SUMMARY REPORT
 Protocol: BRUCE
 History:
 Medication1 :
 Medication2 :
 Medication3 :

PHASE	PHASE TIME	STAGE TIME	SPEED (Km./Hr.)	GRADE (%)	H.R. (BPM)	B.P. (mmHg)	RPP X100	II	ST LEVEL V2	V5	METS
STANDING SUPINE					97	136/86	131	1.9	2.8	2.2	
					86	136/86	116	1.8	2.8	2.2	
STAGE 1	2:59	2:59	2.70	10.00	129	136/86	175	2.1	3.2	2.5	4.80
STAGE 2	5:59	2:59	4.00	12.00	144	150/88	216	1.9	2.7	2.7	7.10
STAGE 3	8:59	2:59	5.40	14.00	164	162/90	265	1.6	2.5	2.8	10.00
STAGE 4	9:14	0:14	6.70	16.00	170	170/92	289	2.2	2.1	3.5	10.31
PEAK EXER	9:21	0:21			174	170/92	295	2.3	1.6	3.9	10.47
RECOVERY	2:59	2:59	0.00	0.00	120	136/86	163	1.2	1.6	1.2	

RESULTS


Exercise Duration : 9:21 Minutes
 Max Heart Rate : 174 bpm 90 % of target heart rate 192 bpm
 Max Blood Pressure : 170/92 mmHg
 Max Work Load : 10.47 METS
 Reason of Termination :

IMPRESSIONS

Negative for ischemic change

ONEPLUS ULTRASOUND LAB
 47, Harsh Vihar, Pitam Pura,
 Delhi-110034
 Ph: 011-42480101, 9559913051
 E-mail: oneplus.ii@gmail.com

Dr. P.K. GUPTA
 M.B.B.S. MD
 Reg. No. 1071
 Cardiologist



ONEPLUS ULTRASOUND LAB

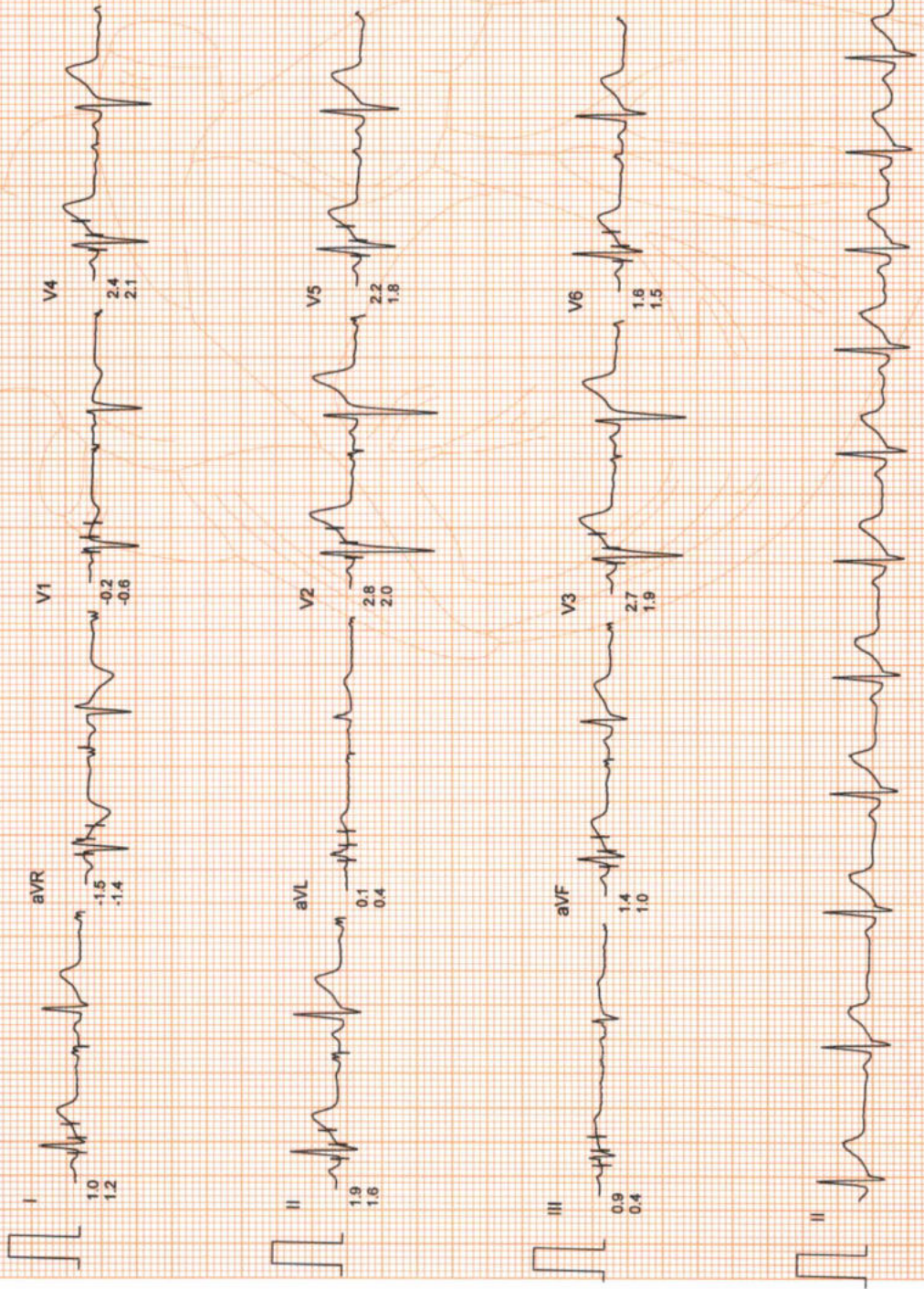
STANDING
PRETEST

Mr. AMAN JAIN
I.D. : 999
AGE/SEX : 28/M
RECORDED : 8-11-2022 12:02

RATE : 97 BPM
B.P. : 136/86 mmHg

ST @ 10mm/mV
80ms PostJ

LINKED MEDIAN



50mm/sec 20mm/mV

ONEPLUS ULTRASOUND LAB
47, Harsh Vihar, Pitampura
Delhi-110034
Ph: 011-42480101, 9599913051
E-mail: oneplusul@gmail.com

ONEPLUS ULTRASOUND LAB

Mr. AMAN JAIN
I.D. : 999
AGE/SEX : 28/M

RECORDED : 8-11-2022 12:02

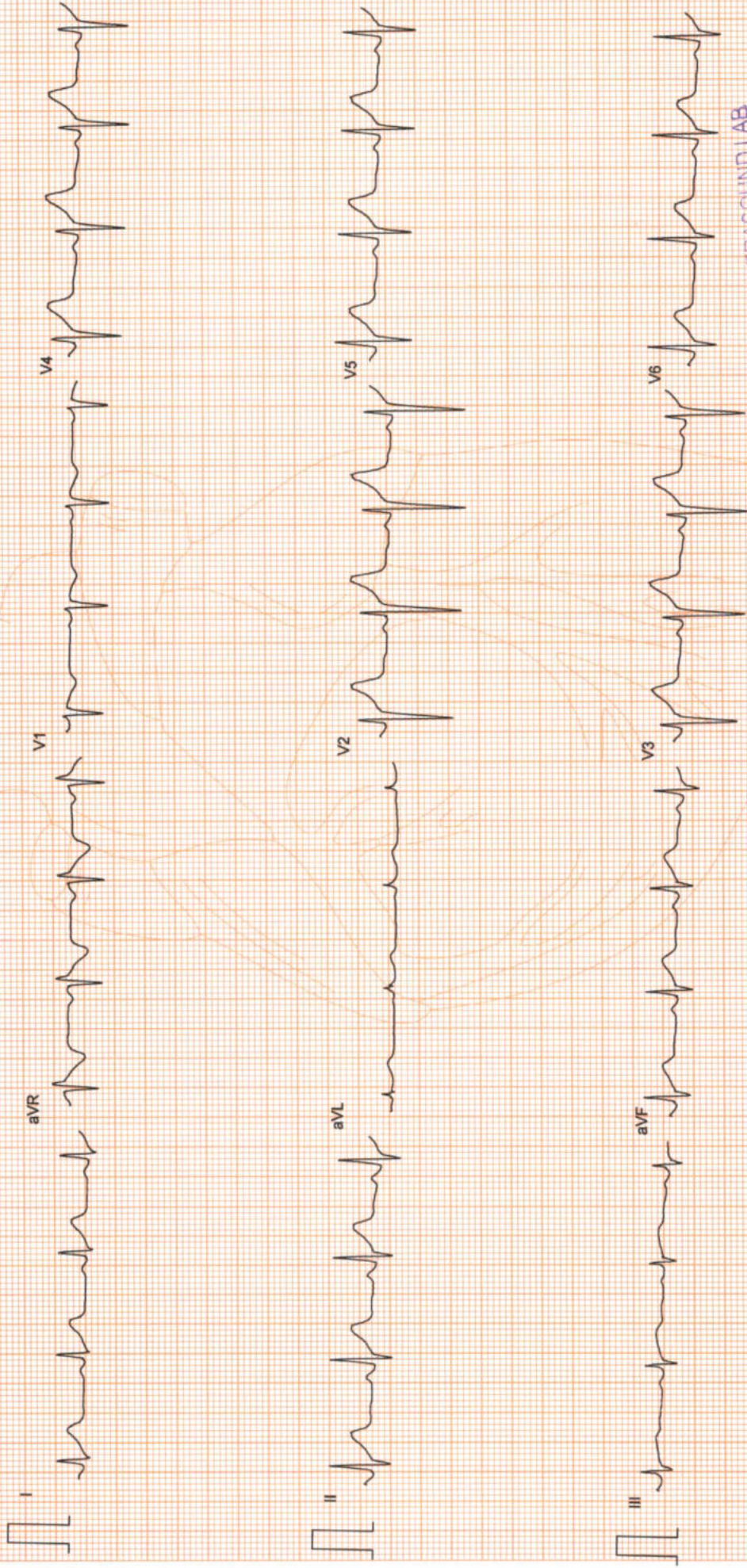
RATE : 86 BPM

B.P. : 136/86 mmHg

ST @ 10mm/mV
80ms PostJ

SUPINE
PRETEST

RAW E.C.G.



ONEPLUS ULTRASOUND LAB
47 Harsh Vihar Pitam Pura,
Delhi-110034
Ph. 011-42480101, 9599913053
E-mail: oneplusul@gmail.com

ONEPLUS ULTRASOUND LAB

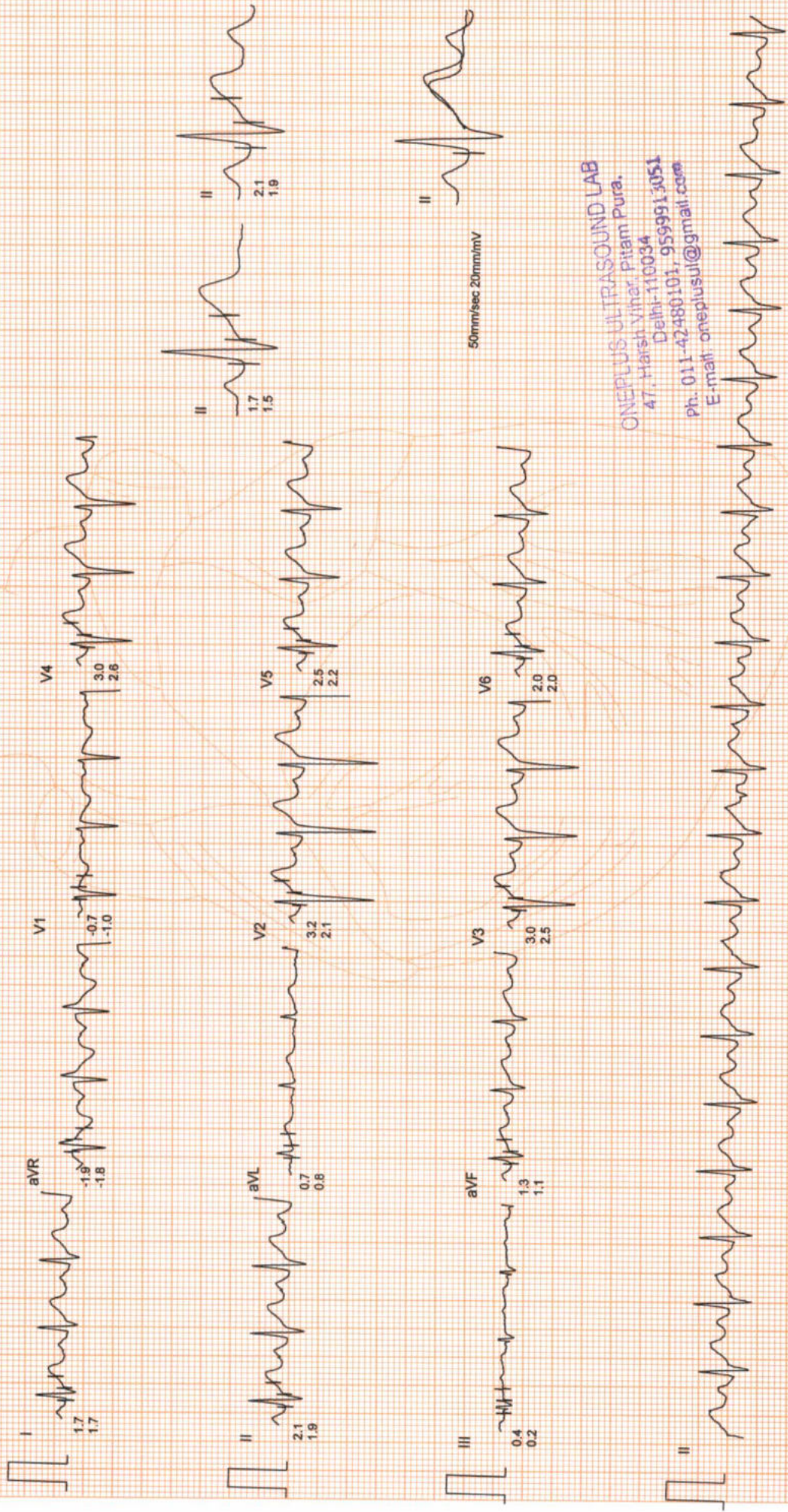
Mr. AMAN JAIN
I.D. : 999
AGE/SEX : 28/M

RECORDED : 8-11-2022 12:02
RATE : 129 BPM
B.P. : 136/86 mmHg

BRUCE
EXERCISE 1
PHASE TIME : 2:59
STAGE TIME : 2:59

ST @ 10mm/mV
80ms PostJ
SPEED : 2.7 Km./Hr.
GRADE : 10.0 %

LINKED MEDIAN



ONEPLUS ULTRASOUND LAB
47, Harsh Vihar, Pitam Pura,
Delhi-110034
ph: 011-42480101, 9599913051
E-mail: oneplusul@gmail.com

ONEPLUS ULTRASOUND LAB

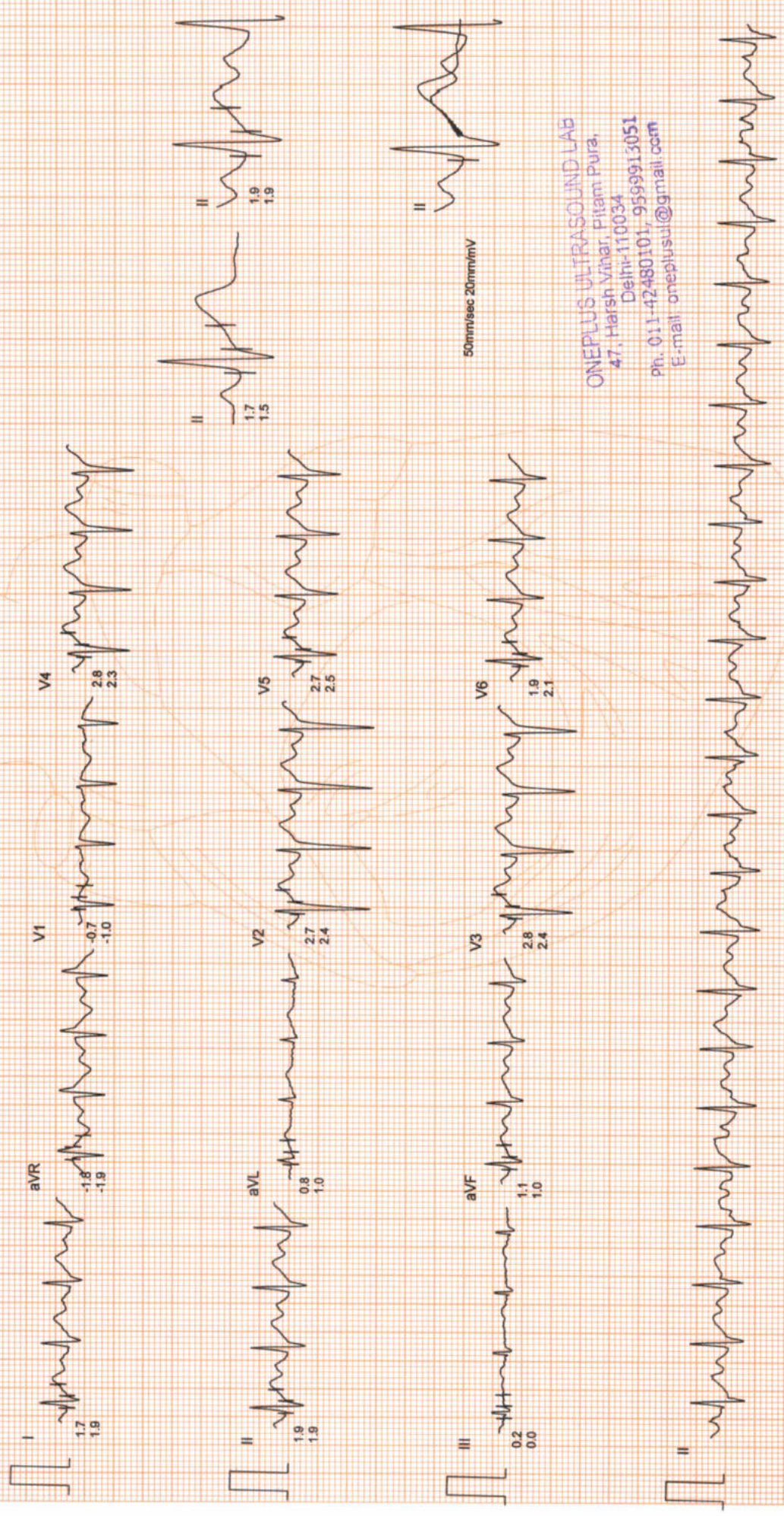
Mr. AMAN JAIN
I.D. : 999
AGE/SEX : 28/M

RECORDED : 8-11-2022 12:02
RATE : 144 BPM
B.P. : 150/88 mmHg

BRUCE
EXERCISE 2
PHASE TIME : 5:59
STAGE TIME : 2:59

ST @ 10mm/mV
80ms PostJ
SPEED : 4.0 Km./Hr.
GRADE : 12.0 %

LINKED MEDIAN



ONEPLUS ULTRASOUND LAB
47, Harsh Vihar, Pitam Pura,
Delhi-110034
Ph. 011-42480101, 9599913051
E-mail: oneplusul@gmail.com

ONEPLUS ULTRASOUND LAB

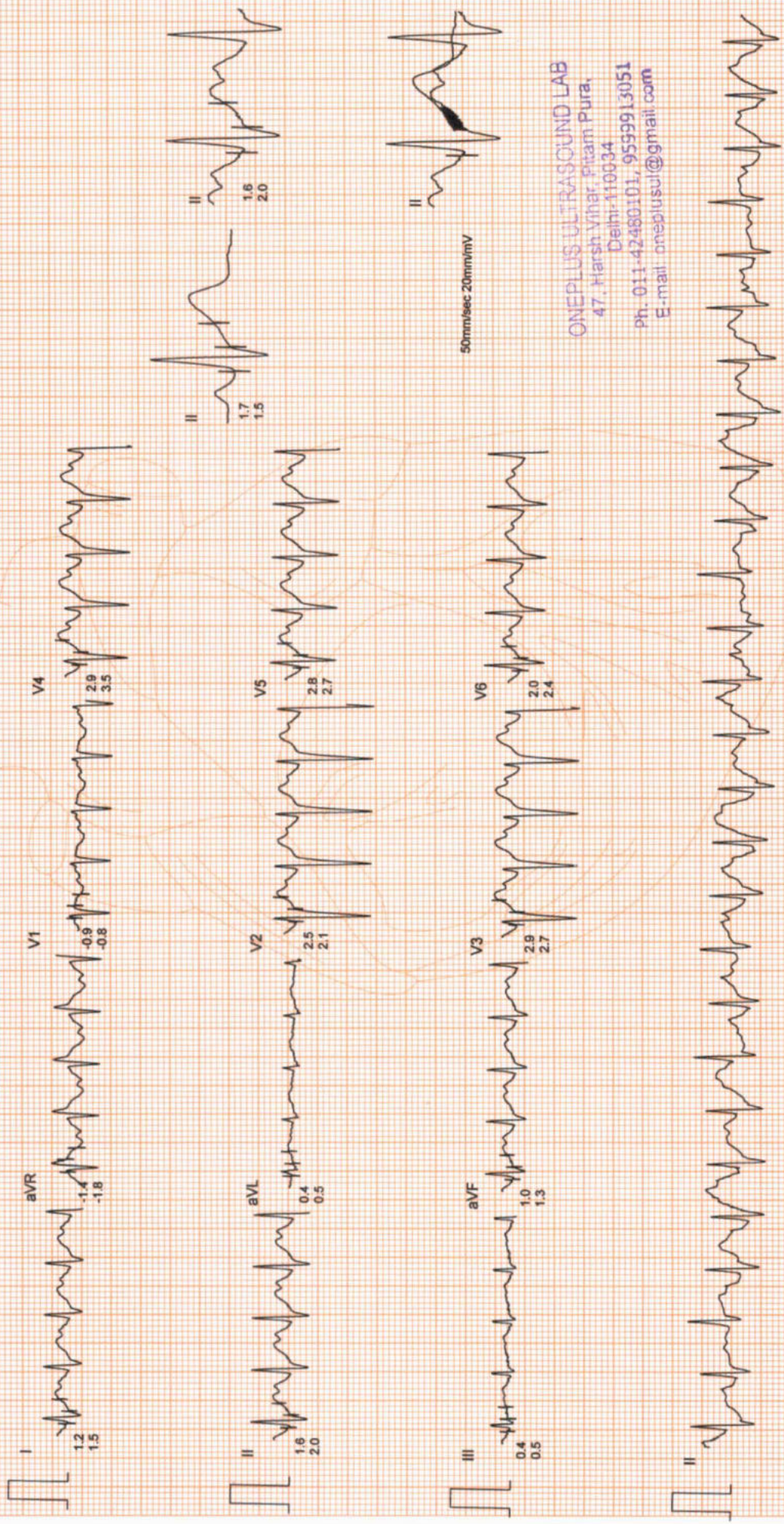
Mr. AMAN JAIN
I.D. : 999
AGE/SEX : 28/M

RECORDED : 8-11-2022 12:02
RATE : 164 BPM
B.P. : 162/90 mmHg

BRUCE
EXERCISE 3
PHASE TIME : 8:59
STAGE TIME : 2:59

ST @ 10mm/mV
80ms PostJ
SPEED : 5.4 Km./Hr.
GRADE : 14.0 %

LINKED MEDIAN



ONEPLUS ULTRASOUND LAB
47, Harsh Vihar, Pitam Pura,
Delhi-110034
Ph. 011-42480101, 9599913051
E-mail: oneplusul@gmail.com

ONEPLUS ULTRASOUND LAB

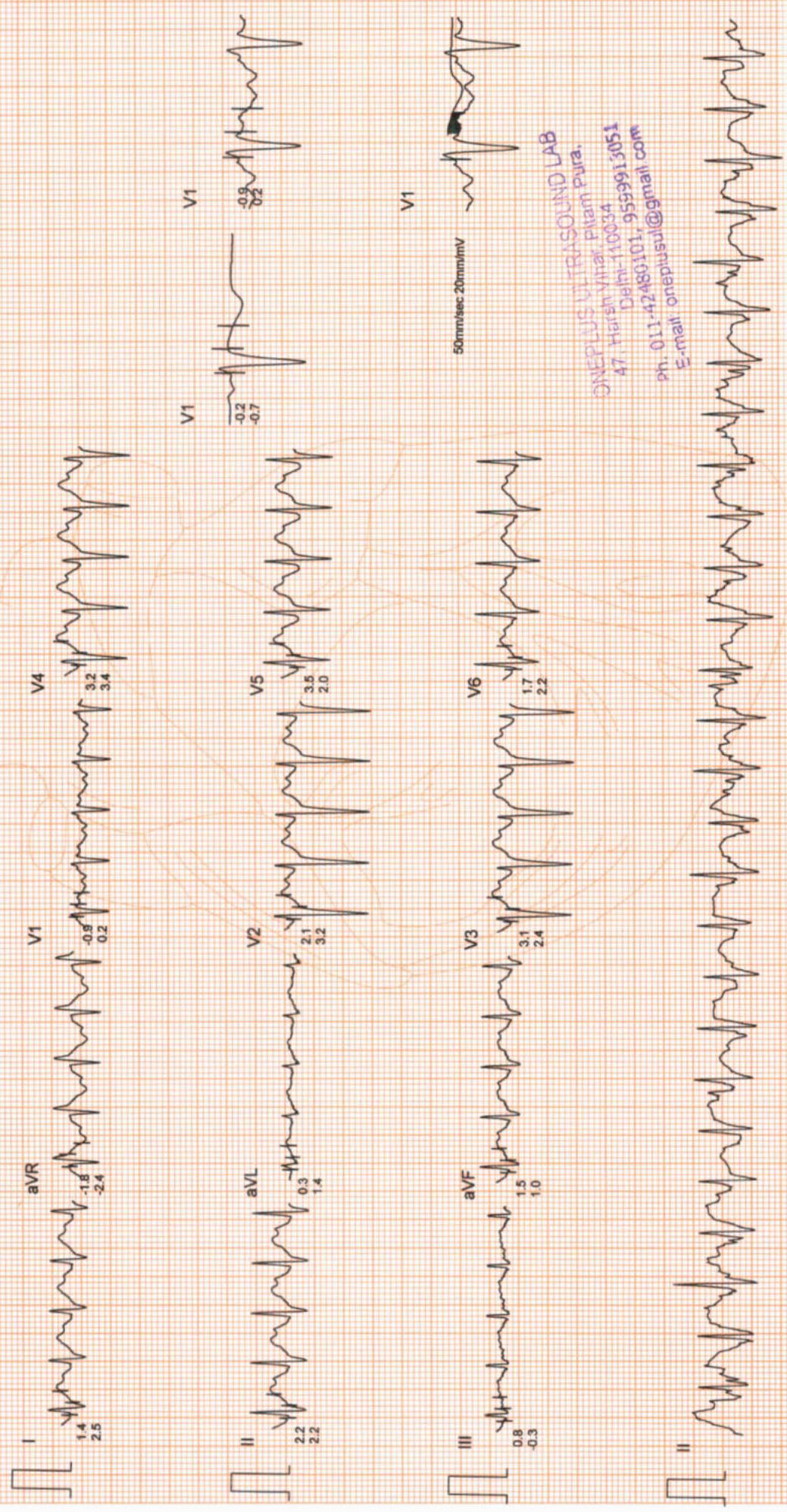
Mr. AMAN JAIN
I.D. : 999
AGE/SEX : 28/M

RECORDED : 8-11-2022 12:02
RATE : 170 BPM
B.P. : 170/92 mmHg

BRUCE
EXERCISE 4
PHASE TIME : 9:14
STAGE TIME : 0:14

ST @ 10mm/mV
80ms PostJ
SPEED : 6.7 Km./Hr.
GRADE : 16.0 %

LINKED MEDIAN



ONEPLUS ULTRASOUND LAB
47 Haren Vihar Pitam Pura,
Delhi-110034
ph. 011-42480101, 9599913051
E-mail: oneplusul@gmail.com

ONEPLUS ULTRASOUND LAB

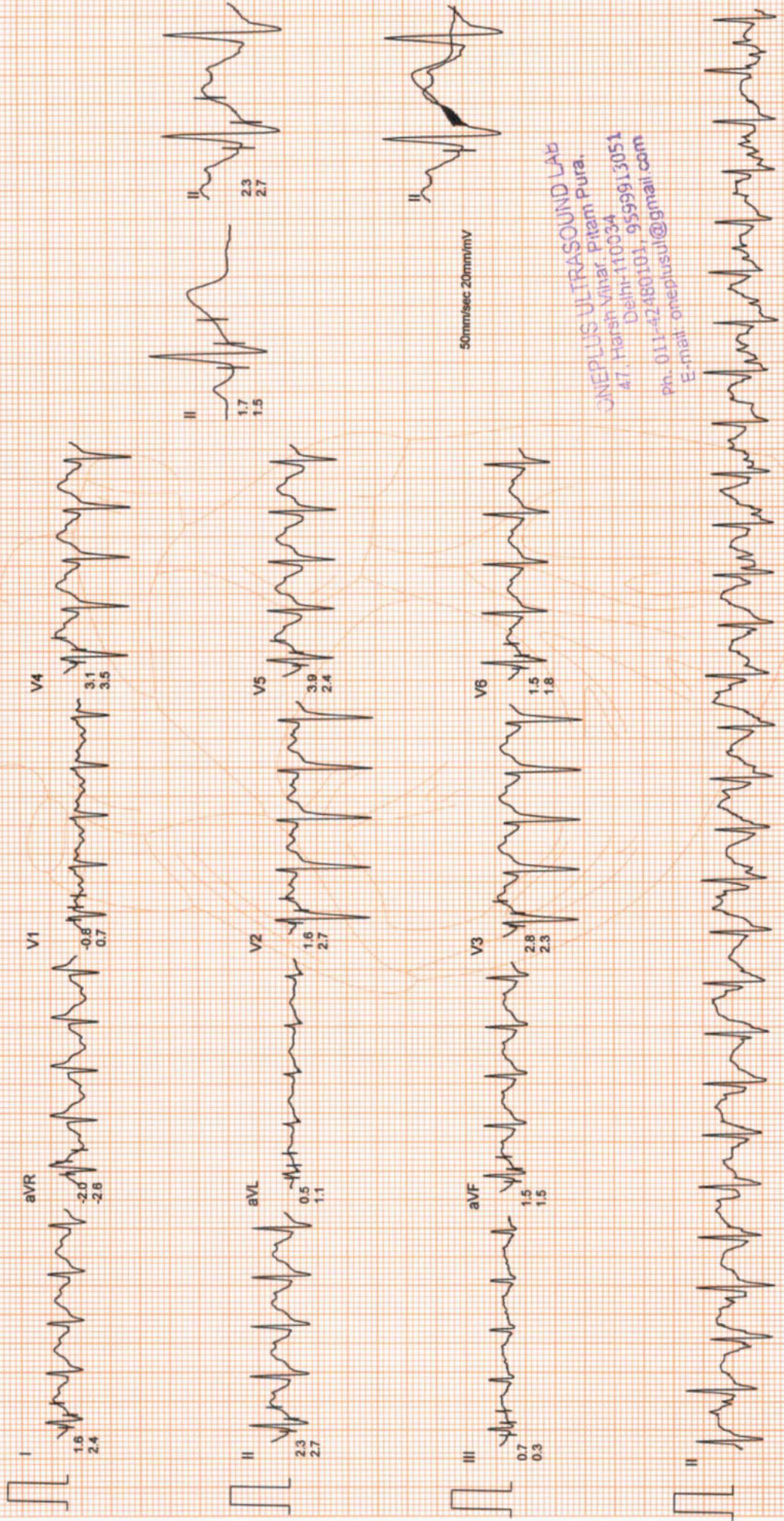
Mr. AMAN JAIN
I.D. : 999
AGE/SEX : 28/M

RECORDED : 8-11-2022 12:02
RATE : 174 BPM
B.P. : 170/92 mmHg

BRUCE
PEAK EXER
PHASE TIME : 9:21
STAGE TIME : 0:21

ST @ 10mm/mV
80ms PostJ
SPEED : 6.7 Km./Hr.
GRADE : 16.0 %

LINKED MEDIAN



ONEPLUS ULTRASOUND LAB
47, Harsh Vihar Pitam Pura,
Delhi-110034
Ph. 011-42489101, 9399913051
E-mail: oneplusul@ gmail.com

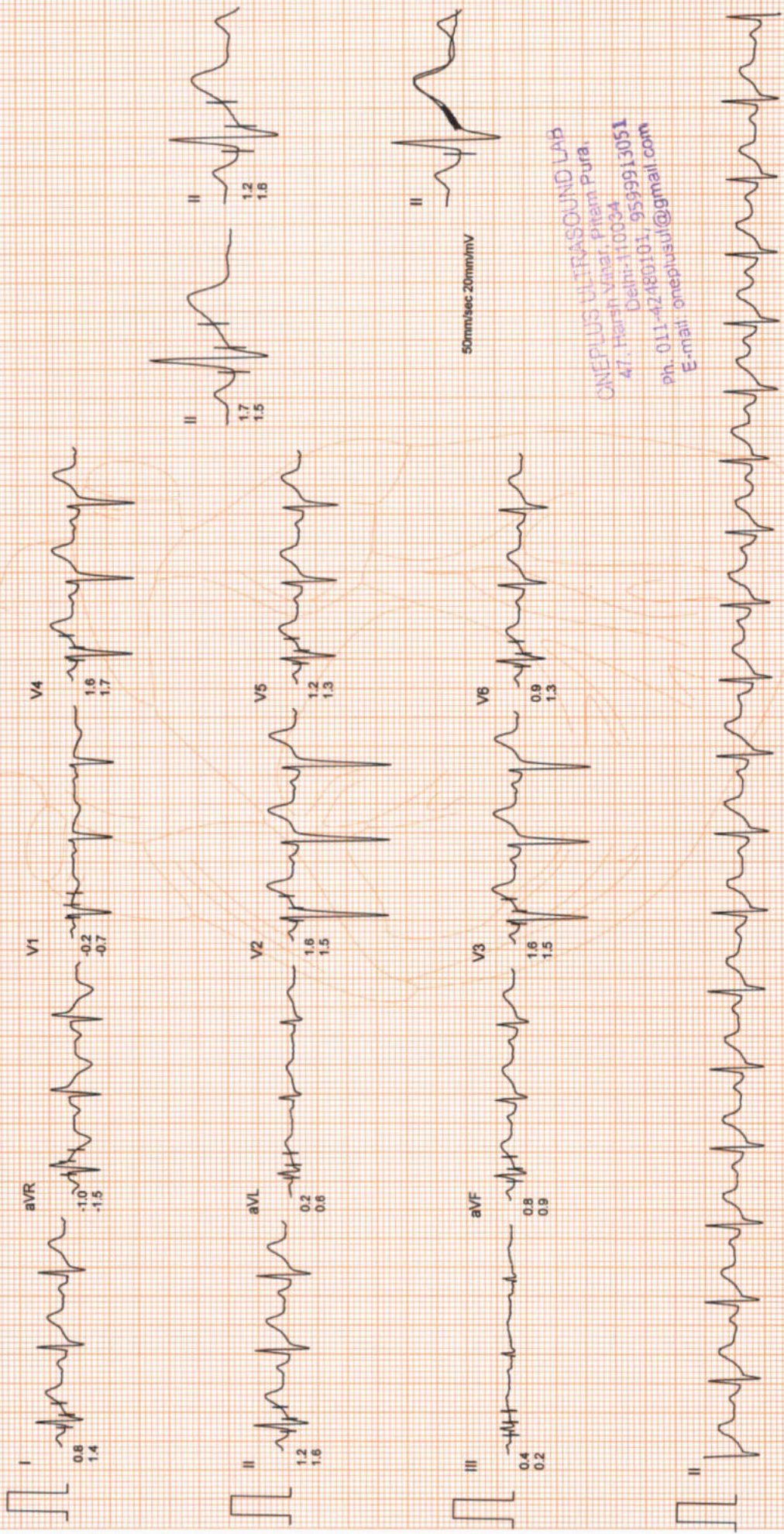
ONEPLUS ULTRASOUND LAB

Mr. AMAN JAIN
I.D. : 999
AGE/SEX : 28/M

RECORDED : 8-11-2022 12:02
RATE : 120 BPM
B.P. : 136/86 mmHg

ST @ 10mm/mV
80ms PostJ
SPEED : 0.0 Km./Hr.
GRADE : 0.0 %

LINKED MEDIAN



ONEPLUS ULTRASOUND LAB
47, Harsh Vimal, Pitam Pura
Delhi-110034
Ph. 011-42480101, 9599913051
E-mail: oneplusul@gmail.com

ONEPLUS ULTRASOUND LAB

I.D. : 999

Mr. AMAN JAIN

AGE/SEX : 28/M

RECORDED : 8-11-2022 12:02

AVG E.C.G.



ONEPLUS ULTRASOUND LAB
 47, Harsh Vihar Pitam Pura,
 Delhi-110034
 Ph. 011-42486101, 9599913051
 E-mail: oneplusul@gmail.com

ONEPLUS ULTRASOUND LAB

AGE/SEX : 28/M

I.D. : 999

RECORDED : 8-11-2022 12:02

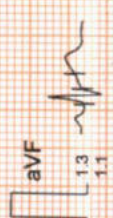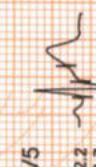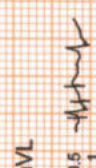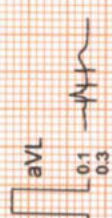



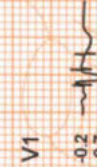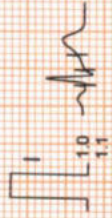
Mr. AMAN JAIN

COMPARISON REPORT

SUPINE
0.0Kmph
0.0%
86 bpm
B.P. 136/86
80ms PostJ

PEAK EXERCISE
9:21
0:21
6.7Kmph
16.0%
174 bpm
B.P. 170/92
80ms PostJ

PEAK EXERCISE
9:21
0:21
6.7Kmph
16.0%
174 bpm
B.P. 170/92
80ms PostJ



ONEPLUS ULTRASOUND LAB
47, Harsh Vihar, Pitam Pura,
Delhi-110034
Ph. 011-42483101, 9599913051
E-mail: oneplusul@gmail.com



OnePLUS
Ultrasound Lab

— QUALITY FIRST... ALWAYS! —

Dr. Nitin Agarwal

Pathologist & Director
Ex. Sr. Res. MAMC
& Lok Nayak Hospital
Ex. Chief of Lab Dr. Lal Path Labs.

Dr. Pooja (Garg) Agarwal

Radiologist & Director
MAMC & Lok Nayak Hospital

Name	: Mr. AMAN JAIN	Age/Sex	: 28 YRS/Male
Ref. By	: Dr. MEDIWHEEL	Lab No	: 012211080024
Date	: 08-Nov-2022	Patient ID	: LSHHI104399

ULTRASOUND EXAMINATION----WHOLE ABDOMEN

Liver is normal in size (13.9 cm) and outline with altered echopattern. **Diffuse increase in echogenicity of liver parenchyma is noted, suggestive of fatty infiltration (grade II).** No abscess or mass lesion seen. Hepatic veins, portal vein, IVC and aorta are normal. Intrahepatic biliary radicles are not dilated. CBD is normal in caliber.

Gall bladder is well distended with anechoic lumen. Wall thickness is normal.

Both kidneys are normal in size, shape, position, outline and echopattern. Corticomedullary differentiation is maintained. No pelvicalyceal dilation or mass lesion is seen.

Spleen is normal in size and echotexture. No mass lesion seen.

Pancreas is normal in size, outline and echotexture.

Urinary bladder is normal in shape and position. No evidence of intravesical stone or mass seen.

Prostate is normal in size, shape and echopattern.

Prostate measures 3.1 x 2.8 x 2.7 cm. **Weight of prostate is 12.7 grams.**

No abnormal bowel wall thickening seen in right iliac fossa.

No free fluid seen anywhere in abdomen.

IMPRESSION: Fatty infiltration of liver (grade II) with no hepatomegaly.

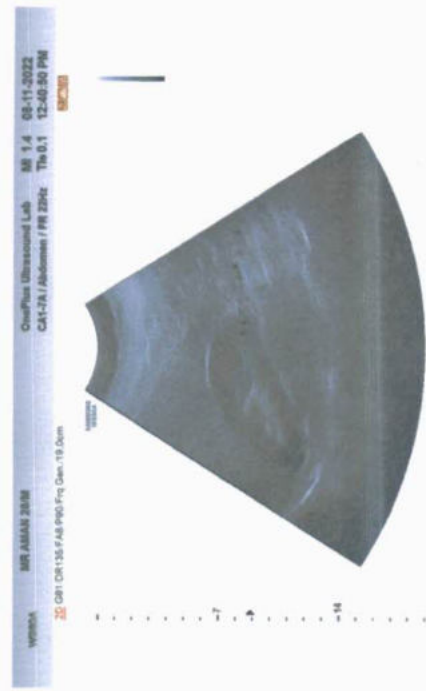
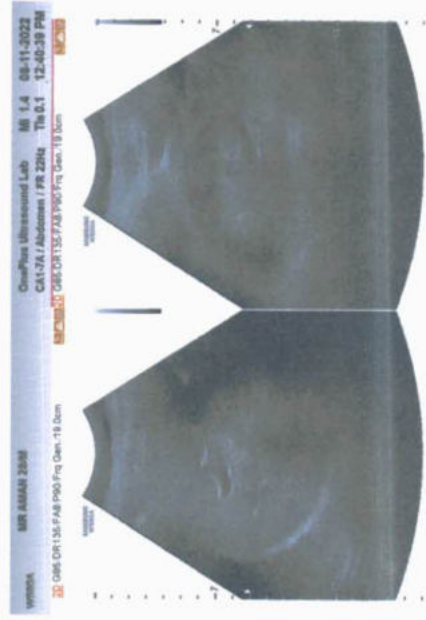
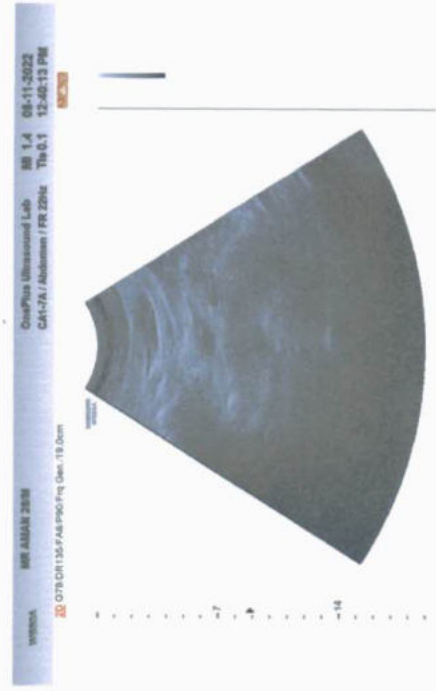
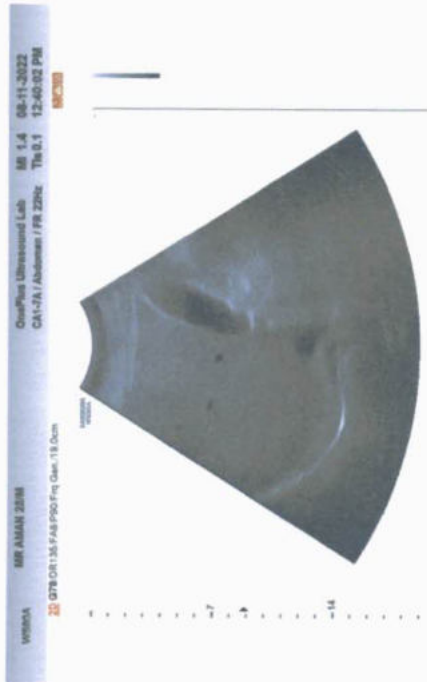
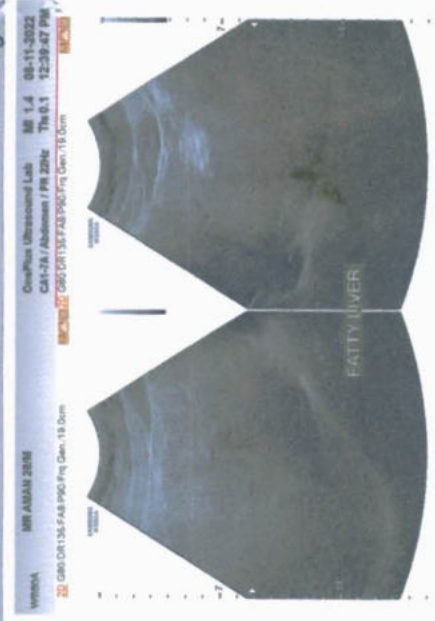
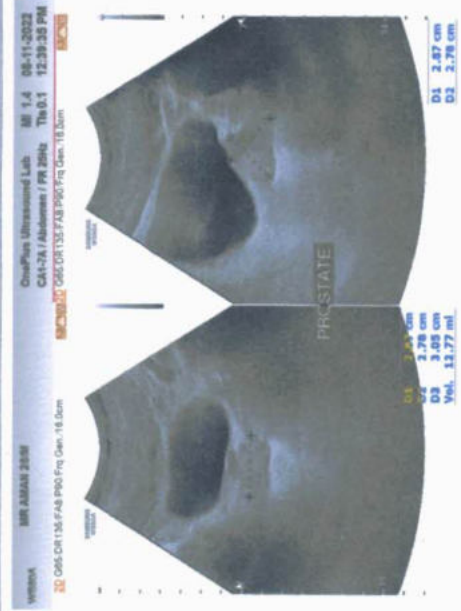
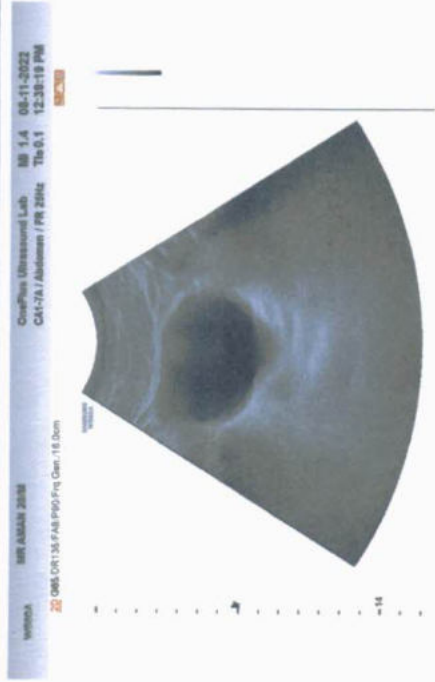
DR. POOJA GARG
RADIOLOGIST

Dr. POOJA GARG
M.B.B.S., D.M.R.D.
Reg No. DMC/R/03398
Radiologist

Type By : darshita

47, Harsh Vihar, Pitampura, New Delhi-110034 | Ph.: 011-42480101, 9599913051
E-mail: oneplusul@gmail.com | Web.: www.oneplusul.in

Clinical correlation is essential for final diagnosis. • If test results are unsatisfactory please contact personally or on phone. • This report is for perusal of doctors only.
• All disputes Subject to Delhi Jurisdiction only. • Not for medicolegal purposes. • All congenital anomalies in a foetus may not be diagnosed in routine obstetric ultrasound.





OnePLUS Ultrasound Lab

— QUALITY FIRST... ALWAYS! —

Dr. Nitin Agarwal
Pathologist & Director
Ex. Sr. Res. MAMC
& Lok Nayak Hospital
Ex. Chief of Lab Dr. Lal Path Labs.

Dr. Pooja (Garg) Agarwal
Radiologist & Director
MAMC & Lok Nayak Hospital



NAME	:Mr. AMAN JAIN	Barcode No	:10131157
AGE/GENDER	:28 YRS/Male	SPECIMEN DATE	:08/Nov/2022 11:03AM
PATIENT ID	:104399	SPECIMEN RECEIVED	:08/Nov/2022 01:27PM
REFERRED BY	:Dr. MEDIWHEEL	REPORT DATE	:08/Nov/2022 03:23PM
CENTRE NAME	:ONEPLUS ULTRASOUND LAB	LAB NO.	:012211080024

Test Name	Result	Unit	Ref. Range
-----------	--------	------	------------

HAEMATOLOGY

Health checkup 2 Male

Glycosylated Hemoglobin (HbA1c)	5.0	%	Non Diabetic adults <5.7 Prediabetic (at risk) 5.7-6.4 Diabetes >6.4
--	-----	---	--

Estimated average blood glucose (eag)	97
--	----

Reference range (mg/dl):

90 - 120:Excellent control, 121 - 150:Good Control, 151 - 180:Average Control, 181 - 210:Action Suggested

>211:Panic value

BLOOD GROUP (ABO)	A
--------------------------	---

Rh typing	POSITIVE
------------------	----------

NOTE :

- * Apart from major A,B,H antigens which are used for ABO grouping and Rh typing, many minor blood group antigens exist. Agglutination may also vary according to titre of antigen and antibody.
- * So before transfusion, reconfirmation of blood group as well as cross-matching is needed.
- * Presence of maternal antibodies in newborns, may interfere with blood grouping.
- * Auto agglutination (due to cold antibody, falciparum malaria, sepsis, internal malignancy etc.) may also cause erroneous result.

CBC

Haemoglobin	13.2	g/dl	13.0-17.0
Total Leucocyte Count	6600	/cumm	4000-10000
Differential leucocyte count			
Neutrophils	69.3	%	40-80
Lymphocyte	26.40	%	20-40
Monocytes	2.30	%	2-10
Eosinophils	01	%	1-6
Basophils	01	%	0-2
RBC Count	4.60	million/cumm	4.5 - 5.5

Checked By.

Dr. NITIN AGARWAL
M B B S , MD (Pathology)
DMC/R/01436

DR. NITIN AGARWAL
MBBS,MD(PATHOLOGIST)

47, Harsh Vihar, Pitampura, New Delhi-110034 | Ph.: 011-42480101, 9599913051

E-mail: oneplusul@gmail.com | Web.: www.oneplusul.in

Page 1 of 6



OnePLUS

Ultrasound Lab

— QUALITY FIRST... ALWAYS! —

Dr. Nitin Agarwal
Pathologist & Director
Ex. Sr. Res. MAMC
& Lok Nayak Hospital
Ex. Chief of Lab Dr. Lal Path Labs.

Dr. Pooja (Garg) Agarwal
Radiologist & Director
MAMC & Lok Nayak Hospital



NAME	:Mr. AMAN JAIN	Barcode No	:10131157
AGE/GENDER	:28 YRS/Male	SPECIMEN DATE	:08/Nov/2022 11:03AM
PATIENT ID	:104399	SPECIMEN RECEIVED	:08/Nov/2022 01:27PM
REFERRED BY	:Dr. MEDIWHEEL	REPORT DATE	:08/Nov/2022 03:23PM
CENTRE NAME	:ONEPLUS ULTRASOUND LAB	LAB NO.	:012211080024

Test Name	Result	Unit	Ref. Range
PCV(Hematocrit)	42.5	%	40-50
MCV	92	fL	83-101
MCH	28.6	Pg	27-32
MCHC	31	G/dL	32-35
Platelet count	288000	/cumm	150000-450000
RDW-CV	12.7	%	11.4-14.0
ESR(WESTEGRENs METHOD)	12	mm in 1st hr	0-20

BIOCHEMISTRY

<u>Blood sugar fasting</u>	94	mg/dL	70-110
<u>Blood sugar pp</u>	119	mg/dL	70.0-140.0
<u>Bun (blood urea nitrogen)</u>	12.60	mg/dl	8.9-21.6
<u>Uric acid, serum</u>	4.6	mg/dl	3.5-7.2
<u>Creatinine, serum</u>	0.7	mg/dl	0.60-1.2

LFT(LIVER FUNCTION TEST)

Bilirubin Total	0.56	mg/dl	0.1-1.2
Bilirubin Conjugated	0.24	mg/dl	0-0.4
Bilirubin Unconjugated	0.32	mg/dl	up to 0.7
SGOT (AST)	59	U/L	0-46
SGPT (ALT)	144	U/L	0-49
Alkaline phosphatase	106	U/L	40-129
Gamma glutamyl transpeptidase	28	U/L	10-45
Total Protein	6.9	gm/dl	6.60 - 8.70
Albumin serum	3.7	g/dL	3.0-5.2
Globulin	3.20	gm/dl	1.8-3.4
Albumin/Globulin Ratio	1.16		1.10 - 2.50

LIPID PROFILE

Cholesterol	223	mg/dl	50-200
Triglycerides	92	mg/dL	25-150

Checked By.

DR. NITIN AGARWAL
M.B.B.S, MD (PATHOLOGIST)

Dr NITIN AGARWAL
M B B S , MD (Path)
DMC/R/01136

47, Harsh Vihar, Pitampura, New Delhi-110034 | Ph.: 011-42480101, 9599913051

E-mail: oneplusul@gmail.com | Web.: www.oneplusul.in

Page 2 of 6



OnePLUS Ultrasound Lab

— QUALITY FIRST... ALWAYS! —

Dr. Nitin Agarwal
Pathologist & Director
Ex. Sr. Res. MAMC
& Lok Nayak Hospital
Ex. Chief of Lab Dr. Lal Path Labs.

Dr. Pooja (Garg) Agarwal
Radiologist & Director
MAMC & Lok Nayak Hospital



NAME	:Mr. AMAN JAIN	Barcode No	:10131157
AGE/GENDER	:28 YRS/Male	SPECIMEN DATE	:08/Nov/2022 11:03AM
PATIENT ID	:104399	SPECIMEN RECEIVED	:08/Nov/2022 01:27PM
REFERRED BY	:Dr. MEDIWHEEL	REPORT DATE	:08/Nov/2022 03:23PM
CENTRE NAME	:ONEPLUS ULTRASOUND LAB	LAB NO.	:012211080024

Test Name	Result	Unit	Ref. Range
HDL Cholesterol	48	mg/dL	40 - 60
LDL cholesterol	157	mg/dL	<130
VLDL cholesterol	18.4	mg/dL	5-40
Cholesterol/HDL Ratio	4.6		Low Risk 3.3-4.97 Average Risk 4.4-7.1 Moderate Risk 7.1-11.0 High Risk >11.0
LDL/HDL Ratio	3.3		0 - 3.55

According to ATP III and NCEP guidelines

Parameter	Normal	Desirable	Borderline	High
Total cholesterol	<200		200-239	240
Triglycerides	<150	150-199	200-499	500
LDL	Optimal <100 Near Optimal 100-129	130-159	160-180	190
HDL	<40 : LOW 60 : HIGH			

ENDOCRINOLOGY


PSA TOTAL

Prostatic specific antigen, Total 0.77 ng/ml <4.0

< 40 years	0.21 to 1.72 ng/ml
40 - 49	0.27 to 2.19 ng/ml
50 - 59	0.27 to 3.42 ng/ml
60 - 69	0.22 to 6.16 ng/ml
> 69	0.21 to 6.77 ng/ml

Notes:

Checked By.


Dr. NITIN AGARWAL
M.B.B.S., MD (Path)
DMC/R/01436
DR. NITIN AGARWAL
MBBS, MD (PATHOLOGIST)

47, Harsh Vihar, Pitampura, New Delhi-110034 | Ph.: 011-42480101, 9599913051

E-mail: oneplusul@gmail.com | Web.: www.oneplusul.in

Page 3 of 6



OnePLUS Ultrasound Lab

— QUALITY FIRST, ALWAYS! —

Dr. Nitin Agarwal
Pathologist & Director
Ex. Sr. Res. MAMC
& Lok Nayak Hospital
Ex. Chief of Lab Dr. Lal Path Labs.

Dr. Pooja (Garg) Agarwal
Radiologist & Director
MAMC & Lok Nayak Hospital



NAME	:Mr. AMAN JAIN	Barcode No	:10131157
AGE/GENDER	:28 YRS/Male	SPECIMEN DATE	:08/Nov/2022 11:03AM
PATIENT ID	:104399	SPECIMEN RECEIVED	:08/Nov/2022 01:27PM
REFERRED BY	:Dr. MEDIWHEEL	REPORT DATE	:08/Nov/2022 03:23PM
CENTRE NAME	:ONEPLUS ULTRASOUND LAB	LAB NO.	:012211080024

Test Name	Result	Unit	Ref. Range
PSA is principally produced by the glandular epithelium of the prostate, and is secreted in the seminal fluid. PSA is also present in urine and blood. PSA acts on seminal fluid to fluidify and increase sperm mobility. PSA levels rise in prostatic pathologies such as benign prostatic hyperplasia (BPH) or prostate cancer.			

THYROID PROFILE(T3,T4,TSH)

Triiodothyronine total [t3]	0.64	ng/dl	0.52-1.9
Thyroxine total [t4]	7.60	µg/dl	4.4 - 10.8
TSH (Thyroid Stimulating Hormone)	2.20	µIU/ml	0.25-5.0

AGE WISE VARIATION IN TSH

AGE	TSH(µIU/ml)	AGE	TSH(µIU/ml)
1-4 weeks	1.00 - 19.0	16-20 yrs	0.25 - 5.0
1-12 mths	1.70 - 9.1	21 - 80 yrs	0.25 - 5.0
1-5 yrs	0.80 - 8.2	I st trimester	0.25 - 5.0
6-10 yrs	0.25 - 5.0	II nd trimester	0.50 - 5.0
11-15 yrs	0.25 - 5.0	III rd trimester	0.4 - 6.0

Reference ranges - Interpretation of Diagnostic tests - (Jacques Wallach)

1. Primary hypothyroidism is accompanied by depressed serum T3 and T4 values and elevated serum TSH level.
2. Primary hyperthyroidism is accompanied by elevated serum T3 and T4 levels along with depressed TSH values.
3. Slightly elevated T3 levels may be found in pregnancy and estrogen therapy, while depressed levels may be encountered in severe illness, renal failure and during therapy with drugs like propranolol and propyl thiouracil.
4. Although elevated TSH levels are nearly always indicative of primary hypothyroidism, and may be seen in secondary thyrotoxicosis

CLINICAL PATHOLOGY

URINE ROUTINE

Physical examination

Quantity	20	ML
Colour	PALE YELLOW	
Transparency	CLEAR	CLEAR
Sp.gravity	1.015	1.010-1.030
pH	6.00	

Checked By.

Dr. NITIN AGARWAL
MBBS, MD (Path)
DMC/R/01436
DR. NITIN AGARWAL
MBBS, MD (PATHOLOGIST)

47, Harsh Vihar, Pitampura, New Delhi-110034 | Ph.: 011-42480101, 9599913051

E-mail: oneplusul@gmail.com | Web.: www.oneplusul.in

Page 4 of 6



OnePLUS

Ultrasound Lab

— QUALITY FIRST... ALWAYS! —

Dr. Nitin Agarwal
Pathologist & Director
Ex. Sr. Res. MAMC
& Lok Nayak Hospital
Ex. Chief of Lab Dr. Lal Path Labs.

Dr. Pooja (Garg) Agarwal
Radiologist & Director
MAMC & Lok Nayak Hospital



NAME	:Mr. AMAN JAIN	Barcode No	:10131157
AGE/GENDER	:28 YRS/Male	SPECIMEN DATE	:08/Nov/2022 11:03AM
PATIENT ID	:104399	SPECIMEN RECEIVED	:08/Nov/2022 01:27PM
REFERRED BY	:Dr. MEDIWHEEL	REPORT DATE	:08/Nov/2022 03:23PM
CENTRE NAME	:ONEPLUS ULTRASOUND LAB	LAB NO.	:012211080024

Test Name	Result	Unit	Ref. Range
Reaction	ACIDIC		ACIDIC
<u>Chemical examination</u>			
Urine protein	NIL		NIL
Urine sugar	NIL		NIL
Bilirubin, urine	NEGATIVE		NEGATIVE
Urobilinogen	NORMAL		NORMAL
Ketones	NEGATIVE		NEGATIVE
<u>Microscopic examination</u>			
Pus cells.	2-3	/HPF	0-2
Epithelial cells	1-2	/HPF	NIL
R.B.C.	NIL	/HPF	NIL
Casts	NIL	/HPF	NIL
Crystals	NIL	/HPF	NIL
Bacteria	NIL	/HPF	NIL
Others.	NIL	NIL	NIL
STOOL ROUTINE			
<u>Physical examination</u>			
Colour	BROWNISH		
Consistency	SEMI FORMED		Semi Formed
Blood	ABSENT		Absent
Mucus	ABSENT		Absent
<u>Chemical examination, stool</u>			
pH	6.50		
<u>Microscopic examination</u>			
Pus cells	0-1	/HPF	
R.B.C.	NIL	/HPF	NIL
Ova	NIL		NIL
Cysts	NIL		NIL
Bacteria	NIL	/HPF	NIL

Checked By.

DR. NITIN AGARWAL
MBBS, MD (PATHOLOGIST)

Dr. NITIN AGARWAL
M B B S . MD (Path)
DMC/B/01426

47, Harsh Vihar, Pitampura, New Delhi-110034 | Ph.: 011-42480101, 9599913051

E-mail: oneplusul@gmail.com | Web.: www.oneplusul.in

Page 5 of 6



OnePLUS Ultrasound Lab

— QUALITY FIRST. ALWAYS! —

Dr. Nitin Agarwal

Pathologist & Director
Ex. Sr. Res. MAMC
& Lok Nayak Hospital
Ex. Chief of Lab Dr. Lal Path Labs.

Dr. Pooja (Garg) Agarwal

Radiologist & Director
MAMC & Lok Nayak Hospital



NAME	:Mr. AMAN JAIN	Barcode No	:10131157
AGE/GENDER	:28 YRS/Male	SPECIMEN DATE	:08/Nov/2022 11:03AM
PATIENT ID	:104399	SPECIMEN RECEIVED	:08/Nov/2022 01:27PM
REFERRED BY	:Dr. MEDIWHEEL	REPORT DATE	:08/Nov/2022 03:23PM
CENTRE NAME	:ONEPLUS ULTRASOUND LAB	LAB NO.	:012211080024

Test Name	Result	Unit	Ref. Range
Others	NIL		

*** End Of Report ***

Checked By.

Dr NITIN AGARWAL
M B B S , MD (Path)
DMC/R/01436
DR. NITIN AGARWAL
MBBS,MD(PATHOLOGIST)

47, Harsh Vihar, Pitampura, New Delhi-110034 | Ph.: 011-42480101, 9599913051

E-mail: oneplusul@gmail.com | Web.: www.oneplusul.in

Page 6 of 6

Clinical correlation is essential for final diagnosis. • If test results are unsatisfactory please contact personally or on phone. • This report is for perusal of doctors only.
• All disputes Subject to Delhi Jurisdiction only. • Not for medicolegal purposes. • All congenital anomalies in a foetus may not be diagnosed in routine obstetric ultrasound.



OnePLUS
Ultrasound Lab

— QUALITY FIRST... ALWAYS! —

Dr. Nitin Agarwal

Pathologist & Director
Ex. Sr. Res. MAMC
& Lok Nayak Hospital
Ex. Chief of Lab Dr. Lal Path Labs.

Dr. Pooja (Garg) Agarwal

Radiologist & Director
MAMC & Lok Nayak Hospital

Name	: Mr. AMAN JAIN	Age/Sex	: 28 YRS/Male
Ref. By	: Dr. MEDIWHEEL	Lab No	: 012211080024
Date	: 08-Nov-2022	Patient ID	: LSHHI104399

X-ray-Chest PA view

Bony cage and soft tissues are normal.

Cardiothoracic ratio is normal.

Mediastinum is normal.


Both hila are normal.

Both costophrenic angles are clear.

Both domes of diaphragm are normal.

Lung fields are clear. No parenchymal lesion seen.

IMPRESSION: Normal Study.


DR. POOJA GARG
RADIOLOGIST
M.B.B.S., D.M.R.D.
Reg No. DMC/R/03398
Radiologist

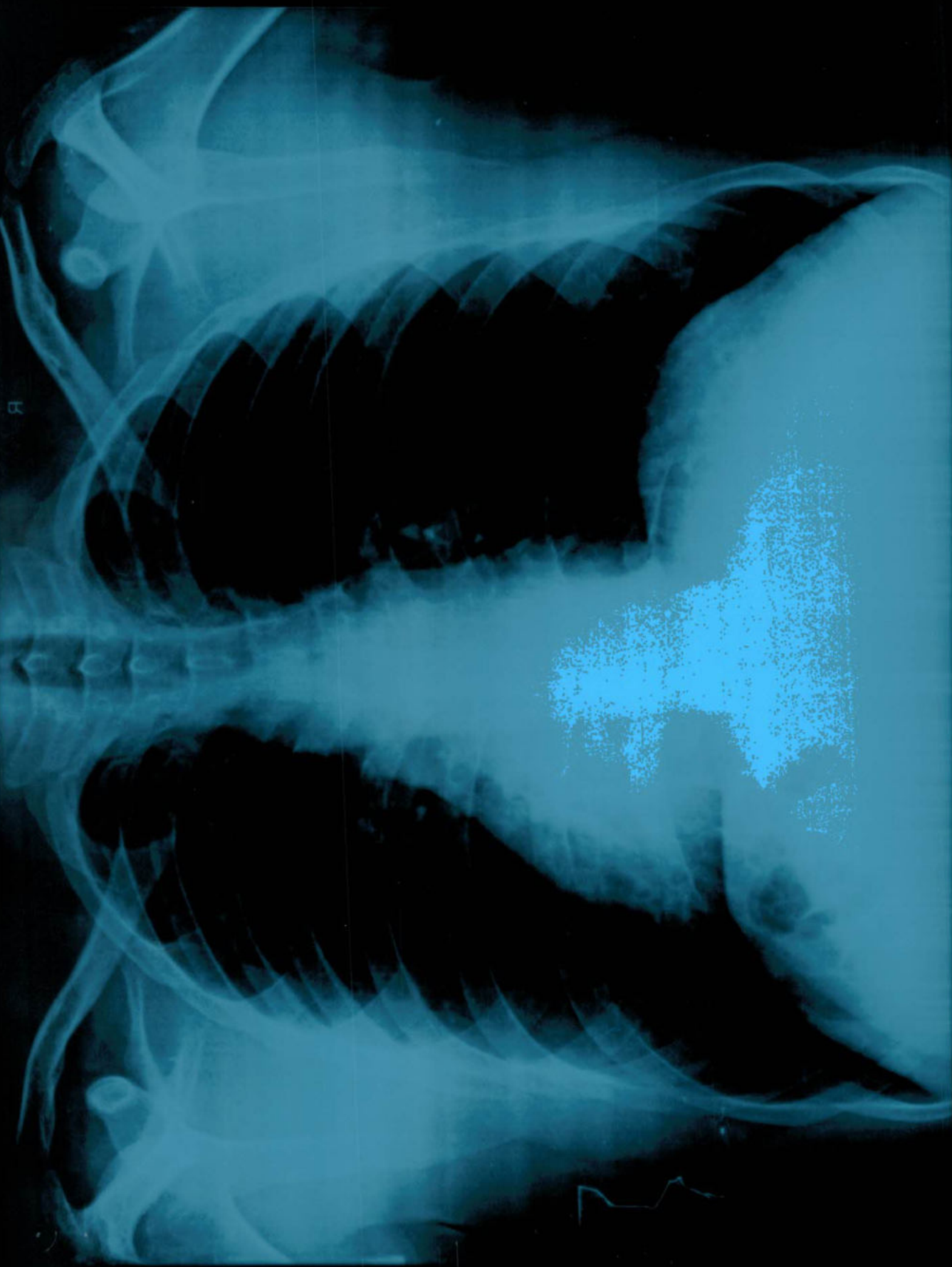
Type By : darshita

47, Harsh Vihar, Pitampura, New Delhi-110034 | Ph.: 011-42480101, 9599913051

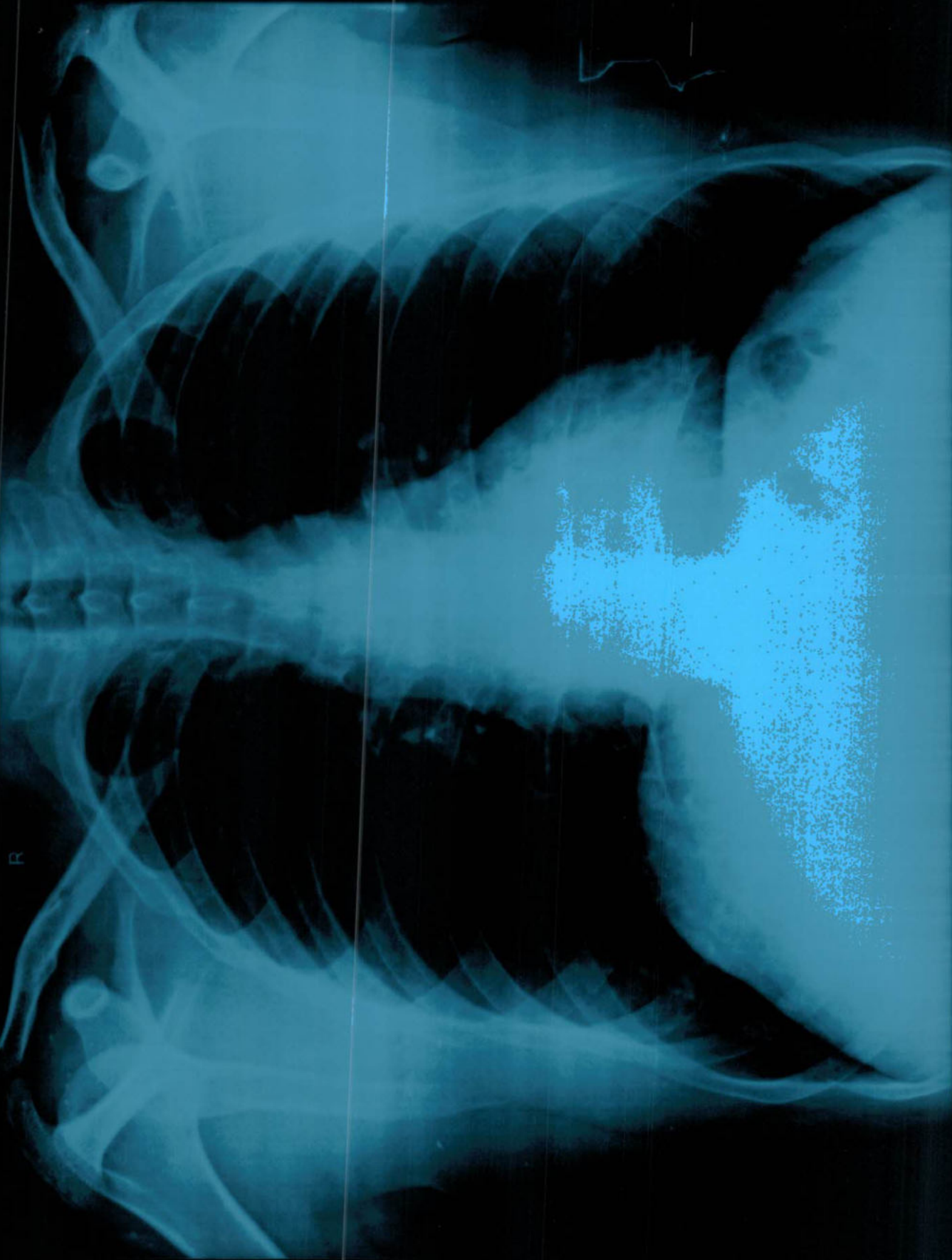
E-mail: oneplusul@gmail.com | Web.: www.oneplusul.in

Clinical correlation is essential for final diagnosis. • If test results are unsatisfactory please contact personally or on phone. • This report is for perusal of doctors only.
• All disputes Subject to Delhi Jurisdiction only. • Not for medicolegal purposes. • All congenital anomalies in a foetus may not be diagnosed in routine obstetric ultrasound.

ONEPLUS ULTRASOUND LAB 41-HARSH VIHAR BILAMPURA
MR AMAN JAIN 58 YRS 08/11/2025 M CHEST PA VIEW 11/8/2025



R



R

MR AMAN JAIN 28 YRS 08/11/2022 M CHEST PA VIEW 11/8/2022
ONEPLUS ULTRASOUND LAB, 47-HARSH VIHAR, PITAMPURA