

HEALTH CHECKUP REPORT

Patient Name: RAHUL AHIRRAO
Age/Gender: 31/M
Reg. No: 27701
Package: MEDIWHEEL

DATE: 12/11/2022

COMPLAINTS (IF ANY):

- Chest heaviness

HISTORY OF HEALTH STATUS: No

PRESENT MEDICATIONS: No

HYPERSENSITIVITY TO ANY DRUG: No

PERSONAL HISTORY:

- | | | | | | |
|---------------|---|----------|-----------------------------|---|---------|
| - Bowel | : | Regular | Diet | : | Veg |
| - Micturition | : | Normal | Habits | : | smoking |
| - Sleep | : | Adequate | Physical Activity/Exercise: | : | no |
| - Appetite | : | Adequate | | | |

HISTORY OF ILLNESS (WITH PAST MEDICATIONS): No

FAMILY HISTORY:

- Father :- hypertension
- Mother :- DM

VITAL SIGNS:

- | | | | |
|------------|----------|---------|------------|
| - Height : | 162 cms | Pulse : | 84/min. |
| - Weight : | 74.9 Kgs | B.P: | 114/76mmHg |



PHYSICIAN CONSULTATION:

1) Clinical Impression

- Pre diabetic
- Hyper Iglyceridemia

2) Recommendations

- 1 hr walk daily
- Avoid fatty food
- TMT
- Healthy life style

(Dr. Rashmi chovatia)

OPHTHALMO CONSULTATION:

RE

LE

Best corrected visual acuity

6/6

6/6

(Dr. Jignesh Shah)

DENTAL CONSULTATION:

Adv:

- Cleaning

(Dr. Parvin Chandarana)

Please take regular medicine as prescribed by the Doctor. (If given)



JCT (USA)



NABH



MC-3040

OUR ACCREDITATIONS

At CIMS...We Care

Patient ID 259086
Patient Name Mr. RAHUL MUKESHKUMAR AHIRRAO
Gender/Age Male/28
Ref Doctor

Dt : 12/11/2022

Rx

	Drug Name	Generic Name	Morning	Afternoon	Evening	Night	Duration
Cap.	SOMPRAZ D oral	ESMEPRAZOLE + DOMPERIDONE	1	0	0	0	1 Month(s)

Dr. Rashmi Chovatia



JCI (USA)



NABH



MC-3049

OUR ACCREDITATIONS

CIMS Hospital Private Limited

Plot No 67/1, Opposite Panchmrut Bunglows Near Shakun Mall, Off Science City Road, Soli, Ahmedabad, Gujarat 380060

© 1800 309 9999 CIN No. U85110GJ2001PTC039962

Reg. No : CIMS/A/2019/277071	VisitNo : HC/121122/12 [HCV]
Patient Name : MR. RAHUL MUKESHKUMAR AHIRRAO	Age(Y-M-D)/Sex : 31 Y 10 M 3 D. / Male
Referring Doctor : Dr. CIMS DOCTOR	Doctor :
Ward/Room :	Bed :

ORD/121122/348 Lab No : 2022167541 LSN : 933341 (Whole Blood) Sample Quality : Normal
 Collection Time : 12/11/2022 9:10:28 Arrival : 12/11/2022 9:52:28 Validation Time : 12/11/2022 12:52:50PM

	Result	Unit	Reference Range
CBC With ESR			
TOTAL COUNT			
Hemoglobin <i>(SLS Hemoglobin Detection method)</i>	13.1	g/dl	13.5 - 18.0 g/dl
Total RBC Count <i>(Hydro Dynamic Focusing Method)</i>	4.51	mill/Cmm	4.7 - 6.0 mill/Cmm
HCT <i>(Hydro Dynamic Focusing Method)</i>	39.2	%	42 - 52 %
Total WBC Count <i>(Flow Cytometry)</i>	7110	/Cmm	4000 - 10500 /Cmm
Platelet Count <i>(Hydro Dynamic Focusing Method)</i>	324000	/Cmm	150000 - 450000 /Cmm
DIFFERENTIAL COUNT (by Flow Cytometry)			
Polymorphs	61	%	40 - 70 %
Lymphocytes	32	%	22 - 45 %
Eosinophils	02	%	01 - 04 %
Monocytes	05	%	01 - 06 %
Basophils	00	%	00 - 01 %
Immature Granulocytes	00	%	0 - 2 %
Smear Study	RBCs are Normochromic & Normocytic. Platelets are adequate in number. Malarial Parasites are not seen. No Premature cells are seen.		
BLOOD INDICES (by Calculated Method)			
M.C.V	86.9	fl	78 - 100 fl
M.C.H	29.0	pg	27 - 31 pg
M.C.H.C.	33.4	gm/dl	32 - 36 gm/dl
RDW-CV	12.80	%	11.5 - 14.0 %
ESR (Red Cell Aggregation)			
After One Hour	06	mm	0 - 10 mm
Blood Group Rh			
ABO	"O"		



Dr. Kazumi Gondalia
M.D. (Path)
Consultant Pathologist
Reg. No. : G-21729

Dr. Manisha Shah
MD (Path & Bact)
Consultant Pathologist
Reg. No. : G-15496

Dr. Jitendra Nayak
MD (Path)
Consultant Pathologist
Reg. No. : G-14786



CIMS Hospital Private Limited

Plot No 67/1, Opp. Panchamrut Bunglows, Near Shukan Mall, Off Science City Road, Sola, Ahmedabad - 380060, Gujarat
 © 1800 309 9999 CIN No. U85110GJ2001PTC039962

Reg. No	: CIMS/A/2019/277071	VisitNo	: HC/121122/12 [HCV]
Patient Name	: MR. RAHUL MUKESHKUMAR AHIRRAO	Age(Y-M-D)/Sex	: 31 Y 10 M 3 D. / Male
Referring Doctor	: Dr. CIMS DOCTOR	Doctor	:
Ward/Room	:	Bed	:

ORD/121122/348 Lab No : 2022167541 LSN :933341 (Whole Blood) Sample Quality : Normal
Collection Time :12/11/2022 9:10:28 Arrival : 12/11/2022 9:52:28 Validation Time: 12/11/2022 12:52:50PM

Rh POSITIVE

HbA1c (Glycosylated Haemoglobin)

TEST

HbA1c (Glyco Hb) (Immuno Turbidimetric)	6.30	%	4.8-5.9% Normal 5.9-7.0% Good diabetic control 7.0-10.0% Fair diabetic control >10.0% Poor diabetic control
Mean Plasma Glucose	147	mg/dL	80 - 140 mg/dL

*** END OF REPORT ***



Dr. Kazumi Gondalia
M.D. (Path)
Consultant Pathologist
Reg. No. : G-21729

Dr. Manisha Shah
MD (Path & Bact)
Consultant Pathologist
Reg. No. : G-15496

Dr. Jitendra Nayak
MD (Path)
Consultant Pathologist
Reg. No. : G-14786



CIMS Hospital Private Limited

Plot No 67/1, Opp. Panchamrut Bunglows, Near Shukan Mall, Off Science City Road, Sola, Ahmedabad - 380060, Gujarat

© 1800 309 9999 CIN No. U85110GJ2001PTC039962

Print By : ankita.rajput

Print Date/Time : 12/11/2022 13:33:54 Page 2 of 2

Reg. No : CIMS/A/2019/277071	VisitNo : HC/121122/12 [HCV]
Patient Name : MR. RAHUL MUKESHKUMAR AHIRRAO	Age(Y-M-D)/Sex : 31 Y 10 M 3 D. / Male
Referring Doctor : Dr. CIMS DOCTOR	Doctor :
Ward/Room :	Bed :


ORD/121122/348 Lab No : 2022167542 LSN : 933341 (SERUM) Sample Quality : Normal
 Collection Time : 12/11/2022 9:10:28 Arrival : 12/11/2022 9:52:28 Validation Time: 12/11/2022 12:40:01PM

Liver Function Test

	<u>Result</u>	<u>Unit</u>	<u>Reference Range</u>
Alkaline Phosphatase <i>(PNPP, AMP Buffer Method, Colorimetric)</i>	97	U/L	40 - 129 U/L
Billirubin			
Total Billirubin <i>(Diazospecial Iazonium Iron with Blank)</i>	0.36	mg/dL	0.0 - 1.0 mg/dL
Direct Billirubin <i>(Diazo, (Evelyn Malloy) with Blank)</i>	0.13	mg/dL	0.0 - 0.2 mg/dL
Indirect Billirubin <i>(Calculated from Total and Direct Billirubin)</i>	0.23	mg/dL	0.0 - 0.8 mg/dL
SGPT (ALT) <i>(IFCC without pyridoxal phosphate)</i>	24.3	U/L	0 - 41 U/L
SGOT (AST) <i>(IFCC without pyridoxal 5 phosphate)</i>	17.7	U/L	0 - 40 U/L
Total Protein			
Total Proteins <i>(Biuret Method)</i>	7.7	gm/dl	6.4 - 8.3 gm/dl
Albumin <i>(Bromocresol Green Colorimetric)</i>	5.05	gm/dl	3.97 - 4.95 gm/dl
Globulin	2.65	gm/dl	2.2 - 3.5 gm/dl
A/G Ratio	1.91		0.9 - 2.1

Dr. Manisha Shah
MD (Path & Bact)
Consultant Pathologist
Reg. No. : G-15496

Dr. Jitendra Nayak
MD (Path)
Consultant Pathologist
Reg. No. : G-14786


Dr. Kazumi Gondalia
M.D. (Path)
Consultant Pathologist
Reg. No. : G-21729



CIMS Hospital Private Limited

Plot No 67/1, Opp. Panchamrut Bunglows, Near Shukan Mall, Off Science City Road, Sola, Ahmedabad - 380060, Gujarat

1800 309 9999 CIN No. U85110GJ2001PTC039962

Print By : ankita.rajput

Print Date/Time : 12/11/2022 13:34:01 Page 1 of 2

Reg. No : CIMS/A/2019/277071	VisitNo : HC/121122/12 [HCV]
Patient Name : MR. RAHUL MUKESHKUMAR AHIRRAO	Age(Y-M-D)/Sex : 31 Y 10 M 3 D. / Male
Referring Doctor : Dr. CIMS DOCTOR	Doctor :
Ward/Room :	Bed :


ORD/121122/348 Lab No : 2022167542 LSN :933341 (SERUM) Sample Quality : Normal
 Collection Time :12/11/2022 9:10:28 Arrival : 12/11/2022 9:52:28 Validation Time: 12/11/2022 12:40:00PM

	<u>Result</u>	<u>Unit</u>	<u>Reference Range</u>
Creatinine (Buffered Jaffe Reaction Kinetic Compensated)	0.78	mg/dL	0.7 -1.2 mg/dL
Estimated GFR	141.68	mL/min/1.73m2	59 - 137 mL/min/1.73m2
Fasting Glucose (Hexokinase)	104.5	mg/dL	70 - 100 mg/dL
Thyroid Function Test			
TOTAL T3 (T3) * (Electrochemiluminescence Assay)	1.1	ng/ml	0.846 - 2.02 ng/ml
TOTAL T4 (T4) * (Electrochemiluminescence Assay)	6.75	µgm/dl	5.13 - 14.06 µgm/dl
TSH (Electrochemiluminescence Assay)	2.68	µIU/ml	0.27- 4.20 µIU/ml
Uric Acid (Uricase Colorimetric Enzymatic)	7.04	mg/dL	3.4 - 7.0 mg/dL

*** END OF REPORT ***

Dr. Manisha Shah
MD (Path & Bact)
Consultant Pathologist
Reg. No. : G-15496

Dr. Jitendra Nayak
MD (Path)
Consultant Pathologist
Reg. No. : G-14786


Dr. Kazumi Gondalia
M.D. (Path)
Consultant Pathologist
Reg. No. : G-21729



CIMS Hospital Private Limited

Plot No 67/1, Opp. Panchamrut Bungalows, Near Shukan Mall, Off Science City Road, Sola, Ahmedabad - 380060, Gujarat

1800 309 9999 CIN No. U85110GJ2001PTC039962

Print By : ankita.rajput

Print Date/Time : 12/11/2022 13:34:01

Page 2 of 2

Reg. No : CIMS/A/2019/277071	VisitNo : HC/121122/12 [HCV]
Patient Name : MR. RAHUL MUKESHKUMAR AHIRRAO	Age(Y-M-D)/Sex : 31 Y 10 M 3 D. / Male
Referring Doctor : Dr. CIMS DOCTOR	Doctor :
Ward/Room :	Bed :

ORD/121122/348 Lab No : 2022167546 LSN : 933341 (SERUM) Sample Quality : Normal
Collection Time : 12/11/2022 9:10:28 Arrival : 12/11/2022 9:52:28 Validation Time: 12/11/2022 12:53:39PM

	<u>Result</u>	<u>Unit</u>	<u>Reference Range</u>
BUN * (Ureas with UV)	9.0	mg/dL	6 - 20 mg/dL

*** END OF REPORT ***

Dr. Manisha Shah
MD (Path & Bact)
Consultant Pathologist
Reg. No. : G-15496

Dr. Jitendra Nayak
MD (Path)
Consultant Pathologist
Reg. No. : G-14786


Dr. Kazumi Gondalia
M.D. (Path)
Consultant Pathologist
Reg. No. : G-21729



CIMS Hospital Private Limited

Plot No 67/1, Opp. Panchamrut Bunglows, Near Shukan Mall, Off Science City Road, Sola, Ahmedabad - 380060, Gujarat

© 1800 309 9999 CIN No. U85110GJ2001PTC039962

Print By: ankita.rajput

Print Date/Time: 12/11/2022 13:34:18


Page 1 of 1

Reg. No : CIMS/A/2019/277071	VisitNo : HC/121122/12 [HCV]
Patient Name : MR. RAHUL MUKESHKUMAR AHIRRAO	Age(Y-M-D)/Sex : 31 Y 10 M 3 D. / Male
Referring Doctor : Dr. CIMS DOCTOR	Doctor :
Ward/Room :	Bed :

ORD/121122/348 Lab No : 2022167542 LSN :933341 (SERUM) Sample Quality : Normal
 Collection : 12/11/2022 9:10:28AM Arrival: 12/11/2022 9:54:41 Validation Time 12/11/2022 12:05:48

<u>Lipid Profile (With Direct LDL)</u>	<u>Result</u>	<u>Unit</u>	<u>Reference Range</u>
Type of Sample	: Fasting	.	
Cholesterol <i>(Enzymatic/Colorimetric, Cholesterol Oxidas, Esterase, Peroxidase Gen.2)</i>	: 188.5	mg/dL	Less than 160 mg/dl Excellent Less than 200 mg/dl Desireble 200-239 mg/dl Borderline High 240 mg/dl & over High
Triglyceride <i>(Enzymetic Colorimetric without Glycerol Blank without Serum Blank)</i>	: 240.2	mg/dL	Less than 150 mg/dl Normal 150 - 199 mg/dl Borderline High 200-499 mg/dl High 500 mg/dl or greater Very High
HDL Cholesterol <i>(Direct Mearuse Homogenous Technique Modified Enzymatic Colorimetric Gen. 3)</i>	: <u>40.3</u>	mg/dL	Less than 40 mg/dl Low 60 mg/dl or above Excellent
L D L Cholesterol (DIRECT) <i>(Homogenous Enzymatic colorimetric Assay)</i>	: <u>116.1</u>	mg/dL	Less than 80 mg/dl Excellent Less than 100 mg/dl Optimal 100 - 129 mg/dl Near or above optimal 130 - 159 mg/dl Borderline High 160 - 189 mg/dl High 190 mg/dl & above Very High
VLDL Cholesterol <i>(Calculated)</i>	: 48.04	mg/dL	15 - 30 mg%
Cholesterol/HDL Ratio <i>(Calculated)</i>	: 4.68		Normal upto 4.5
LDL/HDL Ratio <i>(Calculated)</i>	: 2.88		Less than 3.5

Remarks :


Dr. Kazumi Gondalia
 M.D. (Path)
 Consultant Pathologist
 Reg. No. : G-21729

Dr. Manisha Shah
 MD (Path & Bact)
 Consultant Pathologist
 Reg. No. : G-15496

Dr. Jitendra Nayak
 MD (Path)
 Consultant Pathologist
 Reg. No. : G-14786



Reg. No : CIMS/AJ/2019/277071	VisitNo : HC/121122/12 [HCV]
Patient Name : MR. RAHUL MUKESHKUMAR AHIRRAO	Age(Y-M-D)/Sex : 31 Y 10 M 3 D. / Male
Referring Doctor : Dr. CIMS DOCTOR	Doctor :
Ward/Room :	Bed :


ORD/121122/348 Lab No : 2022167543 LSN : 933341 (Urine) Sample Quality : Normal
 Collection Time : 12/11/2022 9:10:28 Arrival : 12/11/2022 9:52:28 Validation Time : 12/11/2022 12:53:09PM

	Result	Unit	Reference Range
Urine R & M			
PHYSICAL EXAMINATION			
Quantity	20 cc		
Colour	Pale Yellow		
Transperancy	Clear		
Reaction (QDS-10 Strip)	7.0		
Sp. Gravity (QDS-10 Strip)	1.010		1.005 - 1.035 .
CHEMICAL EXAMINATION			
U. Albumin (QDS-10 Strip/Manual)	Nil		
U. Glucose (QDS-10 Strip/Manual)	Nil		
U. Acetone (QDS-10 Strip/Manual)	Absent		
BS/BP (QDS-10 Strip/Manual)	Absent		
MICROSCOPIC EXAMINATION			
Pus Cell	Occasional	/H.P.F.	/H.P.F.
Red Blood Cell	Nil	/H.P.F.	/H.P.F.
Epithelial Cell	1-2	/H.P.F.	/H.P.F.
Cast	Not Seen		
Crystals	Not Seen		
Amorphous	Absent		
Monilia	Absent		

*** END OF REPORT ***

Dr. Manisha Shah
MD (Path & Bact)
Consultant Pathologist
Reg. No. : G-15496

Dr. Jitendra Nayak
MD (Path)
Consultant Pathologist
Reg. No. : G-14786


Dr. Kazumi Gondalia
M.D. (Path)
Consultant Pathologist
Reg. No. : G-21729



CIMS Hospital Private Limited

Plot No 67/1, Opp. Panchamrut Bunglows, Near Shukan Mall, Off Science City Road, Sola, Ahmedabad - 380060, Gujarat
 © 1800 309 9999 CIN No. U85110GJ2001PTC039962

Print By : ankita.rajput

Print Date/Time: 12/11/2022 13:34:09 Page 1 of 1

ECHO Report**Dt : 12/11/2022****Patient Details**

Patient ID 259086
Name Mr. RAHUL MUKESHKUMAR AHIRRAO
Age 28 Years
Gender Male
Blood Group
Referral Doctor

ECHO Identification Detail**Doctor Incharge** Dr. VIPUL KAPOOR**Clinical Status Of Patient****ECHO Code** Hiren

Finding Description

1. Normal cardiac chambers dimensions
2. Normal LV systolic function, LVEF: 60%.
3. No RWMA.
4. Grade I diastolic dysfunction.
5. All cardiac valves are structurally normal.
6. Mild MR, Mild TR, Trivial PR, No AR.
7. Mild PAH, RVSP: 35 mm Hg.
8. IAS/IVS: Intact.
9. No clot/vegetation/pericardial effusion.
10. No coarctation of aorta.

Dr. VIPUL KAPOOR**CIMS Hospital Private Limited**

Plot No 67/1, Opposite Panchmrut Bunglows Near Shakun Mall, Off Science City Road, Sola, Ahmedabad, Gujarat 380060
 © 1800 309 9999 CIN No. U85110GJ2001PTC039962

ID: 892

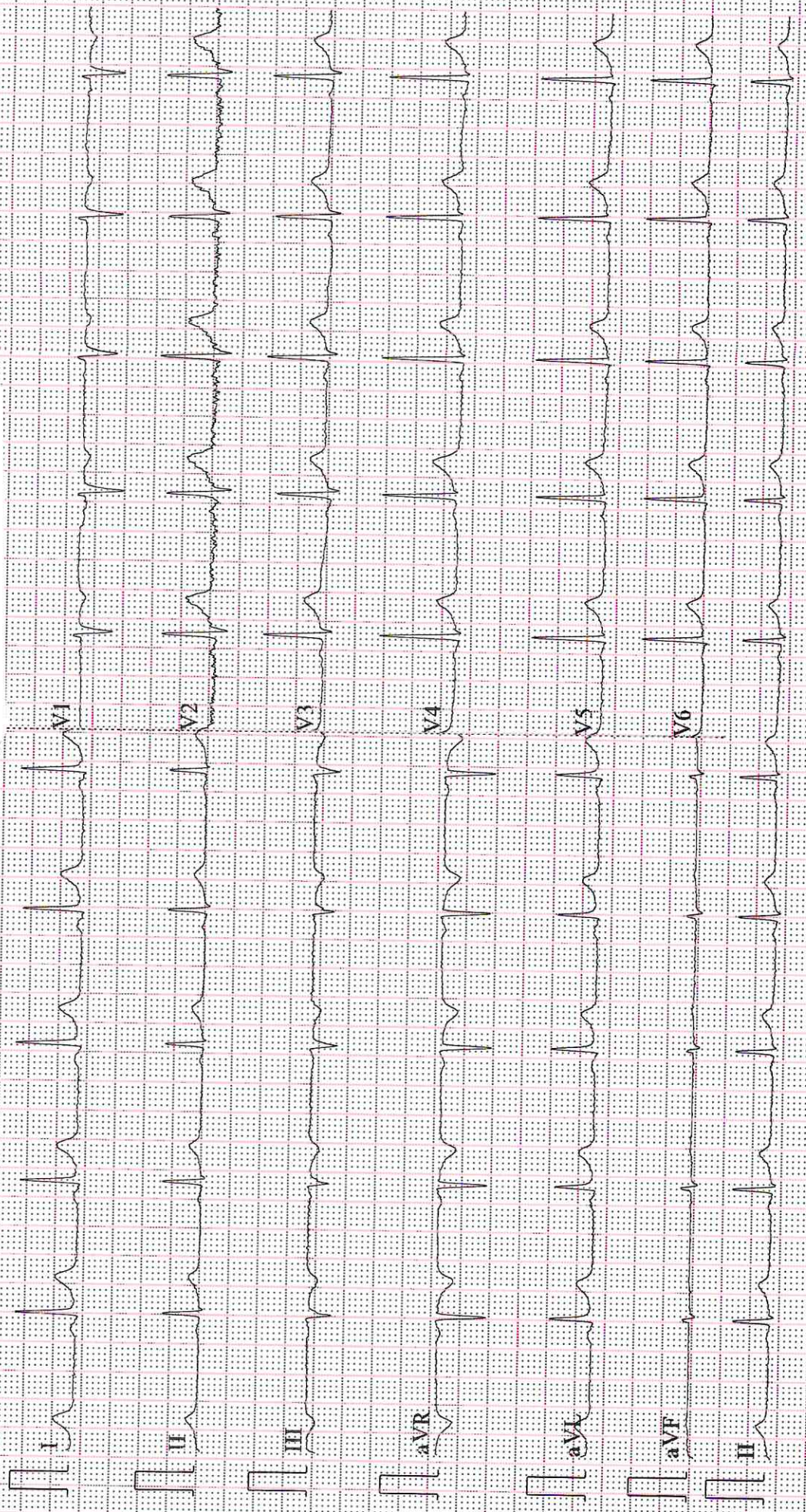
Years

HR 62 bpm
 P 108 ms
 PR 134 ms
 QRST 84 ms
 QT/QTc 372/381 ms
 P/QRS/T -4/0/3 °
 RV5/SV1 1.20/10.6/17 mV

Diagnosis Information:

Name : MR. RAHUL
 MUKESHKUMAR AHIRRAO
 Reg No : CIMS/A/2019/277071
 DoB/Sex 09/01/1991 / Male

NSR/COM



Patient's Name : RAHUL M AHIRRAO
Reg. No. (IP/OP): HC-277071
Referred By Dr. : CIMS

Age, Sex : 28Y/M
Date : 12/11/2022

USG OF ABDOMEN & PELVIS

LIVER: Liver shows bright echotexture and is normal in size. S/O Fatty liver (Grade-I-II). No evidence of focal SOL or dilatation of IHBR seen. Porta hepatis appear normal.

GALLBLADDER: Gallbladder appeared partially distended. No pericholecystic collection is seen.

PANCREAS: Visualised pancreas appeared normal in size and echotexture. No focal lesion, mass or pancreatitis.

SPLEEN: Spleen appears normal in size and echotexture.

PARAAORTIC REGION: Aorta grossly appeared normal. No paraaortic lymphnodes seen.

KIDNEYS: Both kidneys appear normal in size, shape and in position. Cortex and collecting system of both kidneys appeared normal. No evidence of calculus or obstructive uropathy on either side. Right kidney: 91x55mm. Left kidney: 95x50mm.

URINARY BLADDER: Bladder appeared normal. No calculus or mass lesion is seen.

PROSTATE: Prostate appears normal in size and echotexture. Size of prostate: 27x23x32mm. Volume: 10cc.

No evidence of free fluid or collection is seen in peritoneal spaces. Normal small bowel peristalsis noted.

COMMENTS: Appearance suggests,

- **Fatty liver (Grade-I-II).**

Kindly correlate clinically.



DR KIRTAN SHAH M.D. RADIODIAG. CONS. RADIOLOGIST
DR DEEPA SHAH M.D., D.M.R.E. CONS. RADIOLOGIST
DR UMA MEHTA D.M.R.D. F.R.C.R. CONS. RADIOLOGIST
DR NIMISH SHARMA D.M.R.D. (D.N.B.) CONS. RADIOLOGIST
DR RAVINA CHAUHAN M.D. RADIODIAG. CONS. RADIOLOGIST
DR YASH PATEL M.D., D.N.B. CONS. RADIOLOGIST
DR SUNALI DESAI MD, DNB, DM, FRCR NEURORADIOLOGIST

Note: This is only a radiological impression and not the final diagnosis. All diagnostic modalities have their own limitations. Therefore radiological modality report should be interpreted in correlation with clinical and pathological findings.

