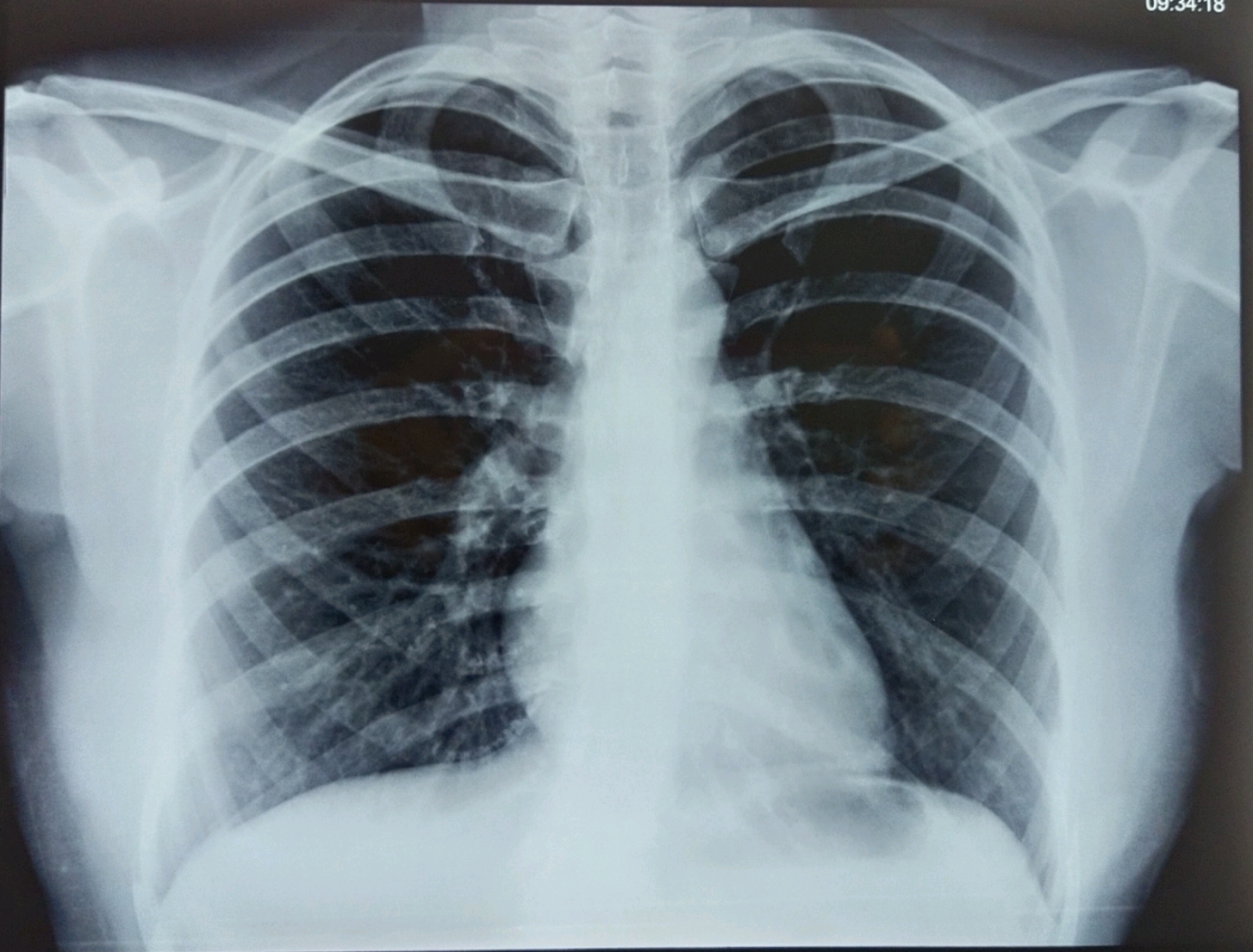


KAVI K 25 Y.,

12/12/2021  
09:34:18





Name	MISS.RAKAVI K	Patient ID	72562
Accession No	75195	Age/Gender	25Y / Female
Referred By	Dr.MEDIWHEEL	Date	13-Dec-2021

## USG REPORT - ABDOMEN AND PELVIS

### LIVER:

Is normal in size ~ 15.1 cm and shows normal echo texture.

No obvious focal lesion seen. No intra - Hepatic biliary radical dilatation seen.

### GALL BLADDER:

Is adequately distended. No calculus or internal echoes are seen. Wall thickness is normal.

### PANCREAS:

Appears normal in size and it shows uniform echo texture.

### SPLEEN:

Is normal in size ~ 9.4 cm and shows uniform echogenicity.

### RIGHT KIDNEY:

Right kidney measures ~ 10 x 4.1 cms.

The shape, size and contour of the right kidney appear normal.

Cortico medullary differentiation is within normal. No evidence of pelvicalyceal dilatation.

No calculi seen.

### LEFT KIDNEY:

Left kidney measures ~ 10.3 x 4.4 cms.

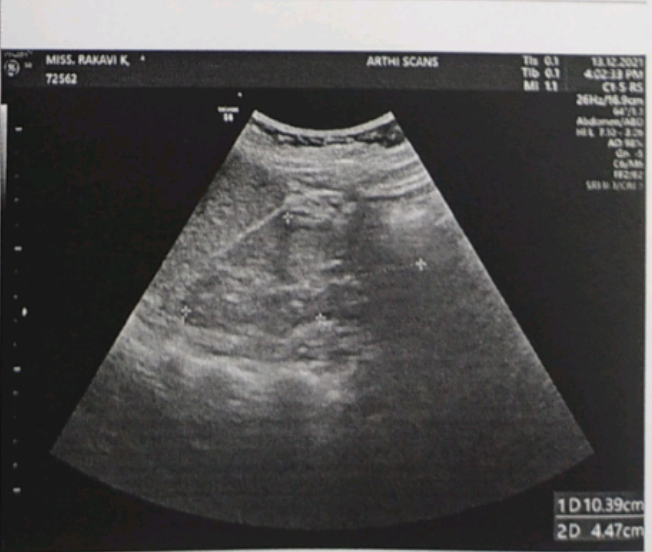
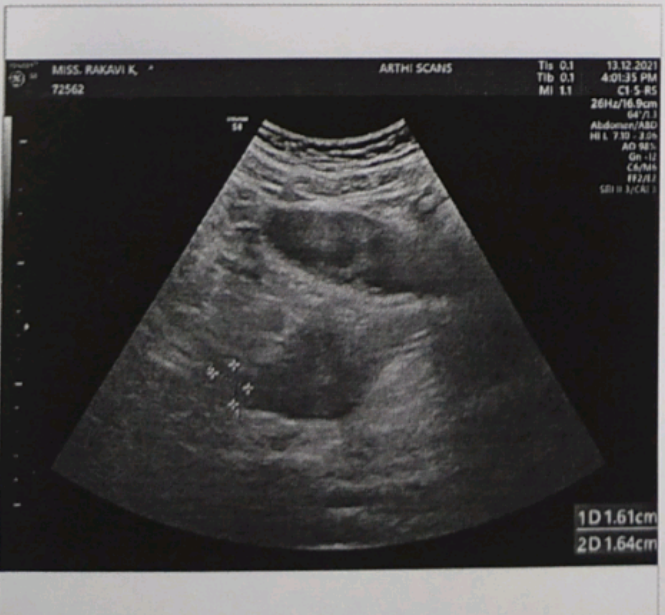
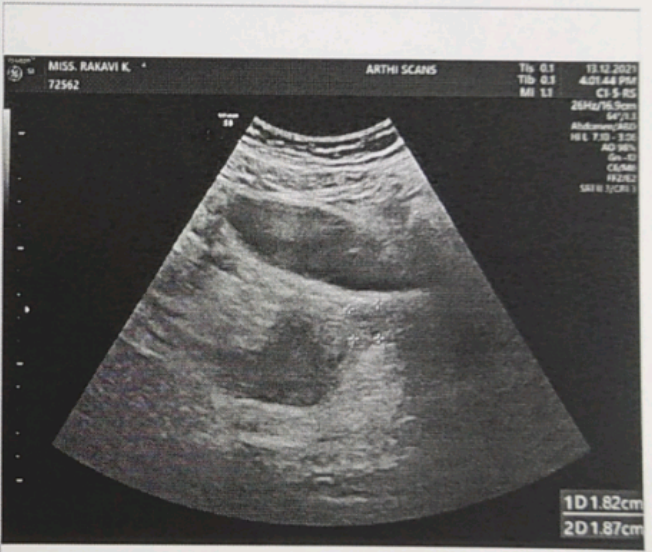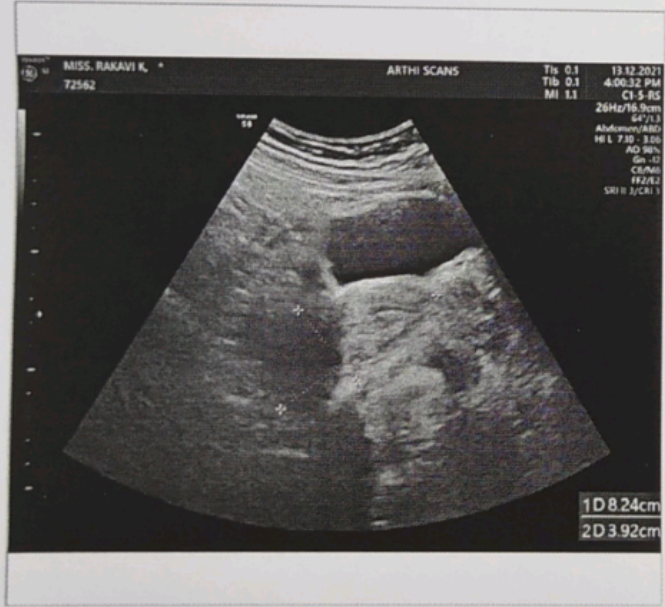
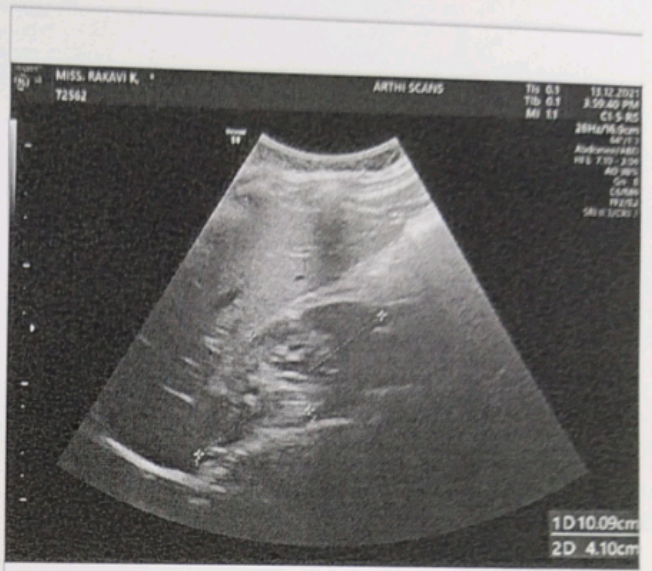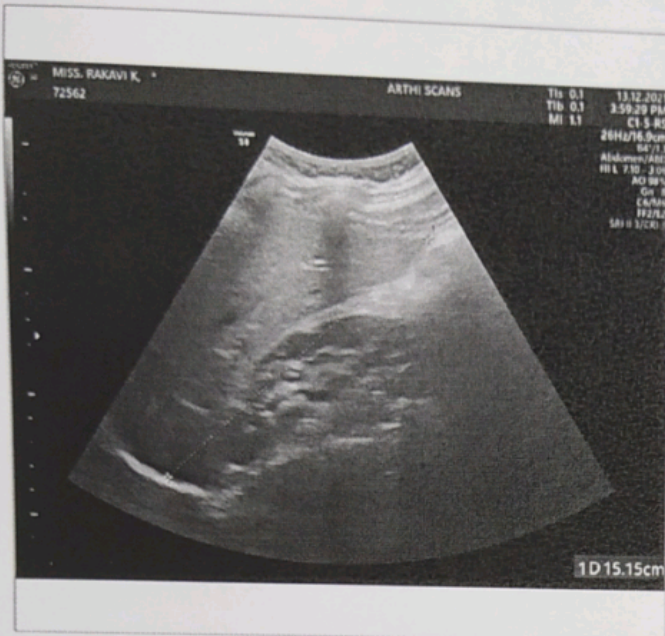
The shape, size and contour of the left kidney appear normal.

Cortico medullary differentiation is within normal. No evidence of pelvicalyceal dilatation.

No calculi seen.

# ARTHI CT AND MRI SCANS

MISS. RAKAVI K /F 72562 13-Dec-2021 03:59:17 PM





Name	MS.RAKAVI K	Patient ID	75195
Accession No	72562	Age/Gender	25 Y / Female
Referred By	Dr.MEDIWHEEL	Date	12-Dec-2021

## X-RAY - CHEST PA VIEW

### OBSERVATION:

The trachea is central.

The mediastinal and cardiac silhouette are normal.

Cardiothoracic ratio is normal.

Cardiophrenic and costophrenic angles are normal.

Both hila are normal.

Lung zones are clear.

Bones of the thoracic cage are normal.

Soft tissues of the chest wall are normal.

### IMPRESSION:

- No significant abnormality seen.

Dr. Abinaya R MDRD.,  
Consultant Radiologist



# ARTHI SCANS

<b>NAME</b>	MISS. RAKAVI K	<b>PATIENT ID</b>	72562
<b>ACCESSION NO</b>	75195	<b>AGE/GENDER</b>	25Y/FEMALE
<b>REFERRED BY</b>	MEDIWHEEL	<b>DATE</b>	12.12.2021

## VISUAL ACUITY (VA )

### WITH BEST CORRECTION

#### **DISTANCE VISION (With glasses)**

**Right** 10/10

**Left** 10/10

**Both** 10/10

#### **NEAR VISION (With glasses)**

**Both** N6

#### **COLOUR VISION (With glasses)**

**BOTH** Normal

#### **DISTANCE VISION (Without glasses)**

**Right** 7/10

**Left** 8 /10

**Both** 8/10

#### **NEAR VISION (Without glasses)**

**Both** N6

#### **COLOUR VISION (Without glasses)**

**BOTH** Normal



# ARTHI SCANS

NAME	MISS. RAKAVI K	PATIENT ID	72562
ACCESSION NO	75195	AGE/GENDER	25Y/FEMALE
REFERRED BY	MEDIWHEEL	DATE	13.12.2021

## ECHOCARDIOGRAPHIC EVALUATION

### MEASUREMENTS: ACOUSTIC WINDOW: OPTIMAL

#### 2D/ M MODE PARAMETERS:

Parameters	Patient Values	Normal Adult Value
LA	2.54	(2.0 - 4.0 cm)
AO	2.13	(2.0 - 4.0 cm)
LVIDD	4.29	(3.5 - 5.5 cm)
LVIDS	2.68	(2.5 - 4.3 cm)
IVSd	0.71	(0.6 - 1.2 cm)
LVPWd	0.71	(0.6 - 1.2 cm)
EF	68	(50% - 70%)

#### IMPRESSION:

- ✚ No regional wall motion abnormality at rest.
- ✚ Normal valves and chambers.
- ✚ No pulmonary hypertension.
- ✚ No pericardial effusion.
- ✚ Normal LV systolic function.

**Dr. KARTHIK C.S.MD.,PGD(CARDIOLOGY,UKR)  
CONSULTANT CARDIOLOGIST.**

Thank you for the courtesy of this referral

Foot note: Patient identify is not verified .Report is not valid for medico legal purpose.

Obli Towers, 594, D.B. Road, R. S. Puram, Coimbatore-641 002. Mobile : 99430 99994 email: info@arthiscans.com

Name	MISS.RAKAVI K	Patient ID	72562
Accession No	75195	Age/Gender	25Y / Female
Referred By	Dr.MEDIWHEEL	Date	13-Dec-2021

## USG REPORT - ABDOMEN AND PELVIS

### BLADDER:

Is normal contour. No intra luminal echoes are seen.

### UTERUS:

**Retroverted uterus.**

Measures ~ 8.2 x 3.9 x 4 cms.

Endometrium is regular and normal (4 mm).

Cervix appears normal.

### OVARIES:

Right ovary measures ~ 1.6 x 1.6 cms.


Left ovary measures ~ 1.8 x 1.8 cms.

No adnexal mass lesion seen. Pouch of Douglas is free. No free fluid in abdomen.

### IMPRESSION:

❖ **Retroverted uterus.**

- **Suggested clinical correlation.**

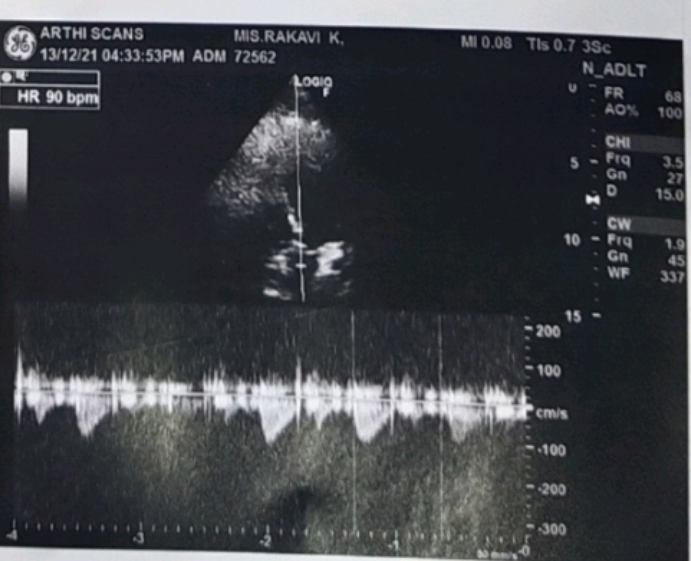
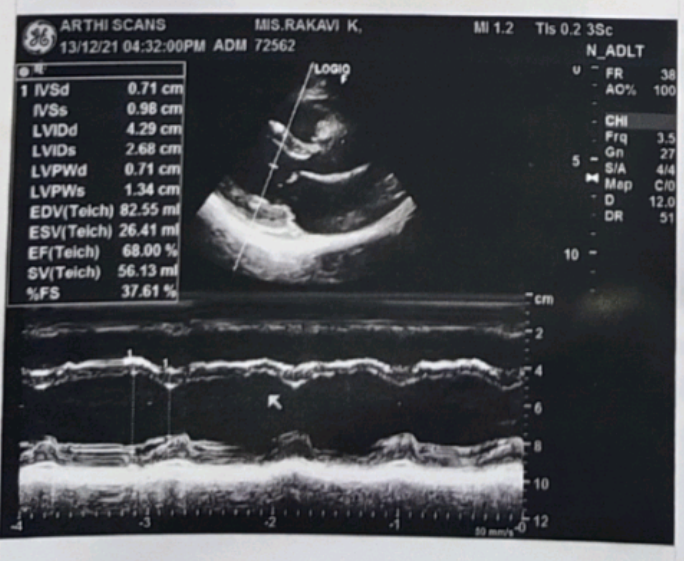
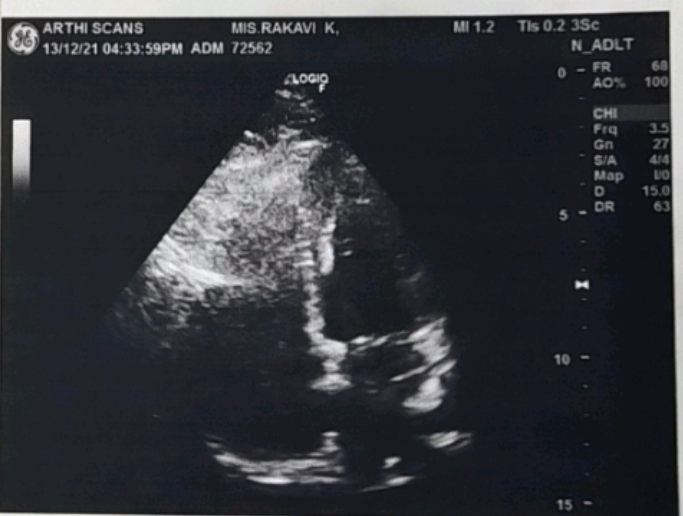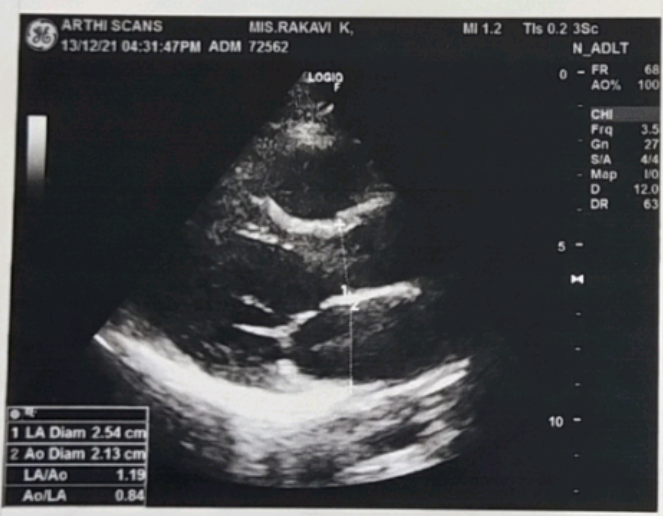
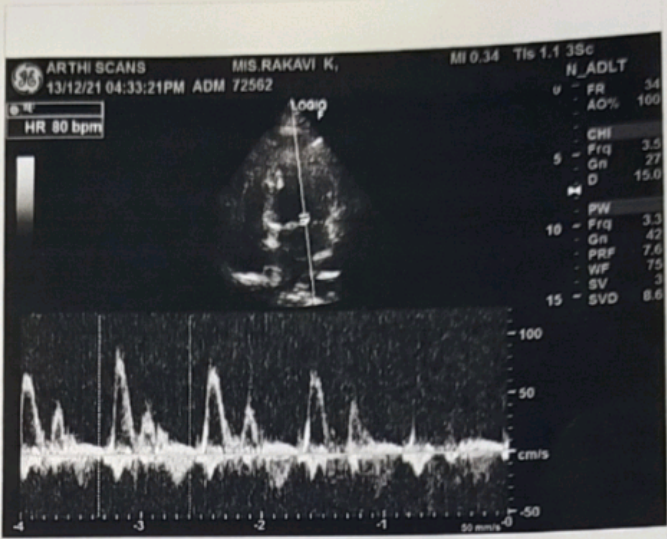
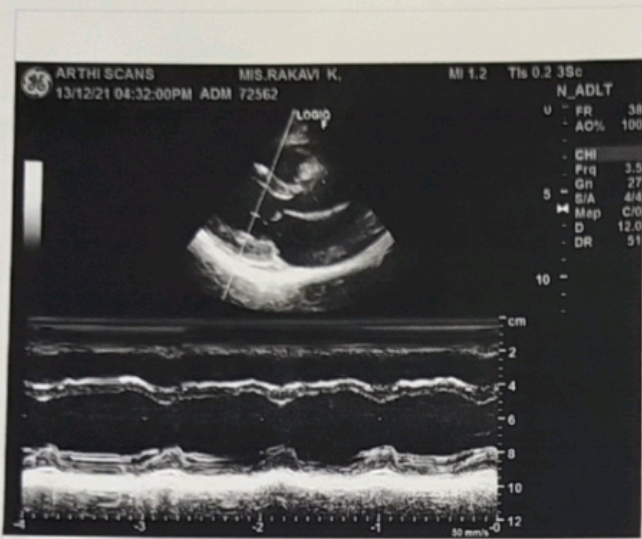


**Dr. Lokesh Babu., MDRD.,  
Radiologist**

**Thank you for the courtesy of this referral**

**Foot Note: Patient's identity is not verified. Report is not valid for medico legal purpose.**

**Dr. Lokesh Babu, MD.,RD.,  
Reg. No: 113030**





Aarthi CT and MRI Scans, R S Puram West

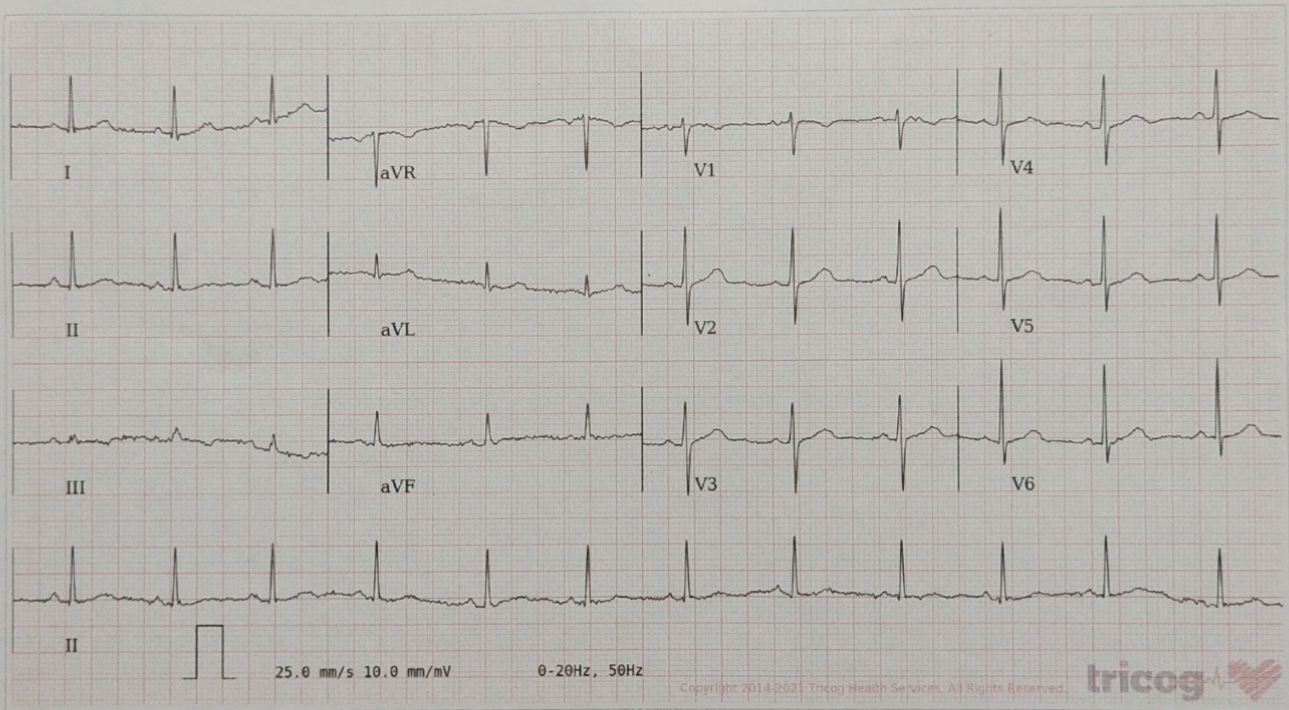


Age / Gender: 25/Female

Date and Time: 13th Dec 21 3:06 PM

Patient ID: 0000072562

Patient Name: MISS. RAKAVI K



AR: 76 bpm VR: 76 bpm QRSD: 82 ms QT: 388 ms QTc: 436 ms PRI: 134 ms P-R-T: 37° 43° 17°

ECG Within Normal Limits: Sinus Rhythm, Normal Axis. Please correlate clinically.

Disclaimer: Analysis in this report is based on ECG alone and should only be used as an adjunct to clinical history, symptoms and results of other invasive and non-invasive tests and must be interpreted by a qualified physician.

