

## CERTIFICATE OF MEDICAL FITNESS

This is to certify that I have conducted the clinical examination

of Mrs. Namita Dixit on 23/09/2023

After reviewing the medical history and on clinical examination it has been found that he/she is

	Tick
<ul style="list-style-type: none"><li>• Medically Fit</li></ul>	<input checked="" type="checkbox"/>
<ul style="list-style-type: none"><li>• Fit with restrictions/recommendations</li></ul> <p>Though following restrictions have been revealed, in my opinion, these are not impediments to the job.</p> <p>1.....</p> <p>2.....</p> <p>3.....</p> <p>However the employee should follow the advice/medication that has been communicated to him/her.</p> <p>Review after _____</p>	<input type="checkbox"/>
<ul style="list-style-type: none"><li>• Currently Unfit. Review after _____ recommended</li></ul>	<input type="checkbox"/>
<ul style="list-style-type: none"><li>• Unfit</li></ul>	<input type="checkbox"/>

Dr. Chinmay D. Naik  
Medical Officer  
The Apollo Clinic, (Location)  
**Dr. Chinmay D. Naik**  
M.B.B.S., CDM  
(certificate course in treatment of  
Diabetes Mellitus)  
Reg.No.:MCI-13/51948

*This certificate is not meant for medico-legal purposes.*

Patient Name : Mrs. NAMITA DIXIT Age : 34 Y F  
UHID : CVIM.0000230594 OP Visit No : CVIMOPV563619  
Reported on : 23-09-2023 12:56 Printed on : 25-09-2023 13:18  
Adm/Consult Doctor : Ref Doctor : SELF

**DEPARTMENT OF RADIOLOGY**

**X-RAY CHEST PA**

**X-RAY CHEST PA**

Trachea appears normal.

Both the lung fields are clear.

Cardiac shadows appear apparently normal.

Both domes of diaphragm appear normal.

Both costophrenic angles are clear.

Bony thoracic cage shows no deformity. Visualised bones appear normal.

Soft tissues appear normal.

**Impression:** Essentially Normal Study.

Printed on:23-09-2023 12:56

---End of the Report---

*Preeti*

**Dr. PREETI P KATHE**  
**DMRE, MD, DNB**  
Radiology

**Apollo Health and Lifestyle Limited**

(CIN - UBS110TG2000PLC115810)

Regd. Office: 1-10-60/62, Ashoka Raghupathi Chambers, 5th Floor, Begumpet, Hyderabad, Telangana - 500 016.

Ph No: 040-4904 7777, Fax No: 4904 7744 | Email ID: enquiry@apollohl.com | www.apollohl.com

**APOLLO CLINICS NETWORK MAHARASHTRA**

Pune (Aundh | Kharadi | Nigdi Pradhikaran | Viman Nagar | Wanowrie)

Online appointments: www.apolloclinic.com

Page 1 of 1  
TO BOOK AN APPOINTMENT

**1860 500 7788**

Patient Name	: Mrs. NAMITA DIXIT	Age	: 34 Y F
UHID	: CVIM.0000230594	OP Visit No	: CVIMOPV563619
Reported on	: 23-09-2023 13:29	Printed on	: 25-09-2023 13:18
Adm/Consult Doctor	:	Ref Doctor	: SELF

## DEPARTMENT OF RADIOLOGY

### ULTRASOUND - WHOLE ABDOMEN

**Liver** appears normal in size and echotexture. No focal lesion is seen. PV and CBD normal. No dilatation of the intrahepatic biliary radicals.

**Gall bladder** is well distended. No evidence of calculus. Wall thickness appears normal. No evidence of periGB collection. No evidence of focal lesion is seen.

**Spleen** appears normal. No focal lesion seen. Splenic vein appears normal.

**Pancreas** appears normal in echopattern. No focal/mass lesion/calcification. No evidence of peripancreatic free fluid or collection. Pancreatic duct appears normal.

**Both the kidneys** appear normal in size, shape and echopattern. Cortical thickness and CM differentiation are maintained. No calculus / hydronephrosis seen on either side.

**Urinary Bladder** is well distended and appears normal. No evidence of any wall thickening or abnormality. No evidence of any intrinsic or extrinsic bladder abnormality detected.

**Uterus** appears normal in size. It shows normal shape & echo pattern. Endometrial echo-complex appears normal and measures 3.8 mm.

**Both ovaries** appear normal in size, shape and echotexture.

No evidence of any adnexal pathology noted.

**Bowel loops and Retroperitoneum** appear normal. Aorta and IVC appear normal. No abnormal lymphadenopathy noted.

#### **IMPRESSION:-**

**No significant abnormality detected.**

#### **Apollo Health and Lifestyle Limited**

(CIN - URS110TG2000PLC115819)

Regd. Office: 1-10-60/62, Ashoka Raghupathi Chambers, 3th Floor, Begumpet, Hyderabad, Telangana - 500 016.

Ph No: 040-4904 7777, Fax No: 4904 7744 | Email ID: enquiry@apollohl.com | www.apollohl.com

APOLLO CLINICS NETWORK MAHARASHTRA

Pune (Aundh | Kharadi | Nigdi Pradhikaran | Viman Nagar | Wanowrie)

Online appointments: www.apolloclinic.com

Patient Name	: Mrs. NAMITA DIXIT	Age	: 34 Y F
UHID	: CVIM.0000230594	OP Visit No	: CVIMOPV563619
Reported on	: 23-09-2023 13:29	Printed on	: 25-09-2023 13:18
Adm/Consult Doctor	:	Ref Doctor	: SELF

(The sonography findings should always be considered in correlation with the clinical and other investigation finding where applicable.) It is only a professional opinion, Not valid for medico legal purpose.

Printed on:23-09-2023 13:29

---End of the Report---

*Preeti*

**Dr. PREETI P KATHE**  
DMRE, MD, DNB  
Radiology



namita 6 - dixit  
@ yahoo . co . in

T-26



<b>Name</b> : Mrs. NAMITA DIXIT	<b>Age</b> : 34 Y	<b>UHID</b> :CVIM.0000230594
<b>Address</b> : PUNE	<b>Sex</b> : F	
<b>Plan</b> : ARCOFEMI MEDIWHEEL FEMALE AHC CREDIT PAN INDIA OP AGREEMENT		<b>OP Number</b> :CVIMOPV563619
		<b>Bill No</b> :CVIM-OCR-59797
		<b>Date</b> : 23.09.2023 10:34

Sno	Service Type/ServiceName	Department
1	ARCOFEMI - MEDIWHEEL - FULL BODY HEALTH ANNUAL PLUS CHECK - FEMALE - 2D ECHO - PAN INDIA - FY2324	
1	URINE GLUCOSE(FASTING)	
2	GAMMA GLUTAMYL TRANSFERASE (GGT)	
3	HbA1c, GLYCATED HEMOGLOBIN	
4	2D ECHO -	
5	LIVER FUNCTION TEST (LFT)	
6	X-RAY CHEST PA	
7	GLUCOSE, FASTING	
8	HEMOGRAM + PERIPHERAL SMEAR	
9	ENT CONSULTATION	
10	FITNESS BY GENERAL PHYSICIAN	
11	GYNAECOLOGY CONSULTATION	
12	DIET CONSULTATION	
13	COMPLETE URINE EXAMINATION	
14	URINE GLUCOSE(POST PRANDIAL) - 2hrs	
15	PERIPHERAL SMEAR	
16	ECG	
17	BLOOD GROUP ABO AND RH FACTOR	
18	LIPID PROFILE	
19	BODY MASS INDEX (BMI)	
20	LFC PAP TEST- PAPSURE	
21	OPHTHAL BY GENERAL PHYSICIAN	
22	RENAL PROFILE/RENAL FUNCTION TEST (RFT/KFT)	
23	ULTRASOUND - WHOLE ABDOMEN	
24	THYROID PROFILE (TOTAL T3, TOTAL T4, TSH)	
25	DENTAL CONSULTATION	
26	GLUCOSE, POST PRANDIAL (PP), 2 HOURS (POST MEAL) - 2hrs	

230594  
34 Years

NAMITA DIXIT (vn)  
Female

23-Sep-23 12:41:48 PM

Rate 80 Sinus rhythm.....normal P axis, V-rate 50-99

PR 163  
QRSD 79  
QT 359  
QTc 415

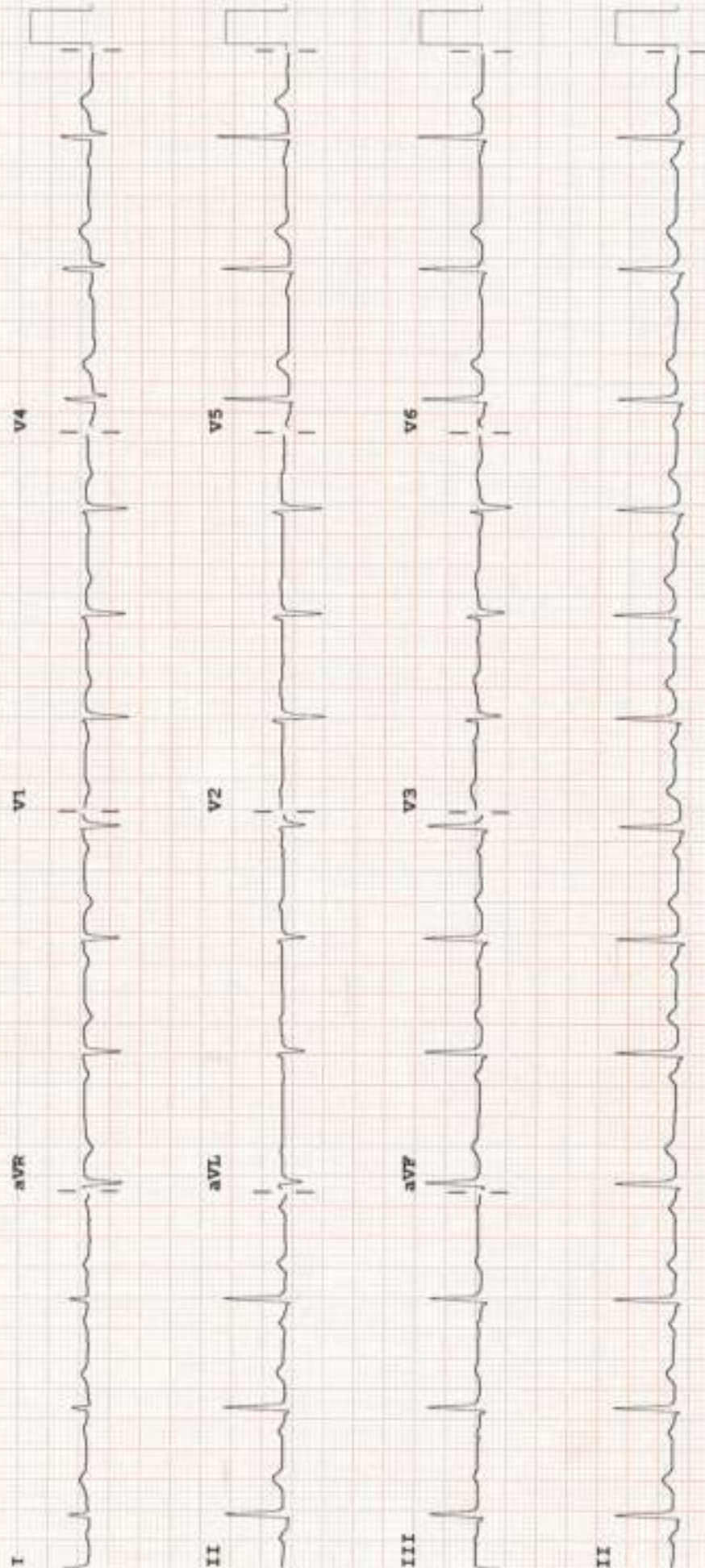
--AXIS--

P 50  
QRS 77  
T 58

12 Lead; Standard Placement

- NORMAL ECG -

Unconfirmed Diagnosis



Device:

Speed: 25 mm/sec Limb: 10 mm/mV Chest: 10.0 mm/mV

F 50- 0,50- 40 Hz W

PH100B CL

P?



NAME : NAMITA DIXIT  
AGE : 34 Y/F

DATE : 23/09/2023

**ECHOCARDIOGRAPHY REPORT**

**MITRAL VALVE** : has thin leaflets, normal subvalvular apparatus. No MR / MS

**AORTIC VALVE** : Thin trileaflets, normal gradients across the valve. No AR/ AS

**PULMONARY VALVE** : normal.

**TRICUSPID VALVE**: normal gradients, No pulmonary hypertension.

**Left Ventricle** : LV is normal in size with normal wall thickness. No regional wall motion abnormality.  
No LV diastolic dysfunction. Good LV systolic function. LVEF 65%.

**Left Atrium** : is normal and free of clots.

**RA/RV** : are normal

**IAS/IVS** : intact.

No clot/veg/ pericardial effusion.

**MEASUREMENTS**

AORTA	:25MM
LEFT ATRIUM	:26 MM
IVSd	:10 MM
PWd	:10 MM
LVIDd	:45MM
LVIDs	: 27 MM
LVEF	: 65 %

**IMPRESSION:**

GOOD LV SYSTOLIC FUNCTION, LVEF 65%  
NO PAH



**DR. PRAMOD NARKHEDE**  
DNB(Medicine), DNB(Cardiology)  
Consultant Interventional Cardiologist  
Apollo clinic, Viman Nagar

**Apollo Health and Lifestyle Limited**

(CIN - U85110TG2000PLC115819)

Regd. Office: 1-10-60/62, Ashoka Raghupathi Chambers, 5th Floor, Begumpet, Hyderabad, Telangana - 500 016.

Ph No: 040-4904 7777, Fax No: 4904 7744 | Email ID: enquiry@apollohl.com | www.apollohl.com

**APOLLO CLINICS NETWORK MAHARASHTRA**

Pune (Aundh) | Kharadi | Nigdi Pradhikaran | Viman Nagar | Wanowrie

Online appointments: www.apolloclinic.com

TO BOOK AN APPOINTMENT

 **1860 500 7788**

# POWER PRESCRIPTION

NAME: M. Srinivas

GENDER: M

DATE: 28/9/23

AGE:

UHID:

## RIGHT EYE

	SPH	CYL	AXIS	VISION
DISTANCE	0.75	0.00	-	6/6
NEAR	_____			

## LEFT EYE

	SPH	CYL	AXIS	VISION
DISTANCE	0.5	0.5	180°	6/6
NEAR	_____			

### INSTRUCTIONS:

D.V. Spect

DR. M. D. ALAVAN  
MBBS, D.O.M.S.  
Consulting Eye Surgeon  
Reg. No. 36319

SIGNATURE



EYE EXAMINATION

DATE: 201 9/23

NAME: NANISA

MO: -

AGE: 30

CORPORATE: As of 2023

	Right Eye	Left Eye
Distant vision	<u>6/6</u>	<u>6/6</u>
Near vision	<u>N/5</u>	<u>N/5</u>
Color vision	<u>Normal</u>	<u>Normal</u>
Fundus examination	<u>Normal</u>	<u>Normal</u>
Intraocular pressure	<u>Normal</u>	<u>Normal</u>
Slit lamp exam.	<u>Normal</u>	<u>Normal</u>

~~As of 2023~~ Ref

Impression - Normal Eye Check Up.

(Ophthalmology)



The Apollo Clinic  
DR. AT. D. ALAVAND  
MBBS. 60303,  
Consulting Eye Surgeon  
Reg. No.: 36319

Namita Sivrit

33yr

Height :	Weight :	BMI :	Waist Circum :
Temp :	Pulse :	Resp :	B.P :

General Examination / Allergies History

23/9/23

6  
Lbc for cytology

Clinical Diagnosis & Management Plan

33yr. P.4 (normal delivery)  
 Cycle 25 day  
 LMP - 19/8/23

Past - nil relevant  
 No familial cancer  
 Alcohol 1/mth  
 O/E - no pain

PIA - SPT  
 NAB

PIs - Cervix  
 NAB



Follow up date:

**DR. SHIVANI JAIN**  
 MS, DNB (OBST & GYNAE)  
 MCh RE. NO. 2022/12/9453  
 Doctor Signature

Mrs Navita Datta

Height :	Weight :	BMI :	Waist Circum :
Temp :	Pulse :	Resp :	B.P :

General Examination / Allergies  
History

Clinical Diagnosis & Management Plan

*[Handwritten signature]*

ENT NASH

ALL ENT  
day surgery

klarylene ea sup 3' (1)

Follow up date:

*[Handwritten signature]*  
Doctor Signature

Date : 23-09-2023  
MR NO : CVIM.0000230594

Department : GENERAL  
Doctor :

Name : Mrs. NAMITA DIXIT

Registration No :

Age/ Gender : 34 Y / Female

Qualification :

Consultation Timing: 10:33

Height : 163	Weight : 59	BMI :	Waist Circum : 86
Temp : 97	Pulse : 80	Resp : 18	B.P : 100/60

General Examination / Allergies History

Clinical Diagnosis & Management Plan

**HOME SAMPLE COLLECTION**  
PH.: 7775870074  
:020-26634331/32/34

No complaints

SYSTEMIC :

. CVS :


. CNS :

. RS :

NAD



**FREE CHECK UP**  
- PHYSIOTHERAPY  
- DENTAL  
- AUDIO (HEARING)  
- OPHTHAL (EYE)

Follow up date:

  
Apollo Clinic Viman Nagar  
DR. CHINMAY NAIK  
MBBS  
Mob.: 989021  
Reg.No.: MCI-13/51948  
Doctor Signature

**Apollo Clinic, Viman Nagar**

Nyati Millenium Premises, Cooperative Society Limited, Shop No. S1 & Stilt Floor,  
Building "C", Viman Nagar, Pin: 411014 | Phone: (020) 2663 4331/32/34

Follow us  /ApolloClinicIndia  /ApolloClinics

BOOK YOUR APPOINTMENT TODAY!  
Whatsapp Number : 970 100 3333  
Toll Number : 1860 500 7788  
Website : www.apolloclinic.com



Patient Name : Mrs.NAMITA DIXIT	Collected : 23/Sep/2023 10:53AM
Age/Gender : 34 Y 3 M 29 D/F	Received : 23/Sep/2023 01:38PM
UHID/MR No : CVIM.0000230594	Reported : 23/Sep/2023 02:39PM
Visit ID : CVIMOPV563619	Status : Final Report
Ref Doctor : Dr.SELF	Sponsor Name : ARCOFEMI HEALTHCARE LIMITED
Emp/Auth/TPA ID : ND088575/-	

**DEPARTMENT OF HAEMATOLOGY**

**ARCOFEMI - MEDIWHEEL - FULL BODY HEALTH ANNUAL PLUS CHECK - FEMALE - 2D ECHO - PAN INDIA - FY2324**

**PERIPHERAL SMEAR , WHOLE BLOOD EDTA**

RBC NORMOCYTIC NORMOCHROMIC  
WBC EOSINOPHILIA  
PLATELETS ARE ADEQUATE ON SMEAR  
NO HEMOPARASITES SEEN





Patient Name : Mrs.NAMITA DIXIT	Collected : 23/Sep/2023 10:53AM
Age/Gender : 34 Y 3 M 29 D/F	Received : 23/Sep/2023 01:38PM
UHID/MR No : CVIM.0000230594	Reported : 23/Sep/2023 03:06PM
Visit ID : CVIMOPV563619	Status : Final Report
Ref Doctor : Dr.SELF	Sponsor Name : ARCOFEMI HEALTHCARE LIMITED
Emp/Auth/TPA ID : ND088575/-	

**DEPARTMENT OF HAEMATOLOGY**

**ARCOFEMI - MEDIWHEEL - FULL BODY HEALTH ANNUAL PLUS CHECK - FEMALE - 2D ECHO - PAN INDIA - FY2324**

Test Name	Result	Unit	Bio. Ref. Range	Method
-----------	--------	------	-----------------	--------

**BLOOD GROUP ABO AND RH FACTOR , WHOLE BLOOD EDTA**

BLOOD GROUP TYPE	B			Microplate Hemagglutination
Rh TYPE	Positive			Microplate Hemagglutination



SIN No:BED230231539







Patient Name : Mrs.NAMITA DIXIT	Collected : 23/Sep/2023 10:53AM
Age/Gender : 34 Y 3 M 29 D/F	Received : 23/Sep/2023 01:38PM
UHID/MR No : CVIM.0000230594	Reported : 23/Sep/2023 03:12PM
Visit ID : CVIMOPV563619	Status : Final Report
Ref Doctor : Dr.SELF	Sponsor Name : ARCOFEMI HEALTHCARE LIMITED
Emp/Auth/TPA ID : ND068575/-	

**DEPARTMENT OF BIOCHEMISTRY**

**ARCOFEMI - MEDIWHEEL - FULL BODY HEALTH ANNUAL PLUS CHECK - FEMALE - 2D ECHO - PAN INDIA - FY2324**

Test Name	Result	Unit	Bio. Ref. Range	Method
HbA1C, GLYCATED HEMOGLOBIN , WHOLE BLOOD EDTA	5.1	%		HPLC
ESTIMATED AVERAGE GLUCOSE (eAG) , WHOLE BLOOD EDTA	100	mg/dL		Calculated

**Comment:**

Reference Range as per American Diabetes Association (ADA) 2023 Guidelines:

REFERENCE GROUP	HbA1C %
NON DIABETIC	<5.7
PREDIABETES	5.7 – 6.4
DIABETES	≥ 6.5
DIABETICS	
EXCELLENT CONTROL	6 – 7
FAIR TO GOOD CONTROL	7 – 8
UNSATISFACTORY CONTROL	8 – 10
POOR CONTROL	>10

**Note:** Dietary preparation or fasting is not required.

- HbA1C is recommended by American Diabetes Association for Diagnosing Diabetes and monitoring Glycemic Control by American Diabetes Association guidelines 2023.
- Trends in HbA1C values is a better indicator of Glycemic control than a single test.
- Low HbA1C in Non-Diabetic patients are associated with Anemia (Iron Deficiency/Hemolytic), Liver Disorders, Chronic Kidney Disease. Clinical Correlation is advised in interpretation of low Values,
- Falsely low HbA1c (below 4%) may be observed in patients with clinical conditions that shorten erythrocyte life span or decrease mean erythrocyte age. HbA1c may not accurately reflect glycemic control when clinical conditions that affect erythrocyte survival are present.
- In cases of Interference of Hemoglobin variants in HbA1C, alternative methods (Fructosamine) estimation is recommended for Glycemic Control
  - A: HbF >25%
  - B: Homozygous Hemoglobinopathy.
 (Hb Electrophoresis is recommended method for detection of Hemoglobinopathy)





Patient Name : Mrs.NAMITA DIXIT	Collected : 23/Sep/2023 10:53AM
Age/Gender : 34 Y 3 M 29 D/F	Received : 23/Sep/2023 01:29PM
UHID/MR No : CVIM.0000230594	Reported : 23/Sep/2023 02:50PM
Visit ID : CVIMOPV563619	Status : Final Report
Ref Doctor : Dr.SELF	Sponsor Name : ARCOFEMI HEALTHCARE LIMITED
Emp/Auth/TPA ID : ND086575/-	

**DEPARTMENT OF BIOCHEMISTRY**

**ARCOFEMI - MEDIWHEEL - FULL BODY HEALTH ANNUAL PLUS CHECK - FEMALE - 2D ECHO - PAN INDIA - FY2324**

Test Name	Result	Unit	Bio. Ref. Range	Method
-----------	--------	------	-----------------	--------





Patient Name : Mrs.NAMITA DIXIT	Collected : 23/Sep/2023 10:53AM
Age/Gender : 34 Y 3 M 29 D/F	Received : 23/Sep/2023 01:29PM
UHID/MR No : CVIM.0000230594	Reported : 23/Sep/2023 02:55PM
Visit ID : CVIMOPV563619	Status : Final Report
Ref Doctor : Dr.SELF	Sponsor Name : ARCOFEMI HEALTHCARE LIMITED
Emp/Auth/TPA ID : ND088575/-	

**DEPARTMENT OF BIOCHEMISTRY**

**ARCOFEMI - MEDIWHEEL - FULL BODY HEALTH ANNUAL PLUS CHECK - FEMALE - 2D ECHO - PAN INDIA - FY2324**

Test Name	Result	Unit	Bio. Ref. Range	Method
-----------	--------	------	-----------------	--------

**LIVER FUNCTION TEST (LFT) , SERUM**

BILIRUBIN, TOTAL	0.72	mg/dL	0.3-1.2	DPD
BILIRUBIN CONJUGATED (DIRECT)	<b>0.20</b>	mg/dL	<0.2	DPD
BILIRUBIN (INDIRECT)	0.52	mg/dL	0.0-1.1	Dual Wavelength
ALANINE AMINOTRANSFERASE (ALT/SGPT)	20.29	U/L	<35	IFCC
ASPARTATE AMINOTRANSFERASE (AST/SGOT)	19.4	U/L	<35	IFCC
ALKALINE PHOSPHATASE	66.30	U/L	30-120	IFCC
PROTEIN, TOTAL	6.76	g/dL	6.6-8.3	Biuret
ALBUMIN	4.16	g/dL	3.5-5.2	BROMO CRESOL GREEN
GLOBULIN	2.60	g/dL	2.0-3.5	Calculated
A/G RATIO	1.6		0.9-2.0	Calculated

**Comment:**

LFT results reflect different aspects of the health of the liver, i.e., hepatocyte integrity (AST & ALT), synthesis and secretion of bile (Bilirubin, ALP), cholestasis (ALP, GGT), protein synthesis (Albumin)

Common patterns seen:

**1. Hepatocellular Injury:**

- AST – Elevated levels can be seen. However, it is not specific to liver and can be raised in cardiac and skeletal injuries.
- ALT – Elevated levels indicate hepatocellular damage. It is considered to be most specific lab test for hepatocellular injury. Values also correlate well with increasing BMI.
- Disproportionate increase in AST, ALT compared with ALP.
- Bilirubin may be elevated.
- AST: ALT (ratio) – In case of hepatocellular injury AST: ALT > 1 In Alcoholic Liver Disease AST: ALT usually >2. This ratio is also seen to be increased in NAFLD, Wilson's diseases, Cirrhosis, but the increase is usually not >2.

**2. Cholestatic Pattern:**

- ALP – Disproportionate increase in ALP compared with AST, ALT.
- Bilirubin may be elevated.
- ALP elevation also seen in pregnancy, impacted by age and sex.
- To establish the hepatic origin correlation with GGT helps. If GGT elevated indicates hepatic cause of increased ALP.

**3. Synthetic function impairment:**

- Albumin- Liver disease reduces albumin levels.
- Correlation with PT (Prothrombin Time) helps.



Patient Name	: Mrs.NAMITA DIXIT	Collected	: 23/Sep/2023 10:53AM
Age/Gender	: 34 Y 3 M 29 D/F	Received	: 23/Sep/2023 01:29PM
UHID/MR No	: CVIM.0000230594	Reported	: 23/Sep/2023 02:55PM
Visit ID	: CVIMOPV563619	Status	: Final Report
Ref Doctor	: Dr.SELF	Sponsor Name	: ARCOFEMI HEALTHCARE LIMITED
Emp/Auth/TPA ID	: ND088575/-		

**DEPARTMENT OF BIOCHEMISTRY**

**ARCOFEMI - MEDIWHEEL - FULL BODY HEALTH ANNUAL PLUS CHECK - FEMALE - 2D ECHO - PAN INDIA - FY2324**

Test Name	Result	Unit	Bio. Ref. Range	Method



Patient Name : Mrs.NAMITA DIXIT	Collected : 23/Sep/2023 10:53AM
Age/Gender : 34 Y 3 M 29 D/F	Received : 23/Sep/2023 01:29PM
UHID/MR No : CVIM.0000230594	Reported : 23/Sep/2023 02:55PM
Visit ID : CVIMOPV563619	Status : Final Report
Ref Doctor : Dr.SELF	Sponsor Name : ARCOFEMI HEALTHCARE LIMITED
Emp/Auth/TPA ID : ND088575/-	

DEPARTMENT OF BIOCHEMISTRY

ARCOFEMI - MEDIWHEEL - FULL BODY HEALTH ANNUAL PLUS CHECK - FEMALE - 2D ECHO - PAN INDIA - FY2324

Test Name	Result	Unit	Bio. Ref. Range	Method
-----------	--------	------	-----------------	--------

RENAL PROFILE/KIDNEY FUNCTION TEST (RFT/KFT) , SERUM

CREATININE	0.59	mg/dL	0.55-1.02	Modified Jaffe, Kinetic
UREA	<b>14.45</b>	mg/dL	17-43	GLDH, Kinetic Assay
BLOOD UREA NITROGEN	<b>6.8</b>	mg/dL	8.0 - 23.0	Calculated
URIC ACID	3.14	mg/dL	2.6-6.0	Uricase PAP
CALCIUM	9.19	mg/dL	8.8-10.6	Arsenazo III
PHOSPHORUS, INORGANIC	3.36	mg/dL	2.5-4.5	Phosphomolybdate Complex
SODIUM	142.06	mmol/L	136-146	ISE (Indirect)
POTASSIUM	4.4	mmol/L	3.5-5.1	ISE (Indirect)
CHLORIDE	107.15	mmol/L	101-109	ISE (Indirect)



Patient Name : Mrs.NAMITA DIXIT	Collected : 23/Sep/2023 10:53AM
Age/Gender : 34 Y 3 M 29 D/F	Received : 23/Sep/2023 01:29PM
UHID/MR No : CVIM.0000230594	Reported : 23/Sep/2023 02:50PM
Visit ID : CVIMOPV563619	Status : Final Report
Ref Doctor : Dr.SELF	Sponsor Name : ARCOFEMI HEALTHCARE LIMITED
Emp/Auth/TPA ID : ND088575/-	

DEPARTMENT OF BIOCHEMISTRY

ARCOFEMI - MEDIWHEEL - FULL BODY HEALTH ANNUAL PLUS CHECK - FEMALE - 2D ECHO - PAN INDIA - FY2324

Test Name	Result	Unit	Bio. Ref. Range	Method
GAMMA GLUTAMYL TRANSPEPTIDASE (GGT) , SERUM	16.12	U/L	<38	IFCC



SIN No:SE04490684





Patient Name : Mrs.NAMITA DIXIT  
 Age/Gender : 34 Y 3 M 29 D/F  
 UHID/MR No : CVIM.0000230594  
 Visit ID : CVIMOPV563619  
 Ref Doctor : Dr.SELF  
 Emp/Auth/TPA ID : ND088575/-

Collected : 23/Sep/2023 10:53AM  
 Received : 23/Sep/2023 01:27PM  
 Reported : 23/Sep/2023 02:44PM  
 Status : Final Report  
 Sponsor Name : ARCOFEMI HEALTHCARE LIMITED

**DEPARTMENT OF IMMUNOLOGY**

**ARCOFEMI - MEDIWHEEL - FULL BODY HEALTH ANNUAL PLUS CHECK - FEMALE - 2D ECHO - PAN INDIA - FY2324**

Test Name	Result	Unit	Bio. Ref. Range	Method



Patient Name : Mrs.NAMITA DIXIT	Collected : 23/Sep/2023 10:53AM
Age/Gender : 34 Y 3 M 29 D/F	Received : 23/Sep/2023 03:34PM
UHID/MR No : CVIM.0000230594	Reported : 23/Sep/2023 04:39PM
Visit ID : CVIMOPV563619	Status : Final Report
Ref Doctor : Dr.SELF	Sponsor Name : ARCOFEMI HEALTHCARE LIMITED
Emp/Auth/TPA ID : ND088575/-	

**DEPARTMENT OF CLINICAL PATHOLOGY**

**ARCOFEMI - MEDIWHEEL - FULL BODY HEALTH ANNUAL PLUS CHECK - FEMALE - 2D ECHO - PAN INDIA - FY2324**

Test Name	Result	Unit	Bio. Ref. Range	Method
-----------	--------	------	-----------------	--------

**COMPLETE URINE EXAMINATION (CUE) , URINE**

**PHYSICAL EXAMINATION**

COLOUR	PALE YELLOW		PALE YELLOW	Visual
TRANSPARENCY	HAZY		CLEAR	Visual
pH	5.5		5-7.5	DOUBLE INDICATOR
SP. GRAVITY	1.010		1.002-1.030	Bromothymol Blue

**BIOCHEMICAL EXAMINATION**

URINE PROTEIN	NEGATIVE		NEGATIVE	PROTEIN ERROR OF INDICATOR
GLUCOSE	NEGATIVE		NEGATIVE	GLUCOSE OXIDASE
URINE BILIRUBIN	NEGATIVE		NEGATIVE	AZO COUPLING REACTION
URINE KETONES (RANDOM)	NEGATIVE		NEGATIVE	SODIUM NITRO PRUSSIDE
UROBILINOGEN	NORMAL		NORMAL	MODIFIED EHRlich REACTION
BLOOD	POSITIVE +		NEGATIVE	Peroxidase
NITRITE	NEGATIVE		NEGATIVE	Diazotization
LEUCOCYTE ESTERASE	TRACE		NEGATIVE	LEUCOCYTE ESTERASE

**CENTRIFUGED SEDIMENT WET MOUNT AND MICROSCOPY**

PUS CELLS	4 - 5	/hpf	0-5	Microscopy
EPITHELIAL CELLS	2 - 3	/hpf	<10	MICROSCOPY
RBC	1 - 2	/hpf	0-2	MICROSCOPY
CASTS	NIL		0-2 Hyaline Cast	MICROSCOPY
CRYSTALS	ABSENT		ABSENT	MICROSCOPY





