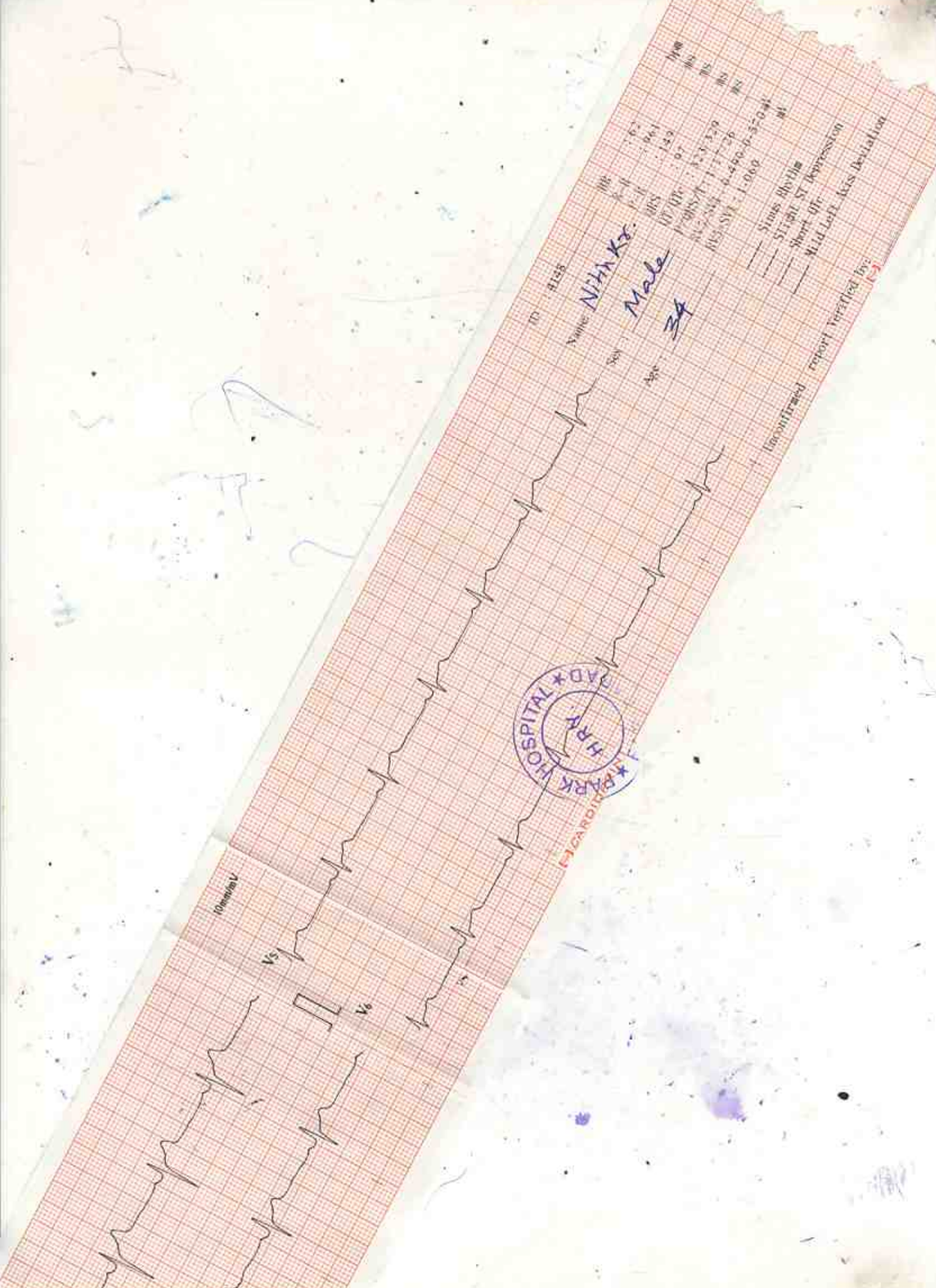

ID: 8125

Name: NITHA KT.

Sex: Male

Age: 34

HR: 34

PR: 160

QT: 370

QTc: 370

QTd: 370

QTST: 0.400

QTSTc: 1.000

QTSTc: 1.000

QTSTc: 1.000

QTSTc: 1.000

QTSTc: 1.000

QTSTc: 1.000

QTSTc: 1.000

QTSTc: 1.000

Unconfirmed report verified by: (S)

10mm/mV

V5

V6



ECHO REPORT

Name of the patient: Mr. Nitin Kumar Age: 34 Sex: Male Female

UHID No: 2337 IPD No: _____ Date: 11/3/22

Refer By Doctor: DR R. Arora

LVEF% 60%

2D ECHO

> Mitral Valve Normal Pulmonary Valve NI Pulm

> Artery NI

> Aortic aive NI Tricuspid valve NI

2D RWMA

> NO RWMA (Regional wall motion abnormality) at rest

COLD DOPPLER

> NO Significant Vavular stenosis / Regurgiation

COMMENTS AND SUMMARY

> All cardiac chambers of NI size and shape NO dilatation or hypertrophy.

> NO RWMA (Regional wall motion abnormality) at rest

> NO Cloth / Vegetation / pericardial effusion

> LV 60% Systolic function

> NO Significant Vavular stenosis / Regurgiation

Final Impression

> EF at Rest 60%

COMMENTS 2DECHO & Color Doppler study with

Dr. Rakesh Kumar Arora
MBBS, MD, DM (Cardiology)
Reg No DMC - 18395
Consultant Cardiology
Park Hospital, Faridkot
Doctor Name : Dr.
Date



Signature :
Time :



DEPARTMENT OF RADIOLOGY

| | | | | |
|--------------|---------------------------------|-------------------|------------------|----------|
| Patient Name | Mr NITIN KUMAR | Billed Date | : 11/03/2023 | 10.11 AM |
| Reg No | 23372 | Reported Date | : 11/03/2023 | |
| Age/Sex | 34 Years 2 Months 11Days / Male | Req. No. | : 23001250 | |
| Type | OPD | Consultant Doctor | : Dr. CONSULTANT | |

X-RAY CHEST AP/PA

Bilateral lungs appears normal.

No focal lung lesion seen.

Both hila are normal in size, have equal density and bear normal relationship.

The heart and trachea are central in position and no mediastinal abnormality is visible.

The cardiac size is normal for patient age and view.

The domes of the diaphragms are normal in position, and show smooth outline.

To be correlated clinically



DR BINOD KR CHAUDHARY
MBBS, MD
CONSULTANT RADIOLOGIST

(This is only professional opinion and not the diagnosis, Please correlate clinically)

J-Block, Sector-10, Near Court, Faridabad - 121004, Haryana

Tel.: 0129-4200000 E-mail : parkfaridabad@gmail.com

PARK GROUP OF HOSPITALS : West Delhi • South Delhi • Gurgaon • Karnal • Panipat • Hodal • Ambala • Behror



DEPARTMENT OF RADIOLOGY

| | | | | |
|--------------|----------------------------------|-------------------|------------------|----------|
| Patient Name | Mr NITIN KUMAR | Billed Date | : 11/03/2023 | 10.11 AM |
| Reg No | 23372 | Reported Date | : 11/03/2023 | |
| Age/Sex | 34 Years 2 Months 11Days / Male. | Req. No. | : 23001250 | |
| Type | OPD | Consultant Doctor | : Dr. CONSULTANT | |

USG WHOLE ABDOMEN

LIVER : The liver is normal in size, shape and echotexture.No evidence of any focal lesion. IHBR is NOT dilated. Portal vein is normal.

GALL BLADDER :The gall bladder is well distended.No evidence any calculus or mass seen. GB wall thickness with in normal limits. No evidence of pericholecystic fluid is seen. The common bile duct is normal in caliber.

SPLEEN :The spleen is normal in size and shape. Its echotexture is homogeneous.No evidence of focal lesion is noted. Splenic vein is normal.

PANCREAS :The pancreas is normal in size, shape, contours and echotexture.

BILATERAL KIDNEYS : The bilateral kidneys are normal in size and echotexture. Cortico-medullary differentiation is maintained. There is no evidence of obvious calculus or hydronephrosis seen.

URINARY BLADDER :The urinary bladder is well distended.Wall thickness within normal limits.No evidence of calculus is seen.No evidence of mass or diverticulum is noted.

PROSTATE Prostate appears normal in size, shape and echotexture.

No free fluid is seen in peritoneal cavity.

No evidence of obvious retroperitoneal or mesentric lymphadenopathy is seen.

IMPRESSION : - USG WHOLE ABDOMEN REVEALS NO OBVIOUS ABNORMALITY.

TO BE CORRELATED CLINICALLY.


DR BINOD K K CHAUDHARY
MBBS,MD
CONSULTANT RADIOLOGIST

(This is only professional opinion and not the diagnosis, Please correlate clinically)

J-Block, Sector-10, Near Court, Faridabad - 121004, Haryana

Tel.: 0129-4200000 E-mail : parkfaridabad@gmail.com

PARK GROUP OF HOSPITALS : West Delhi • South Delhi • Gurgaon • Karnal • Panipat • Hodal • Ambala • Behror



12

DEPARTMENT OF HAEMATOLOGY

Patient Name : Mr. NITIN KUMAR

MR No : 23372

Age/Sex : 34 Years 2 Months 11 Days / Male

Type : OPD

TPA/Corporate : MEDIWHEEL

Bill Date : 11/03/2023

Reporting Date : 13/03/2023

Sample ID : 943

Bill/Req. No. : 23001250

Ref Doctor : Dr. CONSULTANT

| Test | Result | Bio. Ref. Interval | Units |
|---------------------------------|--------|--------------------|-------|
| GLYCOSYLATED HAEMOGLOBIN | | | |
| GLYCOSYLATED HAEMOGLOBIN | 6.3 | 0 - 6.5 | % |

Note : *Done on DCA Vantage

*Results of these tests should always be interpreted in conjunction with patients medical history, clinical presentation and other findings.

*The results of HbA1c are not influenced by recent meals , physical activity or emotional stress.

***** END OF THE REPORT *****

OUT SOURCE
PARK HOSPITAL
GGN



Dr. VAISHALI YADAV
PATHOLOGIST

Dr. PARDIP KUMAR
MICROBIOLOGIST & ICO

S.C.GAUR
LAB INCHARGE

USER NM SAMAY

(This is only professional opinion and not the diagnosis, Please correlate clinically)

J-Block, Sector-10, Near Court, Faridabad - 121004, Haryana

Tel.: 0129-4200000 E-mail : parkfaridabad@gmail.com

PARK GROUP OF HOSPITALS : West Delhi • South Delhi • Gurgaon • Karnal • Panipat • Hodal • Ambala • Behror



DEPARTMENT OF SEROLOGY

Patient Name : Mr. NITIN KUMAR

MR No : 23372

Age/Sex : 34 Years 2 Months 11 Days / Male

Type : OPD

TPA/Corporate : MEDIWHEEL

Bill Date : 11/03/2023

Reporting Date : 13/03/2023

Sample ID : 943

Bill/Req. No. : 23001250

Ref Doctor : Dr. CONSULTANT

| Test | Result | Bio. Ref. Interval | Units |
|------|--------|--------------------|-------|
|------|--------|--------------------|-------|

PSA - TOTAL (PROSTATIC SPECIFIC ANTIGEN) - CANCER MARKER

| | | | |
|--------------------------------|------|------------|-------|
| PROSTATE SPECIFIC ANTIGEN(PSA) | 0.69 | 0.57 - 4.0 | ng/ml |
|--------------------------------|------|------------|-------|

Method : chemiluminescent immunoassay

Note : Clinical Use: -


An aid in the early detection of Prostate cancer in Male. Follow up and management of Prostate cancer patients. Detect metastatic or persistent disease in patients following surgical or medical treatment of Prostate cancer

Note: -

False negative / positive results are observed in patients receiving mouse monoclonal antibodies for diagnosis or therapy. PSA levels may appear consistently elevated / depressed due to the interference by heterophilic antibodies & non-specific protein binding. PSA values regardless of levels should not be interpreted as absolute evidence of the presence or absence of disease. All values should be correlated with clinical findings and results of other investigations.

***** END OF THE REPORT *****

OUT SOURCE
PARK HOSPITAL
GGN



Dr. VAISHALI YADAV
PATHOLOGIST

Dr. PARDIP KUMAR
MICROBIOLOGIST & ICO

S.C. GAUR
LAB INCHARGE

USER NM SAMAY

(This is only professional opinion and not the diagnosis, Please correlate clinically)

J-Block, Sector-10, Near Court, Faridabad - 121004, Haryana

Tel.: 0129-4200000 E-mail : parkfaridabad@gmail.com

PARK GROUP OF HOSPITALS : West Delhi • South Delhi • Gurgaon • Karnal • Panipat • Hodal • Ambala • Behror



DEPARTMENT OF PATHOLOGY

Patient Name : Mr. NITIN KUMAR

MR No : 23372

Age/Sex : 34 Years 2 Months 11 Days / Male

Type : OPD

TPA/Corporate : MEDIWHEEL

Bill Date : 11/03/2023

Reporting Date : 11/03/2023

Sample ID : 933

Bill/Req. No. : 23001250

Ref Doctor : Dr.CONSULTANT

| Test | Result | Blo. Ref. Interval | Units |
|------------------------------|-------------|--------------------|-------------------|
| CBC | | | |
| HAEMOGLOBIN | 14.8 | 12 - 16 | gm/dL |
| PACKED CELL VOLUME | 47.1 | 35.0 - 50.0 | % |
| RED BLOOD CELL COUNT | 5.17 | 3.5 - 5.5 | millions/ μ L |
| MEAN CORPUSCULAR VOLUME | 91.1 | 83 - 101 | fL |
| MEAN CORPUSCULAR HAEMOGLOBIN | 28.6 | 27 - 31 | Picograms |
| MEAN CORPUSCULAR HB CONC | 31.4 | 33 - 37 | g/dl |
| RDW | 13.1 | 11.6 - 14.5 | % |
| TOTAL LEUCOCYTE COUNT | 5940 | 4000-11000 | / μ L |
| DIFFERENTIAL COUNT | | | |
| NEUTROPHILS | 63 | 40.0 - 80.0 | % |
| LYMPHOCYTES | 31 | 20.0 - 40.0 | % |
| MONOCYTES | 04 | 2.0 - 10.0 | % |
| EOSINOPHILS | 02 | 0.0 - 5.0 | % |
| BASOPHILS | 00 | 0.0 - 2.0 | % |
| PLATELET COUNT | 1.55 | 1.50 - 4.50 | Thousand/ μ L |

***** END OF THE REPORT *****

PARK HOSPITAL

 Sample no.
 Dr. VAISHALI YADAV
 PATHOLOGIST

Dr. PARDIP KUMAR
 MICROBIOLOGIST & ICO

S.C.GAUR
 LAB INCHARGE

USER NM PRIYANKA

(This is only professional opinion and not the diagnosis, Please correlate clinically)*

J-Block, Sector-10, Near Court, Faridabad - 121004, Haryana

Tel.: 0129-4200000 E-mail : parkfaridabad@gmail.com

PARK GROUP OF HOSPITALS : West Delhi • South Delhi • Gurgaon • Karnal • Panipat • Hodal • Ambala • Behror



DEPARTMENT OF PATHOLOGY

Patient Name : Mr. NITIN KUMAR

MR No : 23372

Age/Sex : 34 Years 2 Months 11 Days / Male

Type : OPD

TPA/Corporate : MEDIWHEEL

Bill Date : 11/03/2023

Reporting Date : 11/03/2023

Sample ID : 933

Bill/Req. No. : 23001250

Ref Doctor : Dr. CONSULTANT

| Test | Result | Bio. Ref. Interval | Units |
|----------------------------|----------------|--------------------|--------|
| KFT (RENAL PROFILE) | | | |
| KFT | | | |
| SERUM UREA | 22.9 | 10 - 45 | mg/dL |
| SERUM CREATININE | 0.99 | 0.4 - 1.4 | mg/dL |
| SERUM URIC ACID | 5.5 | 2.5 - 7.0 | mg/dL |
| SERUM SODIUM | 135.4 L | 136 - 148 | mmol/L |
| SERUM POTASSIUM | 4.7 | 3.5 - 5.5 | meq/l |
| CHLORIDE | 97.0 | 96 - 106 | meq/l |

***** END OF THE REPORT *****



Dr. VAISHALI YADAV
PATHOLOGIST

Dr. PARDIP KUMAR
MICROBIOLOGIST & ICO

S.C. GAUR
LAB INCHARGE

USER NM PRIYANKA

(This is only professional opinion and not the diagnosis, Please correlate clinically)

J-Block, Sector-10, Near Court, Faridabad - 121004, Haryana

Tel.: 0129-4200000 E-mail : parkfaridabad@gmail.com

PARK GROUP OF HOSPITALS : West Delhi • South Delhi • Gurgaon • Karnal • Panipat • Hodal • Ambala • Behror



DEPARTMENT OF PATHOLOGY

Patient Name : Mr. NITIN KUMAR
 MR No : 23372
 Age/Sex : 34 Years 2 Months 11 Days / Male
 Type : OPD
 TPA/Corporate : MEDIWHEEL

Bill Date : 11/03/2023
 Reporting Date : 11/03/2023
 Sample ID : 933
 Bill/Req. No. : 23001250
 Ref Doctor : Dr. CONSULTANT

| Test | Result | Bio. Ref. Interval | Units |
|----------------------------------|--------|--------------------|-------|
| LFT (LIVER FUNCTION TEST) | | | |
| LFT | | | |
| TOTAL BILIRUBIN | 0.5 | 0 - 1.2 | mg/dL |
| DIRECT BILIRUBIN | 0.3 | 0 - 0.4 | mg/dL |
| INDIRECT BILIRUBIN | 0.2 | 0.10 - 0.6 | mg/dL |
| SGOT (AST) | 32.6 | 0 - 45 | U/L |
| SGPT (ALT) | 41.7 | 0 - 45 | U/L |
| ALKALINE PHOSPHATASE | 87.0 | 30 - 170 | IU/L |
| TOTAL PROTEINS | 7.1 | 6.4 - 8.0 | g/dL |
| ALBUMIN | 4.1 | 3.3 - 5.5 | g/dL |
| GLOBULIN | 3 | 2.3 - 4.5 | g/dL |
| A/G RATIO | 1.37 | 1.1 - 2.2 | |

***** END OF THE REPORT *****



Dr. VAISHALI YADAV
PATHOLOGIST

Dr. PARDIP KUMAR
MICROBIOLOGIST & ICO

S.C.GAUR
LAB INCHARGE

USER NM PRIYANKA

(This is only professional opinion and not the diagnosis, Please correlate clinically)

J-Block, Sector-10, Near Court, Faridabad - 121004, Haryana
 Tel.: 0129-4200000 E-mail : parkfaridabad@gmail.com

PARK GROUP OF HOSPITALS : West Delhi • South Delhi • Gurgaon • Karnal • Panipat • Hodal • Ambala • Behror



DEPARTMENT OF BIOCHEMISTRY

Patient Name : Mr. NITIN KUMAR

MR No : 23372

Age/Sex : 34 Years 2 Months 11 Days / Male

Type : OPD

TPA/Corporate : MEDIWHEEL

Bill Date : 11/03/2023

Reporting Date : 11/03/2023

Sample ID : 933

Bill/Req. No. : 23001250

Ref Doctor : Dr. CONSULTANT

| Test | Result | Bio. Ref. Interval | Units |
|-----------------------------|--------|--------------------|-------|
| LIPID PROFILE | | | |
| LIPID PROFILE | | | |
| TOTAL CHOLESTEROL | 160.42 | 0 - 250 | mg/dL |
| SERUM TRIGLYCERIDES | 60.22 | 60 - 165 | mg/dl |
| HDL-CHOLESTEROL | 40.78 | 30 - 70 | mg/dl |
| VLDL CHOLESTEROL | 12.04 | 6 - 32 | mg/dL |
| LDL | 107.8 | 50 - 135 | mg/dl |
| LDL CHOLESTEROL/HDL RATIO | 2.64 | 1.0 - 3.0 | mg/dL |
| TOTAL CHOLESTEROL/HDL RATIO | 3.93 | 2.0 - 5.0 | mg/dl |

***** END OF THE REPORT *****



Dr. VAISHALI YADAV
PATHOLOGIST

Dr. PARDIP KUMAR
MICROBIOLOGIST & ICO

S.C.GAUR
LAB INCHARGE

USER NM PRIYANKA

(This is only professional opinion and not the diagnosis, Please correlate clinically)

J-Block, Sector-10, Near Court, Faridabad - 121004, Haryana

Tel.: 0129-4200000 E-mail : parkfaridabad@gmail.com

PARK GROUP OF HOSPITALS : West Delhi • South Delhi • Gurgaon • Karnal • Panipat • Hodal • Ambala • Behror



DEPARTMENT OF PATHOLOGY

Patient Name : Mr. NITIN KUMAR

MR No : 23372

Age/Sex : 34 Years 2 Months 11 Days / Male

Type : OPD

TPA/Corporate : MEDIWHEEL

Bill Date : 11/03/2023

Reporting Date : 11/03/2023

Sample ID : 933

Bill/Req. No. : 23001250

Ref Doctor : Dr.CONSULTANT

| Test | Result | Bio. Ref. Interv. | Units |
|----------------------------|--------|-------------------|-------|
| BLOOD SUGAR FASTING | | | |
| PLASMA GLUCOSE FASTING | 87.09 | 60 - 110 | mg/dl |

***** END OF THE REPORT *****



Dr. VAISHALI YADAV
PATHOLOGIST

Dr. PARDIP KUMAR
MICROBIOLOGIST & ICO

S.C.GAUR
LAB INCHARGE

USER NM PRIYANKA

(This is only professional opinion and not the diagnosis, Please correlate clinically)

J-Block, Sector-10, Near Court, Faridabad - 121004, Haryana

Tel.: 0129-4200000 E-mail : parkfaridabad@gmail.com

PARK GROUP OF HOSPITALS : West Delhi • South Delhi • Gurgaon • Karnal • Panipat • Hodal • Ambala • Behror



DEPARTMENT OF HAEMATOLOGY

Patient Name : Mr. NITIN KUMAR

MR No : 23372

Age/Sex : 34 Years 2 Months 11 Days / Male

Type : OPD

TPA/Corporate : MEDIWHEEL

Bill Date : 11/03/2023

Reporting Date : 11/03/2023

Sample ID : 933

Bill/Req. No. : 23001250

Ref Doctor : Dr.CONSULTANT

| Test | Result | Bio. Ref. Interval | Units |
|------|--------|--------------------|-------|
|------|--------|--------------------|-------|

BLOOD GROUPING AND RH FACTOR

| | | | |
|-------------|-------------------|--|--|
| BLOOD GROUP | * B * RH POSITIVE | | |
|-------------|-------------------|--|--|

***** END OF THE REPORT *****



Dr. VAISHALI YADAV
PATHOLOGIST

Dr. PARDIP KUMAR
MICROBIOLOGIST & ICO

S.C.GAUR
LAB INCHARGE

USER NM PRIYANKA

(This is only professional opinion and not the diagnosis, Please correlate clinically) *

J-Block, Sector-10, Near Court, Faridabad - 121004, Haryana

Tel.: 0129-4200000 E-mail : parkfaridabad@gmail.com

PARK GROUP OF HOSPITALS : West Delhi • South Delhi • Gurgaon • Karnal • Panipat • Hodal • Ambala • Behror



Name : Mr.NITIN KUMAR 23001250 78
 Age/Gender : 34 Y(s) /Male
 Reg No : 1103233222
 Lab ID No : KP0198351
 Sample ID : 220200015
 Sample Type : Serum

Location : KPL A43
 Registered On : 11-03-2023 17:58
 Reported On : 11-03-2023 20:43
 Referred By : PARK HOSPITAL
 Client Name : PARK HOSPITAL SARITA
 Reference No :



| Test | Result | Unit | Reference Range |
|----------------------------|---------|--------|-----------------|
| T3 <i>Method: CLIA</i> | : 1.95 | nmo/L | 0.92 - 2.79 |
| T4 <i>Method: CLIA</i> | : 95.26 | nmo/L | 59.0 - 135.0 |
| TSH <i>Method: CLIA</i> | : 3.1 | uIU/mL | 0.35 - 5.5 |

Reference Range for Children

1-4 days : 1.00-39.00
 5 days-5 months : 1.7 - 9.1
 5 months - 20 years : 0.70 - 6.40

- (1) 4.2 to 15 μ U/mL - Correlate clinically as physiological and other factors may falsely elevate TSH levels.
- (2) TSH Values may be transiently altered because of non-thyroidal illness.
- (3) Some drugs may decrease TSH values, e.g., L-dopa, Glucocorticoids.
- (4) Some drugs may increase TSH values, e.g., Iodine, Lithium, and Amiodarone. Abbreviations.

**** End Of The Report ****



Dr.Sherry Khanna
 D.N.B. (Pathology)
 Head-Lab Operations.
 BMC Reg.No-25315

(This is only professional opinion and not the diagnosis, please correlate clinically)

J-Block, Sector-10, Near Court, Faridabad - 121004, Haryana

Print Date : 11-03-2023 23:43

Tel.: 0129-4200000 E-mail: parkfaridabad@gmail.com

PARK GROUP OF HOSPITALS : West Delhi • South Delhi • Gurgaon • Karnal • Panipat • Hodal • Ambala • Behror

the health care providers

the health care providers



DEPARTMENT OF PATHOLOGY

Patient Name : Mr. NITIN KUMAR

MR No : 23372

Age/Sex : 34 Years 2 Months 11 Days / Male

Type : OPD

TPA/Corporate : MEDIWHEEL

Bill Date : 11/03/2023

Reporting Date : 11/03/2023

Sample ID : 943

Bill/Req. No. : 23001250

Ref Doctor : Dr. CONSULTANT

| Test | Result | Bio. Ref. Interval | Units |
|------|--------|--------------------|-------|
|------|--------|--------------------|-------|

URINE ROUTINE AND MICROSCOPY

PHYSICAL CHARACTERISTICS

| | | | |
|------------------|-------------|-----------------|----|
| QUANTITY | 40ml | 5 - 100 | ml |
| COLOUR | Pale Yellow | Pale Yellow | |
| TURBIDITY | Clear | clear | |
| SPECIFIC GRAVITY | 1.20 | 1.000-1.030 | |
| PH | Acidic | Acidic/Alkaline | |

CHEMICAL EXAMINATION-1

| | | | |
|---------------|-----|----------|-------|
| URINE PROTEIN | NIL | NIL | mg/dl |
| GLUCOSE | NIL | 25 - 500 | mg/dL |

MICRO. EXAMINATION

| | | | |
|------------------|----------|-----|-----------|
| PUS CELL | 1-2 /hpf | 0-5 | cells/hpf |
| RED BLOOD CELLS | NIL | 0-2 | cells/hpf |
| EPITHELIAL CELLS | 1-2 | 0-5 | cells/hpf |
| CASTS | NIL | NIL | /lpf |
| CRYSTALS | NIL | NIL | /hpf |

***** END OF THE REPORT *****



Sample no.

Dr. VAISHALI YADAV
PATHOLOGIST

Dr. PARDIP KUMAR
MICROBIOLOGIST & ICO

S.C. GAUR
LAB INCHARGE

USER NM SEHDEV



(This is only professional opinion and not the diagnosis, Please correlate clinically)

J-Block, Sector-10, Near Court, Faridabad - 121004, Haryana

Tel.: 0129-4200000 E-mail : parkfaridabad@gmail.com



DEPARTMENT OF PATHOLOGY

Patient Name : Mr. NITIN KUMAR
 MR No : 23372
 Age/Sex : 34 Years 2 Months 11 Days / Male
 Type : OPD
 TPA/Corporate : MEDIWHEEL

Bill Date : 11/03/2023
 Reporting Date : 12/03/2023
 Sample ID : 943
 Bill/Req. No. : 23001250
 Ref Doctor : Dr. CONSULTANT

| Test | Result | Bio. Ref. Interval | Units |
|------|--------|--------------------|-------|
|------|--------|--------------------|-------|

STOOL ROUTINE AND MICROSCOPY

STOOL ROUTINE AND MICROSCOPY

| | | | |
|--------------|------------|--------|-----------|
| COLOUR | BROWNISH | | |
| CONSISTENCY | Semi Solid | Formed | |
| OCCULT BLOOD | NIL | NIL | |
| MUCUS | NIL | NIL | |
| WUS CELL | 1-2 /HPF | 0-5 | cells/hpf |
| CYSTS | NIL | NIL | |
| OVA | NIL | Nil | |
| FAT GLOBULE | NIL | Nil | |
| PARASITES | NIL | Nil | |

***** END OF THE REPORT *****



Sample no.

Dr. VAISHALI YADAV
PATHOLOGIST

Dr. PARDIP KUMAR
MICROBIOLOGIST & ICO



USER NM SUNIL

(This is only professional opinion and not the diagnosis, Please correlate clinically)

J-Block, Sector-10, Near Court, Faridabad - 121004, Haryana

Tel.: 0129-4200000 E-mail : parkfaridabad@gmail.com

PARK GROUP OF HOSPITALS : West Delhi • South Delhi • Gurgaon • Karnal • Panipat • Hodal • Ambala • Behror