



PARKLINE DIAGNOSTICS PVT. LTD.

L.G. 3, 4 & 5, Bhuvana Towers, S.D. Road, Secunderabad - 500 003.

Tel : +91 40-2784 5852, 6649 1787, 7995421787, 7093445852, Fax : +91 40 2784 7864

Email parklinediagnostics@gmail.com www.parklinediagnostics.com



NABL Accredited
Certificate No.MC-2566

MEDICAL EXAMINATION REPORT

Name	Mr. Prabala Subbarao	Date :	12/03/2022
Company	CVI Mediwheel	Reg. No. :	1869005
Contact No.	9705631034	Sex	<input checked="" type="checkbox"/> M <input type="checkbox"/> F
		Age :	53
Type	Pre-Emp	Emp. No.:	56252
	Overseas	Height	173
	Annual <input checked="" type="checkbox"/>	Weight	75
Remarks	<p>A k/c/o: Bronchial Asthma ⊕ on medication. Continue the same medication.</p> <p>- Routine cholesterolemia ⊕. Advice follow up.</p> <p>- Usg - Grade I fatty liver. Advice follow up.</p> <p>- Rest all physical, lab parameters were.</p> <p>DR. PRIYANKA SANNIDHI MBBS Regn. No: 11351</p>		
Fitness Status	Medically Fit / Unfit	- Physician's Signature	

Distant Vision : Near Vision :

Right Eye: 6/12 - 1.5 sph 6/6

With glasses / Without glasses

left Eye : 6/12 - 1.50 sph 6/6

with glasses / without glasses

Colour Vision : DE normal

Right Ear

Hearing :

(N)

Rinee's Test ;

Weber Test :

Discharge :

NIL

Right Eye: ^{Ng} Add +2.25 sph N6

With glasses / Without glasses

left Eye : Ng Add +2.25 sph N6

with glasses / without glasses

Ophthalmologist's Signature

DR. KATTA
M.B.B.S., D.O., F.R.F.
Regd: 8557 (M.C.)

Left Ear

(N)

NIL

SYSTEMIC EXAMINATION

Pulse :

B.P. : 110/80

Lungs :

- A. Shape of Chest R/L symmetrical
- B. Breath Sounds R/L - clear ⊕
- C. Adventitious Sounds No

Heart :

- A. Sounds S₁ S₂ ⊕
- B. Murmurs no murmurs

Nervous System

Abdomen :

- A. Liver NPD
- B. Spleen NPD
- C. Piles NIL
- D. Any Lump NIL

A. Higher Function :

B. Cranial Nerves :

C. Sensory System :

D. Motor System :

E. Jerks :

(N)

General :

- A. Hernia
 - B. Hydrocele
 - C. Varicocele
- } NAD

Breast :

Rt _____ Lt. _____

CANDIDATE'S DECLARATION

I hereby solemnly declare that I am not suffering from Asthma, Hypertension, Diabetes, Occult Psychological disorders or any other ailment which can be suppressed without my voluntary declaration.

Date :

8/10/18
2

Signature

Place :

Note : General Physical Examination and Investigation included in the health check-up Have certain limitations and may not be able to detect all latent and asymptomatic diseases. Any new symptoms developing after the health check-up or persisting thereafter should be brought to the attention of the treating physician.



PARKLINE DIAGNOSTICS PVT. LTD.

L.G. 3, 4 & 5, Bhuvana Towers, Sarojini Devi Road, Secunderabad - 500 003 Tel. +91 40-2784 5852
6649 1787 Fax : +91 40 2784 7864 Email : parklinediagnostics@gmail.com www.parklinediagnostics.com



NABL Accredited
Certificate No. MC-2566

TEST REPORT

Name : Mr . PRABALA SUBBARAO [56252]
Age / Gender : 53 Years / Male
Ref.By : Medi Wheel
Req. No : BIL1869005

TID : UMR0739567
Registered on : 12-Mar-2022 10:31 AM
Reported On : 13-Mar-2022 09:19 AM

ABDOMINO-PELVIC ULTRASONOGRAPHY

LIVER is normal shape, size (14.0 cms) and increased echopattern.
No evidence of focal lesion or intrahepatic biliary ductal dilatation.
Hepatic and portal vein radicals are normal.

GALL BLADDER shows normal shape and has clear contents.
Gall bladder wall is of normal thickness.
CBD is of normal calibre.

PANCREAS has normal shape, size and uniform echopattern.
No evidence of ductal dilatation or calcification.

SPLEEN shows normal shape, size and echopattern.

KIDNEYS move well with respiration and have normal shape, size and echopattern.
Cortico- medullary differentiations are well made out.
No evidence of calculus or hydronephrosis.
Right kidney measures: 10.2 x 4.2 cms, Left kidney measures: 9.7 x 5.3 cms.

URINARY BLADDER shows normal shape and wall thickness.
It has clear contents. No evidence of diverticula.

PROSTATE : Normal in size and echotexture.
Prostate measures : 2.3 x 3.4 x 3.7 cms, Volume : 15 cc

No evidence of free fluid in the abdomen

IMPRESSION:

* Grade I Fatty liver.

Suggested clinical correlation and follow up

Dr. Abid Yazden
Consultant Radiologist

The Test marked with* are not accredited by NABL

Lab Timings (Weekdays) : 7.00 am to 8.30 pm

Sundays & Holidays : 7.00 am to 1.00 pm

Radiologists Timings (Weekdays) : 7.30 am to 1.30 pm
& 5.30 pm to 7.45 pm

Sundays & Holidays : 7.30 am to 9.30 am



PARKLINE DIAGNOSTICS PVT. LTD.

L.G. 3, 4 & 5, Bhuvana Towers, Sarojini Devi Road, Secunderabad - 500 003 Tel. +91 40-2784 5852
6649 1787 Fax : +91 40 2784 7864 Email : parklinediagnostics@gmail.com www.parklinediagnostics.com



NABL Accredited
Certificate No. MC-2566

TEST REPORT

Name : Mr . PRABALA SUBBARAO [56252]
Age / Gender : 53 Years / Male
Ref.By : Medi Wheel
Req. No : BIL1869005

TID : UMR0739567
Registered on : 12-Mar-2022 10:31 AM
Reported On : 13-Mar-2022 11:46 AM

X-RAY CHEST PA VIEW

Lung fields are clear.

Cardia is normal.


Hila are normal.

C P angles are free.

Bony cage is normal.

Soft tissues are normal.

IMPRESSION : NORMAL CHEST X-RAY


Dr. D.J. MOHAN
MD DMRD
(Reg No. 8995)
Consultant Radiologist

The Test marked with*are not accredited by NABL

Lab Timings (Weekdays) : 7.00 am to 8.30 pm
Sundays & Holidays : 7.00 am to 1.00 pm

Radiologists Timings (Weekdays) : 7.30 am to 1.30 pm
& 5.30 pm to 7.45 pm
Sundays & Holidays : 7.30 am to 9.30 am

Page 1 of 1

MR.PRABALA SUBBARAO

Male 53Years

HR : 69 bpm
P : 96 ms
PR : 151 ms
QRS : 74 ms
QT/QTc : 372/400 ms
P/QRS/T : 59/75/61 °
RV5/SV1 : 1.911/0.492 mV

WNL
Dr. NAVSEEN KUMAR .C
M.D., D.M.
Consultant Cardiologist
Reg. No. 52291

Diagnosis Information:
Sinus Rhythm
Normal ECG

Report Confirmed by:

PATIENT SUMMARY REPORT

KLINE DIAGNOSTICS PVT.LTD
: 1869005
IE : **MR PRABALA SUBBARAO**
: / SEX : 53 / MALE

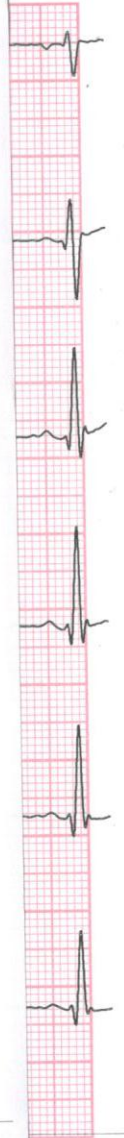
HEIGHT (cm) : 173
WEIGHT (kg) : 75
PROTOCOL : BRUCE

REF. BY : ~~GOROMANDEL INTERNATIONAL~~
DONE BY : DR NAVEEN KUMAR C
TECHNICIAN : G.M.SURESH

ERNATIO
022, 17:36:

SE HISTORY :
ICATION :

JECT OF TEST	: Routine Check Up.
CK FACTOR	: None.
TIVITY	: Very Active.
HER INVESTIGATION	: ECG
ASON FOR TERMINATION	: THR ACHIEVED
ERCISE TOLERANCE	: Moderate (< 10 METS). <i>SMEI,</i>
ERCISE INDUCED ARRHYTHMIAS	: No.
EMO RESPONSE	: Normal.
HRONO RESPONSE	: Normal.
NAL IMPRESSION	: <i>negative for inducible ischemia</i>
TRA COMMENTS	:



Dr. NAVEEN KUMAR .C
M.D., D.M.
Consultant Cardiologist
Reg. No. 52291

Confirmed By : _____

Signature