



BANK OF BARODA MEDICAL EXAMINATION REPORT

Client name :- Sumanika Deb barma

Ref. No. :-

Date of birth :- 25/06/1991 Sex :- Male / Female

Identification mark on the body :- One black mole at cheen

Photo ID Xerox :- Employee ID card (BOB)

Date & place of medical examination :- 23.06.23 - Asansol

Request for medical exam. of **BANK OF BARODA** through Medi Assist Health Care India (Pvt.) Ltd.

- A) 1. Height :- 161 cm. 2. Weight :- 60 kgs.
3. Chest Inspiration :- 93 cm. 4. Chest Expiration :- 89 cm.
5. Abdomen Girth :- 83 cm.
6. Blood Pressure :- I) 110/78 mm. of Hg. II) mm. of Hg.
7. Pulse Rate :- 68 / minute. Character of pulse :- Regular

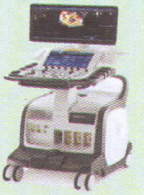- B) 1. Are you now in good health ? Yes
2. Are you currently taking any medicine ? No
3.) Are you married ? Yes
4. Have you ever had a positive test for HIV / AIDS / Malignancy ? No
5. Have you ever suffering from sexually transmitted disease or Hepatitis B or C ?
..... No
6. Have you any congenital disorders ? No
7. Have you any respiratory disorders ? No
8. Have you any musculo skeletal disorders ? No
9. Have you CVS disorders ? No
10. Have you GI system disorders ? No
11. Have you urinary system disorders ? No
12. Have you reproductive system disorders ? She had ovarian cyst and was under medical treatment.



ANUBIKSHAN

Diagnostic Centre

Near Asansol District Hospital(Main Gate)
S.B. Gorai Road, Asansol-713301
Email ID : anubikshan.dc@gmail.com
Ph. : 0341-3590332, M. : 9732362727, 7872772680



13. Have you Diabetes / Hypertension / Endocrine disorders? NO
14. Have you ever done any surgical operation? BB. Caloperated 2016
15. Have you any ear problem? NO
16. Have you any eye problem? No. Vx life, Nerv Vision - No, CV - Normal. *RM 24/6/23*
17. Have you nervous system disorders? NO
18. Have you any abnormal growth? NO
19. Have you any blood disorders? NO
20. What is general appearance of the client? Healthy
21. Does the appearance correspond with the age? Yes
22. Is there any personal peculiarities? NO
23. Tobacco (Stick / gms)- Panmasala/Cigar / Cigarette / Bidi / Gutkha Yes No
Alcohol(ml)- Beer / Wine / Hard Liquor :- Qty./ Day For No. of Yrs

24. Family History	Age if living	Age at death	Present state of health or cause of death
Father	70y	Good health	
Mother	69y	4	
Brother (s)	37y	4	
Sister (s)	no		

25. ANY REMARK BY THE MEDICAL EXAMINAR :-

[Signature]
Signature of the Client

DR. S. K. SHARMA
Name of the Doctor

Date: - 24/06/23

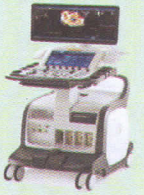[Signature]
Signature & Seal of the Doctor
Dr. Sanjeev Kevin Shan
M.B.B.S., MD (Med.)



ANUBIKSHAN

Diagnostic Centre

Near Asansol District Hospital(Main Gate)
S.B. Gorai Road, Asansol-713301
Email ID : anubikshan.dc@gmail.com
Ph. : 0341-3590332, M. : 9732362727, 7872772680



13. Have you Diabetes / Hypertension / Endocrine disorders? NO
14. Have you ever done any surgical operation? BB. Caloperated 2016
15. Have you any ear problem? NO
16. Have you any eye problem? No. Vx. etc. Nerv. Vision - No, CV - Normal. *RM 24/6/23*
17. Have you nervous system disorders? NO
18. Have you any abnormal growth? NO
19. Have you any blood disorders? NO
20. What is general appearance of the client? Healthy
21. Does the appearance correspond with the age? Yes
22. Is there any personal peculiarities? NO
23. Tobacco (Stick / gms)- Panmasala/Cigar / Cigarette / Bidi / Gutkha Yes No
Alcohol(ml)- Beer / Wine / Hard Liquor :- Qty./ Day For No. of Yrs

24. Family History	Age if living	Age at death	Present state of health or cause of death
Father	70y	Good health	
Mother	69y	4	
Brother (s)	37y	4	
Sister (s)	no		

25. ANY REMARK BY THE MEDICAL EXAMINAR :- _____

[Signature]
Signature of the Client

DR. S. K. SHAH.
Name of the Doctor

Date: - 24/06/23

[Signature]
Signature & Seal of the Doctor
Dr. Sanjeev Kevin Shah
M.B.B.S., MD (Med)



बैंक ऑफ़ बड़ोदा
Bank of Baroda

नाम

Name : **SUMITA DEBBARMA**

कर्मचारी कूट. क्र.

E. C. No. **174500**

जारीकर्ता प्राधिकारी



धारक के हस्ताक्षर

Dr. Sanjeev Kevin Shah
M.B.B.S., MD (Med.)
Reg. No. 16138

Dr. Sanjeev Kevin Shah



ELECTION COMMISSION OF INDIA
ভারতের নির্বাচন কমিশন

IDENTITY CARD

UGI0050070

পরিচয় পত্র



Elector's Name : Sumita Debbarma
নির্বাচকের নাম : সুমিতা দেববর্মা
Father's Name : Nishi Debbarma
পিতার নাম : নিশি দেববর্মা
Sex / লিঙ্গ : Female / স্ত্রী
Age : 20 Years as on 1.1.2011
বয়স : 20 বছর 1.1.2011 অনুসারে

সুমিতা

Dr. Sanjeev Kevin Shah

Dr. Sanjeev Kevin Shah
M.B.B.S., MD (Med.)
Reg. No. 16138

24.06.23

IDENTITY CARD UGI0050070

Address : 49, Kabrakhamar Purba Parswa
Town/Vill - Dinabandhunagar
PS - Jirania
Block Division - Sadar
District - West Tripura PIN - 799045

ঠিকানা : 49, কবরাখামার পূর্ব পার্শ্ব
শহর। গ্রাম - দীনবন্ধুনগর
থানা - জিরানিয়া
মহকুমা - সদর
জিলা - পশ্চিম ত্রিপুরা পিন - 799045

Facsimile Signature
Electoral Registration Officer

নির্বাচক নিবন্ধন আধিকারিক
For 11-Mandai Bazar(ST) Assembly Constituency

11 - মান্দাই বাজার (তপশীলি উপজাতি) বিধানসভা নির্বাচন
ক্ষেত্র

Place : Agartala

Date : 08/01/2011

স্থান : আগরতলা

তারিখ : 08/01/2011

This Card may be used as an Identity Card
under different Government Schemes.



Dr. Rajib Banerjee

B.Sc., B.H.M.S., DOS (Kol)
Consultant Homoeopathic Physician
and optometric Eye Specialist

ADDRESS :

1 No. Mohishila Colony
Bottala Bazar
Asansol - 3
Mob. : 9832197360

Rx

MS Debbavone Sumite

Rt. Eye		Lt. Eye	
Sph	Cyl	Sph	Cyl
∅	∅	∅	∅
Near Add. →	∅	Near Add. →	∅

VOL OFF
L OFF

Near vision No

CV - Normal

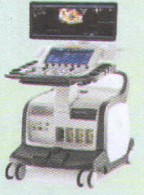RM
24/6/23

Chamber

Balananda Homoeo Clinic
Khejurtala More
Mohishila - 2, Asansol



Morning : 8.00 a.m. to 9.00 a.m.
Evening : 6.00 p.m. to 9.30 p.m.
Saturday Evening Closed
& Sunday Morning Closed



PATIENT'S NAME: - SUMITA DEBBARMA

AGE: - 32 YEAR

GENDER: - FEMALE

REFERED BY DR: - M.O. BANK OF BARODA..

DATE: - 24.06.2023

REPORT

CHEST X – RAY P A VIEW

Soft tissue around chest and bony cage --- normal.


No active lung lesion in either field.

Cardiac configuration normal.

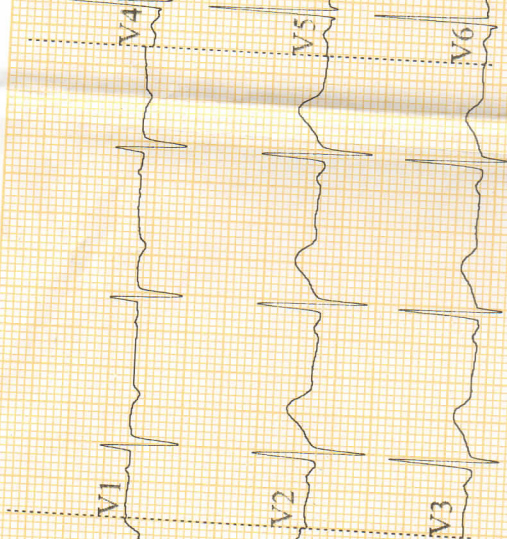
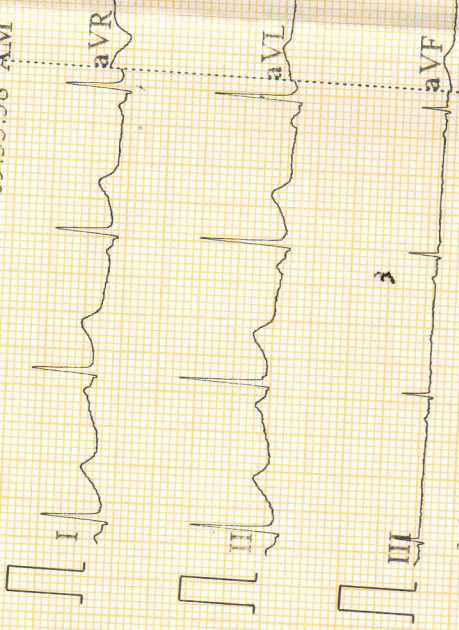
Pleural recesses are clear.

I M P R E S T I O N

✓ **NORMAL SKIAGRAM OF CHEST.**


DR. DIPANKAR DASGUPTA.
(M.B.B.S., D.M.R.D)
(Regd.No:- WB-34374)

ID: 819 24-06-2023 09:55:58 AM

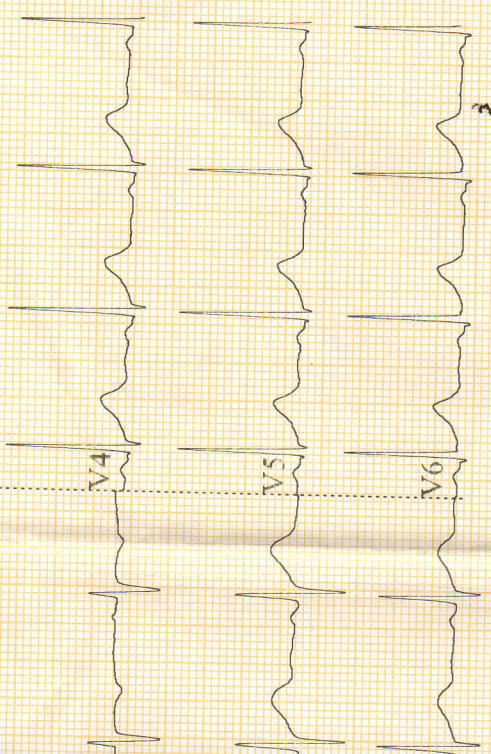


0.67~35Hz AC50 25mm/s 10mm/mV ♡79

V1.0 SEMIP V1.7

CARDIART

BPL



ID: 819

Female
32 Years
cm

mmHg

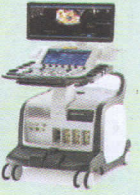kg

Diagnosis Information:
Sinus Rhythm
Normal ECG

Dr. Sunita Debarma, SRMF
me Bob.
S.D.

HR	: 79	bpm
P	: 95	ms
PR	: 127	ms
QRS	: 67	ms
QT/QTc	: 383.440	ms
PQRS/T	: 45/39/33	°
RV5/SVI	: 1.552/0.599	mV

Technician : DEBOJOYTI
Report Confirmed by:



ELECTRO CARDIO GRAM FORMAT

PATIENT'S NAME:- SUMITA DEBBARMA	
AGE:- 32 YRS	SEX:- FEMALE
REF BY DR:- M.O. BANK OF BARODA..	DATE:- 24.06.2023

- ❖ RATE :- 80
- ❖ AXIS :- normal
- ❖ P-WAVE :- normal
- ❖ P-R :- normal
- ❖ QRS :- normal
- ❖ ST-T :- no changes
- ❖ T-WAVE :-

➤ IMPRESSION :- *Normal sinus rhythm*

[Signature]
A. S. Gupta
48372
WB

Dr. SUNIL GUPTA
M B B S MD (Medicine)
Reg No WBMC 48372



ANUBIKSHAN

Diagnostic Centre

Near Asansol District Hospital(Main Gate)
S.B. Gorai Road, Asansol-713301
Email ID : anubikshan.dc@gmail.com
Ph. : 0341-3590332, M. : 9732362727, 7872772680

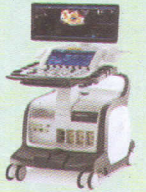PATIENT'S NAME: - SUMITA DEBBARMA

AGE: - 32 YEAR

SEX: - FEMALE

REF. BY DR.: - M.O.BANK OF BARODA.

DATE: - 28.06.2023



U. S. G. OF WHOLE ABDOMEN

LIVER

Normal shape and size. Homogeneous echo texture of the liver is seen.
No focal parenchymal lesion is seen. (Measure:- 125.19 mm.)

PORTA

Portal vein at porta hepatis measures:- 6.71 mm. in diameter.
The appearance of porta is normal.

GALL BLADDER

GB FOSSA EMPTY, History of surgical removal..

COMMON BILEDUCT

Common bile duct is not dilated (Measure:- 1.18 mm.)
No calculus or any intraluminal echogenicity.

PANCREAS

Normal echo-texture of the pancreas is seen. No space occupying lesion is seen.
Its relation with the anatomical landmark is normal.

SPLEEN

Normal dimension of the spleen is seen. It shows normal echo-texture.
No space occupying lesion is seen in the spleen. (Measure:- 78.27 mm.)

KIDNEYS

Both the kidneys are normal in shape, size, margin and axis.
Cortico medullary differentiation is normal.
No calculi or any hydronephrotic changes noted.
(Rt. Kidney Measure:- 96.11 mm. and Lt. Kidney Measure:- 103.88 mm. in length.)

URINARY BLADDER

Normal shape and size of the urinary bladder is seen.
No intraluminal echo is noted.

UTERUS

R/V, Bulky. (Measure: - 64.06 mm. x 29.53 mm. x 42.39 mm.)

OVARIES

Normal shape and size of the ovaries are seen.
Normal echo texture is seen.
No space occupying lesion is seen in the ovaries.
(Right ovary measure :- 39.81 mm. x 25.56 mm.)
(Left ovary measure :- 29.93 mm. x 24.16 mm.)

➤ **IMPRESSION :-**
❖ **NORMAL STUDY.**

ADVICE
Clinical co-relation.

Handwritten signature and date: 28/6

DR. DIPANKAR DASGUPTA.
(M.B.B.S., D.M.R.D)
(Regd.No:- WB-34374)

PATIENT'S NAME:- SUMITA DEBBARMA

AGE:- 29 YEAR SEX:- FEMALE

REF BY DR: - M.O. BANK OF BARODA.

DATE:- 28.06.2023

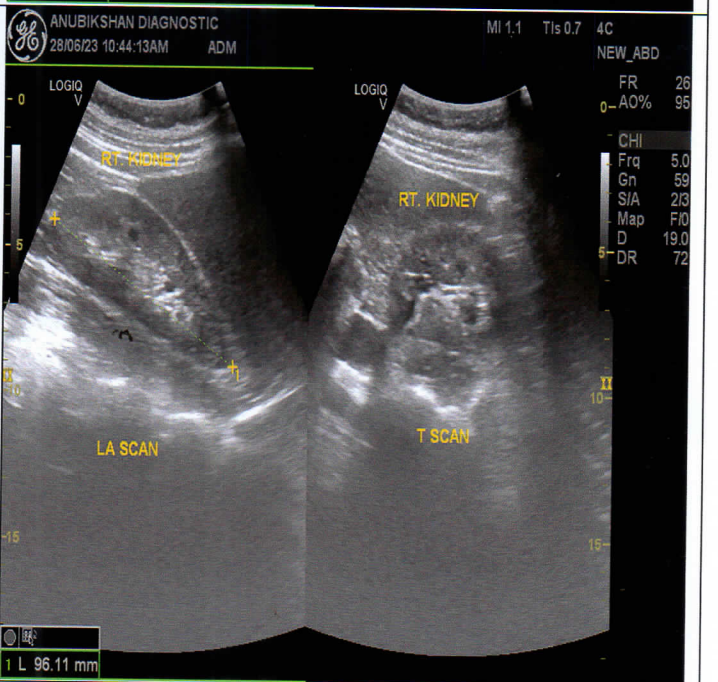
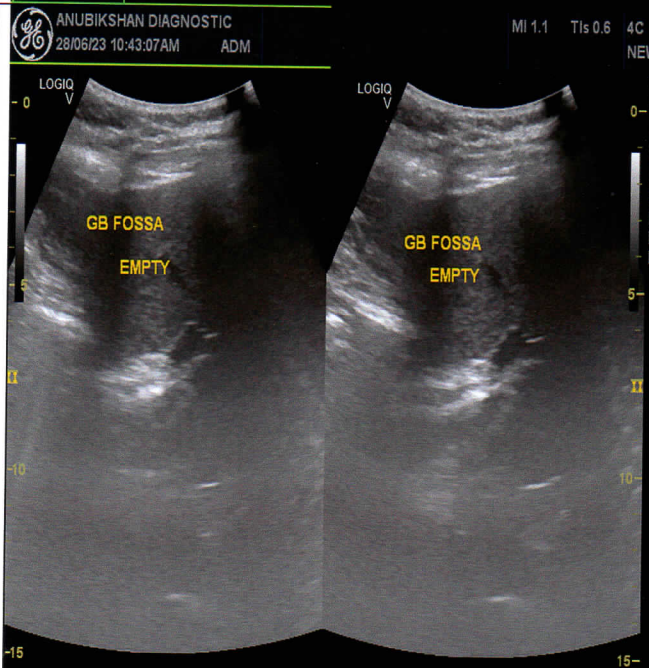
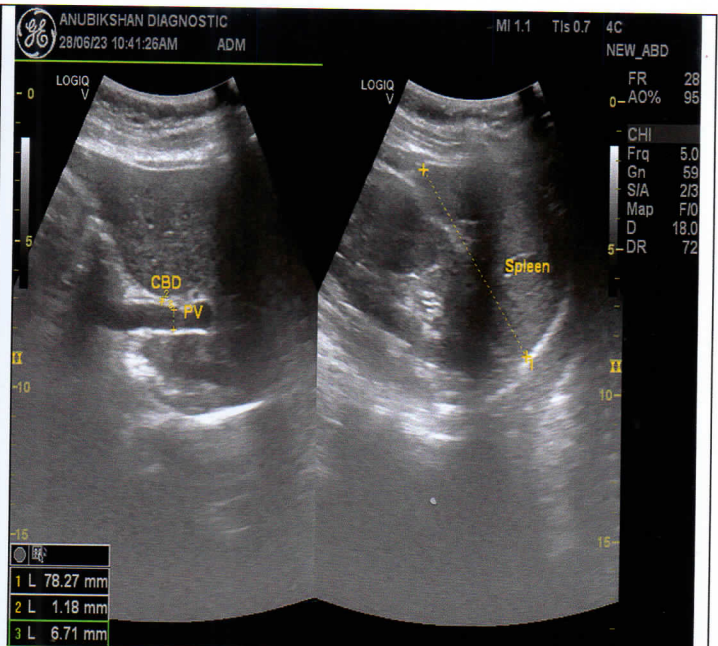
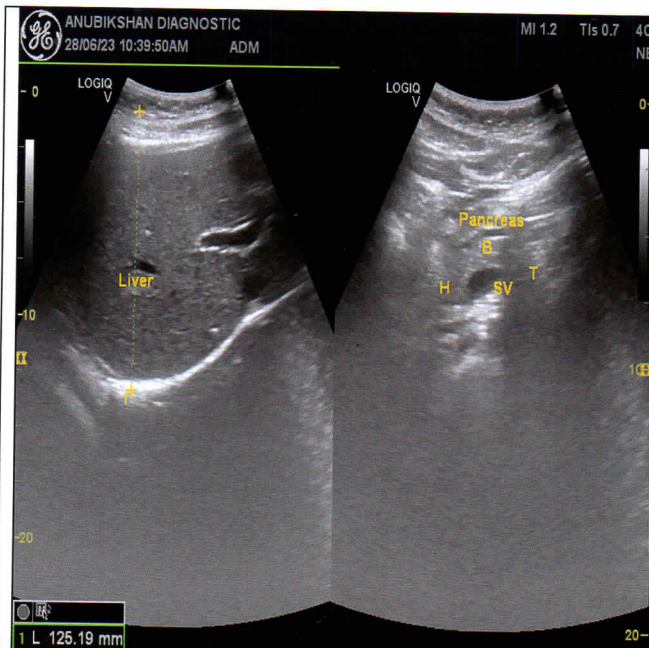
USG OF WHOLE ABDOMEN

ANUBIKSHAN **DIAGNOSTIC CENTRE**

**NEAR ASANSOL DISTRICT HOSPITAL (MAIN GATE)
S.B.GORAI ROAD (EAST) , PIN - 713301**

LANDLINE: - 0341-3590332 //MOB 7872772680

E- mail ID:- anubikshan.dc@gmail.com (1)



PATIENT'S NAME:- SUMITA DEBBARMA

AGE:- 29 YEAR SEX:- FEMALE

REF BY DR: - M.O. BANK OF BARODA.

DATE:- 28.06.2023

USG OF WHOLE ABDOMEN

ANUBIKSHAN

DIAGNOSTIC CENTRE

**NEAR ASANSOL. DISTRICT HOSPITAL (MAIN GATE)
S.B.GORAI ROAD (EAST), PIN – 713301**

LANDLINE: - 0341-3590332 //MOB 7872772680

E- mail ID:- anubikshan.dc@ gmail.com (2)

