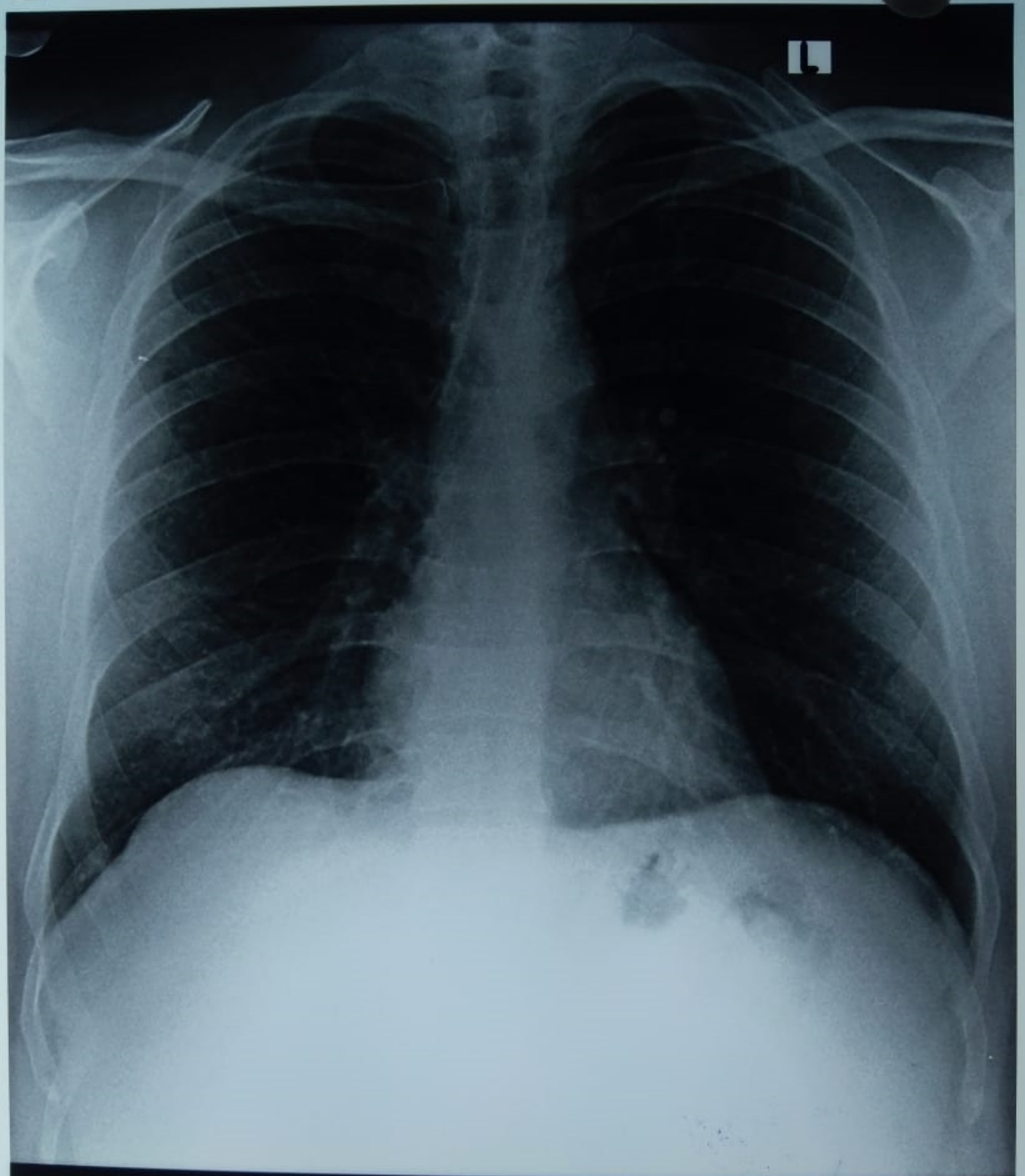

SHIV SHANKAR MAHTO AGE 46 YEARS 574 BY MEDIWHEEL TPA BOB CHEST,FRN P  
A.L.C. Advance Imaging Dignostics Centre PATNA-20



# A.L.C. Advance Imaging Dignostics

ISO 9001:2015 Certified center

(A Unit of P.K.Arogyam Health & Wellness Center)

E-95, P.C. Colony, Near Sai Netryalaya Transformer, Kankarbagh, Patna - 20

alcdiagnostics@gmail.com

www.alhealthcheckup.in

7050037694, 8271206196

OPINION MUST BE CORRELATES WITH CLINICALLY & OTHER INVESTIGATION FOR FINAL DIAGNOSIS. NOT FOR MEDICO LEGAL PURPOSE

BOOKING CODE – bobE 1194

Pt. Name :- SHIV SHANKAR MAHTO

Date:- 31-May-21

Ref. By :- DR./MEDWHEEL

Age / Sex – 46 Yrs. M.

Thanks for your kind referral

## X-RAYCHEST (P.A.VIEW)

The lungs on the either side show equal translucency.

The peripheral pulmonary vasculature is normal.

No focal lung lesion is seen.

The pleural spaces are normal.

Both hila are normal in size, have equal density and bear normal relationship.

The heart and trachea are central in position and no mediastinal abnormality is visible.

The cardiac size is normal.

The domes of the diaphragms are normal in position, and show smooth outline.

## IMPRESSION

- NO EVIDENCE OF PULMONARY OR CARDIAC PATHOLOGY IS NOTED.



31/5/21

Consultant Radiologist

ESTB BY:-

**Dr. P. K. Tiwari**

MD, BRIT (Radio Imaging)  
Consultant Imagonologist

**Dr. S. Kumar**

MD (Pat)  
Consultant Pathologist

**Dr. Abhishek Kumar**

MBBS, MD  
Consultant Neuropatho Physiologist

**Dr. Anjali**

MBBS, MD  
Consultant(TMT,EEG Specialist)

**Dr. Kumari Suman**

MBBS, DGO, MD  
Consultant (TVS & HSG Specialist)

SHIV SHANKAR MAHTO  
MALE

CASE: 1  
AGE: 46 Y 05 M 23 D  
65 Cms 77 Kg

DATE: 63 bpm SINUS RHYTHM  
-R: 946 ms POOR R WAVE PROGRESSION  
-R: 140 ms  
RS: 76 ms  
T: 378 ms  
Tc: 383 ms  
--AXIS--  
P: 76°  
RS: 58°  
T: 33°

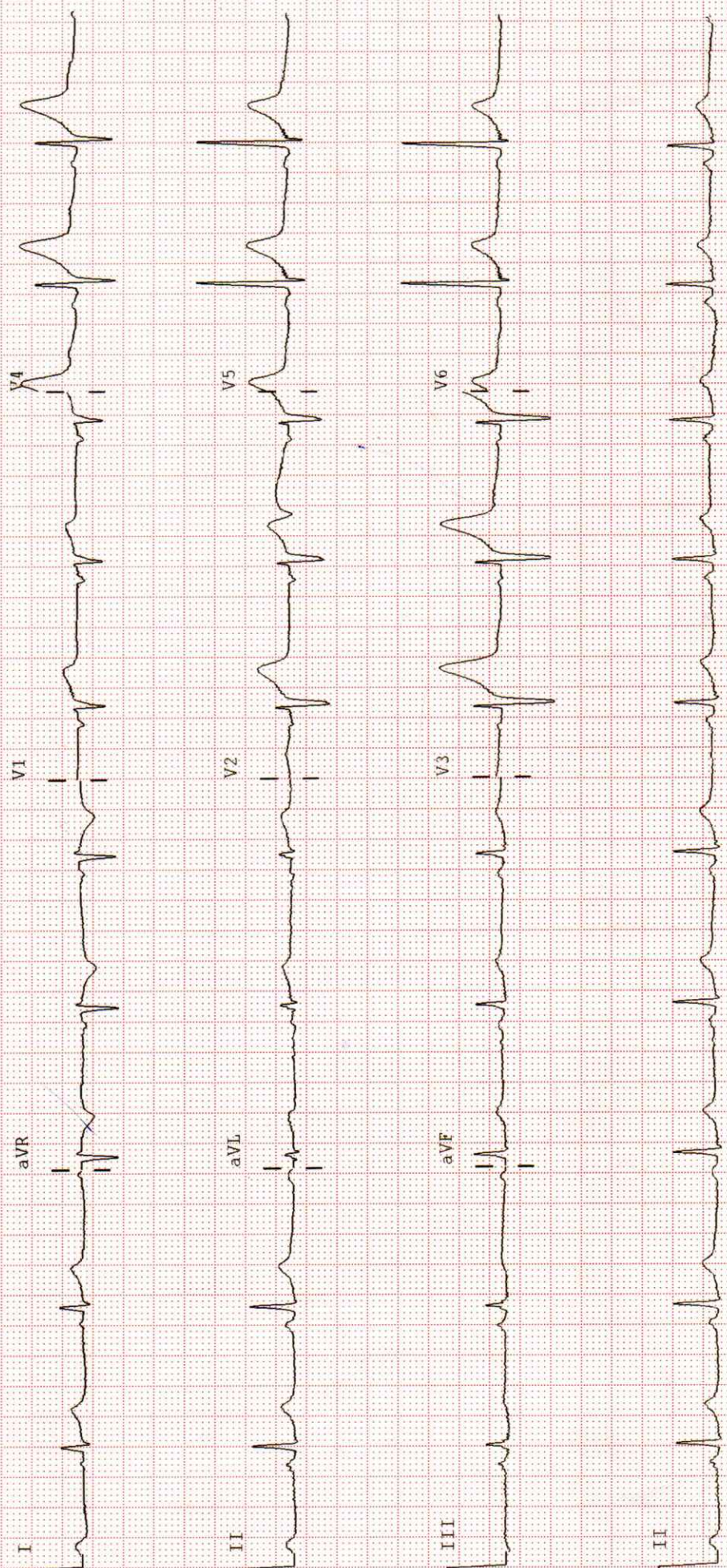
BOOKING CODE -- bobE 1194



Dr. DR ABHISHEK KUMAR MBBS MD

REF. MEDIWHEEL TPA BOB

2 SL; REPORT FORMAT: 3x4+1L SQ





# A.L.C. Advance Imaging Diagnostics

ISO 9001:2015 Certified center

(A Unit of P.K.Arogyam Health & Wellness Center)

E-95, P.C. Colony, Near Sai Netryalaya Transformer, Kankarbagh, Patna - 20

alcdiagnostics@gmail.com

www.alchealthcheckup.in

7050037694, 8271206196

OPINION MUST BE CORRELATES WITH CLINICALLY & OTHER INVESTIGATION FOR FINAL DIAGNOSIS. NOT FOR MEDICO LEGAL PURPOSE

PATIENT NAME : Mr . SHIV SHANKAR MAHTO PATIENT ID: 574  
COL DATE : 31/05/2021 REPORTING DATE: 31/05/2021 AGE SEX:- 46 YRS/M  
REF.BY : DR./MEDIWHEEL TPA B.O.B. BOOKING CODE-bobE 1194

## ROUTINE EXAMINATION OF URINE

### PHYSICAL EXAMINATION

Volume ...	40 ml
Colour	Straw
Appearance	Clear
Sediments	Nil
Specific Gravity	1.020

### CHEMICAL EXAMINATION

PH	5.0
Reaction...	ACIDIC
Sugar ...	NIL
Albumin ...	NIL
Phosphate..	Nil
Nitrite	Not done

### MICROSCOPIC EXAMINATION

Erythrocytes..	Nil
Pus cells	1-4 / HPE
Epithelial Cells	A, Few
Other	Nil



ESTB BY:-

**Dr. P. K. Tiwari**  
MD, BRIT (Radio Imaging)  
Consultant Imagonologist

**Dr. S. Kumar**  
MD (Pat)  
Consultant Pathologist

**Dr. Abhishek Kumar**  
MBBS, MD  
Consultant Neuropatho Physiologist

**Dr. Anjali**  
MBBS, MD  
Consultant(TMT,EEG Specialist)

**Dr. Kumari Suman**  
MBBS, DGO, MD  
Consultant (TVS & HSG Specialist)

**Consultant Radiologist**



# A.L.C. Advance Imaging Diagnostics

ISO 9001:2015 Certified center

(A Unit of P.K.Arogyam Health & Wellness Center)

E-95, P.C. Colony, Near Sai Netryalaya Transformer, Kankarbagh, Patna - 20

alcdiagnostics@gmail.com

www.alhealthcheckup.in

7050037694, 8271206196

OPINION MUST BE CORRELATES WITH CLINICALLY & OTHER INVESTIGATION FOR FINAL DIAGNOSIS. NOT FOR MEDICO LEGAL PURPOSE

PATIENT NAME : Mr. SHIV SHANKAR MAHTO

PATIENT ID:574

COL DATE : 31/05/2021 REPORTING DATE: 31/05/2021 AGE SEX : 46 YRS/M

REF.BY : DR./ MEDIWHEEL TPA B.O.B. BOOKING CODE – bobE 1194

## ROUTINE EXAMINATION OF STOOL

### PHYSICAL EXAMINATION

Colour : Brownish

Consistency : Semisolid

Mucus : Absent

Blood : Absent

### CHEMICAL EXAMINATION

Reaction : Acidic

Reducing Substance: Absent

Occult Blood : Absent

### MICROSCOPIC EXAMINATION

Pus cell : 1-3 HPE

RBCs : Absent

E. Histolytica : Present (+)

Veg. Cell/ Fibres : Present

Cyst : Absent

Fat globules : Absent

Macrophages : Absent

ESTB BY:-

**Dr. P. K. Tiwari**  
MD, BRIT (Radio Imaging)  
Consultant Imagiologist

**Dr. S. Kumar**  
MD (Pat)  
Consultant Pathologist

**Dr. Abhishek Kumar**  
MBBS, MD  
Consultant Neuropatho Physiologist

**Dr. Anjali**  
MBBS, MD  
Consultant (TMT, EEG Specialist)

**Consultant Radiologist**

**Dr. Kumari Suman**  
MBBS, DGO, MD  
Consultant (TVS & HSG Specialist)





# A.L.C. Advance Imaging Diagnostics

ISO 9001:2015 Certified center

(A Unit of P.K.Arogyam Health & Wellness Center)

E-95, P.C. Colony, Near Sai Netryalaya Transformer, Kankarbagh, Patna - 20

alcdiagnostics@gmail.com

www.alchealthcheckup.in

7050037694, 8271206196

OPINION MUST BE CORRELATES WITH CLINICALLY & OTHER INVESTIGATION FOR FINAL DIAGNOSIS. NOT FOR MEDICO LEGAL PURPOSE

PATIENT NAME : Mr. SHIV SHANKAR MAHTO PATIENT ID: 574  
COL DATE : 31/05/2021 REPORTING DATE: 31/05/2021 AGE SEX : 46 YRS/M  
REF.BY : DR./ MEDIWHEEL TPA B.O.B. BOOKING CODE – bobE 1194

## GLYCOSYLATED HEMOGLOBIN

TEST NAME	RESULT	Unit	REF.RANGE
HbA1c	4.1 %		Below 5.7 % : Normal 5.7 – 6.4 % : Prediabetic > = 6.5 % : Diabetic
AVERAGE PLASMA GLUCOSE	99.4 mg/dl		90 – 120 mg/dl : Good Control 121– 150 mg/dl : Fair Control 151- 180 mg/dl: Unsatisfactory Control >180 mg/dl : Poor Control



ESTB BY:-

**Dr. P. K. Tiwari**  
MD, BRIT (Radio Imaging)  
Consultant Imagiologist

**Dr. S. Kumar**  
MD (Pat)  
Consultant Pathologist

**Dr. Abhishek Kumar**  
MBBS, MD  
Consultant Neuropathology

**Dr. Anjali**  
MBBS, MD  
Consultant(TMT,EEG Specialist)

**Consultant Radiologist**

**Dr. Kumari Suman**  
MBBS, DGO, MD  
Consultant (TVS & HSG Specialist)

PRINTING MISTAKE SHOULD BE REPORTED BACK IMMEDIATELY/ यहाँ जन्म से पहले भ्रण का लिंग जाँच नहीं होता है ।



# A.L.C. Advance Imaging Diagnostics

ISO 9001:2015 Certified center

(A Unit of P.K.Arogyam Health & Wellness Center)

E-95, P.C. Colony, Near Sai Netryalaya Transformer, Kankarbagh, Patna - 20

alcdiagnostics@gmail.com

www.alhealthcheckup.in

7050037694, 8271206196

OPINION MUST BE CORRELATES WITH CLINICALLY & OTHER INVESTIGATION FOR FINAL DIAGNOSIS. NOT FOR MEDICO LEGAL PURPOSE

PATIENT NAME : Mr. SHIV SHANKAR MAHTO PATIENT ID: 574  
COL DATE : 31/05/2021 REPORTING DATE: 31/05/2021 AGE SEX:- 46 YRS/M  
REF.BY : DR. / MEDIWHEEL TPA B.O.B. BOOKING CODE – bobE 1194

TEST NAME	RESULT	Unit	REF.RANGE
-----------	--------	------	-----------

BLOOD GROUP	:	'O'	
Rh Typing	:	POSITIVE	

Note: Do always cross – matching before blood transfusion



ESTD BY:-

**Dr. P. K. Tiwari**  
MD, BRIT (Radio Imaging)  
Consultant Imagiologist

**Dr. S. Kumar**  
MD (Pat)  
Consultant Pathologist

**Dr. Abhishek Kumar**  
MBBS, MD  
Consultant Neuropatho Physiologist

**Dr. Anjali**  
MBBS, MD  
Consultant(TMT,EEG Specialist)

**Dr. Kumari Suman**  
MBBS, DGO, MD  
Consultant (TVS & HSG Specialist)

**Consultant Radiologist**



# A.L.C. Advance Imaging Diagnostics

ISO 9001:2015 Certified center

(A Unit of P.K.Arogyam Health & Wellness Center)

E-95, P.C. Colony, Near Sai Netryalaya Transformer, Kankarbagh, Patna - 20

alcdiagnostics@gmail.com

www.alhealthcheckup.in

7050037694, 8271206196

OPINION MUST BE CORRELATES WITH CLINICALLY & OTHER INVESTIGATION FOR FINAL DIAGNOSIS. NOT FOR MEDICO LEGAL PURPOSE

PATIENT NAME : Mr. SHIV SHANKAR MAHTO

PATIENT ID: 574

COL DATE : 31/05/2021 REPORTING DATE: 31/05/2021 AGE SEX : 46 YRS/M

REF.BY : DR./ MEDIWHEEL TPA B.O.B.

BOOKING CODE – bobE 1194

Investigation	Result	Normal Range
Total Triiodothyronin T3	131.20 $\mu$ ng/dl	70 -200 $\mu$ ng/dl
Total Thyroxin T4	6.11 $\mu$ ug/dl	4.8 -13.5 $\mu$ ug/dl
Serum TSH	2.25 $\mu$ U/ml	0.39 -6.16 $\mu$ U/ml

THYROID DISORDER (>): Increase: < Decrease: n Normal

1. T3(n) T4(n) TSH(n) :EUTHYROID STATE:
2. T3(>) T4(>) TSH(<): HYPERTHYROIDISM:
3. T3(<)T4(<) TSH(>): HYPOTHYROIDISM:
4. T3(n)T4(n) TSH(>) : SUB-CLINICAL HYPO-THYROIDISM:
5. T3(n)T4(n) TSH(<): SUB-CLINICAL HYPER-THYROIDISM:
6. T3(>) T4(n) TSH(<): T3 THYROTOXICOSIS:

Total T3/T4 level is dependent on Level:

So determination of free T3/T4is a better MARKER of Thyroid Function.

\*FREE T3/T4 ESTIMATION FACILITY IS AVAILABALE ON REQUEST.:



ESTB BY:-

**Dr. P. K. Tiwari**  
MD, BRIT (Radio Imaging)  
Consultant Imagonologist

**Dr. S. Kumar**  
MD (Pat)  
Consultant Pathologist

**Dr. Abhishek Kumar**  
MBBS, MD  
Consultant Neuropatho Physiologist

**Dr. Anjali**  
MBBS, MD  
Consultant(TMT,EEG Specialist)

**Dr. Kumari Suman**  
MBBS, DGO, MD  
Consultant (TVS & HSG Specialist)

**Consultant Radiologist**





# A.L.C. Advance Imaging Diagnostics

ISO 9001:2015 Certified center

(A Unit of P.K.Arogyam Health & Wellness Center)

E-95, P.C. Colony, Near Sai Netryalaya Transformer, Kankarbagh, Patna - 20

alcdiagnostics@gmail.com

www.alhealthcheckup.in

7050037694, 8271206196

PATIENT NAME: Mr. SHIV SHANKAR MAHTO PATIENT ID: 574  
OPINION MUST BE CORRELATES WITH CLINICALLY & OTHER INVESTIGATION FOR FINAL DIAGNOSIS. NOT FOR MEDICO LEGAL PURPOSE

COL DATE : 31/05/2021 REPORTING DATE: 31/05/2021 AGE SEX : 46 YRS/M

REF.BY : DR./ MEDIWHEEL TPA B.O.B. BOOKING CODE - bobE 1194

TEST NAME	RESULT	Unit	REF.RANGE
ESR	5 mm/hr		<20 mm/hr
CBC			
Total W.B.C. Count	5300 /cumm		4000-11,000 /cumm
R B C COUNT	4.9 Million/ CUmm		4.-7 Million/ CUmm
Platelets count	1.46 Lakh/ cumm		1.5-5.0 Lakh/ cumm
Differential Count of W.B.C.			
Neutrophils	59 %		40-70%
Lymphocytes	37 %		25-40%
Eosinophils	03 %		01-05%
Mnonocytes	01 %		00-02%
Basophiles	00 %		00-0%
HAEMOGLOBIN	14.4 gm/dl ( 98.6 % )		14.6 gm/dl = 100%
PCV	43.1 %		35-47 %
MCV	87.4 fl		76-96 fl
MCH	29.3 pg		29-35 pg
MCHC	33.5 %		30-38 %



Consultant Radiologist

ESTB BY:-

**Dr. P. K. Tiwari**  
MD, BRIT (Radio Imaging)  
Consultant Imagonologist

**Dr. S. Kumar**  
MD (Pat)  
Consultant Pathologist

**Dr. Abhishek Kumar**  
MBBS, MD  
Consultant Neuropatho Physiologist

**Dr. Anjali**  
MBBS, MD  
Consultant(TMT,EEG Specialist)

**Dr. Kumari Suman**  
MBBS, DGO, MD  
Consultant (TVS & HSG Specialist)



# A.L.C. Advance Imaging Diagnostics

ISO 9001:2015 Certified center

(A Unit of P.K.Arogyam Health & Wellness Center)

E-95, P.C. Colony, Near Sai Netryalaya Transformer, Kankarbagh, Patna - 20

alcdiagnostics@gmail.com

www.alhealthcheckup.in

7050037694, 8271206196

OPINION MUST BE CORRELATES WITH CLINICALLY & OTHER INVESTIGATION FOR FINAL DIAGNOSIS. NOT FOR MEDICO LEGAL PURPOSE

PATIENT NAME : Mr. SHIV SHANKAR MAHTO PATIENT ID: 574  
COL DATE : 31/05/2021 REPORTING DATE:31/05/2021 AGE SEX : 46 YRS/M  
REF.BY : DR. /MEDIWHEEL TPA B.O.B. BOOKING CODE – bobE 1194

TEST NAME	RESULT	Unit	REF.RANGE
BLOOD SUGAR ( F )	93.0 mg/dl		70-110 mg/dl
BLOOD SUGAR ( PP )	107.0 mg/dl		70-140 mg/dl
<b>LIPID PROFILE:-</b>			
TOTAL CHOLESTROL	163.2 mg/dl		130-250 mg/dl
TRIGLYCERIDE	<b>165.8</b> mg/dl		50-160 mg/dl
HDL CHOLESTROL	43.0 mg/dl		30- 60 mg/dl
LDL CHOLESTROL	87.1 mg/dl		80-130 mg/dl
VLDL CHOLESTROL	33.1 mg/dl		15-40 mg/dl
T.CH./HDL RATIO	3.1:1		
LDL./HDL RATIO	2.6:1		



Consultant Radiologist

ESTB BY:-

**Dr. P. K. Tiwari**  
MD, BRIT (Radio Imaging)  
Consultant Imagiologist

**Dr. S. Kumar**  
MD (Pat)  
Consultant Pathologist

**Dr. Abhishek Kumar**  
MBBS, MD  
Consultant Neuropatho Physiologist

**Dr. Anjali**  
MBBS, MD  
Consultant(TMT,EEG Specialist)

**Dr. Kumari Suman**  
MBBS, DGO, MD  
Consultant (TVS & HSG Specialist)

PRINTING MISTAKE SHOULD BE REPORTED BACK IMMEDIATELY/ यहाँ जन्म से पहले भ्रूण का लिंग जाँच नहीं होता है ।



# A.L.C. Advance Imaging Diagnostics

ISO 9001:2015 Certified center

(A Unit of P.K.Arogyam Health & Wellness Center)

E-95, P.C. Colony, Near Sai Netryalaya Transformer, Kankarbagh, Patna - 20

alcdiagnostics@gmail.com

www.alhealthcheckup.in

7050037694, 8271206196

OPINION MUST BE CORRELATES WITH CLINICALLY & OTHER INVESTIGATION FOR FINAL DIAGNOSIS. NOT FOR MEDICO LEGAL PURPOSE

PATIENT NAME : Mr. SHIV SHANKAR MAHTO

PATIENT ID: 574

COL DATE : 31/05/2021 REPORTING DATE: 31/05/2021 AGE SEX:- 46 YRS/M

REF.BY : DR. / MEDIWHEEL TPA B.O.B. BOOKING CODE – bobE 1194

TEST NAME	RESULT	Unit	REF.RANGE
<b>LFT:-</b>			
GGT	19.7 IU/l		8 – 38 IU/L
SGPT	27.7 IU/L		5 – 40 IU/L
S G O T	36.1 IU/L		5 – 40 IU/L
ALKALINE PHOSPHATASE	100.4 IU/L		25-147 IU/L
SERUM ALBUMIN	5.0 g/dl		3.5 --5.4 g/dl
SERIUM GLUBLINE	2.8 g/dl		2.3 -- 3.6 g/dl
AG RATIO	1.7 : 1		1.0—2.3 g/dl
BILIRUBIN			
	TOTAL	0.8 mg/dl	0.1- 1.0mg/dl
	DIRECT	0.3 mg/dl	0.0- 0.3mg/dl
	INDIRECT	0.5 mg/dl	0.0- 0.7 mg/dl
<b>KFT/RFT</b>			
URIC ACID	5.0 mg/dl		3.2—7.0 mg/dl
TOTAL PROTIN	7.8 g/dl		6.0--8.7 g/dl
SERUM CREATNINE	0.7 mg/dl		0.6-1.5 mg/dl
BLOOD UREA	29.6 mg/dl		5 - 45 mg/dl
BLOOD URIA NITROZEN(BUN).	13.8 mg/dl		13- 39 mg/dl
BUN/CREATININE RATIO	19.7:1		



ESTB BY:-

Consultant Radiologist

Dr. P. K. Tiwari

MD, BRIT (Radio Imaging)  
Consultant Imagiologist

Dr. S. Kumar

MD (Pat)  
Consultant Pathologist

Dr. Abhishek Kumar

MBBS, MD  
Consultant Neuropatho Physiologist

Dr. Anjali


MBBS, MD  
Consultant(TMT,EEG Specialist)

Dr. Kumari Suman


MBBS, DGO, MD  
Consultant (TVS & HSG Specialist)

PRINTING MISTAKE SHOULD BE REPORTED BACK IMMEDIATELY/ यहाँ जन्म से पहले भ्रूण का लिंग जाँच नहीं होता है ।

भारत सरकार  
GOVERNMENT OF INDIA



शिव शंकर महतो  
Shiv Shankar Mahto  
जन्म तिथि/ DOB: 25/12/1975  
पुरुष / MALE



7596 7392 7976

मेरा आधार, मेरी पहचान



बैंक ऑफ़ बड़ोदा  
Bank of Baroda



नाम SHIV SHANKAR MAHTO  
Name

कार्यकारी स्टैंड नं. 63151  
E.C. NO.



जारीकर्ता अधिकारी  
Issuing Authority



धारक के हस्ताक्षर  
Signature of Holder




**भारतीय विरिक्त पहचान प्राधिकरण**  
 UNIQUE IDENTIFICATION AUTHORITY OF INDIA

<p><b>पता:</b>          आनमज, कैलाश महतो,          नयमा, बॉर्ड-8, डुमरा,          मितापडी,          बिहार - 843301</p>	<p><b>Address:</b>          S/O Kailash Maho, Jagma,          ward-8, Dumra, Sitamarhi,          Bihar - 843301</p>
--	---

7596 7392 7976

---

MERA AADHAAR, MERI PEHACHAN

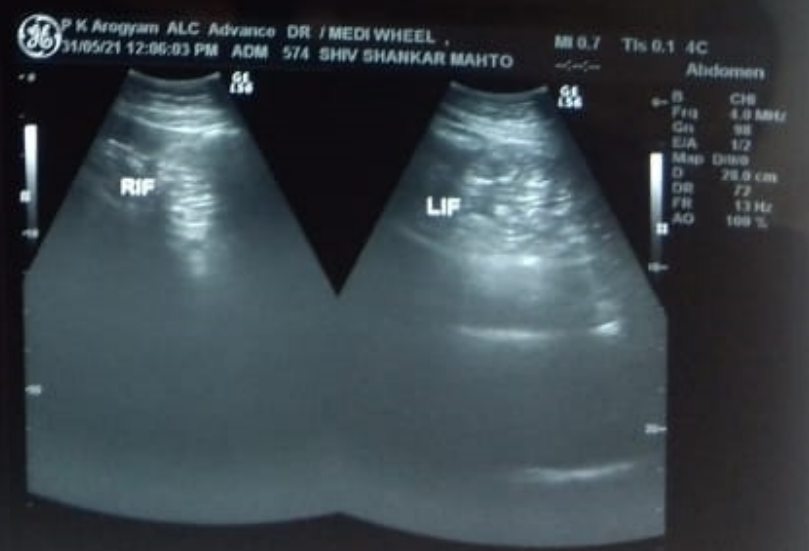
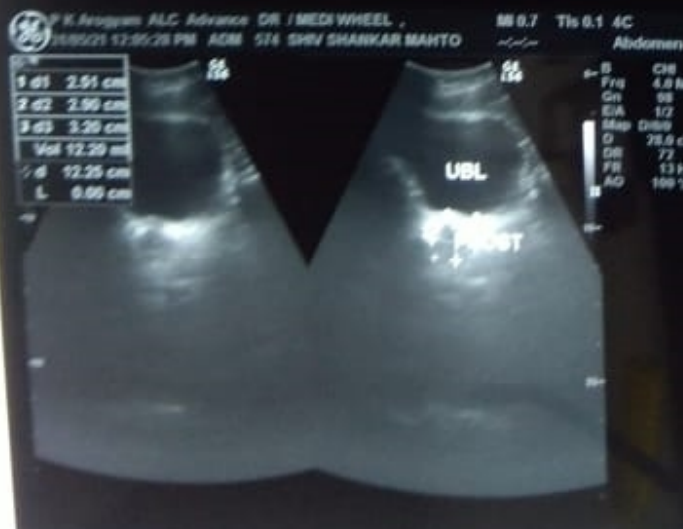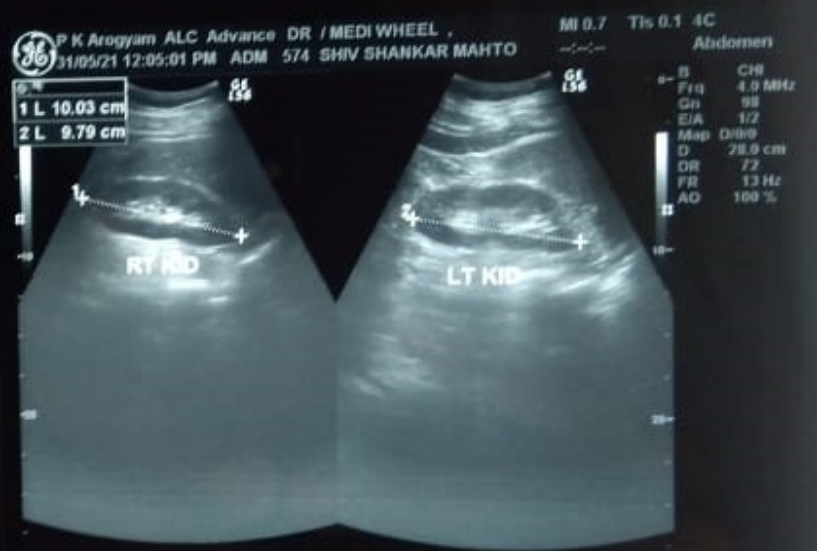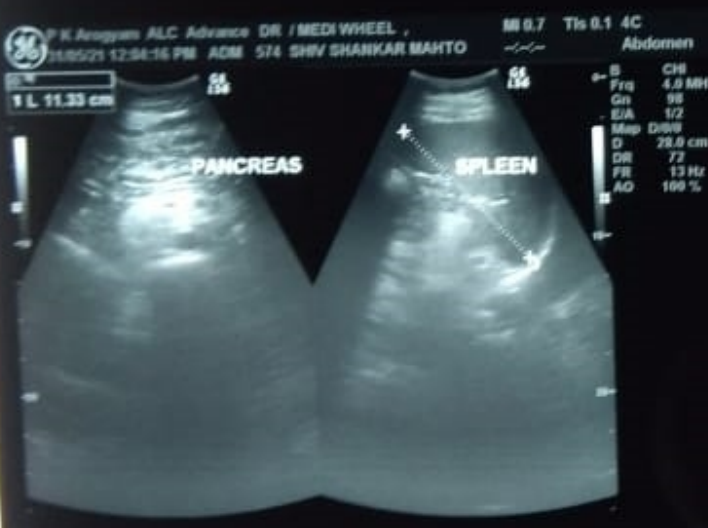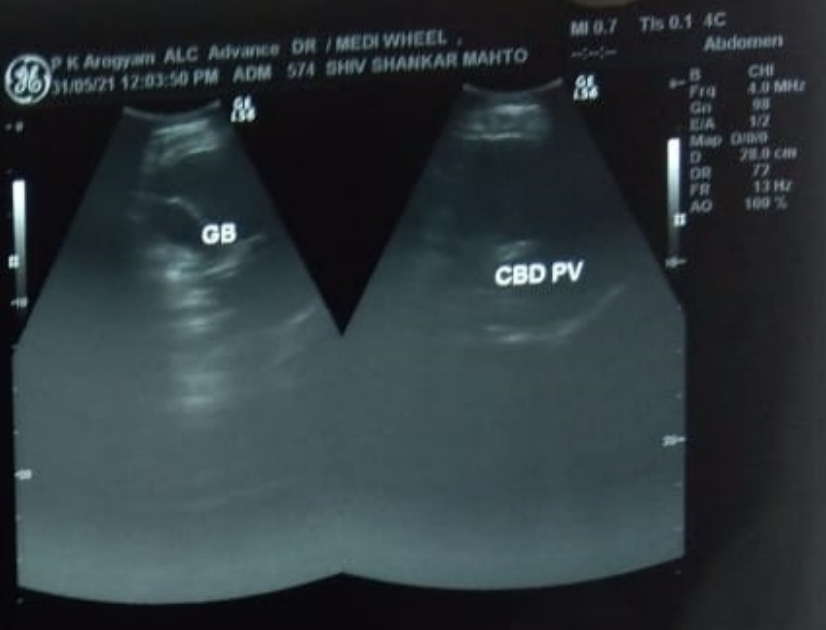
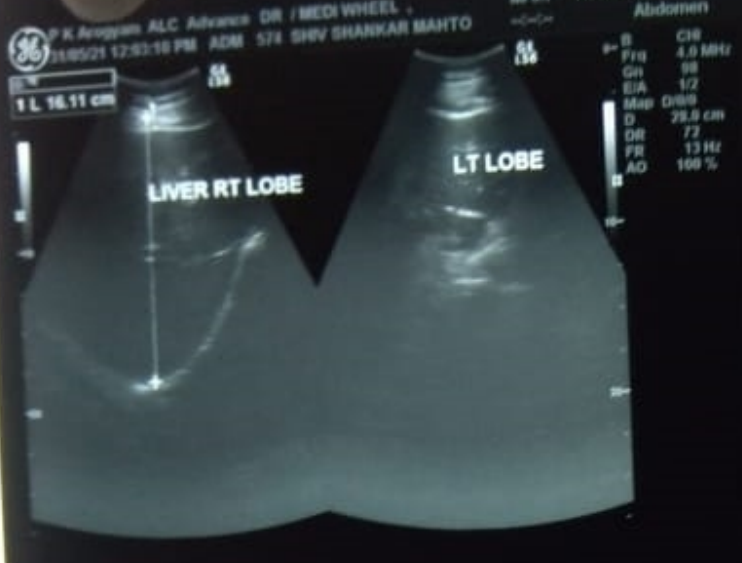
**मिलने पर, निम्नलिखित को लौटायें**  
 सहायक महाप्रबंधक (सुरक्षा)  
 बैंक ऑफ़ बड़ोदा, बड़ोदा कॉर्पोरेट सेंटर  
 सी-26 जी-ब्लॉक, बान्द्रा कुर्ला कॉम्प्लेक्स, मुंबई - 400 051, भारत  
 फोन 91 22 6698 5196 फैक्स 91 22 2652 5747

**If found, please return to**  
 Asst. General Manager (Security)  
 Bank of Baroda, Baroda Corporate Centre  
 C-26, G-Block, Bandra-Kurla Complex, Mumbai-400 051, India  
 Phone 91 22 6698 5196 Fax 91 22 2652 5747

**रक्त समूह / Blood Group** O+  
**पहचान चिन्ह / Identification Marks** STEECH ON RIGHT SIDE OF THE HEAD



JI PRINTER





# A.L.C. Advance Imaging Dignostics

ISO 9001:2015 Certified center

(A Unit of P.K.Arogyam Health & Wellness Center)

E-95, P.C. Colony, Near Sai Netryalaya Transformer, Kankarbagh, Patna - 20

alcdiagnostics@gmail.com

www.alhealthcheckup.in

7050037694, 8271206196

OPINION MUST BE CORRELATES WITH CLINICALLY & OTHER INVESTIGATION FOR FINAL DIAGNOSIS. NOT FOR MEDICO LEGAL PURPOSE

**Pt. Name :- SHIV SHANKAR MAHTO**

**Date:- 31-May-21**

**Ref. By :- DR. MEDI WHEEL** BOOKING CODE – bobE 1194 **Age / Sex :- 46 Yrs. M.**

## REAL TIME U.S.G. OF WHOLE ABDOMEN

Thanks for your kind referral

### ( Report.)

**LIVER :- Measures 16.11 cm. Mild Enlarged in shape , size and echo texture fatty change seen in liver parenchyma .I.H.B.R. are not dilated.**

**Hepatic veins are normal. No SOL seen.**

**G.BL. :- Lumen is echo free. Wall thickness appears normal.**

**C.B.D. :- Measures 3.5 mm in diameter with echo free lumen. No calculi or mass seen.**

**P.V. :- Measures 7.7 mm in diameter. Appears normal. No thrombus seen.**

**PANCREAS :- Normal in shape, size and echo texture. No calcification mass seen.**

**SPLEEN :- Measures 11.33 cm. Normal in shape, size and echo texture. No SOL seen.**

**KIDNEY :- Both kidney shows normal shape, size & echotexture. C.M.D.intact. P.C.S.is not dilated.**

**Right Kidney :- Measures 10.10 X 3.50 cm.**

**Left Kidney :- Measures 9.70 X 3.50 cm.**

**URETER :- Not dilated .No apparent calculi seen.**

**U.BLADDER:- Shows normal in outline with echo free lumen. No calculi or mass seen.**

**Pre void – 320 ml. Post void – is in significant**

**PROSTATE :- Measures 12 gms.(approx). Appears Normal in size, shape, and echo texture. No calcification , mass ,growth seen. capsule is intact.**

**R.I.F. :- Son graphically no appendicular mass or collection seen.**

**OTHERS :- Excess Gasses bowel distention seen in Abdomen .No Ascites No Lymph Adenopathy. No pleural Effusion seen on either side**

### IMPRESSION

- **Mild Hepatomegaly With fatty liver G-I**
- **Excess Gasses bowel distention seen in Abdomen**
- **Adv:- Further work up other investigation**  
**Otherwise son graphically normal scan. of rest organs**



31/5/21

Consultant Radiologist

ESTB BY:-

**Dr. P. K. Tiwari**  
MD, BRIT (Radio Imaging)  
Consultant Imagionologist

**Dr. S. Kumar**  
MD (Pat)  
Consultant Pathologist

**Dr. Abhishek Kumar**  
MBBS, MD  
Consultant Neuropatho Physiologist

**Dr. Anjali**  
MBBS, MD  
Consultant(TMT,EEG Specialist)

**Dr. Kumari Suman**  
MBBS, DGO, MD  
Consultant (TVS & HSG Specialist)