



DEPARTMENT OF PATHOLOGY

Patient Name : Mr. JITESH KUMAR MUCHCHAL
MR No : 667973
Age/Sex : 42 Years 2 Months 26 Days / Male
Type : OPD
TPA/Corporate : MEDIWHEEL PVT LTD

Bill Date : 17/12/2022
Reporting Date : 17/12/2022
Sample ID : 76289
Bill/Req. No. : 23009491
Ref Doctor : Dr.RMO

Test	Result	Bio. Ref. Interval	Units	Method
KFT (RENAL PROFILE)				
KFT				
SERUM UREA	31	10 - 45	mg/dL	UREASE-GLDH
SERUM CREATININE	1.4	0.4 - 1.4	mg/dL	MODIFIED JAFFES
SERUM URIC ACID	7.2	<i>H</i> 2.5 - 7.0	mg/dL	URICASE
SERUM SODIUM	144	136 - 145	meq/l	ISE
SERUM POTASSIUM	4.6	3.5 - 5.5	meq/l	ISE
SERUM CALCIUM	8.5	8.5 - 10.5	mg/dL	ARSENAZO III
SERUM PHOSPHORUS	3.7	2.5 - 4.5	mg/dL	AMMONIUM
SPECIMEN TYPE	SERUM			

***** END OF THE REPORT *****



Sample no.

Dr. SONIA KUMARI
MBBS, MD (PATHOLOGY) Gold medalist

Dr. PRADIP KUMAR
Consultant (Microbiology)

Dr. NISHA TIWARI
MBBS, MD (Microbiology)

USER NM NIKHIL

(This is only professional opinion and not the diagnosis, Please correlate clinically)

Q Block South City 11, Sohna Road, Main Sector-47, Gurgaon, Haryana
Ph.: 0124-4900000 (100 Lines) Fax : 0124-2218733 E-mail : parkmedicenters@gmail.com

PARK GROUP OF HOSPITALS : West Delhi • South Delhi • Gurgaon • Karnal • Panipat • Hodal • Ambala • Behror

the **health** care providers

the **health** care providers





NABL
Cert. No. NC - 4530



NABH
Cert. No. H-2016-2389

DEPARTMENT OF PATHOLOGY

Patient Name : Mr. JITESH KUMAR MUCHCHAL
MR No : 667973
Age/Sex : 42 Years 2 Months 26 Days / Male
Type : OPD
TPA/Corporate : MEDIWHEEL PVT LTD

Bill Date : 17/12/2022
Reporting Date : 17/12/2022
Sample ID : 76289
Bill/Req. No. : 23009491
Ref Doctor : Dr.RMO

Test	Result	Bio. Ref. Interval	Units	Method
LIPID PROFILE				
LIPID PROFILE				
TOTAL CHOLESTEROL	232	0 - 250	mg/dL	CHOD -Trinder
SERUM TRIGLYCERIDES	193	H 60 - 165	mg/dl	GPO-TRINDER
HDL-CHOLESTEROL	49	30 - 70	mg/dl	DIRECT
VLDL CHOLESTEROL	38	H 6 - 32	mg/dL	calculated
LDL	145	H 50 - 135	mg/dl	calculated
LDL CHOLESTEROL/HDL RATIO	2.9	1.0 - 3.0	mg/dL	calculated
TOTAL CHOLESTEROL/HDL RATIO	4.7	2.0 - 5.0	mg/dl	calculated

***** END OF THE REPORT *****



Sample no.

Dr. SONIA KUMARI
MBBS, MD (PATHOLOGY) Gold medalist

Dr. PRADIP KUMAR
Consultant (Microbiology)

Dr. NISHA TIWARI
MBBS, MD (Microbiology)

USER NM SHOAIBPA166

(This is only professional opinion and not the diagnosis, Please correlate clinically)

Q Block South City 11, Sohna Road, Main Sector-47, Gurgaon, Haryana Page 1 of 1
Ph.: 0124-4900000 (100 Lines) Fax : 0124-2218733 E-mail : parkmedicenters@gmail.com

PARK GROUP OF HOSPITALS : West Delhi • South Delhi • Gurgaon • Karnal • Panipat • Hodal • Ambala • Behror

the **health** care providers

the **health** care providers



DEPARTMENT OF PATHOLOGY

Patient Name : Mr. JITESH KUMAR MUCHCHAL
 MR No : 667973
 Age/Sex : 42 Years 2 Months 26 Days / Male
 Type : OPD
 TPA/Corporate : MEDIWHEEL PVT LTD

Bill Date : 17/12/2022
 Reporting Date : 17/12/2022
 Sample ID : 76289
 Bill/Req. No. : 23009491
 Ref Doctor : Dr.RMO

Test	Result	Bio. Ref. Interval	Units	Method
BLOOD SUGAR 2 HR. PP				
BLOOD SUGAR P.P.	113	80 - 150	mg/dl	

***** END OF THE REPORT *****



Sample no.

Dr. SONIA KUMARI
 MBBS, MD (PATHOLOGY) Gold medalist

Dr. PRADIP KUMAR
 Consultant (Microbiology)

Dr. NISHA TIWARI
 MBBS, MD (Microbiology)

USER NM SONU

(This is only professional opinion and not the diagnosis, Please correlate clinically)

Q Block South City 11, Sohna Road, Main Sector-47, Gurgaon, Haryana Page 1 of 1
 Ph.: 0124-4900000 (100 Lines) Fax : 0124-2218733 E-mail : parkmedicenters@gmail.com

PARK GROUP OF HOSPITALS : West Delhi • South Delhi • Gurgaon • Karnal • Panipat • Hodal • Ambala • Behror

the **health** care providers the **health** care providers



Cert. No. MC - 4830



Cert. No. H-2016-0305

DEPARTMENT OF PATHOLOGY

Patient Name : Mr. JITESH KUMAR MUCHCHAL
 MR No : 667973
 Age/Sex : 42 Years 2 Months 26 Days / Male
 Type : OPD
 TPA/Corporate : MEDIWHEEL PVT LTD

Bill Date : 17/12/2022
 Reporting Date : 17/12/2022
 Sample ID : 76289
 Bill/Req. No. : 23009491
 Ref Doctor : Dr.RMO

Test	Result	Bio. Ref. Interval	Units	Method
BLOOD SUGAR FASTING				
PLASMA GLUCOSE FASTING	104	H 60 - 100	mg/dl	GOD TRINDERS

***** END OF THE REPORT *****



Sample no.

Dr. SONIA KUMARI
 MBBS, MD (PATHOLOGY) Gold medalist

Dr. PRADIP KUMAR
 Consultant (Microbiology)

Dr. NISHA TIWARI
 MBBS, MD (Microbiology)

USER NM NIKHIL

(This is only professional opinion and not the diagnosis, Please correlate clinically)

Q Block South City 11, Sohna Road, Main Sector-47, Gurgaon, Haryana Page 1 of 1
 Ph.: 0124-4900000 (100 Lines) Fax : 0124-2218733 E-mail : parkmedicenters@gmail.com

PARK GROUP OF HOSPITALS : West Delhi • South Delhi • Gurgaon • Karnal • Panipat • Hodal • Ambala • Behror

the **health** care providers

the **health** care providers



DEPARTMENT OF PATHOLOGY

Patient Name : Mr. JITESH KUMAR MUCHCHAL
MR No : 667973
Age/Sex : 42 Years 2 Months 26 Days / Male
Type : OPD
TPA/Corporate : MEDIWHEEL PVT LTD

Bill Date : 17/12/2022
Reporting Date : 17/12/2022
Sample ID : 76289
Bill/Req. No. : 23009491
Ref Doctor : Dr.RMO

Test	Result	Bio. Ref. Interval	Units	Method
URINE ROUTINE AND MICROSCOPY				
PHYSICAL CHARACTERISTICS				
QUANTITY	30ml	5 - 100	ml	
COLOUR	Pale Yellow	Pale Yellow		Vishal
TURBIDITY	Clear	clear		
SPECIFIC GRAVITY	1.020	1.000-1.030		urinometer
PH	Acidic	Acidic/Alkaline		PH PAPER
CHEMICAL EXAMINATION-1				
UROBILINOGEN	NIL	NIL		Ehrlich
URINE PROTEIN	NIL	NIL	mg/dl	Protein error indicator
GLUCOSE	NIL	NIL	mg/dL	GOD-POD/Benedicts
URINE KETONE	NIL	NIL		SOD.
MICRO.EXAMINATION				
PUS CELL	2-4	0-5	cells/hpf	Microscopic
RED BLOOD CELLS	Nil	0-2	cells/hpf	
EPITHELIAL CELLS	1-2	0-5	cells/hpf	
CASTS	NIL	NIL	/lpf	
CRYSTALS	NIL	NIL	/hpf	
OTHER	NIL			

***** END OF THE REPORT *****



Sample no.

Dr. SONIA KUMARI
MBBS, MD (PATHOLOGY) Gold medalist

Dr. PRADIP KUMAR
Consultant (Microbiology)

Dr. NISHA TIWARI
MBBS, MD (Microbiology)

USER NM SHOAIBPA166

(This is only professional opinion and not the diagnosis, Please correlate clinically)

Q Block South City 11, Sohna Road, Main Sector-47, Gurgaon, Haryana Page 1 of 1
Ph.: 0124-4900000 (100 Lines) Fax : 0124-2218733 E-mail : parkmedicenters@gmail.com

PARK GROUP OF HOSPITALS : West Delhi • South Delhi • Gurgaon • Karnal • Panipat • Hodal • Ambala • Behror

the health care providers

the health care providers

DEPARTMENT OF PATHOLOGY

Patient Name : Mr. JITESH KUMAR MUCHCHAL
MR No : 667973
Age/Sex : 42 Years 2 Months 26 Days / Male
Type : OPD
TPA/Corporate : MEDIWHEEL PVT LTD

Bill Date : 17/12/2022
Reporting Date : 17/12/2022
Sample ID : 76289
Bill/Req. No. : 23009491
Ref Doctor : Dr.RMO

Test	Result	Bio. Ref. Interval	Units	Method
BLOOD GROUPING AND RH FACTOR				
BLOOD GROUP	" A " RH POSITIVE			MATRIX GEL

***** END OF THE REPORT *****



Sample no.

Dr. SONIA KUMARI
MBBS, MD (PATHOLOGY) Gold medalist

Dr. PRADIP KUMAR
Consultant (Microbiology)

Dr. NISHA TIWARI
MBBS, MD (Microbiology)

USER NM SONU

(This is only professional opinion and not the diagnosis, Please correlate clinically)

Q Block South City 11, Sohna Road, Main Sector-47, Gurgaon, Haryana Page 1 of 1
Ph.: 0124-4900000 (100 Lines) Fax : 0124-2218733 E-mail : parkmedicenters@gmail.com

PARK GROUP OF HOSPITALS : West Delhi • South Delhi • Gurgaon • Karnal • Panipat • Hodal • Ambala • Behror

the **health** care providers

the **health** care providers

DEPARTMENT OF PATHOLOGY

Patient Name : Mr. JITESH KUMAR MUCHCHAL
MR No : 667973
Age/Sex : 42 Years 2 Months 26 Days / Male
Type : OPD
TPA/Corporate : MEDIWHEEL PVT LTD

Bill Date : 17/12/2022
Reporting Date : 17/12/2022
Sample ID : 76289
Bill/Req. No. : 23009491
Ref Doctor : Dr.RMO

Test	Result	Bio. Ref. Interval	Units	Method
CBC				
HAEMOGLOBIN	16.0	12 - 16	gm/dL	COLORIMETRY
TOTAL LEUCOCYTE COUNT	7200	4000-11000	/ μ L	ELECTRICAL
DIFFERENTIAL COUNT				
NEUTROPHILS	62	40.0 - 80.0	%	FLOW CYTOMETRY
LYMPHOCYTES	33	20.0 - 40.0	%	FLOW CYTOMETRY
MONOCYTES	03	2.0 - 10.0	%	FLOW CYTOMETRY
EOSINOPHILS	02	0.0 - 5.0	%	FLOW CYTOMETRY
BASOPHILS	00	0.0 - 2.0	%	FLOW CYTOMETRY
RED BLOOD CELL COUNT	4.9	3.5 - 5.5	millions/ μ L	ELECTRICAL
PACKED CELL VOLUME	45.3	35.0 - 50.0	%	ELECTRICAL
MEAN CORPUSCULAR VOLUME	91.8	83 - 101	fL	ELECTRICAL
MEAN CORPUSCULAR HAEMOGLOBIN	32.3	<i>H</i> 27 - 31	Picogrammes	CALCULATED
MEAN CORPUSCULAR HB CONC	35.3	33 - 37	g/dl	CALCULATED
PLATELET COUNT	293	150 - 450	thou/ μ L	ELECTRICAL
RDW	12.7	11.6 - 14.5	%	CALCULATED
SPECIMEN TYPE	WHOLE BLOOD-EDTA			

***** END OF THE REPORT *****



Sample no.

Dr. SONIA KUMARI
MBBS, MD (PATHOLOGY) Gold medalist

Dr. PRADIP KUMAR
Consultant (Microbiology)

Dr. NISHA TIWARI
MBBS, MD (Microbiology)

USER NM NIKHIL

(This is only professional opinion and not the diagnosis, Please correlate clinically)

Q Block South City 11, Sohna Road, Main Sector-47, Gurgaon, Haryana Page 1 of 1
Ph.: 0124-4900000 (100 Lines) Fax : 0124-2218733 E-mail : parkmedicenters@gmail.com

PARK GROUP OF HOSPITALS : West Delhi • South Delhi • Gurgaon • Karnal • Panipat • Hodal • Ambala • Behror

the **health** care providers

the **health** care providers



DEPARTMENT OF PATHOLOGY

Patient Name : Mr. JITESH KUMAR MUCHCHAL
MR No : 667973
Age/Sex : 42 Years 2 Months 26 Days / Male
Type : OPD
TPA/Corporate : MEDIWHEEL PVT LTD

Bill Date : 17/12/2022
Reporting Date : 17/12/2022
Sample ID : 76289
Bill/Req. No. : 23009491
Ref Doctor : Dr.RMO

Test	Result	Bio. Ref. Interval	Units	Method
ESR (WESTERGREN)				
E.S.R. - II HR.	25		mm II Hr.	Westergren

***** END OF THE REPORT *****



Sample no.

Dr. SONIA KUMARI
MBBS, MD (PATHOLOGY) Gold medalist

Dr. PRADIP KUMAR
Consultant (Microbiology)

Dr. NISHA TIWARI
MBBS, MD (Microbiology)

USER NM NIKHIL

(This is only professional opinion and not the diagnosis, Please correlate clinically)

Q Block South City 11, Sohna Road, Main Sector-47, Gurgaon, Haryana
Ph.: 0124-4900000 (100 Lines) Fax : 0124-2218733 E-mail : parkmedicenters@gmail.com

Page 1 of 1

PARK GROUP OF HOSPITALS : West Delhi • South Delhi • Gurgaon • Karnal • Panipat • Hodal • Ambala • Behror

the **health** care providers

the **health** care providers



DEPARTMENT OF PATHOLOGY

Patient Name : Mr. JITESH KUMAR MUCHCHAL
MR No : 667973
Age/Sex : 42 Years 2 Months 26 Days / Male
Type : OPD
TPA/Corporate : MEDIWHEEL PVT LTD

Bill Date : 17/12/2022
Reporting Date : 19/12/2022
Sample ID : 76289
Bill/Req. No. : 23009491
Ref Doctor : Dr.RMO

Test	Result	Bio. Ref. Interval	Units	Method
------	--------	--------------------	-------	--------

URINE C/S

NAME OF SPECIMEN	URINE			
ORGANISM IDENTIFIED	NO GROWTH SEEN IN CULTURE AFTER 48 HRS OF INCUBATION AT 37 C DEGREE.			Aerobic culture
Method :				
Note :				

***** END OF THE REPORT *****



Sample no.

Dr. SONIA KUMARI
MBBS, MD (PATHOLOGY) Gold medalist

Dr. PRADIP KUMAR
Consultant (Microbiology)

Dr. NISHA TIWARI
MBBS, MD (Microbiology)

USER NM SHOAIBPA166

(This is only professional opinion and not the diagnosis, Please correlate clinically)

Q Block South City 11, Sohna Road, Main Sector-47, Gurgaon, Haryana Page 1 of 1
Ph.: 0124-4900000 (100 Lines) Fax : 0124-2218733 E-mail : parkmedicenters@gmail.com

PARK GROUP OF HOSPITALS : West Delhi • South Delhi • Gurgaon • Karnal • Panipat • Hodal • Ambala • Behror

the health care providers

the health care providers



DEPARTMENT OF PATHOLOGY

Patient Name : Mr. JITESH KUMAR MUCHCHAL
MR No : 667973
Age/Sex : 42 Years 2 Months 26 Days / Male
Type : OPD
TPA/Corporate : MEDIWHEEL PVT LTD

Bill Date : 17/12/2022
Reporting Date : 17/12/2022
Sample ID : 76289
Bill/Req. No. : 23009491
Ref Doctor : Dr.RMO

Test	Result	Bio. Ref. Interval	Units
THYROID PROFILIE			
TRI-IODOTHYRONINE (T3)	1.21	0.60 - 1.81	ng/ml
THYROXINE (T4)	11.8	5.01 - 12.45	µg/dL
THYROID STIMULATING HORMONE (TSH)	2.66	0.5-5.50	µIU/ml
SPECIMEN TYPE	SERUM		

Method : chemiluminescent immunoassay

Note : Clinical Significance:

Thyroid function tests (TFTs) is a collective term for blood tests used to check the function of the thyroid. TFTs may be requested if a patient is thought to suffer from hyperthyroidism (overactive thyroid) or hypothyroidism (underactive thyroid), or to monitor the effectiveness of either thyroid-suppression or hormone replacement therapy. It is also requested routinely in conditions linked to thyroid disease, such as atrial fibrillation and anxiety disorder. A TFT panel typically includes thyroid hormones such as thyroid-stimulating hormone (TSH, thyrotropin) and thyroxine (T4), and triiodothyronine (T3) depending on local laboratory policy.

Note: Please correlate with clinical condition

***** END OF THE REPORT *****



Dr. NALANDA BUKTARE
MD (Pathology)

Dr. PRADIP KUMAR
Consultant (Microbiology)

Dr. NISHA TIWARI
MBBS, MD (Microbiology)

USER NM DINESH

(This is only professional opinion and not the diagnosis, Please correlate clinically)

Q Block South City 11, Sohna Road, Main Sector-47, Gurgaon, Haryana
Ph.: 0124-4900000 (100 Lines) Fax : 0124-2218733 E-mail : parkmedicenters@gmail.com

PARK GROUP OF HOSPITALS : West Delhi • South Delhi • Gurgaon • Karnal • Panipat • Hodal • Ambala • Behror

the **health** care providers

the **health** care providers

DEPARTMENT OF PATHOLOGY

Patient Name : Mr. JITESH KUMAR MUCHCHAL
 MR No : 667973
 Age/Sex : 42 Years 2 Months 26 Days / Male
 Type : OPD
 TPA/Corporate : MEDIWHEEL PVT LTD

Bill Date : 17/12/2022
 Reporting Date : 17/12/2022
 Sample ID : 76289
 Bill/Req. No. : 23009491
 Ref Doctor : Dr.RMO

Test	Result	Bio. Ref. Interval	Units	Method
LFT (LIVER FUNCTION TEST)				
LFT				
TOTAL BILIRUBIN	1.2	0 - 1.2	mg/dL	DIAZO
DIRECT BILIRUBIN	0.4	0 - 0.4	mg/dL	DIAZO
INDIRECT BILIRUBIN	0.8	<i>H</i> 0.10 - 0.6	mg/dL	CALCULATED
SGOT (AST)	21	0 - 45	U/L	IFCC WITHOUT
SGPT (ALT)	28	0 - 45	U/L	IFCC WITHOUT
ALKALINE PHOSPHATASE	77	30 - 170	IU/L	MODIFIED IFCC
TOTAL PROTEINS	6.4	6.4 - 8.0	g/dL	BIURET
ALBUMIN	4.2	3.3 - 5.5	g/dL	BCG DYE
GLOBULIN	2.2	<i>L</i> 2.3 - 4.5	g/dL	CALCULATED
A/G RATIO	1.91	1.1 - 2.2		CALCULATED
SPECIMEN TYPE	SERUM			

***** END OF THE REPORT *****



Sample no.

Dr. SONIA KUMARI
 MBBS, MD (PATHOLOGY) Gold medalist

Dr. PRADIP KUMAR
 Consultant (Microbiology)

Dr. NISHA TIWARI
 MBBS, MD (Microbiology)

USER NM NIKHIL

(This is only professional opinion and not the diagnosis, Please correlate clinically)

Q Block South City 11, Sohna Road, Main Sector-47, Gurgaon, Haryana Page 1 of 1
 Ph.: 0124-4900000 (100 Lines) Fax : 0124-2218733 E-mail : parkmedicenters@gmail.com

PARK GROUP OF HOSPITALS : West Delhi • South Delhi • Gurgaon • Karnal • Panipat • Hodal • Ambala • Behror

the **health** care providers

the **health** care providers



DEPARTMENT OF RADIOLOGY

Patient Name	Mr JITESH KUMAR MUCHCHAL	Billed Date	: 17/12/2022	8.50 AM
Reg No	667973	Reported Date	: 17/12/2022	
Age/Sex	42 Years 2 Months 26Days / Male	Req. No.	: 23009491	
Type	OPD	Consultant Doctor	: Dr. RMO	

USG WHOLE ABDOMEN

The Real time, B mode, gray scale sonography of the abdominal organs was performed.

LIVER : The liver is normal in size 12.7cm **with fatty infiltration**. No evidence of any focal lesion. IHBR is not dilated.

GALL BLADDER :The gall bladder is well distended. No evidence any calculus or mass seen.No evidence of pericholecystic fluid is seen.

BILE DUCT :The common bile duct is normal in caliber. No evidence of calculus is noted in common bile duct.

SPLEEN :The spleen is normal in size 9.8 cm and shape.Its echotexture is homogeneous.No evidence of focal lesion is noted.

PANCREAS :The pancreas is normal in size, shape, contours and echotexture.No evidence of solid or cystic mass lesion is noted.MPD is not dilated. No evidence of peripancreatic collection.

KIDNEYS :The bilateral kidneys are normal in size and echotexture. Cortico-medullary differentiation is maintained.There is no evidence of obvious calculus or hydronephrosis.

URINARY BLADDER :The urinary bladder is minimal distended.Wall thickness within normal limits.No evidence of calculus is seen.No evidence of mass or diverticulum is noted.

PROSTATE: Prostate appears normal in shape, size and echotexture. It measures 22.5 CC.

No evidence of ascites or interbowel free fluid is seen.

No evidence of obvious retroperitoneal or mesentric lymphadenopathy is seen.

Bowel loop distended with gas.

IMPRESSION- Fatty liver grade-I

To be correlated clinically
Dr. ANSHU K. SHARMA
MBBS, MD
CONSULTANT RADIOLOGIST

Dr. MANJEET SEHRAWAT
MBBS, MD, PDCC
CONSULTANT RADIOLOGIST

Dr. NEENA SIKKA
MBBS, DNB
CONSULTANT RADIOLOGIST



(This is only professional opinion and not the diagnosis, Please correlate clinically)

Q Block South City 11, Sohna Road, Main Sector-47, Gurgaon, Haryana

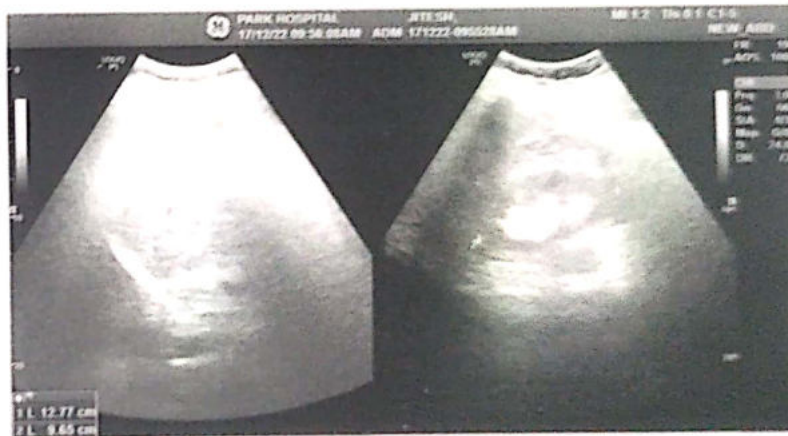
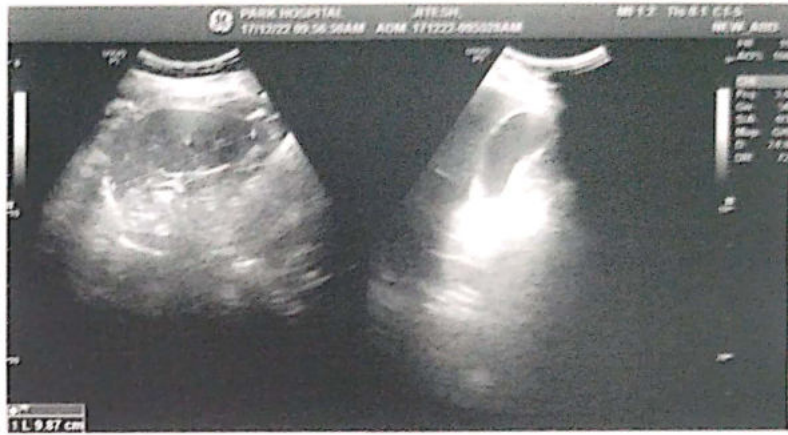
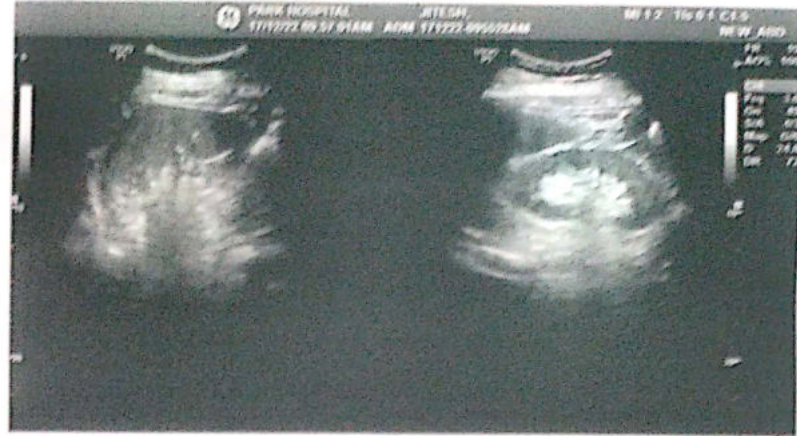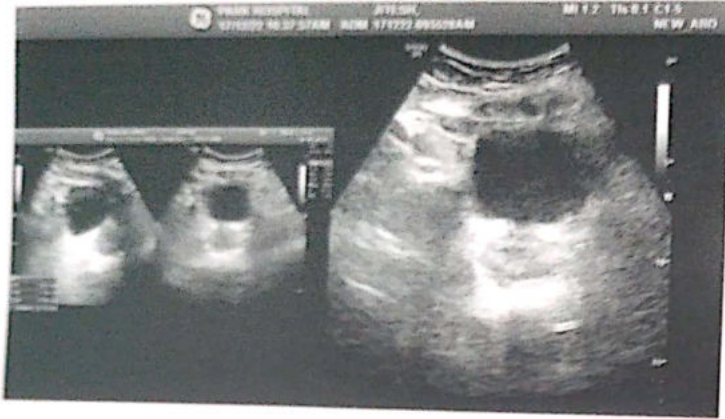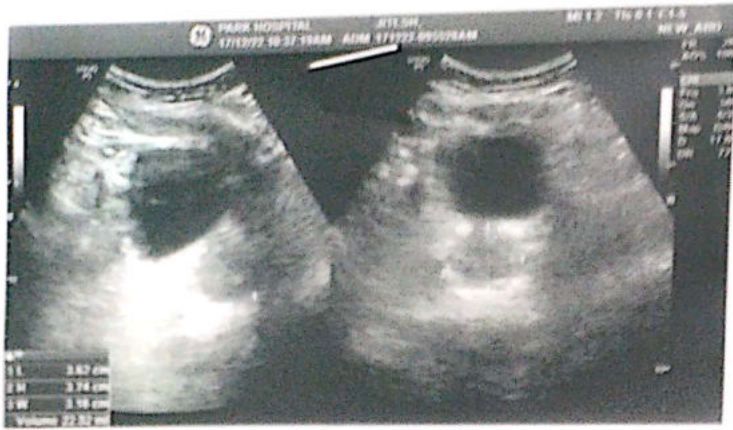
Ph.: 0124-4900000 (100 Lines) Fax : 0124-2218733 E-mail : parkmedicenters@gmail.com

PARK GROUP OF HOSPITALS : West Delhi • South Delhi • Gurgaon • Karnal • Panipat • Hodal • Ambala • Behror

the health care providers

the health care providers







DEPARTMENT OF PATHOLOGY

Patient Name : Mr. JITESH KUMAR MUCHCHAL
MR No : 667973
Age/Sex : 42 Years 2 Months 26 Days / Male
Type : OPD
TPA/Corporate : MEDIWHEEL PVT LTD

Bill Date : 17/12/2022
Reporting Date : 20/12/2022
Sample ID : 76289
Bill/Req. No. : 23009491
Ref Doctor : Dr.RMO

Test	Result	Bio. Ref. Interval	Units	Method
PSA TOTAL				
PROSTATE SPECIFIC ANTIGEN(PSA)	0.59	0.57 - 4.0	ng/ml	Chemiluminescence
SPECIMEN TYPE	SERUM			
Method : chemiluminescent immunoassay				

Note : Clinical Use: -

An aid in the early detection of Prostate cancer in Male. Follow up and amazement of Prostate cancer patients. Detect metastatic or persistent disease in patients following surgical or medical treatment of Prostate cancer

Note: -

False negative / positive results are observed in patients receiving mouse monoclonal antibodies for diagnosis or therapy. PSA levels may appear consistently elevated / depressed due to the interference by heterophilic antibodies & non-specific protein binding. PSA values regardless of levels should not be interpreted as absolute evidence of the presence or absence of disease. All values should be correlated with clinical findings and results of other investigations.

***** END OF THE REPORT *****



Sample no.

Dr. SONIA KUMARI
MBBS, MD (PATHOLOGY) Gold medalist

Dr. PRADIP KUMAR
Consultant (Microbiology)

Dr. NISHA TIWARI
MBBS, MD (Microbiology)

USER NM DINESH

(This is only professional opinion and not the diagnosis, Please correlate clinically)

Q Block South City 11, Sohna Road, Main Sector-47, Gurgaon, Haryana
Ph.: 0124-49000000 (100 Lines) Fax : 0124-2218733 E-mail : parkmedicenters@gmail.com

PARK GROUP OF HOSPITALS : SOUTH DELHI • WEST DELHI • GURUGRAMA • FARIDABAD • PANIPAT • SONIPAT

the health care providers

the health care providers





NAME	: MR. JITESH KUMAR MUCHCHAL	DATE	: 17 / 12 / 2022
Age Sex	: 42 Years / Male	Inpatient No	:
PERFORMED BY	: Dr. ELA MADAAN	Bill no.	: 23009491

TRANS THORACIC ECHO CARDIOGRAPHY REPORT

MITRAL VALVE

Morphology AML: Normal / Thickening / Calcification / Flutter / Vegetation / Non significant Prolapse / SAM
PML: Normal / Thickening / Calcification / Prolapse / Paradoxical Motion / Fixed.
Subvalvular deformity: Present / Absent

Doppler

Normal / Abnormal
Mitral Stenosis Present / Absent
Mitral Regurgitation; Absent / Normal / Mild / Trace / Moderate / Severe.

TRICUSPID VALVE

Morphology Normal / Atresia / Thickening / Calcification / Prolapse / Vegetation / Doming.

Doppler

Normal / Abnormal
Tricuspid Stenosis : Present / Absent.
Tricuspid Regurgitation: Absent / Mild / Trace / Moderate

PULMONARY VALVE

Morphology Normal / Atresia / Thickening / Calcified / Doming / Vegetation.

Doppler

Normal / Abnormal.
Pulmonary stenosis: Present / Absent
Pulmonary regurgitation: Present / Absent

AORTIC VALVE

Morphology Normal / Thickened / Mildly / Calcified / Flutter / Vegetation / Restricted / Opening
No. of Cusps 1 / 2 / 3 / 4

Doppler

Normal / Abnormal
Aortic Stenosis : Present / Absent
Aortic regurgitation : Present / Absent / Mild / Trace

(This is only professional opinion and not the diagnosis, Please correlate clinically)

Q Block South City 11, Sohna Road, Main Sector-47, Gurgaon, Haryana

Ph.: 0124-4900000 (100 Lines) Fax : 0124-2218733 E-mail : parkmedicenters@gmail.com

PARK GROUP OF HOSPITALS : West Delhi • South Delhi • Gurgaon • Karnal • Panipat • Hodal • Ambala • Behror

the **health** care providers

the **health** care providers



Measurements

IVSD : 0.8cm
LVID : 5.0cm
LVPW : 0.9cm
EF : 56%

Normal Values

(0.6-1.1cm)
(3.7-5.6cm)
(0.6-1.1cm)
(55% - 80%)

Measurements

LA : 2.9cm
LVOT : 1.3cm
AORTA : 2.8cm
IVSmotion :

Normal Value

(1.9-4.0cm)
(2.0-3.7cm)
Normal / Flat /
Paradoxical

Any Other

CHAMBERS:-

LV **Normal** / Enlarged / **Clear** / Thrombus / .
Contraction Normal LV shows concentric LVH, no gradient across LVOT / Inetic / Intra capillary
Regional wall motion abnormality: **Absent** / Present
LA **Normal** / Enlarged / Clear / Thrombus / Myxoma; **LAA: Clear** / Thrombus
RA **Normal** / **Clear** / Thrombus, Dilated.
RV **Normal** / Mildly Dilated / Enlarged / **Clear** / Thrombus / Hypertrophied/
PERICARDIUM **Normal** / Thickening / Calcification / Effusion.

COMMENTS & SUMMARY:-

- All Cardiac Chamber Dimensions are within normal limits.
- Global LVEF 56%
- No RWMA
- NORMAL LV FUNCTION
- TRACE MR
- NO AR / NO AS
- MILD TR
- GOOD RV FUNCTION
- IAS/IVS. No Flow seen across IAS/IVS.
- No Thrombus/Mass in any chamber.
- No Pericardial Effusion.

Please correlate clinically

Dr. ELA MADAAN
MBBS, PGDCC
Fellowship in non Invasive
Cardiology

Dr. NAVJEET SINGH
M.D.(Medicine) D.M (Cardiology).
HOD & Director Interventional cardiology.

(This is only professional opinion and not the diagnosis, Please correlate clinically)

Q Block South City 11, Sohna Road, Main Sector-47, Gurgaon, Haryana
Ph.: 0124-4900000 (100 Lines) Fax : 0124-2218733 E-mail : parkmedicenters@gmail.com

PARK GROUP OF HOSPITALS : West Delhi • South Delhi • Gurgaon • Karnal • Panipat • Hodal • Ambala • Behror

the **health** care providers the **health** care providers



for health check up

cl0 polyphagia

Family H10 T2DM.

Chief Complaints :

01E

Present Illness :

Patient is insulin

P° J° C°

PR

BP - 120/80 mm Hg.

Chest - B/L vesicular B/s

aus - S1 S2 (+)

Past History :

Adv

Drug Allergies : (if any)

Treatment :

1. Rami with reports

[Signature]

Vitals :
BP 120/80
wt - 91.2 kg
HT. ~~205~~ 5.3 ft

Investigation :



Dental

Vitals :

Chief Complaints :

Routine dental checkup

H/O Present Illness :

O/e • stains ++, Calculus ++

Past History :

- Elli's class I in 45
- Generalised Attrition

Investigation :

Drug Allergies : (if any)

Treatment :

Advise

scaling and polishing

Composite restoration per tooth

Occlusal night guard



Gurgaon

Q Block South City 11, Sohna Road, Main Sector-47, Gurgaon, Haryana Ph.: 0124-49000000 Fax : 0124-2218733
E-mail : parkmedicenters@gmail.com

• West Delhi • South Delhi • Faridabad • Panipat • Karnal





DEPARTMENT OF RADIOLOGY

Patient Name	Mr JITESH KUMAR MUCHCHAL	Billed Date	: 17/12/2022	8 50 AM
Reg No	667973	Reported Date	: 17/12/2022	
Age/Sex	42 Years 2 Months 26Days / Male	Req. No.	: 23009491	
Type	OPD	Consultant Doctor	: Dr. RMO	

X-RAY CHEST AP/PA

X-RAY CHEST P.A. VIEW

Bilateral lungs appears normal.

No focal lung lesion seen.

No evidence of free fluid is seen.

Both hila are normal in size, have equal density and bear normal relationship.

The heart and trachea are central in position and no mediastinal abnormality is visible.

The cardiac size is normal for patient age and view.

The domes of the diaphragms are normal in position, and show smooth outline.

To be correlated clinically



Dr. ANSHU K. SHARMA
MBBS, MD
CONSULTANT RADIOLOGIST

Dr. MANJEET SEHRAWAT
MBBS, MD, PDCC
CONSULTANT RADIOLOGIST

Dr. NEENA SIKKA
MBBS, DNB
CONSULTANT RADIOLOGIST

(This is only professional opinion and not the diagnosis, Please correlate clinically)

Q Block South City 11, Sohna Road, Main Sector-47, Gurgaon, Haryana

Ph.: 0124-4900000 (100 Lines) Fax : 0124-2218733 E-mail : parkmedicenters@gmail.com

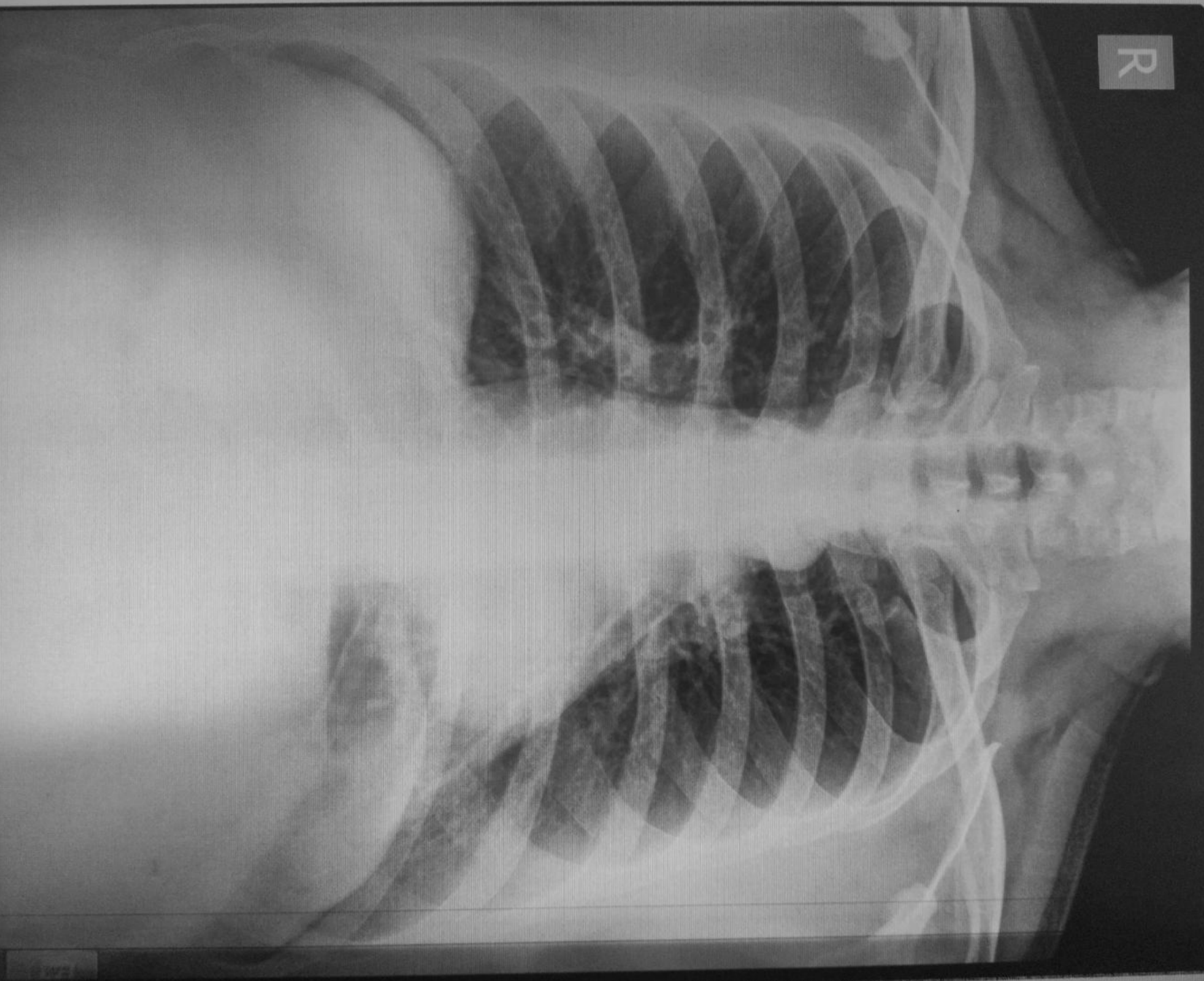
PARK GROUP OF HOSPITALS : West Delhi • South Delhi • Gurgaon • Karnal • Panipat • Hodal • Ambala • Behror

the **health** care providers

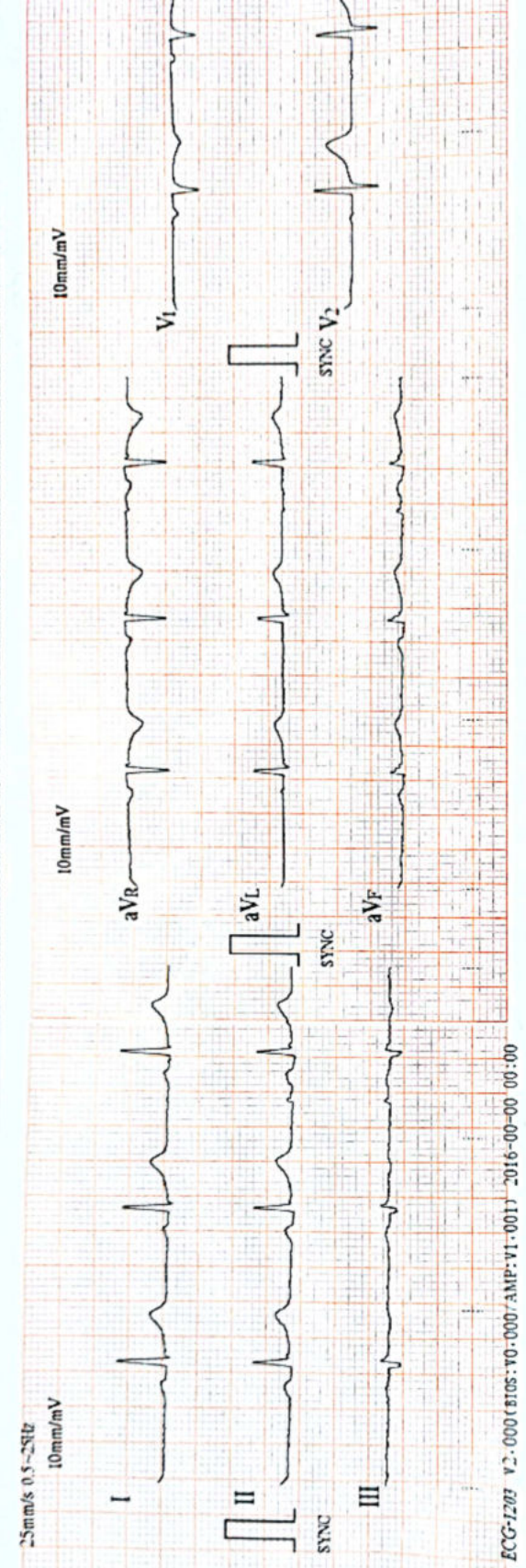
the **health** care providers



R

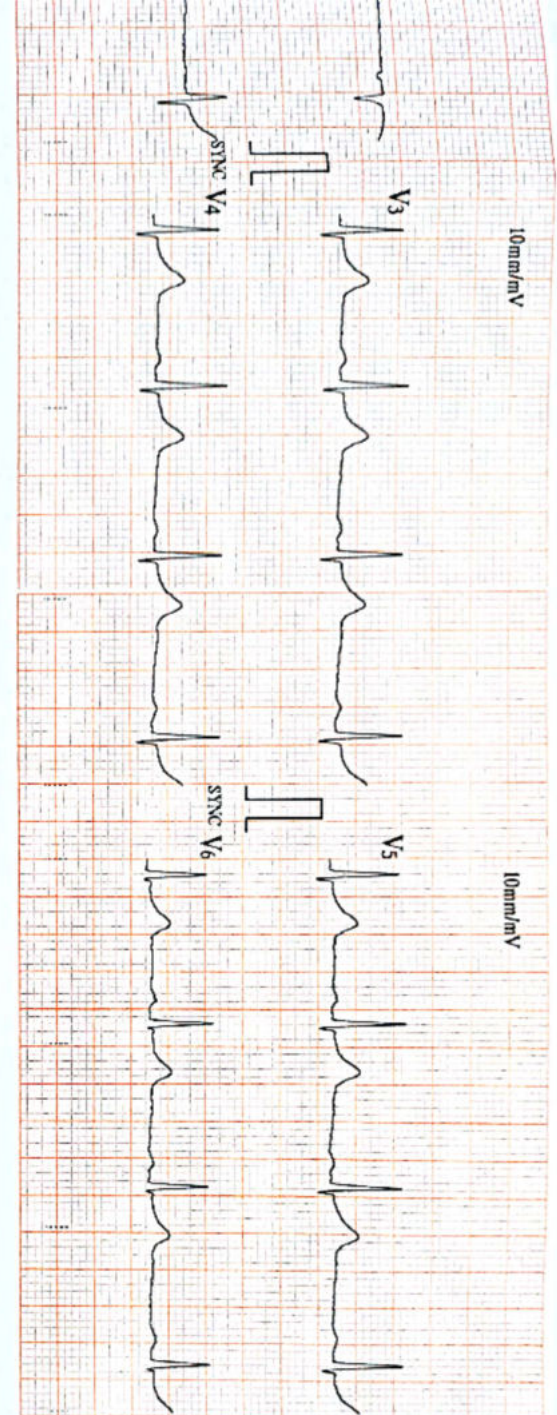


JITESH KUMAR 42Y Male
Chest PA
REO-2300949112/17/2022 9:19:33 AM
PARK HOSPITAL, SOUTH CITY II, GURGAON, HARYANA



ECG-1202 V2.000/ST03/10:00/AMP:V1-001/2016-00-00 00:00

25mm/s 0.50 s/mV
10mm/mV



Unconfirmed Report Verified by:

ID :	0001	HR :	66	bpm
Name:	DEEPA RAMONA	R-R :	902	ms
Sex :	male	P-R :	173	ms
Age :	42	QRS :	74	ms
		QT/QTc :	373/392	ms
		P/QRS/T :	57/27/28	°
		RV5/SV1 :	0.960/0.390	mV
		RV5+SV1 :	1.350	mV

- Sinus Rhythm
- Left Atrial Enlargement
- Abnormal Q
- Marked Counter Clockwise Rotation
- Mild Left Axis Deviation