



Reg.No: 659/25/01/2021

LIFE LINE

Multispeciality Hospital Maternity Home & ICU

Plot No. 20, Gut No. 103, Opp. Surya Lawns Beed Bypass, Devlai, Aurangabad. Mob.: 9067028989, 9067038989

Rx

Date 15/10/2023

Medical Fitness Certificate

This is to certify that below mentioned candidate has been examined on medical parameters and found free from contagious diseases there by medically fit for work. Final investigation reports will be forwarded to you at the earliest.

1. Name	: KIRAN KOTKAR
2. Age	: 40Yrs.
3. Sex	: MALE
4. Physical Examination	: Normal
5. Systemic Examination	: Normal
6. Ophthalmic Examination	: Normal
7 Vision /Colour Vision	: i) Normal - Normal
ii) Colour Blindness	: Normal
8 E C G	: Normal
9 USG	: Normal
10 X RAY CHEST	: Normal
11 2D EHCO	: Normal

Remark- **Person is fit to work in Company**

DR. SACHIN BANGAR
MD, DNB (MEDI.)
No. 02/08/3045

Dr. SACHIN BANGAR

Medical officer



LIFE LINE

Multispeciality Hospital Maternity Home & ICU

Plot No. 20, Gut No. 103, Opp. Surya Lawns Beed Bypass, Devlai, Aurangabad. Mob.: 9067028989, 9067038989

Rx

NAME: KIRAN KOTKAR
AGE/SEX: 40/MALE

DATE: 15/10/2023

PRE-EMPLOYMENT HEALTH CHECKUP 2023

HISTORY :- Nil

ADDICATION: - Nil

GENERAL MEDICAL EXAMINATION

1. Physical Examination

Height : 169cms

Weight : 70Kg

Pulse : 80 Min

B.P. : 120/80mmHg

Skin Examination- Any diseases :-No

Oral Examination Hygiene- Any diseases :-No

ENT Examination- Any diseases :-No

2. SYSTEMIC EXMINATION

a) Abdomen :- Soft, No Organomegaly

b) CVS :- Normal Heart sound

c) Respiratory System :- Normal Air Entry Both Lungs

d) Nervous System :- Normal Clinically

INVESTIGATIONS (POSITIVE FINDING)

Pathological investigation :- (Reports Enclosed) Annexure

Vision :- (Reports Enclosed) Annexure

Color Vision :- (Reports Enclosed) Annexure

E.C.G :- (Reports Enclosed) Annexure

X-Ray Chest :- (Reports Enclosed) Annexure

USG :- (Reports Enclosed) Annexure

2D-EHCO :- (Reports Enclosed) Annexure

Fit for employment

DR. SACHIN BANGAR
MD, MB (MEDI.)
R. No. 02/08/3045
Medical Examiner



LIFE LINE

Multispeciality Hospital Maternity Home & ICU

Plot No. 20, Gut No. 103, Opp. Surya Lawns Beed Bypass, Devlai, Aurangabad. Mob.: 9067028989, 9067038989

Rx

OPHTHALMIC EXAMINATION

NAME OF EMPLOYEE: KIRAN KOTKAR

AGE: 40/MALE

DATE OF EXAMINATION: -15/10/2023

		RE (RIGHT EYE)	LE (LEFT EYE)
NEAR VISION	WITH GLASSES		
	WITH OUT GLASSES	N/6	N/6
DISTANCE VISION	WITH GLASSES		
	WITH OUT GLASSES	N/6	N/6

COLOUR VISION: - NORMAL

DR. SACHIN BANGAR
(SINGNATURE)
M.B.B.S. DNB (MEDI.)
Reg. No. 5178/3045



LIFE LINE

Multispeciality Hospital Maternity Home & ICU

Plot No. 20, Gut No. 103, Opp. Surya Lawns Beed Bypass, Devlai, Aurangabad. Mob.: 9067028989, 9067038989

Rx

NAME OF THE PATIENT: KIRAN KOTKAR

AGE: 40/MALE

DATE: -15/10/2023

REPORT:

Condition of Lung pleura: WNL

Heart & Aorta:

Transverse Diameter of Heart: WNL


Transverse Diameter of Aortic Arch: WNL

Cardio-Thoracic Ratio: WNL

Any changes of Arteriosclerosis or Calcification of Aorta etc.
WNL

CONCLUSION & REMARK:

X-RAY CHEST IS WITH IN NORMAL LIMITS.


DR. SACHIN BANGAR
MD, DNB (MEDI.)
Reg. No. 01/08/3045
Medical Examiner



LIFE LINE

Multispeciality Hospital Maternity Home & ICU

Plot No. 20, Gut No. 103, Opp. Surya Lawns Beed Bypass, Devlai, Aurangabad. Mob.: 9067028989, 9067038989

Rx

Patient Name	KIRAN KOTKAR	Date: 15/10/2023
Age / Sex	40Yrs /M	Performed By: DR. VIVEK JAJU

USG ABDOMEN AND PELVIS

LIVER: Liver is normal in size measuring 13.5 cm & shows normal echo texture. No evidence of any diffuse or focal pathology. Intrahepatic biliary radicals are not dilated. Portal vein & CBD are normal in diameter.

GALL BLADDER: Is well-distended. No evidence of calculus or mass. Gall bladder wall thickness is normal.

PANCREAS: is normal in size and echo texture. Pancreatic duct is not dilated.

SPLEEN: Spleen is normal in size measuring 9.2 cm & shows normal echo texture. No evidence of any focal lesion.

KIDNEYS:

Right Kidney measures 9.2 x 4.6 cm in size.

Left Kidney measures 9.5 x 5.2 cm in size.

Both kidneys are normal in size and echo texture. Corticomedullary differentiation is normal. No evidence of calculus or hydronephrosis on both sides.

Urinary Bladder is Well-distended.

Prostate is normal in size and echo texture.

IVC and aorta are normal. No Para aortic lymphadenopathy.

No evidence of any intra- abdominal or pelvic mass.

No e/o any free fluid in abdomen and pelvis.

High resolution USG was performed with high frequency linear transducer, which reveals normal bowel loops and mesenteric structures. No evidence of significant mesenteric lymphadenopathy.

IMPRESSION:

No significant abnormality detected.



Vigilance Diagnostics
PATHOLOGY LABORATORY
LIFE LINE MULTISPECIALITY HOSPITAL

Plot No. 20, Gut No. 103, Opp. Surya Lawns,
Beed By Pass Road, Deolai, Aurangabad

Accession No : 2023101513

Patient Name : Mr. KIRAN KOTKAR

Age / Sex : 40 Year/Male

Referred by : LIFELINE MULTISPECIALITY HOSPITAL

Registered On : 15/10/2023

Reporting On : 15/10/2023


Printed On : 15/10/2023



Test Name	Patient value	Reference Range	Unit
HEMATOLOGY			
COMPLETE BLOOD COUNTS			
Hb	14.2		
RBC COUNT	4.69	13.0 - 18.0	g/dL
TLC	8200	4.50 - 5.50	10 ⁶ /ul
RED CELL ABSOLUTE VALUES			
HCT	45.3	4000 - 10000	10 ³ /ul
MCV	96.59	35.0 - 60.0	%
MCH	30.28	83.0 - 101.0	fL
MCHC	31.35	27.0 - 32.0	pg
DLC (DIFFERENTIAL LEUKOCYTE COUNT)			
NEUTROPHILS	63	31.5 - 34.5	g/dL
LYMPHOCYTES	30	40.0 - 80.0	%
EOSINOPHILS	03	20.0 - 40.0	%
MONOCYTES	04	2.0 - 6.0	%
BASOPHILS	0	1.0 - 8.0	%
PLATELET COUNT			
PLATELET COUNT	214000	< 1.0	%
E.S.R	15	150000 - 450000	10 ³ /ul
		1 - 20	MM/HRS

Kindly Correlate Clinically !
Thanks for referral !

----- End of Report -----


Dr. Shubhangi Chaudhari
M.D Pathology
Reg No. 2012/08/2421



Vigilance Diagnostics

PATHOLOGY LABORATORY

LIFE LINE MULTISPECIALITY HOSPITAL

Plot No. 20, Gut No. 103, Opp. Surya Lawns,
Beed By Pass Road, Deolai, Aurangabad

Accession No : 2023101513

Patient Name : Mr. KIRAN KOTKAR

Age / Sex : 40 Year/Male

Referred by : LIFELINE MULTISPECIALITY HOSPITAL

Registered On : 15/10/2023

Reporting On : 15/10/2023

Printed On : 15/10/2023



Test Name	Patient value	Reference Range	Unit
-----------	---------------	-----------------	------

HEMATOLOGY

BLOOD GROUP

BLOOD GROUP

"A" RH POSITIVE

Note : Grouping & Cross matching is absolutely essential prior to blood transfusion patient identity as disclosed by patients himself/herself.

BIOCHEMISTRY

BLOOD SUGAR

BLOOD SUGAR (FASTING)

86.23

70 - 110

mg/dl

BLOOD SUGAR (Post Meal)

102.74

70 - 140

mg/dl

Kindly Correlate Clinically !

Thanks for referral !

Dr. Shubhangi Chaudhari

M.D Pathology

Reg No. 2012/08/2421

----- End of Report -----



Vigilance Diagnostics

PATHOLOGY LABORATORY

LIFE LINE MULTISPECIALITY HOSPITAL

Plot No. 20, Gut No. 103, Opp. Surya Lawns,
Beed By Pass Road, Deolai, Aurangabad

Accession No : 2023101513

Patient Name : Mr. KIRAN KOTKAR

Age / Sex : 40 Year/Male

Referred by : LIFELINE MULTISPECIALITY HOSPITAL

Registered On : 15/10/2023


Reporting On : 15/10/2023

Printed On : 15/10/2023



Test Name	Patient value	Reference Range	Unit
BIOCHEMISTRY			
LIVER FUNCTION TEST			
BILIRUBIN TOTAL	0.86	0.1 - 1.2	mg/dl
DIRECT	0.21	0.0 - 0.3	mg/dl
INDIRECT	0.65	0.1 - 1.0	mg/dl
SGOT	20.14	10 - 40	mg/dl
SGPT	23.44	06 - 40	mg/dl
ALKALINE PHOSPHATASE	104.63	42 - 141	g/dl
TOTAL PROTINE	6.78	6 - 8	g/dl
ALBUMIN	3.74	3.5 - 4.8	g/dl
GLOBULIN	3.04	2.8 - 3.3	g/dl
Y-Glutamyl Transpeptidase	25.30	0 - 55	U/L

Kindly Correlate Clinically !
Thanks for referral !


Dr. Shubhangi Chaudhari
M.D Pathology
Reg No. 2012/08/2421

----- End of Report -----



Vigilance Diagnostics

PATHOLOGY LABORATORY

LIFE LINE MULTISPECIALITY HOSPITAL

Plot No. 20, Gut No. 103, Opp. Surya Lawns,
Beed By Pass Road, Deolai, Aurangabad

Accession No : 2023101513

Patient Name : Mr. KIRAN KOTKAR

Age / Sex : 40 Year/Male

Referred by : LIFELINE MULTISPECIALITY HOSPITAL

Registered On : 15/10/2023

Reporting On : 15/10/2023

Printed On : 15/10/2023




GLYCOSYLATED HAEMOGLOBIN

Test Name	Patient Value	Reference Range	Unit
Glycosylated Haemoglobin (HbA1c)	6.01	Non-Diabetic : Upto 6%, Pre-Diabetic : 6.0-6.5%, Diabetic : >6.5%, Good Control : 6.5-7.0%, Moderate Control : 7-8%, Poor Control : >8.0%	%

----- END OF REPORT -----

Kindly Correlate Clinically !

Thanks for referral !


Dr. Shubhangi Chaudhari
M.D Pathology
Reg No. 2012/08/2421



Vigilance Diagnostics
PATHOLOGY LABORATORY
LIFE LINE MULTISPECIALITY HOSPITAL

Plot No. 20, Gut No. 103, Opp. Surya Lawns,
 Beed By Pass Road, Deolai, Aurangabad

Accession No : 2023101513

Patient Name : Mr. KIRAN KOTKAR

Age / Sex : 40 Year/Male

Referred by : LIFELINE MULTISPECIALITY HOSPITAL

Registered On : 15/10/2023

Reporting On : 15/10/2023

Printed On : 15/10/2023



THYROID PROFILE

Test Name	Patient Value	Reference Range	Unit
T3	0.96	0.58 - 1.59	nmo
T4	8.66	4.87 - 11.92	nmo
TSH	1.01	0.27 - 4.20	uIU/ml

Interpretation(s)

TSH stimulates the production and secretion of the metabolically active thyroid hormones, thyroxine (T4) and triiodothyronine (T3) by interacting with a specific receptor on the thyroid cell surface. The synthesis and secretion of TSH is stimulated by Thyrotropin releasing hormone (TRH), the hypothalamic tripeptide in response to low levels of circulating thyroid hormones. Elevated levels of T3 and T4 suppress the production of TSH a classic negative feedback mechanism. Failure at any level of regulation of the hypothalamic-pituitary-thyroid axis will result in either underproduction (hypothyroidism) or overproduction (hyperthyroidism) of T4 and /or T3.

Clinical Condition T3 Levels T4 Levels TSH level

Primary hypothyroidism	Reduced	Reduced	Increased (Significantly)
Subclinical Hypothyroidism	Normal or Low	Normal	Normal or Low Normal High
Primary hyperthyroidism	Increased	Increased	Reduced (at times undetectable)
Subclinical Hyperthyroidism	Normal or High	Normal	Normal or High Normal Reduced

-----END OF REPORT-----

Kindly Correlate Clinically !

Thanks for referral !

Dr. Shubhangi Chaudhari
 M.D Pathology
 Reg No. 2012/08/2421



Vigilance Diagnostics

PATHOLOGY LABORATORY

LIFE LINE MULTISPECIALITY HOSPITAL

Plot No. 20, Gut No. 103, Opp. Surya Lawns,
Beed By Pass Road, Deolai, Aurangabad

Accession No : 2023101513

Patient Name : Mr. KIRAN KOTKAR

Age / Sex : 40 Year/Male

Referred by : LIFELINE MULTISPECIALITY HOSPITAL

Registered On : 15/10/2023

Reporting On : 15/10/2023

Printed On : 15/10/2023



PS FOR OPINION

Test Name	Patient Value	Reference Range	Unit
RBCs	Normocytic normochromic picture seen.		
WBCs	WBC'S are normal in number		
PLATELETS	Platelets are adequate		
HEMOPARASITE	No malarial parasite seen		

----- END OF REPORT -----

Kindly Correlate Clinically !

Thanks for referral !

Dr. Shubhangi Chaudhari
M.D Pathology
Reg No. 2012/08/2421



Vigilance Diagnostics

PATHOLOGY LABORATORY

LIFE LINE MULTISPECIALITY HOSPITAL

Plot No. 20, Gut No. 103, Opp. Surya Lawns,
Beed By Pass Road, Deolai, Aurangabad

Accession No : 2023101513

Patient Name : Mr. KIRAN KOTKAR

Age / Sex : 40 Year/Male

Referred by : LIFELINE MULTISPECIALITY HOSPITAL

Registered On : 15/10/2023


Reporting On : 15/10/2023

Printed On : 15/10/2023



Test Name	Patient value	Reference Range	Unit
BIOCHEMISTRY			
Kidney Function Test			
CREATININE	0.96	0.5 - 1.4	mg/dl
UREA	20.13	10 - 50	mg/dl
LIPID PROFILE			
S. Cholesterol	187.20	0 - 200	mg/dl
S. Triglycerides	156.23	25 - 160	mg/dl
HDL Cholesterol	37.44	30 - 60	mg/dl
LDL Cholesterol	118.51	85 - 150	mg/dl

Kindly Correlate Clinically !
Thanks for referral !


Dr. Shubhangi Chaudhari
M.D Pathology
Reg No. 2012/08/2421

----- End of Report -----



Vigilance Diagnostics
PATHOLOGY LABORATORY
LIFE LINE MULTISPECIALITY HOSPITAL

Plot No. 20, Gut No. 103, Opp. Surya Lawns,
Beed By Pass Road, Deolai, Aurangabad

Accession No : 2023101513
Patient Name : Mr. KIRAN KOTKAR
Age / Sex : 40 Year/Male
Referred by : LIFELINE MULTISPECIALITY HOSPITAL

Registered On : 15/10/2023
Reporting On : 15/10/2023
Printed On : 15/10/2023




URINE ROUTINE EXAMINATION

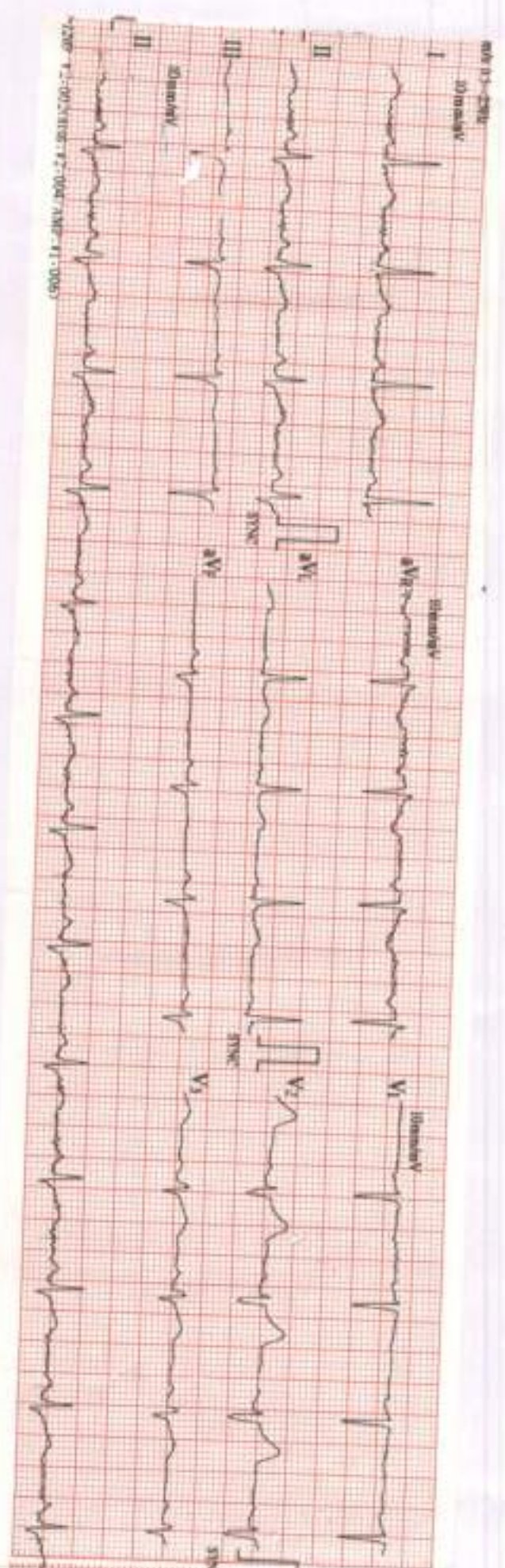
Test Name	Patient Value	Reference Range	Unit
<u>PHYSICAL EXAMINATION</u>			
VOLUME	5 ML	(NORMAL : 2 TO 6)	
COLOUR	PALE YELLOW		
APPEARANCE	CLEAR		
<u>CHEMICAL EXAMINATION</u>			
PROTEIN	NIL	NOT DETECTED	
GLUCOSE	NIL	NOT DETECTED	
<u>MICROSCOPIC EXAMINATION</u>			
EPITHELIAL CELLS	1-2		/hpf
PUS CELL / LEUCOCYTES	2-4		/hpf/Leu/UL
RED BLOOD CELLS/BLD	ABSENT	NIL	/hpf/Ery/UL
CASTS	NOT DETECTED	NOT DETECTED	
CRYSTALS	NOT DETECTED	NOT DETECTED	
BACTERIA	NOT DETECTED	NOT DETECTED	

----- END OF REPORT -----

Kindly Correlate Clinically !
Thanks for referral !


Dr. Shubhangi Chaudhari
M.D Pathology
Reg No. 2012/08/2421

Package name	Package Incursions	Customer Name	Gender M/F
ARCOFEMI - MEDIWHEEL - FULL BODY ANNUAL PLUS MALE - 2D ECHO - PAN INDIA - FY2324	Dietician consultation,Lipid Profile (all Parameters),Renal Function Test,Ultrasound - Whole Abdomen,Package Consultation - ENT,2 D ECHO,Consultation - Dental,Blood Grouping And Typing (Abo And Rh),ECG,Fitness by General Physician,URINE GLUCOSE(POST PRANDIAL),Urine Routine (CUE),GGTP: Gamma Glutamyl Transpeptidase - Serum,GLUCOSE - SERUM / PLASMA(FASTING AND POST PRANDIAL, THYROID PROFILE - I(T3, T4 AND TSH),Glycosylated Hemoglobin (HbA1C) - Whole Blood,LIVER FUNCTION TEST (PACKAGE),X-Ray Chest PA,HEMOGRAM (CBC+ESR),Opthal by General Physician,URINE GLUCOSE(FASTING),BMI,GLUCOSE, POST PRANDIAL (PP), 2 HOURS (POST MEAL),GLUCOSE, FASTING,RENAL PROFILE/RENAL FUNCTION TEST (RFT/KFT),COMPLETE URINE EXAMINATION,LIVER FUNCTION TEST (LFT),Doctor,DIET CONSULTATION,THYROID PROFILE (TOTAL T3, TOTAL T4, TSH),PERIPHERAL SMEAR,HEMOGRAM + PERIPHERAL SMEAR,BLOOD GROUP ABO AND RH FACTOR,GAMMA GLUTAMYL TRANSFERASE (GGT),HbA1c, GLYCATED HEMOGLOBIN,LIPID PROFILE,BODY MASS INDEX (BMI)	MR. KOTKAR KIRAN BHIMRAO	male



ID: 2358
 Name: 844. 52M
 Sex: M
 Age: 5
 Status: Sinus rhythm
 Location: Left Atrial enlargement
 Ref: Prof. R. Pragasam
 Ref: Left Atrial Enlargement
 Patient Name: Katras Kiran
 Bed No: 844
 Room No: 844
 Date: 14/10/25
 Doctor: Agarwal Satish
 Location: Left Atrial Enlargement
 Date: 14/10/25
 Doctor: Agarwal Satish

DR. SACHIN BANGAR
 MD, DNB (MED.)
 Reg. No. 0108/3045

NAME: KIRAN KOTKAR

AGE: 40YRS/M

DATE: 15/10/2023

2D ECHO DOPPLER REPORT

Patient in tachycardia during study

La Ra Normal in Size and shape.

LV is normal in size and shape.

Good LV Systolic function.

LVEF>55%

NO DIASTOLIC DYSFUNCTION.

NO regional wall motion abnormality

No intra cardiac shunts vegetation.

No MR/TR/AR

NO PERICARDIAL EFFUSION.

IMPRESSION: ESSENTIALLY NORMAL 2D ECHO DOPPLER STUDY


DR. SACHIN BANGAR
MBBS, MD (MEDI.)
Reg. No. 02/08/2015
(SIGNATURE)



भारत सरकार
GOVERNMENT OF INDIA



क्रान्ति भीमराव कोटकार
Kran Bhimrao Kotkar

जन्म वर्ष / Year of Birth 1983
पुरुष / Male



9697 8233 1526

आधार – सामान्य माणसाचा अधिकार

V B N M



भारतीय विज्ञान-संचार प्राधिकरण
INDIAN TELECOMMUNICATION AUTHORITY OF INDIA

पता: F/38, गल्ली नं. 3, नागसेन बुद्ध
विहार अबाद, रामा नगर, क्रांती चौक,
औरंगाबाद, महाराष्ट्र, 431005

Address: F/38, GALLI NO 3,
NEAR NAGSEN BUDDH VIHAR,
RAMA NAGAR, KRANTI CHOWK,
AURANGABAD, Maharashtra,
431005



1947
1800 130 1947



help@nitel.gov.in



www.nitel.gov.in



P.O. Box No. 1947,
Bangalore-560 081