

mediwheel.  
Jyothi of




భారత ప్రభుత్వం  
GOVERNMENT OF INDIA

జ్యోతి ఆనంద్ ధవాలేశ్వరపు  
Jyothi Anand Dhavaleswarapu

05/05/1972



పుట్టిన సంవత్సరం/Year of Birth 1972  
స్త్రీ / Female



3424 0532 2959

ఆధార్ - సామాన్యుని హక్కు

S/F

2 Jy

DR. HARI CHHABLANI  
M.B.B.S. (RESP. MEDICINE) PGDHHA, PAF  
ICU INTENSIVE CARE  
DMC REG. NO. - 91702

DR. PLUS HEALTHCARE CENTRE  
'NATHANI HEIGHTS', B-WING  
42, MUMBAI CENTRAL (EAST)



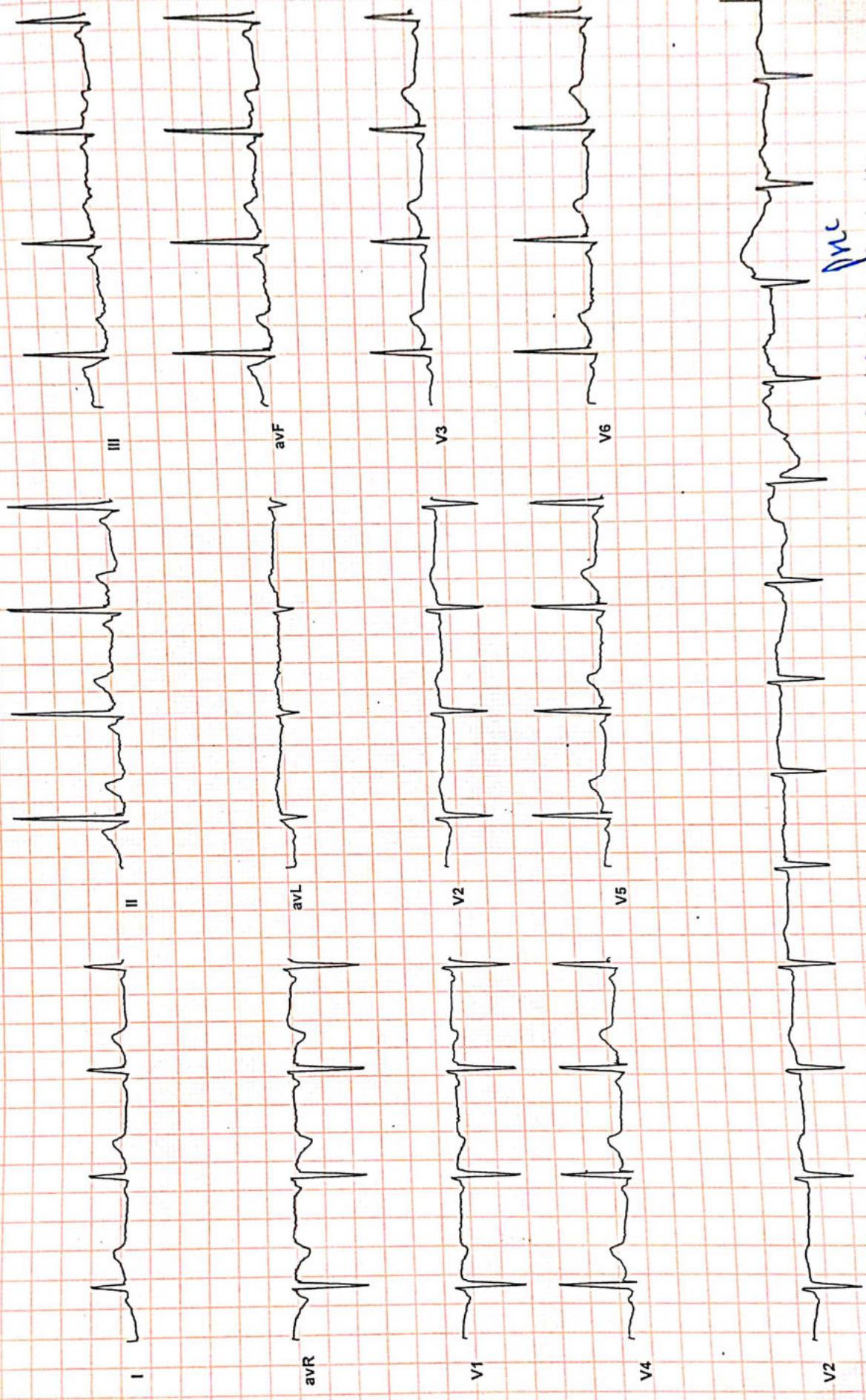
ECG

DR PLUS HEALTHCARE CENTRE - MUMBAI CENTRAL

2195 / JYOTHI DHAVALESWARAPU / 50 Yrs / F

Heart Rate : 81 bpm / Tested On : 24-Sep-22 10:58:42 / HF 0.05 Hz - LF 100 Hz / Notch 50 Hz / Sn 1.00 Cm/mV / Sw 25 mm/s

/ Refd By.: DR.HARI CHHABLANI



mc

WNL

DR. PURVI CHHABLANI

Reported By: DR. PURVI CHHABLANI

Consultant Physician And Intensivist

Reg. No. 7769F

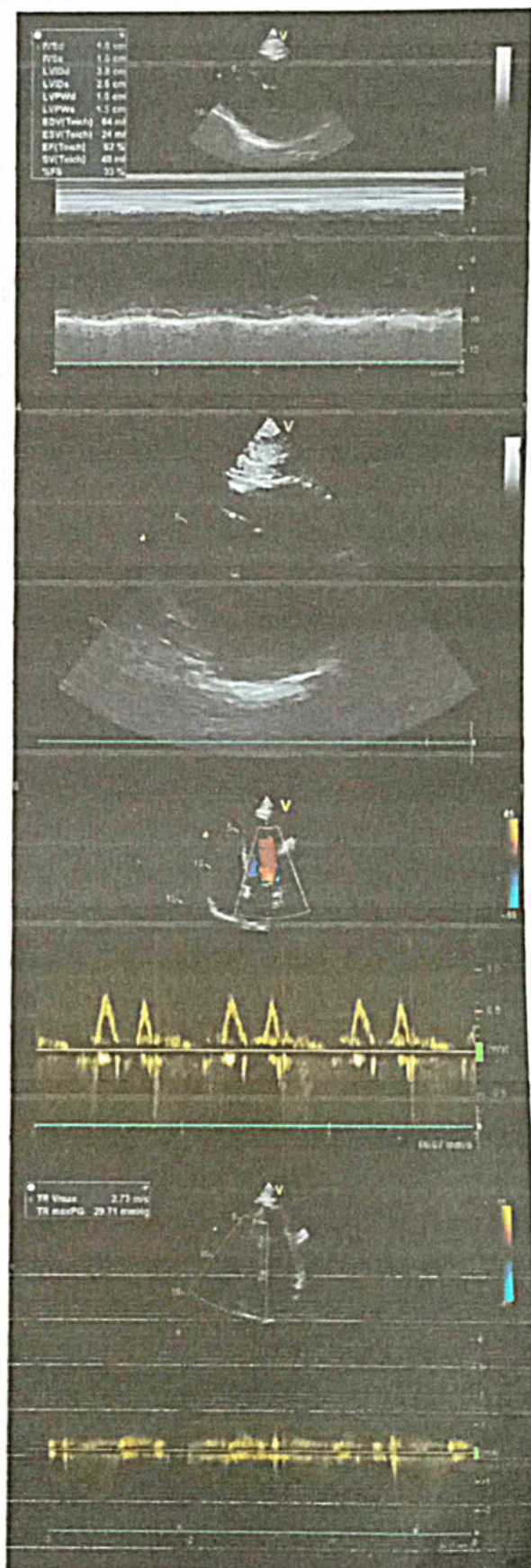



Name JYOTHI DHAVALSWARAPU

Sex Female

Age 50

Date 24/09/2022



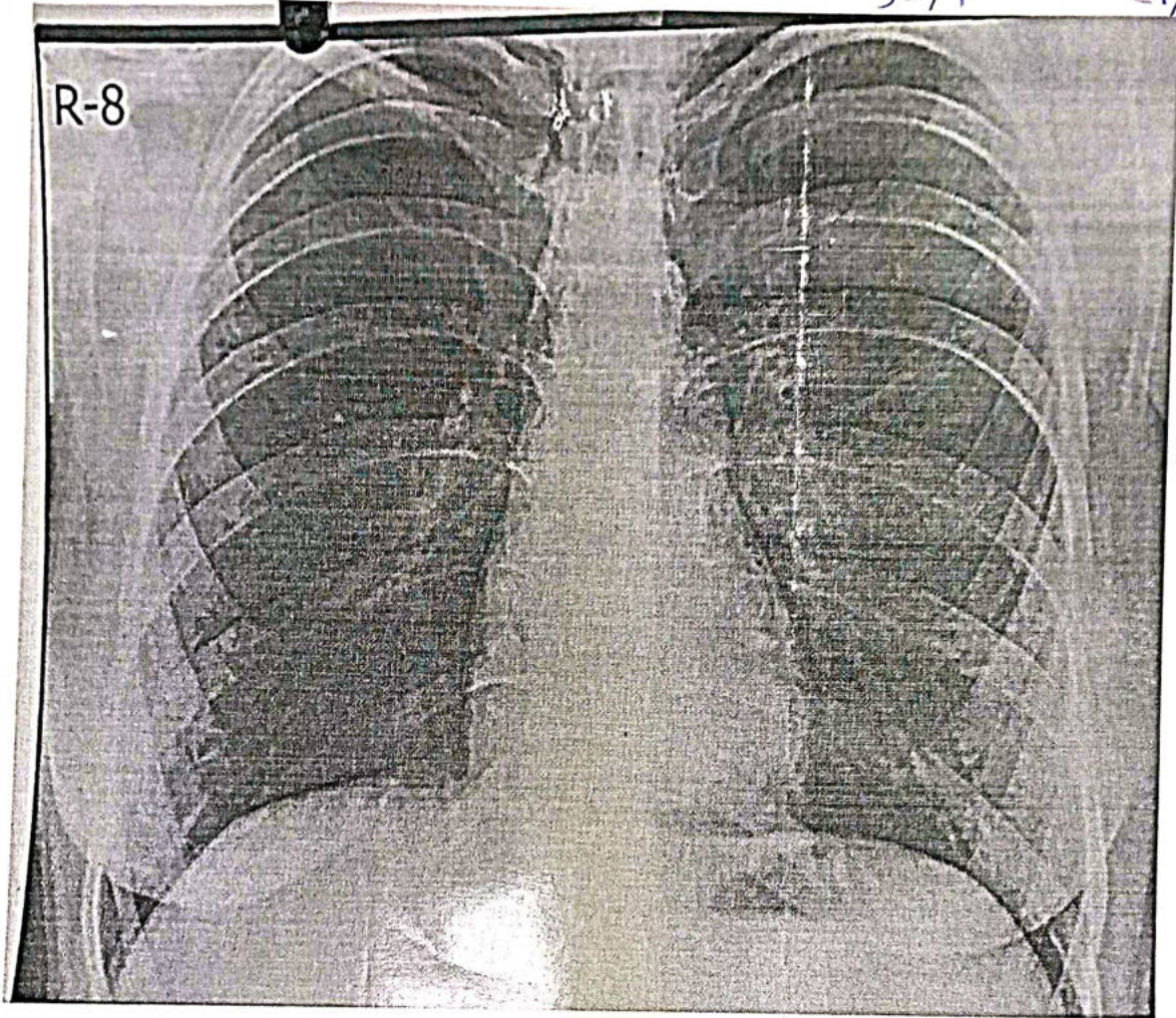


JYOTI

DHAVLESWARAPU

50/f

24/09/22



DR. PLUS HEALTHCARE CENTRE  
NATHANI HEIGHTS', B-WING  
42, MUMBAI CENTRAL (EAST)



# Dr-Plus Healthcare Centre

NATHANI HEIGHTS, B Wing, Shop No. 51, Ground Floor, Opp. Mumbai Central Station (East), Mumbai - 400 008.

Patient's Name : JYOTHI DHAVALESWARAPU

Report Date : 24/09/2022

Referred By : SELF

Age : 50 Years

Sex : FEMALE

## X- RAY CHEST

BOTH THE LUNG FIELED ARE CLEAR.

THE HILAR SHADOWS APPEAR NORMAL.

THE COSTO-PHRENIC ANGELS ARE CLEAR.

THE CARDIAC SHADOWS APPEAR NORMAL.

THE TRACHEAL IS CENTRAL IN POSITION.

THE BONY CAGE APPEARS NORMAL.

**IMPRESSION : THE ABOVE EXAMINATION IS WITHIN NORMAL LIMITS.**

  
DR. A. J. MAZUMDAR

MD. DMRE, MDRD

DR. PLUS HEALTHCARE CENTRE  
NATHANI HEIGHTS, B-WING,  
42, MUMBAI CENTRAL (EAST)





# Dr-Plus Healthcare Centre

NATHANI HEIGHTS, B Wing, Shop No. 51, Ground Floor, Opp Mumbai Central Station (East), Mumbai - 400 008.

NAME : JYOTHI DHAVALESWARAPU

50/F


DATE:24/09/2022

REF BY : SELF

## 2D-ECHO. AND COLOR DOPPLER REPORT

- NORMAL CARDIAC VALVES WITH TRIVIAL TR.
- NORMAL CARDIAC CHAMBERS
- NO E/O REGIONAL WALL MOTION ABNORMALITY. WITH NORMAL LVEF OF 65 %.
- E/O MILD PULMONARY HYPERTENSION .PASP 30 mmHg by TR jet.
- NO E/O LEFT VENTRICULAR HYPERTROPHY.
- NO E/O DIASTOLIC DYSFUNCTION.
- NO E/O PERICARDIAL EFFUSION.
- NO E/O INTRACARDIAC CLOT OR VEGETATION
- INTACT IAS / IVS
- **CONVENTIONL DOPPLER :**
  - E TO A RATIO IS MORE THAN ONE IN LV INFLOW.
  - THERE IS NO GRADIENT ACROSS AV,LVOT OR RVOT
  - PASP FROM TR JET IS 30 mm OF Hg.
- **COLOUR DOPPLER:**
  - TRIVIAL TR

EF Slope	108	85-120 mm/sec		
Opening Amplitude	22			
Posterior leaflet				
E.P.S.S	02	mm		
Mitral valve prolapse				
Vegetations				
<b>TRICUSPID VALVE</b>	<b>OBSERVED</b>	<b>NORMAL VALUES</b>		
<b>PULMONARY VALVE</b>	<b>OBSERVED</b>	<b>NORMAL VALUES</b>		
EF Slope				
'A' Wave				
Midsystolic notch				
Flutter				
Other Findings				
<b>AORTIC VALVE</b>	<b>OBSERVE</b>	<b>NORMAL VALUES</b>		
Cuspal opening	15	mm		
Closure line	Central			
Eccentricity index	1			
Other Findings				
<b>DIMENSIONS</b>	<b>OBSERVED</b>	<b>NORMAL VALUES</b>		
1. Lvd (Diastolic)	38	26-52		
2. Lvd (Systolic )	26	24-42mm		
3. RVD (Diastolic)	18	7-23mm		
4. IVST (Diastolic)	10	6-11mm		
5. IVST (Systolic )	15			
6. LVPWT (Diastolic)	10	6-11mm		
7. LVPWT (Systolic )	15			
8. Aortic root	23	22-37mm		
9. left Atrium	30	19-40mm		
	<b>STRUCTURE</b>	<b>REGURG GRADING</b>	<b>VELOCITY m/sec</b>	<b>STENOSIS GRADIENT mm/Hg</b>
			Max mean	Peak mean
<b>MITRAL VALVE</b>	NORMAL	0/3	/	/
<b>TRICUSPID VELVE</b>	NORMAL	TRIVIAL	/	/
<b>PULMONARY VELVE</b>	NORMAL	0/4	/	/
<b>AORTIV VALVE</b>	NORMAL	0/4	/	/

  
**DR.P.H.CHHABLANI**  
 M.B.B.S, DNB.(MEDICINE)  
 CONSULTANT PHYSICIAN AND CARDIOLOGIST.

**DR. PURVI CHHABLANI**  
 MBBS, DNB, (Medicine,  
 consultant Physician And Intensive  
 Reg No 77896





# Dr-Plus Healthcare Centre

NATHANI HEIGHTS, B-Wing, Shop No. 51, Ground Floor, Opp. Mumbai Central Station (East), Mumbai - 400 008.

Full Name :

JYOTHI DHAVALSWARAPU 50/F

24/09/2022

## HAEMOGRAM

		Normal Range	
1.	Red Blood Cell Count	3.59	[M : 4.5 - 5.6 / F : 3.5 - 5.5/cu.mm]
2.	Hb%	11.5	[M: 14-18 / F : 11-16%]
3.	Hematocrit	35.8	[M : 40-53 / F : 30-47 %]
4.	Indices:		
(a)	MCV(Mean Corpuscular Volume)	89.7	[79-101 cu.mi.]
(b)	MCH(Mean Corpuscular Hb)	30.1	[27-32 pg]
(c)	MCHC(Mean Corpuscular Hb Concentration)	34.3	[32-38%]
5.	Morphology		
	Macrocytes : --	Microcytes: --	Hypochromia: --
	Poikilocytosis: --	Anisocytosis: --	
6.	Target cells: --		
	Spherocytes: --	Elliptocytes: --	
7.	TOTAL W.B.C.Count	6,000	{4000-11000/cu.mm}
Differential Count			
a)	Neutrophils :	60	[45 - 70%]
b)	Lymphocytes :	30	[20 - 45%]
e)	Basophils :	00	[00 - 01%]
c)	Eosinophils:	04	[01 - 06%]
d)	Monocytes:	06	[00 - 08%]
8.	Platelets :3.52		1.5-4.5 Lacks/cu.mm
9.	Erythrocyte Sedimentation Rate (ESR): 15		Up to 20 mm at end of hour
			Method : Westergrens

## ROUTINE URINE EXAMINATION (RUA)

### 1. Physical Examination:

(i)	Colour:	PALE YELLOW	(ii)	Sediment:	CLEAR
(iii)	Transparency:	CLEAR	(iv)	Reaction:	ACIDIC
(v)	Specific gravity	1.010			

### 2. Chemical Examination:

(i)	Protein :	NIL	(ii)	Sugar:	NIL
(iii)	Bile salt:	NIL	(iv)	Bile pigment:	NIL

### 3. Microscopic Examination:

(i)	Red Blood Cells:	ABSENT	(ii)	Epithelial Cells:	1 TO 2/ HPF
(iii)	Crystals:	ABSENT	(iv)	Pus Cells:	1 TO 2/HPF
(v)	Casts:	ABSENT	(vi)	Deposits:	ABSENT
(vii)	Bacteria's :	ABSENT			

DR. RAKESH PATIL  
 M.D., D.N.B. (Pathology)  
 Reg. No. 2010/051000





# Dr-Plus Healthcare Centre

NATHANI HEIGHTS, B-Wing, Shop No. 51, Ground Floor, Opp. Mumbai Central Station (East), Mumbai - 400 008.

Full Name

JYOTHI DHAVALESWARAPU 50/F

24/09/2022

Life to be assured:

	Type of Test	Actual Reading	Normal Range
1	Fasting Blood Sugar	79.6	70-100 mg%
2	PPBS	110.1	110 TO 140 mg%
3	Total Cholesterol	170.3	120-200 mg%
4	VERY LOW DENSITY LEVEL(VLDL)	20.2	10-30 mg/dl
5	High Density Lipid (HDL)	49.0	40-60 mg%
6	Low Density Lipid (LDL)	99.1	<u>Upto 150</u>
7	S. Triglycerides	124.6	50-150 mg%
8	CHOL/HDL	3.4	Upto 5
9	HDL/LDL	0.4	
10	S. Creatinine	0.8	0.5-1.2 mg%
11	Blood Urea Nitrogen (BUN)	16.5	7-21 mg%
12	BUN/CREAT RATIO	20.6	
13	S. Proteins	6.8	6.0-7.9 mg%
14	(a) Albumin	3.7	3.5-5.5 mg%
15	(b) Globulin	3.1	2.0-3.5 mg%
16	A/G RATIO	1.1	
17	S. Bilirubin	0.8	0.3-1.3mg%
18	(a) Direct	0.6	0.0-0.8 mg%
19	(b) Indirect	0.2	0.0-0.5 mg%
20	SGOT (AST)	23.6	05-34 IU
21	SGPT (ALT)	28.4	05-40 IU
22	GGTP (GGT)	39.8	05-50 IU
23	SGOT/SGPT	0.8	
24	HBA1C	5.4	UPTO 6.5
25	S. Alkaline Phosphatase	96.1	30-115 IU
26	T3	123.4	80-180ng/dl
27	T4	6.5	4.6-12 ug/dl
28	TSH	2.2	0.4-4.0 mIU/L
29	SERUM URIC ACID	5.6	2.5-7.2mg/dl
30	URINE SUGAR PP	ABSENT	
31	URINE SUGAR FASTING	ABSENT	
32	BLOOD GROUP	"O POSITIVE "	

DR. RAKESH PATKAR  
M.D., D.N.B. (Pathology)  
Reg. No. 2013/05/1660





**Dr. Hari Chhablani**

Cardiometabolic Physician & Intensivist  
M.B.B.S., F.C.C.P. (RESP. MED.), PGDHMM,  
PGDMLS, FELLOW INTENSIVE CARE MED.

ATTACHED TO : Wockhardt Hospital • Saifee Hospital • Apollo Spectra Hospital

NATHANI HEIGHTS, B-Wing, Shop No. 42, Ground Floor, Opp. Mumbai Central Station (East),  
Mumbai - 400 008. • Cell : 98206 46163 • E : drharichhablani@gmail.com

**PHYSICIAN REPORT**

DATE : 24/09/2022

NAME : JYOTHI DHAVALSWARAPU 50/F

PRESENTING COMPLAINS : NIL.

PAST HISTORY : H/O HYSTRECTOMY - FIBROID -2015

COVID-19 POSITIVE IN -JAN.2022 ,HOME QUARANTINED .

FAMILY HISTORY: NOT SIGNIFICANT.

TREATMENT : NIL.

HABITS: NIL

HT.- 158 CM. WT.- 59 Kg. BMI.-23

P: 80/MIN ., REGULAR BP: 116/80

EYE EXAMINATION : NEAR VISION -R/E- N18 , L/E- N36 , DISTANT VISION -R/E - 6/18 , L/E -6/18

COLOR VISION : NORMAL

RS: CLEAR

CVS: S1,S2 REGULAR

PA: SOFT

CNS: CLINICALLY NAD

ENT EXAMINATION : WNL

LABS: ATTACHED

2-D- ECHO : ATTACHED

ECG: ATTACHED


X-RAY: ATTACHED

IMPRESSION : : FIT ON CLINICAL MEDICAL EXAMINATION .

**DR. HARICHHABLANI**  
M.B.B.S.(F.C.C.P.(RESP.MED.)) PGDHMM, PGDMLS  
FELLOW INTENSIVE CARE  
MMC REG. NO. - 91702





 GPS Map Camera

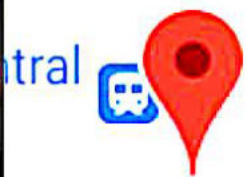## Mumbai, Maharashtra, India

Shop No 65, Nathani Heights, Marzban Parsi Colony, Dalal Estate, Mumbai Central, Mumbai, Maharashtra 400008, India

Lat 18.968781°

Long 72.819977°

24/09/22 09:18 AM GMT +05:30



Google