

Mr Durga Shankar Singh/M

Routine eye check up

No active complaints. AR < $+2.50 / -2.50 @ 75^\circ$
 $+3 / -1.25 @ 105^\circ$

O/E vitreous 6/6, NB (O) (N)

colour vision (N)

slit lamp - NAD

medicated fundus - NAD

Ad
Annual eye check up

U
19/9/22



Consultant
Department of Ophthalmology
SIGNATURE HOSPITAL
Gurugram

(This is only professional opinion and not the diagnosis. Please correlate clinically)

Sector 37-D, BPTP, Dwarka Express Way, Gurugram, Hry.,

Patient Name : Mr. DURGA SHANKAR SHARMA	UHID : 22550
Age / Gender : 59 Years 4 Months 3Days / Male	IPNO :
Referred By : Dr. CMO	Registered : 19/09/2022/ 8.55 AM
Req.No : 22225504	Sample Collection Dt & Tm : 19/09/2022/ 09.42 AM
Sample ID : 2235916	Sample Receiving Dt & Tm : 19/09/2022/ 09:43 AM
Patient Type : OPD	Report Released on : 19/09/2022/ 1.44 PM
Bed No :	

BIOCHEMISTRY

Blood Sugar Fasting

TEST NAME	RESULT	UNITS	REFERENCE INTERVAL	BIOLOGICAL SPECIMEN TYPE
TEST METHOD				
BLOOD SUGAR FASTING (God- Trinders)	126	mg/dl	75 - 115	Flouride Plasma

Increased In:
 Diabetes Mellitus
 Stress (e.g, emotion, burns, shock, anesthesia)
 Acute Pancreatitis
 Chronic Pancreatitis
 Wernicke encephalopathy (Vitamin B1 deficiency)
 Effect of drugs (e.g. corticosterogens, alcohol, phenytoin, thiazides)

Decreased in :
 Pancreatitis disorders
 Extrapancreatic tumors
 Endocrine disorders
 Malnutrition
 Hypothalamic lesions
 Alcoholism
 Endocrine Disorders

-**** End of Report ****-

This is Provisional Report

Lab Technician	Dr.NishaTiwari (MD.Microbiology)	Dr. Neha Gupta MBBS,MD(Pathology) (Consultant Pathologist)	Dr. Shreya Pradhan MBBS,MD(Microbiology) (Consultant Microbiologist)
----------------	-------------------------------------	------------------------------------------------------------------	----------------------------------------------------------------------------

(This is only professional opinion and not the diagnosis. Please correlate clinically)

Sector 37-D, BPTP, Dwarka Express Way, Gurugram, Hry.,

Ph.: 0124-6034444, 8526000000, E-mail : signaturehospital@gmail.com, Web.: www.thesignaturehealthcare.com

PARK GROUP OF HOSPITAL : ★ West Delhi ★ South Delhi ★ Gurugram ★ Faridabad ★ Panipat ★ Karnal

Patient Name : Mr. DURGA SHANKAR SHARMA	UHID : 22550
Age / Gender : 59 Years 4 Months 3Days / Male	IPNO :
Referred By : Dr. CMO	Registered : 19/09/2022/ 8.55 AM
Req.No : 22225504	Sample Collection Dt & Tm : 19/09/2022/ 09.42 AM
Sample ID : 2235916	Sample Receiving Dt & Tm : 19/09/2022/ 09:43 AM
Patient Type : OPD	Report Released on : 19/09/2022/ 1.50 PM
Bed No :	

CLINICAL PATHOLOGY

MICROSCOPIC EXAMINATION - URINE

PUS CELLS (Microscopic)	1-2	/HPF	0 - 3	Urine
RBC- Urine (Per Oxidase Reaction)	NIL	/HPF	NIL	Urine
EPITHELIAL CELLS	0-1	/HPF	0 - 5	
CAST	NIL		NIL	
CRYSTALS	NIL		NIL	
BACTERIA	NIL			
OTHERS	NIL			

COMMENTS: Actual numerical values for WBCs, RBCs and Epithelial cells are not defined and must be correlated clinically.


Test Methods: Reagent strip analysis and urine sediment microscopy.


Reagent strip / chemical analysis are based on: pH-Double Indicator principle; Specific gravity Ion exchange method; Glucose Glucose oxidase-peroxidase/Benedicts; Protein Acid-base indicator/Sulfosalicylic acid; Urobilinogen Coupling reaction/Ehrlich's reaction, Bilirubin Coupling reaction, Ketones Nitroprusside method/Rotheras test.

-**** End of Report ****-

Lab Technician


 Dr. Nisha Tiwari
 (MD. Microbiology)


 Dr. Neha Gupta
 MBBS, MD (Pathology)
 (Consultant Pathologist)


 Dr. Shreya Pradhan
 MBBS, MD (Microbiology)
 (Consultant Microbiologist)

(This is only professional opinion and not the diagnosis. Please correlate clinically)

Sector 37-D, BPTP, Dwarka Express Way, Gurugram, Hry.,

Ph.: 0124-6034444, 8526000000, E-mail : signaturehospital@gmail.com, Web.: www.thesignaturehealthcare.com

PARK GROUP OF HOSPITAL : ★ West Delhi ★ South Delhi ★ Gurugram ★ Faridabad ★ Panipat ★ Karnal

Patient Name : Mr. DURGA SHANKAR SHARMA	UHID : 22550
Age / Gender : 59 Years 4 Months 3Days / Male	IPNO :
Referred By : Dr. CMO	Registered : 19/09/2022/ 8.55 AM
Req.No : 22225504	Sample Collection Dt & Tm : 19/09/2022/ 09.42 AM
Sample ID : 2235916	Sample Receiving Dt & Tm : 19/09/2022/ 09:43 AM
Patient Type : OPD	Report Released on : 19/09/2022/ 1.44 PM
Bed No :	

BIOCHEMISTRY

Blood Sugar Fasting

TEST NAME	RESULT	UNITS	REFERENCE INTERVAL	BIOLOGICAL SPECIMEN TYPE
TEST METHOD				
BLOOD SUGAR FASTING (God- Trinders)	126	mg/dl	75 - 115	Flouride Plasma


Increased In:
 Diabetes Mellitus
 Stress (e.g. emotion, burns, shock, anesthesia)
 Acute Pancreatitis
 Chronic Pancreatitis
 Wernicke encephalopathy (Vitamin B1 deficiency)
 Effect of drugs (e.g. corticosterogens, alcohol, phenytoin, thiazides)

Decreased in :
 Pancreatitis disorders
 Extrapancreatic tumors
 Endocrine disorders
 Malnutrition
 Hypothalamic lesions
 Alcoholism
 Endocrine Disorders

-**** End of Report ****-



Dr. Neha Gupta
 MBBS,MD(Pathology)
 (Consultant Pathologist)



Dr. Shreya Pradhan
 MBBS,MD(Microbiology)
 (Consultant Microbiologist)

Lab Technician

Dr.NishaTiwari
 (MD.Microbiology)

(This is only professional opinion and not the diagnosis. Please correlate clinically)

Sector 37-D, BPTP, Dwarka Express Way, Gurugram, Hry.,

Ph.: 0124-6034444, 8526000000, E-mail : signaturehospital@gmail.com, Web.: www.thesignaturehealthcare.com

PARK GROUP OF HOSPITAL : ★ West Delhi ★ South Delhi ★ Gurugram ★ Faridabad ★ Panipat ★ Karn

Patient Name : Mr. DURGA SHANKAR SHARMA	UHID : 22550
Age / Gender : 59 Years 4 Months 3Days / Male	IPNO :
Referred By : Dr. CMO	Registered : 19/09/2022/ 8.55 AM
Req.No : 22225504	Sample Collection Dt & Tm : 19/09/2022/ 09.42 AM
Sample ID : 2235916	Sample Receiving Dt & Tm : 19/09/2022/ 09:43 AM
Patient Type : OPD	Report Released on : 19/09/2022/ 1.44 PM
Bed No :	

BIOCHEMISTRY

Lipid Profile


TEST NAME	RESULT	UNITS	REFERENCE INTERVAL	BIOLOGICAL SPECIMEN TYPE
TEST METHOD				
<u>LIPID PROFILE</u>				
CHOLESTROL (CHOD-TRINDER)	200	mg/dl	00 - 200	SERUM
TRIGLYCERIDES (GPO-Trinders)	205	mg/dl	35 - 170	SERUM
HDL- CHOL (Direct Method/ Enzymatic Colorometric)	56	mg/dl	40 - 60	SERUM
VLDL-CHOL CALCULATED	41	mg/dl	10 - 40	
LDL-CHOLESTROL	103	mg/dl	0 - 130	
LDL/HDL RATIO	1.84		0-3	
CHOLESTROL/HDL RATIO	3.57			

-**** End of Report ****-

Lab Technician

Dr.NishaTiwari
(MD.Microbiology)


 Dr. Neha Gupta
 MBBS,MD(Pathology)
 (Consultant Pathologist)


 Dr. Shreya Pradhan
 MBBS,MD(Microbiology)
 (Consultant Microbiologist)

Page 1 of 2

(This is only professional opinion and not the diagnosis. Please correlate clinically)

Sector 37-D, BPTP, Dwarka Express Way, Gurugram, Hry.,

Ph.: 0124-6034444, 8526000000, E-mail : signaturehospital@gmail.com, Web.: www.thesignaturehealthcare.com

PARK GROUP OF HOSPITAL : ★ West Delhi ★ South Delhi ★ Gurugram ★ Faridabad ★ Panipat ★ Karna

Patient Name : Mr. DURGA SHANKAR SHARMA	UHID : 22550
Age / Gender : 59 Years 4 Months 3Days / Male	IPNO :
Referred By : Dr. CMO	Registered : 19/09/2022/ 8.55 AM
Req.No : 22225504	Sample Collection Dt & Tm : 19/09/2022/ 09.42 AM
Sample ID : 2235916	Sample Receiving Dt & Tm : 19/09/2022/ 09:43 AM
Patient Type : OPD	Report Released on : 19/09/2022/ 1.45 PM
Bed No :	

BIOCHEMISTRY

Renal Profile


TEST NAME	RESULT	UNITS	REFERENCE INTERVAL	BIOLOGICAL SPECIMEN TYPE
TEST METHOD				
BLOOD UREA (Urease UV/GLDH)	24	mg/dl	- 13 - 45	SERUM
SERUM CREATININE (Jaffe Rate)	1.3	mg/dl	0.6 - 1.4	SERUM
URIC ACID (Enzymatic/Uricase)	6.5	mg/dl	3.6 - 7.2	SERUM
<u>ELECTROLYTES</u>				
SODIUM (ISE-Indirect)	143	mmol/L	132 - 150	SERUM
POTASSIUM (ISE-Indirect)	4.2	mmol/L	3.5 - 5.5	SERUM

-**** End of Report ****-

Lab Technician

Dr.NishaTiwari
(MD.Microbiology)


 Dr. Neha Gupta
 MBBS,MD(Pathology)
 (Consultant Pathologist)


 Dr. Shreya Pradhan
 MBBS,MD(Microbiology)
 (Consultant Microbiologist)

(This is only professional opinion and not the diagnosis. Please correlate clinically)

Sector 37-D, BPTP, Dwarka Express Way, Gurugram, Hry.,

Ph.: 0124-6034444, 8526000000, E-mail : signaturehospital@gmail.com, Web.: www.thesignaturehealthcare.com

PARK GROUP OF HOSPITAL : ★ West Delhi ★ South Delhi ★ Gurugram ★ Faridabad ★ Panipat ★ Karn

Patient Name : Mr. DURGA SHANKAR SHARMA	UHID : 22550
Age / Gender : 59 Years 4 Months 3Days / Male	IPNO :
Referred By : Dr. CMO	Registered : 19/09/2022/ 8.55 AM
Req.No : 22225504	Sample Collection Dt & Tm : 19/09/2022/ 09.42 AM
Sample ID : 2235916	Sample Receiving Dt & Tm : 19/09/2022/ 09:43 AM
Patient Type : OPD	Report Released on : 19/09/2022/ 1.47 PM
Bed No :	

BIOCHEMISTRY

Liver Function Test Profile


TEST NAME	RESULT	UNITS	REFERENCE INTERVAL	BIOLOGICAL SPECIMEN TYPE
TEST METHOD				
<u>BILIRUBIN TOTAL AND DIRECT</u>				
BILIRUBIN TOTAL (Diazonium Salt)	2.1	mg/dl	0.1 - 1.2	SERUM
BILIRUBIN DIRECT (Diazonium Salt)	0.5	mg/dl	00 - 0.3	SERUM
BILIRUBIN INDIRECT (CALCULATED)	1.6	md/dl	0 - 0.9	
SGOT/AST (UV-KINETIC)	22	U/I	0 - 45	SERUM
SGPT/ALT (UV-KINETIC)	16	U/I	0 - 45	SERUM
ALKALINE PHOSPHATASE (ALP) (Kinetic)	67	U/I	41 - 137	SERUM

-**** End of Report ****-

Lab Technician

Dr.NishaTiwari
(MD.Microbiology)


 - Dr. Neha Gupta
 MBBS,MD(Pathology)
 (Consultant Pathologist)


 Dr. Shreya Pradhan
 MBBS,MD(Microbiology)
 (Consultant Microbiologist)

(This is only professional opinion and not the diagnosis. Please correlate clinically)

Sector 37-D, BPTP, Dwarka Express Way, Gurugram, Hry.,

Ph.: 0124-6034444, 8526000000, E-mail : signaturehospital@gmail.com, Web.: www.thesignaturehealthcare.com

PARK GROUP OF HOSPITAL : ★ West Delhi ★ South Delhi ★ Gurugram ★ Faridabad ★ Panipat ★ Karnal

(This is only professional opinion and not the diagnosis. Please correlate clinically)

Sector 37-D, BPTP, Dwaraka Express Way, Gurugram, Hry.,

Ph.: 0124-6034444, 8526000000, E-mail : signaturerehospital@gmail.com, Web.: www.signaturerehospital.com
PARK GROUP OF HOSPITAL : * West Delhi * South Delhi * Gurugram * Faridabad * Panipat * Karnal

Dr. Shreya Pradhan
MBBS,MD(Microbiology)
(Consultant Microbiologist)

Dr. Neha Gupta
MBBS,MD(Pathology)
(Consultant Pathologist)

Dr.NishatTiwari
(MD, Microbiology)

Lab Technician

This is Provisional Report

-**** End of Report ****-

Patient Name : Mr. DURGA SHANKAR SHARMA
Age / Gender : 59 Years 4 Months 3Days / Male
Referred By : Dr. CMO
Req.No : 22225504
Sample ID : 2235916
Patient Type : OPD
Bed No :
Report Released on : 19/09/2022 / 3.00 PM
Sample Collection Dt & Tm : 19/09/2022/ 09.42 AM
Sample Receiving Dt & Tm : 19/09/2022/ 09.43 AM
Registered : 19/09/2022/ 8.55 AM
UHID : 22550
IPNO :
HEMATOLOGY
Blood Group And Rh Factor
TEST NAME RESULT UNITS
TEST METHOD BLOOD GROUP(ABORh) "A" NEGATIVE
REFERENCE INTERVAL BIOLOGICAL SPECIMEN TYPE

The Signature
ADVANCED SUPER SPECIALTY
HOSPITAL



UID	22550	Date: 19 Sep 2022
Name/Age/Sex :	DURGA SHANKAR SHARMA 59Yr / Male	
Treating Dr. :		

X-RAY CHEST PA VIEW

OBSERVATION:

Left CP angle are obscured suggest ?minimal pleural effusion.

Bilateral prominent hila with prominent bronchovascular markings in bilateral lung fields .

The trachea is central.

The mediastinal and cardiac silhouette are normal.

Cardiothoracic ratio is normal.

Bones of the thoracic cage are normal.

Soft tissues of the chest wall are normal.

IMPRESSION:

Left CP angle are obscured suggest ?minimal pleural effusion.

Bilateral prominent hila with prominent bronchovascular markings in bilateral lung fields .

ADV USG THORAX IF CLINICALLY INDICATED.



Dr. Avinash Rathod (DMRD)
Consultant Radiologist
Reg. No. 2011/05/1616/1616

(This is only professional opinion and not the diagnosis. Please correlate clinically)

Sector 37-D, BPTP, Dwarka Express Way, Gurugram, Haryana
Webrad associated center
Powered by www.stradus.in

DEPARTMENT OF IMAGING & INTERVENTIONAL RADIOLOGY, THE SIGNATURE HOSPITAL

NAME: DURGA SHANKAR SHARMA	DATE: 19/09/2022
AGE: 59 Y/M	MR NO.: 22550

USG WHOLE ABDOMEN

LIVER: is normal in size and echotexture. No evidence of any focal lesion or IHBR dilation is present. Portal vein and CBD are normal in caliber at porta.

GALL BLADDER is well distended and lumen is echofree. Wall thickness is normal. No pericholecystic fluid is seen.

SPLEEN is normal in size and echotexture. No focal lesion is seen.

PANCREAS is normal in size and echotexture. Peripancreatic fat planes are clear. MPD is not dilated.

RIGHT KIDNEY: is normal in size and position and outline. Corticomedullary differentiation is maintained. There is no evidence of any focal lesion / calculus / backpressure changes.

LEFT KIDNEY: is normal in size and position and outline. Corticomedullary differentiation is maintained. There is no evidence of any focal lesion / calculus / backpressure changes.

URINARY BLADDER is well distended and lumen is echofree. Wall thickness is normal. No evidence of any focal lesion.

PROSTATE: is normal in size.

No free fluid is noted.

IMPRESSION:

- **No significant abnormality.**

Please correlate clinically



Dr. Guru
Senior Consultant
Diagnostic & Interventional Radiology

(This is only professional opinion and not the diagnosis. Please correlate clinically)

Sector 37-D, BPTP, Dwarka Express Way, Gurugram, Hry.,

Ph.: 0124-6034444, 8526000000, E-mail : signaturehospital@gmail.com, Web.: www.thesignaturehealthcare.com

PARK GROUP OF HOSPITAL : ★ West Delhi ★ South Delhi ★ Gurugram ★ Faridabad ★ Panipat ★ Karnal


The Signature
ADVANCED SUPER SPECIALITY
H O S P I T A L



PATIENT NAME	: Mrs. USHA RANI SHARMA	MR NO	: 22551
BILL NO	: 22225507	BILL DATE/TIME	: 19/09/2022 8.59 AM
AGE/SEX	: 55 YEARS 11 MONTHS 4DAYS /	SAMPLE DATE/TIME	: 19/09/2022 10.26 AM
TYPE	: OPD	REPORTING DATE/TIME	: 19/09/2022 10.28 AM
DOCTOR NAME	: Dr. CMO	APPROVED DATE/TIME	:
		PRINT DATE/TIME	: 19/09/2022 10.28 AM
		MOBILE NO	: 9412372011

DEPARTMENT OF ULTRASOUND

ULTRA SOUND WHOLE ABDOMEN

LIVER: is normal in size and raised in echotexture. No evidence of any focal lesion or IHBR dilation is present. Portal vein and CBD are normal in caliber at porta.

GALL BLADDER is well distended and lumen is echofree. Wall thickness is normal. No pericholecystic fluid is seen.

SPLEEN: is normal in size and echotexture. No focal lesion is seen.

PANCREAS: is normal in size and echotexture. Peripancreatic fat planes are clear. MPD is not dilated.

RIGHT KIDNEY: is normal in size and position and outline corticomedullary differentiation is maintained. There is no evidence of any focal lesion / calculus / backpressure changes.

LEFT KIDNEY: is normal in size and position and outline corticomedullary differentiation is maintained. There is no evidence of any focal lesion / calculus / backpressure changes.

URINARY BLADDER is well distended. Wall thickness is normal. No evidence of any focal lesion.

Uterus post menopausal. No adnexal mass lesion seen.

IMPRESSION:

- **Grade II fatty liver.**

Please correlate clinically


Dr. Guru

Senior Consultant

Diagnostic & Interventional Radiology

(This is only professional opinion and not the diagnosis. Please correlate clinically)

Sector 37-D, BPTP, Dwarka Express Way, Gurugram, Hry.,

Page No:1

0124-6034444, 8526000000, E-mail : signaturehospital@gmail.com, Web.: www.thesignaturehealthcare.com

K GROUP OF HOSPITAL : ★ West Delhi ★ South Delhi ★ Gurugram ★ Faridabad ★ Panipat ★ Karnal

TRANSTHORACIC ECHO- DOPPLER REPORT

NAME - MR DURGA SHANKAR SHARMA	AGE/SEX -59/M
MR. NO. -22550	DATE - 19/9/2022

M-MODE / 2-D DESCRIPTION

- ❖ **Left Ventricle:** No regional wall motion abnormality. LVEF ~ 55 %.
- ❖ **Left Atrium:** Normal.
- ❖ **Right atrium:** It is Normal Sized.
- ❖ **Right ventricle:** It is Normal Sized. RV Systolic Function is Normal.
- ❖ **Aortic valve:** Aortic Cusps are Normal.
- ❖ **Mitral valve:** It Appears Normal.
- ❖ **Tricuspid valve:** It Appears Normal.
- ❖ **Pulmonic valve:** It Appears Normal.
- ❖ **Main pulmonary artery & its branches:** Appear Normal.
- ❖ **Pericardium:** No Pericardial Effusion Seen
- ❖ **Inter atrial septum:** It is Intact.
- ❖ **Inter ventricular septum:** It is Intact.
- ❖ **IVC:** It is Normal in Size, collapsing & Respiratory Variability.
- ❖ **Clot / Vegetation:** No Intracardiac Clot, Vegetation.

Measurements (mm):

LEFT HEART			RIGHT HEART		
	Observed values (mm)	Normal values		Observed values (mm)	Normal values
Aortic root	32	20-36 (22mm/M ²)	IVC size	-	17-21mm
Aortic valve opening		15-26 (mm/M ²)	IVC respiratory variability		>50%
LA size	28	19-40 (mm/M ²)	RA size	-	<18cm ²
LA volume index (ml/M ²)		<34 ml/M ²		-	
LVID(D)	52	(ED=37-56)	RV basal		24-42mm
LVID(S)	40		RV mid cavity	-	20-35mm
IVS(D)	9	(ED=6-12)	RV longitudinal	-	56-86mm
			RVOT proximal	-	18-33mm
PW(D)	11	(ED=5-10)	TAPSE	-	>15mm
			RV free wall thickness	-	<5mm
LVEF(%)	55%	55%-70%		-	≥44%

(This is only professional opinion and not the diagnosis. Please correlate clinically)

Sector 37-D, BPTP, Dwarka Express Way, Gurugram, Hry.,

Doppler velocities (cm/sec)

Aortic valve		Pulmonary valve	
Max/ Vel	111	Max velocity	105
Max/ PG		Max PG	
Mitral valve		Tricuspid valve	
E	62	Max Velocity	
A	61	PASP	
DT	-	E/E' (>6)	-
E/A	-	S' Velocity (>10cm2/sec)	-

Regurgitation

MR		TR	
Severity	Nil	Severity	Nil
AR		PR	
Severity	Nil	Severity	Nil

Final Interpretation:

- No regional wall motion abnormality. LVEF ~ 55 %.
- Normal Cardiac Chamber Dimension.
- No MR, No AR, No TR.
- Grade I Diastolic dysfunction
- No Vegetation, Pericardial Effusion.


Dr. AJAY DUA

DNB (Medicine), DNB (Cardiology)
 Sr. Consultant Interventional Cardiology

(This is only professional opinion and not the diagnosis. Please correlate clinically)

Sector 37-D, BPTP, Dwarka Express Way, Gurugram, Hry.,

Ph.: 0124-6034444, 8526000000, E-mail : signaturehospital@gmail.com, Web.: www.thesignaturehealthcare.com
PARK GROUP OF HOSPITAL : ★ West Delhi ★ South Delhi ★ Gurugram ★ Faridabad ★ Panipat ★ Karnal

SIGNATURE HOSPITAL
SEC 3TD GUBURAH

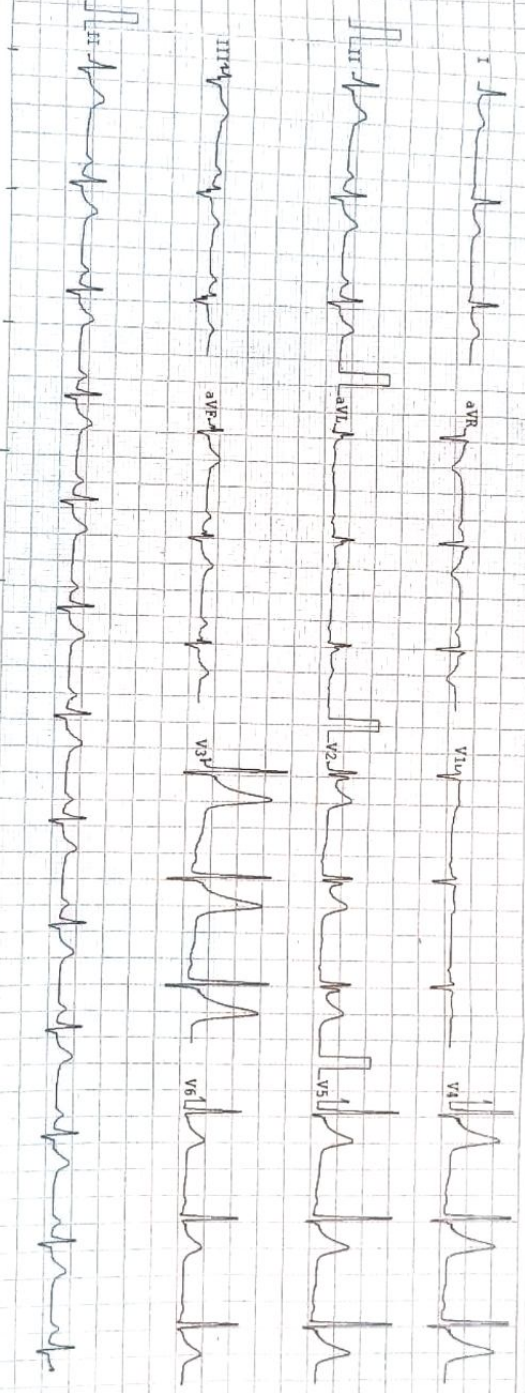
PATIENT INFORMATION

ID: 22509 CASE: -
NAME: MR DURGGA SANKER
AGE: 59 GENDER: M SMOKER: No
HEIGHT: ECG WEIGHT: K9
DOCTOR: DR CMO
REF: -
DATE/TIME: 19/09/2022 09:09:03

ECG SETTINGS

PRINTING MODE: AUTO 3+1
GAIN mm/mV: 1.0
SPEED mm/Sec: 25
FILTER Hz: 0.05 -35
NOTCH/BLC: ON-OFF
RHYTHM LEAD: II

ALLENGERS PISCES (VER-5.02)



OBSERVATIONS

HEART RATE: 73 bpm
R-R: 812 ms
P-R: 152 ms
P DUR: 100 ms
QRS: 92 ms
T DUR: 206ms
ST DUR: 54 ms
QT: 352 ms
QTc: 325 ms

INTERPRE

SINUS RHYTHM

REMARKS: -

P AXIS: 77°
 R AXIS: 100°
 T AXIS: 100°
 ST AXIS: 31°