



CID : 2307018682
Name : Mr Sunil Samnani
Age / Sex : 34 Years/Male
Ref. Dr :
Reg. Location : Pimple Saudagar, Pune Main Centre
Reg. Date : 11-Mar-2023
Reported : 11-Mar-2023 / 18:03

ULTRASOUND OF ABDOMEN AND PELVIS

Liver- Normal in size, shape **with slightly raised parenchymal echo pattern s/o grade I fatty Liver.** No focal lesion. Intrahepatic biliary and portal radicals appear normal. Visualized portion of CBD appears normal in calibre. Portal vein appears normal.

Gall bladder- partially distended with normal wall thickness. No calculus or mass lesion noted. No peri-cholecystic collection. No probe tenderness.

Pancreas- Head and body are visualized and appear normal in size, shape and echo pattern. No focal lesion seen. No peripancreatic collection noted.

Spleen - Appears normal in size (9.3cm), shape & echo pattern. No focal lesion seen.

Kidneys- Right kidney - 9.7 x 4.9 cm, Left kidney - 12.4 x 5.1 cm, both kidneys appear normal in size, shape, position & echo pattern with maintained cortico-medullary differentiation. Tiny papillary concretions are noted in both the kidneys. No hydronephrosis, hydroureter or calculus noted.

Urinary bladder- Is partially distended & shows normal wall thickness. No calculus or mass lesion is noted.

Prostate - appears normal in size, shape and echo-pattern for age. No focal lesion.

No free fluid in abdomen and pelvis.

Visualized bowel loops are gaseously distended appear grossly normal and show normal peristalsis. No evidence of enlarged lymph nodes.

IMPRESSION:

Grade I fatty Liver - Advice LFT correlation

Advice - Clinical correlation and further evaluation if clinically indicated.

Ghodaake

Dr. SATYAJEET S. GHODAKE
MBBS, MD, DNB, MNAMS.
Regd. No. 2013/05/1417
Consultant Radiologist

-----End of Report-----

This report is prepared and physically checked by DR SATYAJEET before dispatch.
Investigations have their own limitations. Solitary radiological investigation never leads to a final diagnosis. They should be always correlated with clinical and pathological examinations.

Click here to view images <http://3.111.232.119/iRISViewer/NeoradViewer?AccessionNo=2023031109033773>

TMT

11-3-23

Sunil Samnani
34/M

PHY2.

R
E
P
O
R
T

History and Complaints:

NIL

EXAMINATION FINDINGS:

Height (cms):	174		Weight (kg):	82	BMI
Temp (0c):	Afebrile		Skin:	Normal	} <i>msd</i>
Blood Pressure (mm/hg):	110/80		Nails:	Healthy	
Pulse:	86		Lymph Node:	Not Palpable	

Systems

Cardiovascular: S1,S2 Normal No Murmurs

Respiratory: Air Entry Bilaterally Equal

Genitourinary: Normal

GI System: Soft non tender No Organomegaly

CNS: Normal

} *msd*

IMPRESSION:

Grade 1 ^{FII} fatty liver



ADVICE:

Diet + Regular exercise.


CHIEF COMPLAINTS:

- 1) Hypertension:
- 2) IHD:
- 3) Arrhythmia:
- 4) Diabetes Mellitus :
- 5) Tuberculosis :
- 6) Asthama:
- 7) Pulmonary Disease :
- 8) Thyroid/ Endocrine disorders :

} *msd*

9)	Nervous disorders :	
10)	GI system :	
11)	Genital urinary disorder :	
12)	Rheumatic joint diseases or symptoms :	
13)	Blood disease or disorder :	
14)	Cancer/lump growth/cyst :	
15)	Congenital disease :	
16)	Surgeries :	

PERSONAL HISTORY:

1)	Alcohol	
2)	Smoking	
3)	Diet	
4)	Medication	



Dr. KRUTIKA INGLE
 MBBS, D.DM, PG in Diabetology (USA)
 MMC Regd - 2012 103018

Preventive Health Check-up | Pathology | Digital X-Ray | Sonography | Colour Doppler | Mammography | BMD (DXA Scan) | OPG | ECG
Stress Test/TMT | 2D Echo | Spirometry | Eye Examination | Dental Examination | Diet Consultation | Audiometry | OT Sterility | Water Sterility | Clinical Research

Date:- 11-3-23
Name:- Sunil Samnani

CID:
Sex / Age: 36 M

EYE CHECK UP

Chief complaints:

Systemic Diseases:

Past history:

Unaided Vision:

Aided Vision:

Refraction:

gms
na
na

	(Right Eye)				(Left Eye)			
	Sph	Cyl	Axis	Vn	Sph	Cyl	Axis	Vn
Distance				6/6				6/6
Near				12/6				12/6

Colour Vision: Normal / Abnormal

Remark:

na

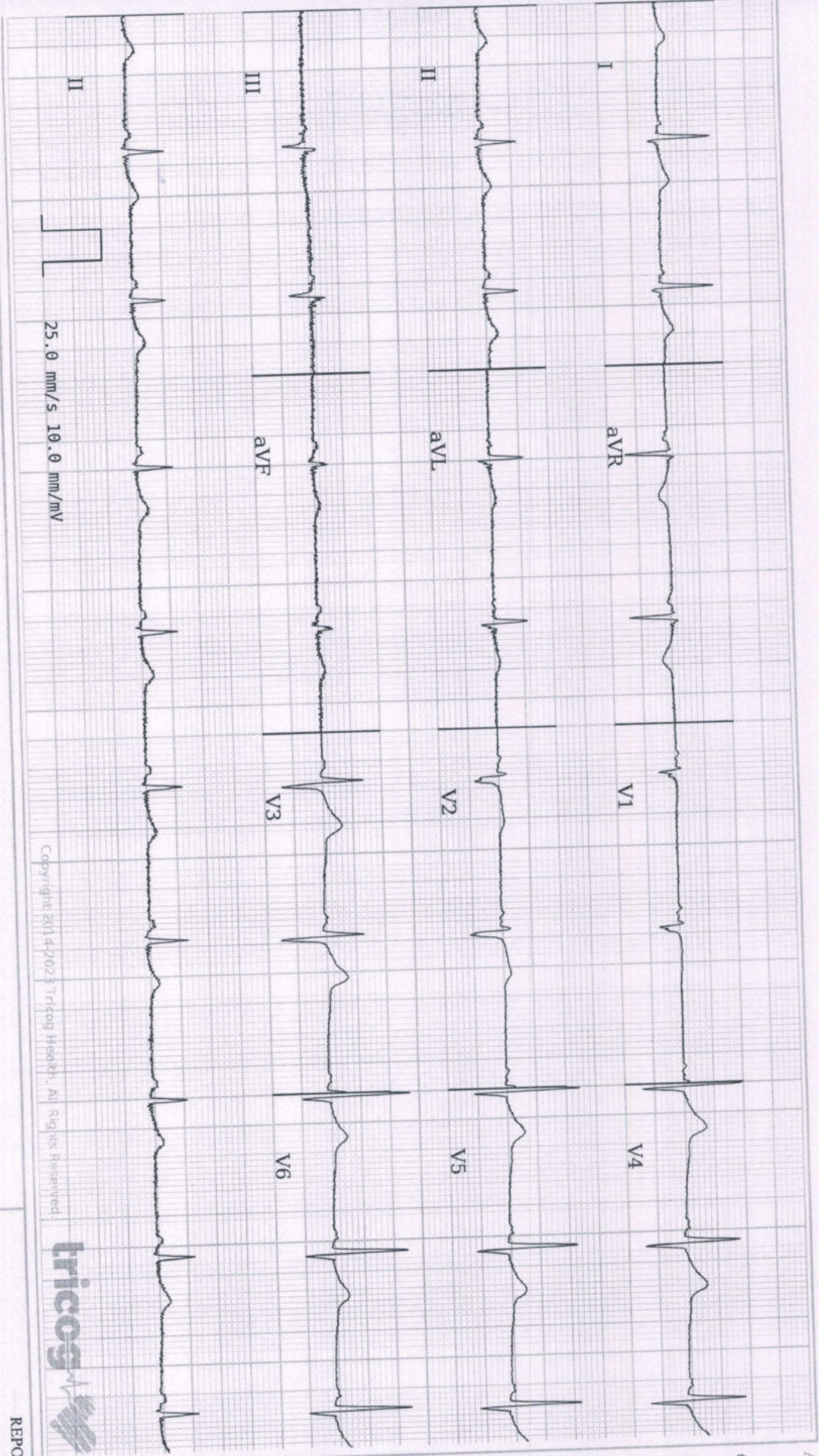
[Signature]

Dr. KRUTIKA INGLE

MBBS, D.DM, PG in Diabetology (USA)
MMC Regd - 2012 103018

Patient Name: **SUNIL SAMNANI**
Patient ID: **2307018682**

Date and Time: **11th Mar 23 9:39 AM**



Age **34** years **3** months **25** days

Gender **Male**

Heart Rate **57bpm**

Patient Vitals

BP: **110/80 mmHg**
Weight: **82 kg**
Height: **174 cm**
Pulse: **86 bpm**
SpO2: **NA**
Resp: **NA**
Others:

Measurements

QRSD: **82ms**
QT: **420ms**
QTc: **408ms**
PR: **120ms**
P-R-T: **49° 21° 31°**

REPORTED BY

[Signature]

Dr. Kratika Ingle
MBBS, D.D.M., PG in Diabetology (USA)
2012103018

Sinus Bradycardia. Please correlate clinically.

Copyright 2014-2023 Tricog Health, All Rights Reserved



Disclaimer: This report is based on ECG alone and should be used as an adjunct to clinical history, symptoms, and results of other invasive and non-invasive tests and must be interpreted by a qualified physician. 21 Patient Vitals are as entered by the clinician and not derived from the ECG.

CID : 2307018682
Name : Mr Sunil Samnani
Age / Sex : 34 Years/Male
Ref. Dr :
Reg. Location : Pimple Saudagar, Pune Main Centre
Reg. Date : 11-Mar-2023
Reported : 11-Mar-2023 / 17:23

Use a QR Code Scanner
Application To Scan the Code

X-RAY CHEST PA VIEW

Trachea is central.

Slightly prominent bronchovascular markings are noted bilaterally.

Visualized bilateral lung fields otherwise appear grossly normal.

Both hila appear normal.

Cardiac silhouette has grossly normal appearance for age.

Bilateral costophrenic and cardiophrenic angles appear grossly normal.

Visualized bony thorax and soft-tissues are grossly normal for age.

IMPRESSION :

Slightly prominent bronchovascular markings are noted bilaterally.

No other significant abnormality detected

Advice - Clinical correlation and further evaluation if clinically indicated.

Dr. SATYAJEET S. GHODAKE
MBBS, MD, DNB, MNAMS.
Regd. No. 2013/05/1417
Consultant Radiologist

-----End of Report-----


This report is prepared and physically checked by DR SATYAJEET before dispatch.
Investigations have their own limitations. Solitary radiological investigation never leads to a final diagnosis. They should be always correlated with clinical and pathological examinations.

Click here to view images <<ImageLink>>

भारत सरकार
Government of India

अधार

Download Date: 22/01/2021



Sunil Suresh Samnani
Date of Birth/DOB: 17/11/1988
Male/ MALE

Issue Date: 29/12/2020

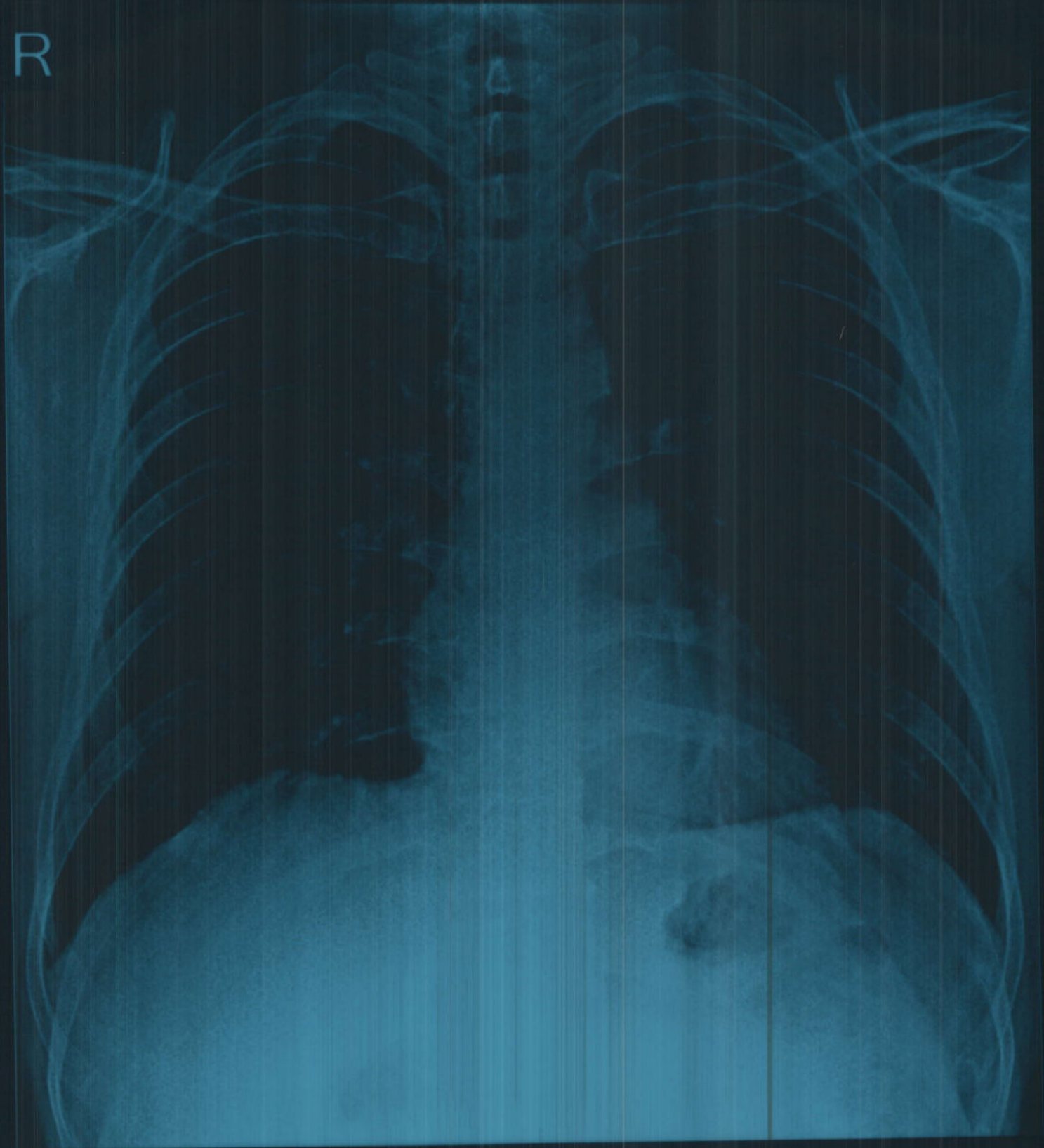2594 6133 5309
VID : 9119 1501 4732 2043

मेरा आधार, मेरी पहचान

Sunil

SUBURBAN DIAGNOSTIC (I) PVT. LTD.
"Fortuna" Ground Floor, Near Shivar
Garden Chowk, Next to Radha Krishna
Hotel, Pimple Saudagar, Pune-411 027.

R



Mr Sunil Samnani M 034Y 2307018682 CHEST PA 3/11/2023
SUBURBAN DIAGNOSTICS PIMPLE SAUDAGAR