

Blood Pressure : 100/64 mm of Hg

Height : 174 cm

Weight : 74 Kg

Body Mass Index : 24.5

EMERGENCY

ACCIDENT & TRAUMA LINE

 Home Care
Service At Your
Doorstep

Medicine Delivery at Your Doorstep Call.:

07720965555

Patient Name : MR. ABHIJIT S DESHMUKH

Age/Sex : 38 Yrs / Male

Order Date : 11/02/2023 10:19 AM

UHID : WHN2.0000334255

Referred by :

Reporting Date : 11/02/2023 02:58 PM

Order No. : 1573

Bill No. : OCR3/23/0000302

CHEST X-RAY PA VIEW :

Both lung fields are clear.

The costophrenic angles and domes of diaphragm appear normal.

No hilar or mediastinal lesion seen.

Cardiac silhouette is within normal limits.

Visualised bony thorax and soft tissues appear normal.

Impression:

Normal Chest X-Ray.

DR. PREETI CHOUDHARY JAIN
M.B.B.S., D.M.R.E.
RADIOLOGIST

WOCKHARDT HOSPITALS, NAGPUR

1643, North Ambazari Road, Nagpur - 440 010. Tel : (0712) 6624444, 6624100

Fax : (0712) 2261266 Website : www.wockhardthospitals.com

Registered Office Address :- Wockhardt Towers, BKC, Bandra (East) Mumbai 400051

CIN: U85100MH1991PLC063096

Patient Name : MR. ABHIJIT S DESHMUKH
 Age/Sex : 38 Yrs / Male
 UHID : WHN2.0000334255
 Reporting Date : 11/02/2023 02:32 PM
 Bill No. : OCR3/23/0000302

Order Date : 11/02/2023 10:19 AM
 Referred by :
 Order No. : 1573

USG ABDOMEN WITH PELVIS :

Real time sonography of the abdomen and pelvis was performed using the 3.5 MHz transducer.

The liver is normal in size and echotexture. No focal parenchymal lesion noted.

Intrahepatic biliary tree and venous radicles are normal.

The portal vein and CBD appear normal in course and calibre.

The gall bladder is collapsed.

The pancreas is normal in size and echotexture. No evidence of focal lesion or calcification or duct dilatation seen.

The spleen is normal in size and echotexture.

Both kidneys are normal in size, position and echogenecity.

Cortical thickness and corticomedullary differentiation are normal.

No hydronephrosis or calculi noted.


The bladder is normal in contour, capacity and wall thickness. No vesical calculi noted.

The prostate is normal in size and homogenous in echotexture.

There is no evidence of ascites.

Impression :

No significant abnormality noted on this study.



DR. PREETI CHOUDHARY JAIN
 M.B.B.S., D.M.R.E.
 RADIOLOGIST



DEPARTMENT OF LABORATORY MEDICINE

HEMATOLOGY

WOCKHARDT
HOSPITALS

LIFE
Final Report

Patient Name	: MR. ABHIJIT S DESHMUKH	Order Date	: 11/02/2023 10:19 AM
Age / Sex	: 38 Years / Male	Sample Collection	: 11/02/2023 10:29 AM
UHID	: WHN2.0000334255	Report Date	: 11/02/2023 12:19 PM
Primary Consultant	: DR. WOCKHARDT DOCTOR	Specimen	: EDTA Blood
Order No.	: 4155		
Bill No.	: OCR3/23/0000302		

PARAMETER	METHOD	RESULT	UNIT	B.R.I
MEDIWHEEL FULL BODY HCU MALE AND FEMALE BELOW 40				
Complete Blood Count (With ESR)- EDTA Blood				
Haemoglobin	SLS Method	14.7	g%	11-15
Haematocrit	RBC Pulse Height Detection	43.3	%	40 - 50
MCV	Calculated	91.0	fl	83-101
MCH	Calculated	30.9	pg	27-32
MCHC	Calculated	33.9	g/dl	32-35
RBC Count	DC Detection	4.76	Million/ul	4.5-5.5
RDW-CV	Calculated	12.8	%	12-14
WBC Total Count (TLC)	Electrical Impedance	6530	Cells/cumm	4000 - 10000
Neutrophils	Hydrodynamic Focussing And Microscopy	55.8	%	40-80
Lymphocytes	Hydrodynamic Focussing And Microscopy	34.9	%	20-40
Monocytes	Hydrodynamic Focussing And Microscopy	7.5	%	2-10
Eosinophils	Hydrodynamic Focussing And Microscopy	1.5	%	0-6
Basophils		0.3	%	0-2
Platelet Count	Hydrodynamic Focusing DC	254	Thou/Cumm	150-450
MPV		8.8	Calculated	9.4-12.3
Neutrophil Lymphocyte Ratio		1.59		



WOCKHARDT HOSPITALS, NAGPUR

1643, North Ambazari Road, Nagpur - 440 010. Tel : (0712) 6624444, 6624100

Fax : (0712) 2261266 Website : www.wockhardthospitals.com

Registered Office Address :- Wockhardt Towers , BKC , Bandra (East) Mumbai 400051

CIN: U85100MH1991PLC063096

--- END OF REPORT ---



SONAL SINGH
Verified By

Dr. ALKA THOOL
Consultant Pathologist
M.B.B.S, MD PATH

Partial Reproduction of Report not permitted. This Report Relates to Sample received by Laboratory
* B.R.I : BIOLOGICAL REFERENCE INTERVAL ** Test not in Scope of Accreditation



WOCKHARDT HOSPITALS, NAGPUR

1643, North Ambazari Road, Nagpur - 440 010. Tel : (0712) 6624444, 6624100

Fax : (0712) 2261266 Website : www.wockhardthospitals.com

Registered Office Address :- Wockhardt Towers , BKC , Bandra (East) Mumbai 400051

CIN: U85100MH1991PLC063096

DEPARTMENT OF LABORATORY MEDICINE

BIOCHEMISTRY

WOCKHARDT
HOSPITALS


LIFE
WING
Final Report

Patient Name : MR. ABHIJIT S DESHMUKH
 Age / Sex : 38 Years / Male
 UHID : WHN2.0000334255
 Primary Consultant : DR. WOCKHARDT DOCTOR
 Order No. : 4155
 Bill No. : OCR3/23/0000302
 Order Date : 11/02/2023 10:19 AM
 Sample Collection : 11/02/2023 10:29 AM
 Report Date : 11/02/2023 01:39 PM
 Specimen : EDTA Blood

PARAMETER	METHOD	RESULT	UNIT	B.R.I
MEDIWHEEL FULL BODY HCU MALE AND FEMALE BELOW 40				
Glycosylated Haemoglobin- EDTA Blood				
Glycosylated Haemoglobin	HPLC	5.9	%	Action required: 7.0-8.0% Good control: 6.5-7.0% Normal control: 4.8-6.4% Poor control: >8.0%
Estimated Mean glucose	Calculated	132.74	mg/dL	

--- END OF REPORT ---

JWALA GAJBHIYE
Verified By



Dr. ALKA THOOL
Consultant Pathologist
M.B.B.S, MD PATH

Partial Reproduction of Report not permitted. This Report Relates to Sample received by Laboratory
 * B.R.I : BIOLOGICAL REFERENCE INTERVAL ** Test not in Scope of Accreditation



DEPARTMENT OF LABORATORY MEDICINE

BIOCHEMISTRY




Patient Name : MR. ABHIJIT S DESHMUKH
 Age / Sex : 38 Years / Male
 UHID : WHN2.0000334255
 Primary Consultant : DR. WOCKHARDT DOCTOR
 Order No. : 4155
 Bill No. : OCR3/23/0000302
 Order Date : 11/02/2023 10:19 AM
 Sample Collection : 11/02/2023 12:59 PM
 Report Date : 11/02/2023 01:46 PM
 Specimen : Fluoride Plasma

PARAMETER	METHOD	RESULT	UNIT	B.R.I
MEDIWHEEL FULL BODY HCU MALE AND FEMALE BELOW 40				
Plasma Glucose- Post Glucose		91	mg/dL	70-140
Urine Sugar Post Prandial	Double Sequential Enzyme Reaction - GOD/ POD	NA		

--- END OF REPORT ---

JWALA GAJBHIYE
 Verified By


 Dr. ALKA THOOL
 Consultant Pathologist
 M.B.B.S, MD PATH

Partial Reproduction of Report not permitted. This Report Relates to Sample received by Laboratory
 * B.R.I : BIOLOGICAL REFERENCE INTERVAL ** Test not in Scope of Accreditation



WOCKHARDT HOSPITALS, NAGPUR

1643, North Ambazari Road, Nagpur - 440 010. Tel : (0712) 6624444, 6624100

Fax : (0712) 2261266 Website : www.wockhardthospitals.com

Registered Office Address :- Wockhardt Towers , BKC , Bandra (East) Mumbai 400051

CIN: U85100MH1991PLC063096

DEPARTMENT OF LABORATORY MEDICINE

BIOCHEMISTRY

WOCKHARDT
HOSPITALS

LIFE
WINS
Final Report

Patient Name : MR. ABHIJIT S DESHMUKH
 Age / Sex : 38 Years / Male
 UHID : WHN2.0000334255
 Primary Consultant : DR. WOCKHARDT DOCTOR
 Order No. : 4155
 Bill No. : OCR3/23/0000302
 Order Date : 11/02/2023 10:19 AM
 Sample Collection : 11/02/2023 10:29 AM
 Report Date : 11/02/2023 01:46 PM
 Specimen : Serum

PARAMETER	METHOD	RESULT	UNIT	B.R.I
MEDIWHEEL FULL BODY HCU MALE AND FEMALE BELOW 40				
Serum Urea	Urease-GLDH	18	mg/dL	1-50
Blood Urea Nitrogen	Calculated	8.5	mg/dL	6-20
Creatinine- Serum				
Creatinine	Enzymatic colorimetric	0.81	mg/dL	0.67-1.17
Plasma Glucose				
Random Sugar		89.26	mg/dl	
Uric Acid- Serum				
Uric Acid	Enzymatic colorimetric	5.7	mg/dL	3.4-7
Cholesterol	Colorimetric - Cholesterol Oxidase	228.34	mg/dL	0-200
Triglycerides	Enzymatic colorimetric	108.6	mg/dL	0-150
HDL Cholesterol - Direct	Direct Homogenous Enzymatic Colorimetric	68.2		>65: No risk 45-65 : Moderate risk <45: High risk
LDL-Cholesterol -Direct	Direct Homogenous Enzymatic Colorimetric	138.42	mg/dL	0-100
VLDL Cholesterol	Calculated	21.72	mg/dL	10-35
Chol/HDL Ratio		3.34		0-3



DEPARTMENT OF LABORATORY MEDICINE

BIOCHEMISTRY

WOCKHARDT
HOSPITALS

LIFE
WINGS
Final Report

Patient Name	: MR. ABHIJIT S DESHMUKH	Order Date	: 11/02/2023 10:19 AM
Age / Sex	: 38 Years / Male	Sample Collection	: 11/02/2023 10:29 AM
UHID	: WHN2.0000334255	Report Date	: 11/02/2023 01:46 PM
Primary Consultant	: DR. WOCKHARDT DOCTOR	Specimen	: Serum
Order No.	: 4155		
Bill No.	: OCR3/23/0000302		

PARAMETER	METHOD	RESULT	UNIT	B.R.I
-----------	--------	--------	------	-------


MEDIWHEEL FULL BODY HCU MALE AND FEMALE BELOW 40

Liver Function Test (L.F.T.)

Alkaline Phosphatase	Colorimetric IFCC	71.3	U/L	40-129
Total Protein (Serum)	Colorimetric - Biuret Method	6.77	g/dL	6.4-8.3
Albumin, BCG	Colorimetric - Bromo-Cresol Green	4.52	g/dL	3.5-5.2
Globulin	Calculated	2.25	g/dL	1.9-3.5
Albumin/Globulin Ratio	Calculated	2.00		0.9-2
Serum Total Bilirubin	Colorimetric Diazo	0.47	mg/dL	0-1.2
Serum Direct Bilirubin	Colorimetric Diazo	0.16	mg/dL	0-0.4
Serum Indirect Bilirubin	Calculated	0.31	mg/dL	0-1

--- END OF REPORT ---

SONAL SINGH
Verified By


Dr. ALKA THOOL
Consultant Pathologist
M.B.B.S, MD PATH

Partial reproduction of Report not permitted. This Report Relates to Sample received by Laboratory
* B.R.I : BIOLOGICAL REFERENCE INTERVAL ** Test not in Scope of Accreditation




IMMUNOLOGY

Patient Name : MR. ABHIJIT S DESHMUKH
Age / Sex : 38 Years / Male Order Date : 11/02/2023 10:19 AM
UHID : WHN2.0000334255 Sample Collection : 11/02/2023 10:29 AM
Primary Consultant : DR. WOCKHARDT DOCTOR Report Date : 11/02/2023 12:05 PM
Order No. : 4155 Specimen : Serum
Bill No. : OCR3/23/0000302

PARAMETER	METHOD	RESULT	UNIT	B.R.I
MEDIWHEEL FULL BODY HCU MALE AND FEMALE BELOW 40				
TOTAL T3	ECLIA	106.1	ng/dl	80-200
TOTAL T4	ECLIA	7.90	ug/dl	4.5-11.7
TSH	ECLIA	3.66	μIU/mL	0.27-4.2

--- END OF REPORT ---

SONAL SINGH
Verified By


Dr. ALKA THOOL
Consultant Pathologist
M.B.B.S, MD PATH



DEPARTMENT OF LABORATORY MEDICINE

CLINICAL PATHOLOGY

WOCKHARDT HOSPITALS

LIFE WINS Final Report

Patient Name : MR. ABHIJIT S DESHMUKH
Age / Sex : 38 Years / Male Order Date : 11/02/2023 10:19 AM
UHID : WHN2.0000334255 Sample Collection : 11/02/2023 10:29 AM
Primary Consultant : DR. WOCKHARDT DOCTOR Report Date : 11/02/2023 11:52 AM
Order No. : 4155 Specimen : Urine
Bill No. : OCR3/23/0000302

PARAMETER METHOD RESULT UNIT B.R.I

MEDIWHEEL FULL BODY HCU MALE AND FEMALE BELOW 40


Urine Routine

Physical Examination

Colour	yellow		
Appearance	Clear		
Urinalyser (Roche UriSys 1100)			
Specific Gravity	1.025		1.003 - 1.035
Reaction (pH)	5		
Leukocytes, microscopy	neg	/hpf	
Erythrocytes, microscopy	neg	/hpf	
Nitrite, urinalyser	neg		
Protein, urinalyser	neg		
Glucose, urinalyzer	neg		
Ketone, urinalyser	neg		
Urobilinogen urinalyser	neg		
Billirubin uirnalyser	neg		

--- END OF REPORT ---

WALA GAJBHIYE
Verified By


Dr. ALKA THOOL
Consultant Pathologist
M.B.B.S, MD PATH



2D ECHOCARDIOGRAPHY & DOPPLER REPORT

Name	: Mr. Abhijit Deshmukh	Age / Sex	: 38 yrs / Male
Done by	: Dr. Nitin Tiwari	Date	: February 11, 2023
OPD		UHID	: 334255

Comments :

Sector echo done in plax, psax, apical 4 & 5 chambers, subcostal view shows:

Normal morphology of aortic, mitral, tricuspid and pulmonary valves.

The left atrium, left ventricle, right atrium and right ventricle are normal in dimension and morphology. There is no regional wall motion abnormality of left ventricle at rest. The left ventricular systolic function is **good**. The global left ventricular ejection fraction is 63 %.

The IAS and IVS are intact.

The pericardium is normal. There is no pericardial effusion.

There is no clot or vegetation seen.

CW, PW and Colour Doppler: Transmitral flow is suggestive of normal left ventricular diastolic function. There is trivial tricuspid regurgitation. There is no evidence of pulmonary hypertension.

Impression:

Normal cardiac valves and chamber dimensions

No regional wall motion abnormality of left ventricle at rest

Good left ventricular systolic function. LVEF – 63 %

Normal LV diastolic function

No pulmonary hypertension

Dr. Nitin Tiwari
MD, DNB (Med.), DM, DNB (Card.),
MNAMS, MAPSIC
Sr. Interventional Cardiologist



WOCKHARDT HOSPITALS, NAGPUR

1643, North Ambazari Road, Nagpur - 440 010, Tel : (0712) 6624444, 6624100

Fax : (0712) 2261266 Website : www.wockhardthospitals.com

Registered Office Address :- Wockhardt Towers , BKC , Bandra (East) Mumbai 400051

CIN: U85100MH1991PLC063096

Rate 69 . Age not entered, assumed to be 50 years old for purpose of ECG interpretation
 . Sinus rhythm.....normal P axis, V-rate 50-99
 . Borderline T wave abnormalities.....T/QRS ratio < 1/20 or flat T

PR 132
 QRSD 87
 QT 382
 QTc 410

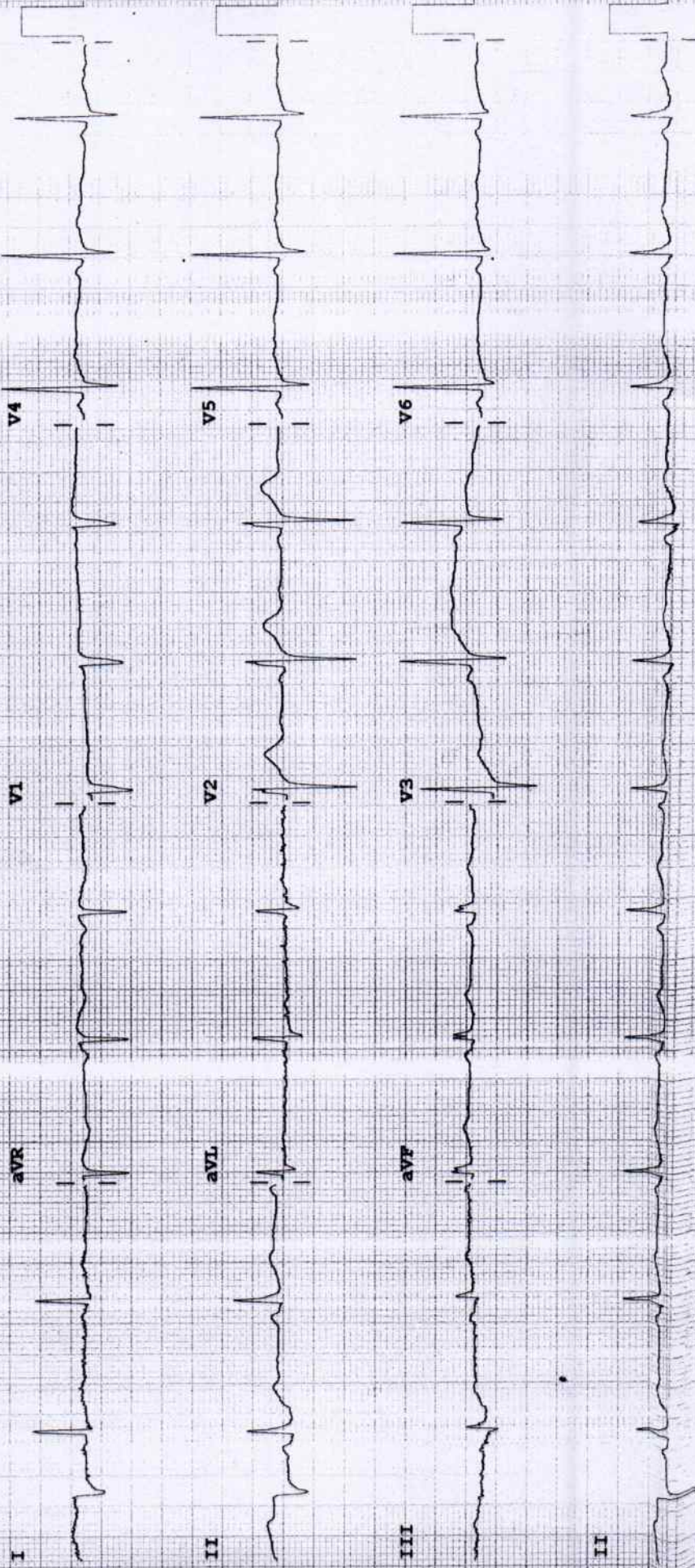
--AXIS--

P 60
 QRS 40
 T 55

- BORDERLINE ECG -

12 Lead; Standard Placement

Unconfirmed Diagnosis



Device:

Speed: 25 mm/sec

Limb: 10 mm/mV

Chest: 10.0 mm/mV

F 60~ 0.15-100 Hz

PH100B CL

P?

Name : Abhijit Doshmulech Age/ Sex : yrs / Date: 11/4/23

Fundus Examination
(Direct Ophthalmoscopy)

	Right	Left
Media	Cec	Cec
<u>Optic Disc</u>		
Colour		
Size		
Shape		
Margin		
NRR		
C:D	0.7:1	0.6:1

Blood Vessels
A:V ratio
Abnormalities

Macula
FR
Abnormalities

+ +

Periphery

Impression

Adv
- Perimetry 24-2 (BC)
- OCT RNFL (BE)
L

Dr. NITIN DHOK
9096377550
Consultant Ophthalmology



WOCKHARDT HOSPITALS, NAGPUR

1643, North Ambazari Road, Nagpur - 440 010. Tel : (0712) 6624444, 6624100

Fax : (0712) 2261266 Website : www.wockhardthospitals.com

Registered Office Address :- Wockhardt Towers , BKC , Bandra (East) Mumbai 400051

CIN: U85100MH1991PLC063096