

Baabi Biswas

CHECK LIST			
NAME			PATHOLOGY/PP
OP			EKG/PFT
AGE			ECHO/TMT
DATE	11/03/23		USG / CXR
PACKAGE			URINE / STOOL
REFERRED BY			MAMMO/ PAP
HT	151cm		EYE/ DENTAL
WT	54kg		GP CONSULTATION
BP	100/70 mmHg		DIETITION
PULSE	95bpm		CARDIOLOGIST
WAIST	89 cm		GYNECOLOGIST
HIP	91cm		DENTAL
RESPIRATORY RATE			
CHEST (INHALE)	96cm		
CHEST (EXHALE)	98cm		
ABDOMEN	96cm		

SPO₂ — 98%

Bony Bony



LABORATORY INVESTIGATION REPORT

Patient Name : Mrs. BANTI BISWAS

UHID : NMHK.2305846

Episode : OP

Ref. Doctor : NMH

Address : 57/7 R.N. TAGORE ROAD , THAKURPUKUR ,Kolkata
a,West Bengal ,700063

Age/Sex : 33 Year(s)/Female

Order Date : 11/03/2023 09:18

Mobile No : 6289558097

DOB : 10/03/1990

Facility : NARAYAN MEMORIAL HOSPITAL

Biochemistry

INVESTIGATION	RESULTS	UNITS	BIOLOGICAL REF RANGE
---------------	---------	-------	----------------------

Sample No : 07H0106055

Collection Date : 11/03/23 09:31

Ack Date : 11/03/2023 14:09

Report Date : 13/03/23 13:10

SERUM CREATININE

SAMPLE : SERUM

SERUM CREATININE

Jaffe Gen2 Compensated

0.6

mg/dl

0.5 - 0.9

BLOOD UREA NITROGEN

BLOOD UREA NITROGEN

Calculated

06

mg/dl

6 - 20

URIC ACID

SAMPLE : SERUM

URIC ACID

Enzymatic Colorimetric

4.6

mg/dl

2.4 - 5.7

SAMPLE : SERUM

RESULT

10.0

Sample No : 07H0106055B

Collection Date : 11/03/23 09:31

Ack Date : 11/03/2023 14:10

Report Date : 13/03/23 13:10

BLOOD SUGAR(F)

SAMPLE : PLASMA

BLOOD SUGAR FASTING

Hexokinase

91

mg/dl

70 - 109

Sample No : 07H0106115B

Collection Date : 11/03/23 13:22

Ack Date : 11/03/2023 14:37

Report Date : 13/03/23 13:10

BLOOD SUGAR(PP)

SAMPLE : PLASMA

BLOOD SUGAR PP

Hexokinase

133

mg/dl

70 - 140

End of Report



LABORATORY INVESTIGATION REPORT

Patient Name : Mrs. BANTI BISWAS

UHID : NMHK.2305846

Episode : OP

Ref. Doctor : NMH

Address : 57/7 R.N. TAGORE ROAD , THAKURPUKUR ,Kolkata
a,West Bengal ,700063

Age/Sex : 33 Year(s)/Female

Order Date : 11/03/2023 09:18

Mobile No : 6289558097

DOB : 10/03/1990

Facility : NARAYAN MEMORIAL HOSPITAL

Dr.S. Chatterjee
MD, MBBS, FAACC
(CONSULTANT BIOCHEMIST)

Checked By



LABORATORY INVESTIGATION REPORT

Patient Name : Mrs. BANTI BISWAS

UHID : NMHK.2305846

Episode : OP

Ref. Doctor : NMH

Address : 57/7 R.N. TAGORE ROAD , THAKURPUKUR ,Kolkata
a,West Bengal ,700063

Age/Sex : 33 Year(s)/Female

Order Date : 11/03/2023 09:18

Mobile No : 6289558097

DOB : 10/03/1990

Facility : NARAYAN MEMORIAL HOSPITAL

Biochemistry

INVESTIGATION	RESULTS	UNITS	BIOLOGICAL REF RANGE
Sample No : 07H0106055	Collection Date : 11/03/23 09:31	Ack Date : 11/03/2023 14:09	Report Date : 13/03/23 13:10

LIVER FUNCTION TEST (LFT)

SAMPLE : SERUM

TOTAL BILIRUBIN <i>Diazo Method</i>	0.5	mg/dl	0 - 1.1
DIRECT BILIRUBIN <i>Diazo Method</i>	0.2	mg/dl	0 - 0.2
INDIRECT BILIRUBIN <i>Calculated</i>	0.3	mg/dl	0.2 - 0.9
SGPT (ALT) <i>IFCC Without Pyridoxal Phosphate</i>	39 ▲	U/L	0 - 34
SGOT (AST) <i>IFCC Without Pyridoxal Phosphate</i>	30	U/L	0 - 31
ALKALINE PHOSPHATASE <i>IFCC</i>	126	U/L	53 - 128
TOTAL PROTEIN <i>Biuret</i>	8.1	g/dl	6.4 - 8.2
ALBUMIN <i>Bromocresol Green</i>	4.8	gm/dl	3.5 - 5.2
GLOBULIN <i>Calculated</i>	3.3	g/dl	2 - 3.5
ALBUMIN:GLOBULIN <i>Calculated</i>	1.5	-	1.1 - 2.5
GGT <i>Enzymatic colorimetric assay</i>	21	U/L	5 - 36



LABORATORY INVESTIGATION REPORT

Patient Name : Mrs. BANTI BISWAS

UHID : NMHK.2305846

Episode : OP

Ref. Doctor : NMH

Address : 57/7 R.N. TAGORE ROAD , THAKURPUKUR ,Kolkata
a,West Bengal ,700063

Age/Sex : 33 Year(s)/Female

Order Date : 11/03/2023 09:18

Mobile No : 6289558097

DOB : 10/03/1990

Facility : NARAYAN MEMORIAL HOSPITAL

End of Report

Dr.S. Chatterjee
MD, MBBS, FAACC
(CONSULTANT BIOCHEMIST)

Checked By



LABORATORY INVESTIGATION REPORT

Patient Name : Mrs. BANTI BISWAS

UHID : NMHK.2305846

Episode : OP

Ref. Doctor : NMH

Address : 57/7 R.N. TAGORE ROAD , THAKURPUKUR ,Kolkata
a,West Bengal ,700063

Age/Sex : 33 Year(s)/Female

Order Date : 11/03/2023 09:18

Mobile No : 6289558097

DOB : 10/03/1990

Facility : NARAYAN MEMORIAL HOSPITAL

Biochemistry

INVESTIGATION	RESULTS	UNITS	BIOLOGICAL REF RANGE
Sample No : 07H0106055	Collection Date : 11/03/23 09:31	Ack Date : 11/03/2023 14:09	Report Date : 13/03/23 13:10

LIPID PROFILE

SAMPLE : SERUM

TOTAL CHOLESTEROL	156	mg/dl	Desirable <200 Borderline 200-239 High >=240
<i>CHOD-PAP</i>			
HDL CHOLESTEROL	40	mg/dl	40 - 60
<i>Homogenous Enzymatic Colorimetric</i>			
LDL CHOLESTEROL	96	mg/dl	Optimal < 100 Borderline 130
<i>Homogenous Enzymatic Colorimetric</i>			
VLDL	20	mg/dl	0 - 30
<i>CALCULATED</i>			
CHOLESTEROL-HDL RATIO	3.90	-	
LDL-HDL RATIO	2.40	-	
TRIGLYCERIDES	137	mg/dl	Desirable <150 Borderline 150 - 200 High >200

Enzymatic Colorimetric

End of Report

Dr. S. Chatterjee
MD, MBBS, FAACC
(CONSULTANT BIOCHEMIST)

Checked By



LABORATORY INVESTIGATION REPORT

Patient Name : Mrs. BANTI BISWAS

UHID : NMHK.2305846

Episode : OP

Ref. Doctor : NMH

Address : 57/7 R.N. TAGORE ROAD , THAKURPUKUR ,Kolkata
a,West Bengal ,700063

Age/Sex : 33 Year(s)/Female

Order Date : 11/03/2023 09:18

Mobile No : 6289558097

DOB : 10/03/1990

Facility : NARAYAN MEMORIAL HOSPITAL

Hematology

INVESTIGATION	RESULTS	UNITS	BIOLOGICAL REF RANGE
Sample No : 07H0106055	Collection Date : 11/03/23 09:31	Ack Date : 11/03/2023 10:48	Report Date : 11/03/23 13:27

COMPLETE HAEMOGRAM (CBC)

SAMPLE : EDTA BLOOD

HAEMOGLOBIN (HB) <i>Colorimetric method (Cyn Meth)</i>	12.1	gm/dl	12 - 15
RBC COUNT <i>Electrical Impedance Method</i>	5.0 ▲	$\times 10^6/\text{ul}$	3.8 - 4.8
TOTAL WBC COUNT <i>Electrical Impedance Method</i>	10.1 ▲	$10^3/\text{cmm}$	4 - 10
PLATELET COUNT <i>Electrical Impedance Method</i>	390	$10^3/\text{cmm}$	150 - 410
PCV <i>RBC pulse ht. detection method</i>	38	%	36 - 46
MCV <i>calculated</i>	75 ▼	fl	83 - 101
MCH <i>Calculated</i>	24 ▼	pg	27 - 32
MCHC <i>Calculated</i>	32	gm/dl	31.5 - 34.5
ESR <i>Modified Westergren Method</i>	30 ▲	%	0 - 12
<u>DIFFERENTIAL COUNT</u>			
NEUTROPHILS <i>Microscopy</i>	65	%	40 - 80
LYMPHOCYTES <i>Microscopy</i>	29	%	20 - 40
MONOCYTES <i>Microscopy</i>	04	%	2 - 10



LABORATORY INVESTIGATION REPORT

Patient Name : Mrs. BANTI BISWAS

UHID : NMHK.2305846

Episode : OP

Ref. Doctor : NMH

Address : 57/7 R.N. TAGORE ROAD , THAKURPUKUR ,Kolkata
a,West Bengal ,700063

Age/Sex : 33 Year(s)/Female

Order Date : 11/03/2023 09:18

Mobile No : 6289558097

DOB : 10/03/1990

Facility : NARAYAN MEMORIAL HOSPITAL

EOSINOPHILS	02	%	1 - 6
<i>Microscopy</i>			
BASOPHILS	00	%	0 - 2
<i>Microscopy</i>			

PERIPHERAL BLOOD SMEAR

RBC	Normocytic normochromic.
WBC	Within normal limits.
PLATELET	Adequate.

End of Report

Angkita K. Ghosh

Dr. ANGKITA K. GHOSH
MBBS, MD(PATH)
(CONSULTANT PATHOLOGIST)

RegNo: 82734

Checked By



LABORATORY INVESTIGATION REPORT

Patient Name : Mrs. BANTI BISWAS

UHID : NMHK.2305846

Episode : OP

Ref. Doctor : NMH

Address : 57/7 R.N. TAGORE ROAD , THAKURPUKUR ,Kolkata
a,West Bengal ,700063

Age/Sex : 33 Year(s)/Female

Order Date : 11/03/2023 09:18

Mobile No : 6289558097

DOB : 10/03/1990

Facility : NARAYAN MEMORIAL HOSPITAL

Immunology

INVESTIGATION	RESULTS	UNITS	BIOLOGICAL REF RANGE
Sample No : 07H0106055	Collection Date : 11/03/23 09:31	Ack Date : 11/03/2023 10:48	Report Date : 11/03/23 15:33

BLOOD GROUPING & Rh TYPING

SAMPLE : EDTA BLOOD

BLOOD GROUP

Agglutination forward & Reverse

RH TYPE

' A '

POSITIVE

End of Report

Angkita K. Ghosh

Dr. ANGKITA K. GHOSH
MBBS, MD(PATH)
(CONSULTANT PATHOLOGIST)

RegNo: 82734

Checked By





LABORATORY INVESTIGATION REPORT

Patient Name : Mrs. BANTI BISWAS

UHID : NMHK.2305846

Episode : OP

Ref. Doctor : NMH

Address : 57/7 R.N. TAGORE ROAD , THAKURPUKUR ,Kolkata
a,West Bengal ,700063

Age/Sex : 33 Year(s)/Female

Order Date : 11/03/2023 09:18

Mobile No : 6289558097

DOB : 10/03/1990

Facility : NARAYAN MEMORIAL HOSPITAL

Immunology

INVESTIGATION	RESULTS	UNITS	BIOLOGICAL REF RANGE
Sample No : 07H0106055	Collection Date : 11/03/23 09:31	Ack Date : 11/03/2023 14:09	Report Date : 13/03/23 13:10

THYROID FUNCTION TEST

SAMPLE : SERUM

T3	1.45	ng/ml	0.60 - 1.80
ECLIA			
T4	9.77	ug/dL	5.40 - 11.70
ECLIA			
TSH	1.43	uIU/ml	Adult Male – 0.27-5.50 Adult Female – 0.27-5.50 Newborns - <25 Upto 12 years – 0.3-5

ECLIA

Interpretations:

1. For diagnostic purposes, the result should always be assessed in conjunction with the patient's medical history, clinical examinations and other findings.

2. The assay is unaffected by icterus (Bilirubin < 701 µmol/L or < 41 mg/dL), hemolysis (Hb < 0.621 mmol/L or < 1 g/dL), lipemia (intrali pid < 1500 mg/dL), biotin (<102 nmol/L or < 25 ng/ml), IgG < 2 g/dL and IgM < 0.5 g/dL)

3. There is no high dose hook effect at TSH concentrations upto 1000 µmol/ml.

4. TSH values may be transiently altered because of non thyroidal illness like several infections, liver disease, renal and heart failure, several burns, trauma and surgery etc. Drugs that decrease TSH values e.g. L-dopa, Glucocorticoid drugs that increase TSH values e.g. Iodine, Lithium, Amiodarone.

5. The assay is unaffected by icterus (bilirubin< 633 µmol/L or < 37 mg/dl), hemolysis (Hb< 1.4 mmol/L or < 2.3 g/dl), lipemia (triglycerid es< 28.5 mmol/L or 2500 mg/dl) and biotin (< 409 nmol or < 100 ng/ml).

6. The assay is unaffected by icterus (bilirubin< 599 µmol/L or < 35 mg/dl), hemolysis (Hb<1.2 mmol/L or < 2.0 g/dl), lipemia (Intralipid< 1800 mg/dl) and biotin (< 123 nmol or < 30 ng/ml).

End of Report

Dr.S. Chatterjee
MD, MBBS, FAACC
(CONSULTANT BIOCHEMIST)

Checked By





LABORATORY INVESTIGATION REPORT

Patient Name : Mrs. BANTI BISWAS
UHID : NMHK.2305846
Episode : OP
Ref. Doctor : NMH
Address : 57/7 R.N. TAGORE ROAD , THAKURPUKUR ,Kolkata
a,West Bengal ,700063
Age/Sex : 33 Year(s)/Female
Order Date : 11/03/2023 09:18
Mobile No : 6289558097
DOB : 10/03/1990
Facility : NARAYAN MEMORIAL HOSPITAL

Clinical Pathology

INVESTIGATION	RESULTS	UNITS	BIOLOGICAL REF RANGE
Sample No : 07H0106055	Collection Date : 11/03/23 09:31	Ack Date : 11/03/2023 12:40	Report Date : 13/03/23 10:42

URINE FOR R/E

SAMPLE : URINE

PHYSICAL EXAMINATION

VOLUME	20	ml	
COLOUR	PALE YELLOW		
APPEARANCE	HAZY		
SPECIFIC GRAVITY	1.010		1.010 - 1.030
REACTION(pH)	ACIDIC (pH-6.0)		

CHEMICAL EXAMINATION

SUGAR	ABSENT		ABSENT
ALBUMIN.	ABSENT		ABSENT
BLOOD	ABSENT		ABSENT
KETONE	ABSENT		ABSENT
BILE SALT	ABSENT		ABSENT
BILE PIGMENTS	ABSENT		ABSENT

MICROSCOPIC EXAMINATION

PUS CELLS	1-2/HPF		<5/HPF
EPITHELIAL CELLS	8-10/HPF		<20/HPF
RBC	ABSENT		
CAST	ABSENT		ABSENT
CRYSTAL	ABSENT		ABSENT
OTHERS	MICRO ORGANISM PRESENT		

Please correlate clinically.

STOOL FOR R/E

SAMPLE : STOOL

PHYSICAL EXAMINATION

COLOUR.	BROWNISH
CONSISTENCY	SEMI-SOLID





LABORATORY INVESTIGATION REPORT

Patient Name : Mrs. BANTI BISWAS	Age/Sex : 33 Year(s)/Female
UHID : NMHK.2305846	Order Date : 11/03/2023 09:18
Episode : OP	Mobile No : 6289558097
Ref. Doctor : NMH	DOB : 10/03/1990
Address : 57/7 R.N. TAGORE ROAD , THAKURPUKUR ,Kolkata a,West Bengal ,700063	Facility : NARAYAN MEMORIAL HOSPITAL

MUCUS ABSENT
VISIBLE BLOOD NOT FOUND
ADULT PARASITE NOT FOUND

CHEMICAL EXAMINATION

REACTION ACIDIC

MICROSCOPIC EXAMINATION

PUS CELLS	0-1/HPF	<5/HPF
VEG CELL	PRESENT	
RBC	ABSENT	
OVA	NOT FOUND	
PARASITES	NOT FOUND	
CYSTS	NOT FOUND	
BACTERIAL FLORA	ABSENT	
FAT GLOBULES	ABSENT	
STARCH GRANULES	PRESENT	

Please correlate clinically.

End of Report

Dr. MAINAK CHAKRABORTY
MBBS, MD(PATH)
(CONSULTANT PATHOLOGIST)

Checked By





DIAGNOSTICS REPORT

Patient Name	: Mrs. BANTI BISWAS	Order Date	: 11/03/2023 09:18
Age/Sex	: 33 Year(s)/Female	Report Date	: 11/03/2023 17:42
UHID	: NMHK.2305846	IP No	:
Ref. Doctor	: NMH	Facility	: NARAYAN MEMORIAL HOSPITAL
Address	: 57/7 R.N. TAGORE ROAD, THAKURPUKUR, Kolkata, West Bengal, 700063	Mobile	: 6289558097

USG REPORT OF WHOLE ABDOMEN (SCREENING)

LIVER : Liver is enlarged in size (15 cm). Parenchymal echogenicity is raised. Intrahepatic biliary radicles are not dilated. No focal mass lesion is seen.

PORTA :PV : Normal. PV measures 0.8 cm.

CBD : Normal . CBD measures 0.2 cm.

GALL BLADDER : Gall bladder is normal in size, contour, outline and position. No calculus is seen. Wall thickness is normal.

PANCREAS : Pancreas is normal in size and parenchymal echogenicity. Pancreatic duct is not dilated.

SPLEEN : Spleen is not enlarged and parenchyma shows normal homogeneous pattern.

KIDNEYS : Both kidneys are normal in size, shape, outline, position and parenchymal echogenicity. Cortico medullary differentiation maintained. No evidence of any calculus/ mass / hydronephrosis is seen.

Right kidney measures : 9.7 cm & Left kidney measures : 9.9 cm.

URINARY BLADDER : Urinary bladder is normal in contour, outline and distension. No vesical lesion is seen.



DIAGNOSTICS REPORT

Patient Name	: Mrs. BANTI BISWAS	Order Date	: 11/03/2023 09:18
Age/Sex	: 33 Year(s)/Female	Report Date	: 11/03/2023 17:42
UHID	: NMHK.2305846	IP No	:
Ref. Doctor	: NMH	Facility	: NARAYAN MEMORIAL HOSPITAL
Address	: 57/7 R.N. TAGORE ROAD, THAKURPUKUR,Kolkata, West Bengal, 700063	Mobile	: 6289558097

UTERUS : Retroflexed , normal in size, shape, outline, position and parenchymal echogenicity. Cavity is empty. Uterus measures 7.6 cm x 4.8 cm x 3.9 cm.

OVARIES : Both ovaries are normal in size, shape and echopattern.

Right ovary : measures 2.8 cm x 2.3 cm.

Left ovary : measures 2.3 cm x 1.0 cm.

PERITONEUM : No free fluid is noted.

RETROPERITONEUM : IVC and aorta appear normal. No lymphadenopathy is seen.

IMPRESSION : Hepatomegaly with diffuse fatty changes.

Dr.MADHUSHREE RAY NASKAR ,
MBBS,DMRD

Consultant Radiologist

RegNo: 57032



DIAGNOSTICS REPORT

Patient Name	: Mrs. BANTI BISWAS	Order Date	: 11/03/2023 09:18
Age/Sex	: 33 Year(s)/Female	Report Date	: 11/03/2023 16:23
UHID	: NMHK.2305846	IP No	:
Ref. Doctor	: NMH	Facility	: NARAYAN MEMORIAL HOSPITAL
Address	: 57/7 R.N. TAGORE ROAD, THAKURPUKUR,Kolkata, West Bengal, 700063	Mobile	: 6289558097

CHEST X-RAY REPORT OF PA VIEW

Lung fields are clear. No focal parenchymal opacity is seen.

No appreciable pleural thickening / calcification is noted.

Costo-phrenic angles are normal.

Cardiac shadow appears normal.

Bilateral hilar shadows are normal.

No obvious bony abnormality is seen.

Dr.Sayani Mahal , MD Radiology (AIIMS), PDCC (AIIMS)

RegNo: 74369



DIAGNOSTICS REPORT

Patient Name	: Mrs. BANTI BISWAS	Order Date	: 11/03/2023 09:18
Age/Sex	: 33 Year(s)/Female	Report Date	: 11/03/2023 15:07
UHID	: NMHK.2305846	IP No	:
Ref. Doctor	: NMH	Facility	: NARAYAN MEMORIAL HOSPITAL
Address	: 57/7 R.N. TAGORE ROAD, THAKURPUKUR,Kolkata, West Bengal, 700063	Mobile	: 6289558097

ELECTROCARDIOGRAM REPORT (ECG)

HR	: 79 bpm
Rhythm	: Sinus
P wave	: Normal
PR Interval	: 158 msec
QRS axis	: Normal (78 Degree)
QRS duration	: 82 msec
QRS configuration	: Normal
T wave	: Non specific changes
ST segment	: Non specific changes
QTc	: 414 msec
QT	: 360 msec

IMPRESSION:

- Sinus rhythm. Normal QRS axis.
- Non specific ST-T changes.

Clinical correlation please.

Dr.INDIRA BANERJEE ,
MD,DNB,MRCPC (UK)

Board Certified Comprehensive
Echocardiographer (USA)

BANTI BISWAS

2305846

33 years Female

..... cm / kg

HR 79/min

Axis: P 38°

QR5 78°

T 36°

SINUS RHYTHM
NORMAL ECG

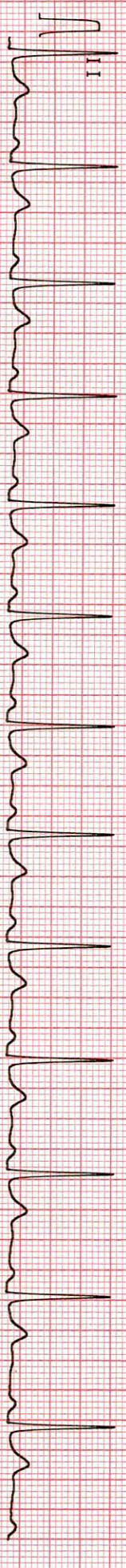
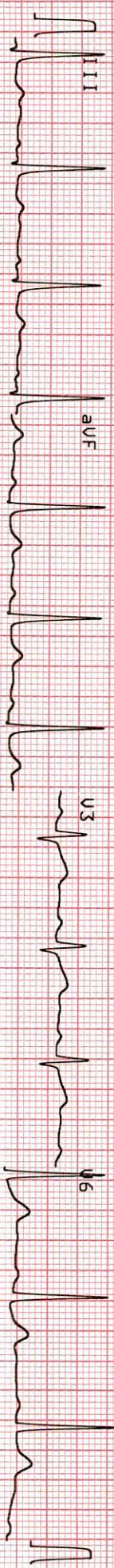
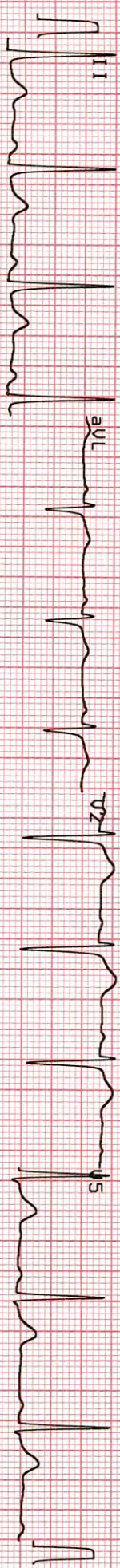
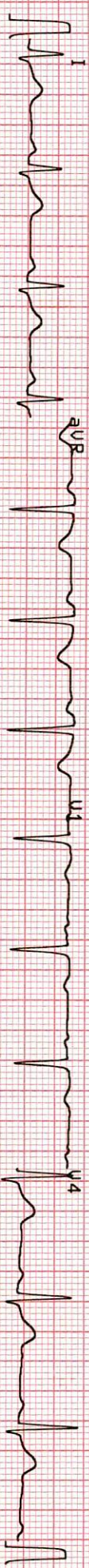
6.02

UNCONFIRMED REPORT

Intervals:
 RR 761 ms
 P 98 ms
 PR 158 ms
 QR5 82 ms
 QT 360 ms
 QTc 414 ms
 (Bazett)
 10 mm/mV

P (I1) 0.10 mV
 S (V1) -1.05 mV
 R (V5) 1.73 mV
 Sokol. 3.31 mV

10 mm/mV



25 mm/s
 10 mm/mV
 0.05-25 Hz F50 SSF 5B5
 11.03.2023 11:49:12
 NARAYAN MEMORIAL HOSPITAL, BEHALA
 AT-102plus 1.25





DIAGNOSTICS REPORT

Patient Name	: Mrs. BANTI BISWAS	Order Date	: 11/03/2023 09:18
Age/Sex	: 33 Year(s)/Female	Report Date	: 11/03/2023 14:28
UHID	: NMHK.2305846	IP No	:
Ref. Doctor	: NMH	Facility	: NARAYAN MEMORIAL HOSPITAL
Address	: 57/7 R.N. TAGORE ROAD, THAKURPUKUR, Kolkata, West Bengal, 700063	Mobile	: 6289558097

ECHOCARDIOGRAPHY (SCREENING)

Status of Patient :

- * No regional wall motion abnormality at rest.
- * Good LV systolic function (EF = 65%).
- * Good RV systolic function (TAPSE = 21 mm).
- * Mild TR. TR gradient = 22 mmHg.
- * Normal valve morphology.
- * Normal LV diastolic function.
- * No pericardial effusion.
- * No pulmonary arterial hypertension.
- * IVC normal diameter & > 50% respiratory variation.
- * No thrombus, mass, vegetation seen.

**Dr.INDIRA BANERJEE ,
MD,DNB,MRCPC (UK)**

Board Certified Comprehensive
Echocardiographer (USA)

