

डॉ. धर्मेंद्र चांदवाणी (एम.एस.)

बिनटाके नेत्र भिंगतज्ञ व कॉन्टॅक्टलेन्स तज्ञ

एकता आय हॉस्पिटल एण्ड लेझर सेंटर

देवळाली प्लाझा, पहिला मंजला, एचडीएफसी बँक समोर,
लॅम रोड, देवळाली कॅम्प, फोन : २४९७२३४ / ९३७०२९५८५४
वेळ : सका १०.३० ते १.३०, सांय ५.३० ते ७.३०

श्रीलीला नेत्रालय

शिवम कॉम्प्लेक्स, पहिला मजला, मुक्तीधामसमोर,
नासिक रोड, फोन : २४५४९९७
वेळ : दु. : १.३० ते ३.०० व सांय. ८.०० ते ९.००

मानद नेत्रतज्ञ - जयराम हॉस्पिटल, नाशिक रोड. फोन : २४६३४९४

रजि. नं. 62917

Mr Vishal Deshpande 24/11/2022

Age: 35 years MR

Routine Eye Checkup

No Complications

BE ext examination NAD

Pupil NDR

⊕

Dist. - 6/6 Unaided
Near N6 Unaided

Fundus (BS) NAD

Ocular movements (N)

Squint - Nil

Chandwan
Dr DR Chandwan

रविवार बंद

सुविधा : बिना टाक्यानी मोतीबिंदू शस्त्रक्रिया

● कॉन्टॅक्टलेन्स ● काचबिंदू, तिरळेपणा इतर शस्त्रक्रिया

DATE :- 24/11/22.

HEIGHT - 165cm

WEIGHT:- 73.70kg



MAGNUM NASHIK HEALTHCARE LLP

MAGNUM

MULTISPECIALITY HOSPITAL

(Health checkup)

S/B DR. JAYDEEP BHAMBARE

PATIENT NAME :- MR. Vishal Deshmukh

AGE /SEX:- 36/MA

Clb

- Health checkup.
- Good exercise tolerance.
- No active complaints.

HbA1c 6.2%

diet / lifestyle modification

BP - 130/80 mmHg
 HR - 66/min.
 SpO₂ - 99.1% on R.A.

fw x 6 mts
 c
 HbA1c / Lipids

CVS - S1S2 ⊕
 CNS - Conscious
 RS -

24/11/22,
 Triglyceride - 209.6
 VLDL Chol - 41.9
 Chol / HDL Chol - 6.46.

LETTER OF APPROVAL / RECOMMENDATION

To,

The Coordinator,
Mediwheel (Arcofemi Healthcare Limited)
Helpline number: 011- 41195959

Dear Sir / Madam,

Sub: Annual Health Checkup for the employees of Bank of Baroda

This is to inform you that the following employee wishes to avail the facility of Cashless Annual Health Checkup provided by you in terms of our agreement.

PARTICULARS	EMPLOYEE DETAILS
NAME	MR. DESHMUKH VISHAL SHESHRAO
EC NO.	168698
DESIGNATION	SINGLE WINDOW OPERATOR B
PLACE OF WORK	TALONDE
BIRTHDATE	09-12-1986
PROPOSED DATE OF HEALTH CHECKUP	24-11-2022
BOOKING REFERENCE NO.	22D168698100030326E

This letter of approval / recommendation is valid if submitted along with copy of the Bank of Baroda employee id card. This approval is valid from **15-11-2022** till **31-03-2023** The list of medical tests to be conducted is provided in the annexure to this letter. Please note that the said health checkup is a **cashless facility** as per our tie up arrangement. We request you to attend to the health checkup requirement of our employee and accord your top priority and best resources in this regard. The EC Number and the booking reference number as given in the above table shall be mentioned in the invoice, invariably.

We solicit your co-operation in this regard.

Yours faithfully,

Sd/-

Chief General Manager
HRM Department
Bank of Baroda

(Note: This is a computer generated letter. No Signature required. For any clarification, please contact Mediwheel (Arcofemi Healthcare Limited))



बैंक ऑफ़ बड़ौदा
Bank of Baroda



नाम
Name

Vishal S Deshmukh

कर्मचारी फ़ूर नं.
E.C.No.

168698



जारीकर्ता प्राधिकारी
Issuing Authority
Chief Manager (Security)
Pune Zone

Vishal S Deshmukh

धारक के हस्ताक्षर
Signature of Holder



NAME: MR. VISHAL DESHMUKH	DATE: 24/11/2022
AGE/ SEX: 36 YEARS/ MALE	REFERRED BY: DR MANOJ CHOPDA

XRAY CHEST PA (VIEW)

Clinical profile- Health check up.

Both the lungs are clear and do not show any obvious focal lesion.
Bilateral costo-phrenic and cardio-phrenic angles appear clear.

There is no evidence of pleural effusion or pneumothorax on either side.

Both the hilum appear normal.
Domes of diaphragm have normal contours and positions.

Visualised bones and soft tissues reveal no abnormality.

CONCLUSION:

- No significant abnormality is seen.

DR TRIPTI PAREEK
(DNB RADIODIAGNOSIS)



MAGNUM NASHIK HEALTHCARE LLP

MAGNUM

MULTISPECIALITY HOSPITAL

Patient's Name : Mr. Vishal Deshmukh

Date : 24/11/2022

Ref. By : Dr. Manoj Chopda (MD,DM)

Age/Sex : 36yrs/Male

BLOOD EXAMINATION REPORT

(By Fully Automated cell counter)

Haemoglobin : 15.2 gm % (12 – 18 gm %)

White Blood Cells

Total Count : 5900 / cmm (4000 – 11000 / cmm)

Differential Count

Neutrophils : 63 % (50 – 70 %)
Lymphocytes : 32 % (20 – 40 %)
Eosinophils : 02 % (01 – 04 %)
Monocytes : 03 % (02 – 08 %)
Basophils : 00 % (00 – 01 %)

Platelets : 1.87 Lacs/cmm (1.5 – 4.5 Lacs/cmm)

R.B.C. : 5.24 mil/cmm (3.50 – 5.50 mil/cmm)

Haematocrit (P.C.V.) : 46.1 % (37 - 51 %)

M.C.V. : 88.0 fL (80 – 97 fL)

M.C.H. : 29.1 pg (26 – 32 pg)

M.C.H.C. : 33.0 g/dl (31 – 36 g/dl)

R.D.W. : 13.1 % (11.5 – 16.0 %)

E.S.R : 10 mm/hrs 0 - 15 mm/hrs

Pathologist
Dr. Sudhir Sankalecha
MD (Path)
Reg. No. 70405



MAGNUM NASHIK HEALTHCARE LLP

MAGNUM

MULTISPECIALITY HOSPITAL

Patient's Name : Mr. Vishal Deshmukh

Date : 24/11/2022

Ref. By : Dr. Manoj Chopda (MD,DM)

Age/Sex : 36yrs/Male

BIOCHEMISTRY REPORT

<u>TEST</u>	<u>OBSERVED VALUE</u>	<u>NORMAL VALUE</u>
Blood Sugar (Fasting) :	95.4 mg/dl	60 – 110 mg/dl
Urine Sugar :	Absent	
Urine Ketones :	Absent	
Blood Sugar (PP) :	102.1 mg/dl	60 – 140 mg/dl
Urine Sugar :	SNR	
Urine Ketones :	SNR	

Pathologist
Dr. Sudha Sankalecha
MD (Path)
Reg. No. 70405

Patient's Name : Mr. Vishal Deshmukh

Date : 24/11/2022

Ref. By : Dr. Manoj Chopda (MD,DM)

Age/Sex : 36yrs/Male

HAEMATOLOGY

<u>Test</u>	<u>Result</u>	<u>Reference Range</u>
HBA1C :	6.2 %	4.0 – 6.0 %
METHOD :	HPLC METHOD	

Reference Range As per ADA

Normal : Below 5.7%

Pre-Diabetes : 5.7% - 6.4%

Diabetes : \geq 6.5%

Guidance For Known Diabetes

Good Control : Below 6.5%

Fair Control : 6.5% - 7.0%

Unsatisfactory Control : 7.0% - 8.0%

Poor Control : $>$ 8.0%

Pathologist
Dr. Sudhir Sankalecha
MD (Path)
Reg. No. 70405



MAGNUM NASHIK HEALTHCARE LLP

MAGNUM

MULTISPECIALITY HOSPITAL

Patient's Name : Mr. Vishal Deshmukh

Date : 24/11/2022

Ref. By : Dr. Manoj Chopda (MD,DM)

Age/Sex : 36yrs/Male

LIPID PROFILE REPORT

<u>TEST</u>	<u>OBSERVED VALUE</u>	<u>NORMAL VALUE</u>
S. Cholesterol :	193.8 mg/dl	Up to 200 mg/dl
S. Triglyceride :	209.6 mg/dl	Up to 160 mg/dl
HDL Cholesterol :	30.0 mg/dl	30 – 65 mg/dl
LDL Cholesterol :	121.9 mg/dl	75 – 165 mg/dl
VLDL Cholesterol :	41.9 mg/dl	6.0 – 38.0 mg/dl
LDL/HDL Ratio :	4.06	2.5 – 4
Chol/HDL Chol Ratio :	6.46	3 – 5.5

Pathologist
Dr. Sudhir Sankalecha
MD (Path)
Reg. No. 70405

Patient's Name : Mr. Vishal Deshmukh

Date : 24/11/2022

Ref. By : Dr. Manoj Chopda (MD,DM)

Age/Sex : 36yrs/Male

BIOCHEMISTRY REPORT

<u>TEST</u>	<u>OBSERVED VALUE</u>	<u>NORMAL RANGE</u>
Blood Urea	: 21.9 mg/dl	15 – 45 mg/dl
S.Creatinine	: 1.21 mg/dl	0.6 – 1.4 mg/dl
S.Uric acid	: 6.8 mg/dl	2.5 – 7.2 mg/dl
LFT		
S.Bilirubin		
Total	: 0.8 mg/dl	0.2 – 1.1 mg/dl
Direct	: 0.2 mg/dl	0.0 – 0.4 mg/dl
Indirect	: 0.6 mg/dl	0.2 – 0.6 mg/dl
S.G.O.T.	: 25.5 IU/L	8 – 40 IU/L
S.G.P.T.	: 26.1 IU/L	5 – 50 IU/L
S.Alk PO4	: 65.1 IU/L	70 – 306 IU/L
S.Proteins		
Total	: 7.1 g/dl	6 – 7.8 g/dl
Albumin	: 4.2 g/dl	3.2 – 4.6 g/dl
Globulin	: 2.9 g/dl	2.3 – 3.5 g/dl
A/G Ratio	: 1.44	

Pathologist
 Dr. Sudhir Sankalecha
 MD (Path)
 Reg.No - 70405



Patient's Name : Mr. Vishal Deshmukh

Date : 24/11/2022

Ref. By : Dr. Manoj Chopda (MD,DM)

Age/Sex : 36yrs/Male

THYROID FUNCTION TEST REPORT

<u>TEST</u>	<u>OBSERVED VALUE</u>	<u>NORMAL RANGE</u>
T3	: 0.90 ng/ml	0.69 – 2.15 ng/ml
T4	: 10.36 ug/dl	5.2 – 12.7 ug/dl
TSH Ultra-Sensitive	: 2.09 uIU/ml	0.4 – 4.5 uIU/ml

METHOD : By Chemiluminescence System

Pathologist
Dr. Sudhir Sankalecha
MD (Path)
Reg. No. 70405



Patient's Name : Mr. Vishal Deshmukh

Date : 24/11/2022

Ref. By : Dr. Manoj Chopda (MD,DM)

Age/Sex : 36yrs/Male

BLOOD EXAMINATION REPORT

Test

Result

Blood Group

: ' A '

Rh Factor

: Positive

Pathologist
Dr. Sudhir Sankalecha
MD (Path)
Reg. No. 70405



Patient's Name : Mr. Vishal Deshmukh

Date : 24/11/2022

Ref. By : Dr. Manoj Chopda (MD,DM)

Age/Sex : 36yrs/Male

URINE EXAMINATION REPORT

PHYSICAL CHARACTERISTICS

Volume : 30 ml

Appearance : Clear

Colour : Pale Yellow

Reaction : Acidic

CHEMICAL EXAMINATION

Albumin : Absent

Bile Salts : Absent

Sugar : Absent

Bile Pigments : Absent

Ketones : Absent

MICROSCOPIC EXAMINATION

Epithelial Cells : 1 - 2/hpf

R.B.C.s : Absent

Pus Cells : 0 - 2/hpf

Casts : Absent

Crystals : Absent

Bacilli : Absent

Other : Absent

Pathologist
Dr. Sudhir Sankalecha
MD (Path)
Reg. No. 70405

ULTRASOUND ABDOMEN & PELVIS

NAME: MR. VISHAL DESHMUKH	DATE: 24/11/2022
AGE/ SEX: 36 YEARS/ MALE	REFERRED BY: HEALTH CARE

Clinical profile- Health check up

Liver: Normal in size(13.8 cm), shape and shows normal echotexture. No evidence of any space occupying lesion seen. Intrahepatic biliary radicals are not dilated. Portal vein is normal in caliber.

Gallbladder: GB is partially distended. No evidence of any calculus **seen**. No wall thickening/pericholecystic fluid collection noted. CBD is normal in caliber.

Pancreas: Head & part of the body is visualized, appears normal in bulk & echotexture. Rest of the pancreas is obscured by bowel gases.

Spleen: Appears normal in size (11.3 cm), shape and echotexture. No calcification or mass is seen. Splenic vein is not dilated.

Kidneys: Right kidney – 10.6 x 4.2 cm. Left kidney - 10.8 x 5 cm.

Both kidneys are normal in shape, positions and echotexture. Bilateral corticomedullary differentiation appears normal. No hydronephrosis seen. No evidence of any calculus or mass lesion seen.

Urinary Bladder: is well distended. No evidence of calculus/ wall thickening noted.

Prostate is normal in size and echotexture.


Lymphadenopathy: No significant lymphadenopathy noted.

Free fluid: No evidence of any free fluid in peritoneal cavity.

IMPRESSION:

No other significant abnormality seen

Clinical correlation is suggested.


DR TRIPTI PAREEK
(DNB RADIODIAGNOSIS)

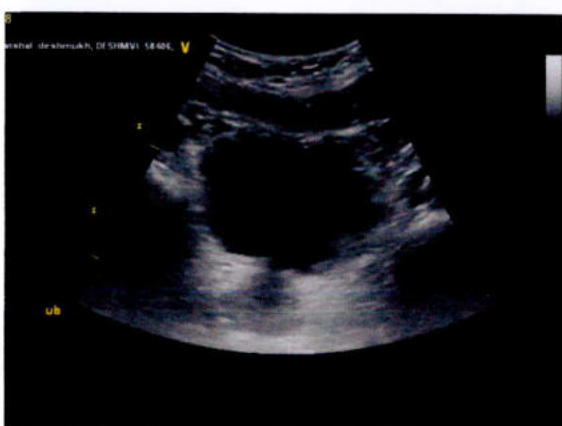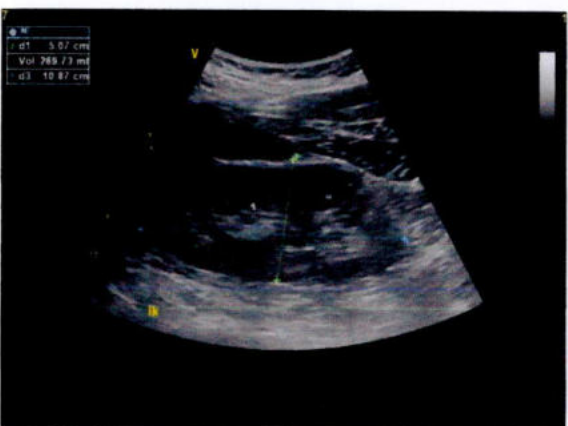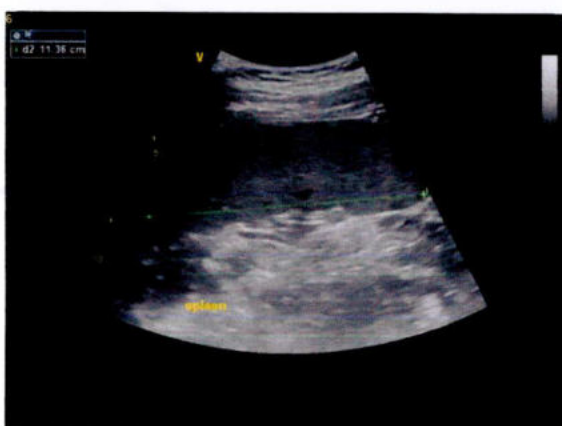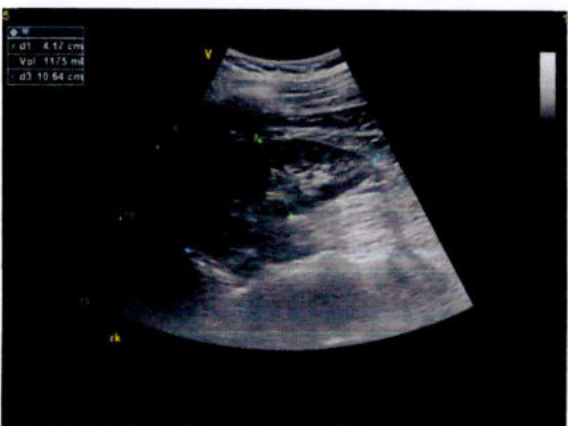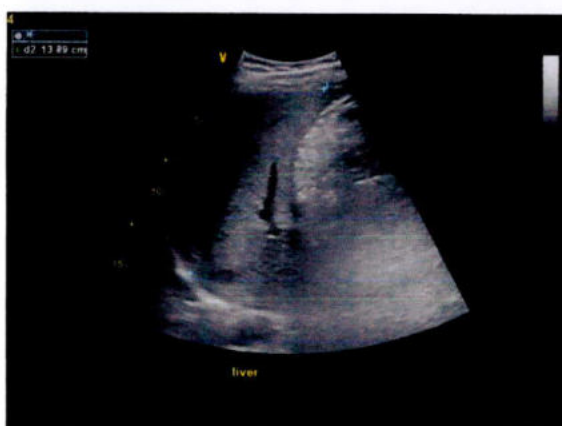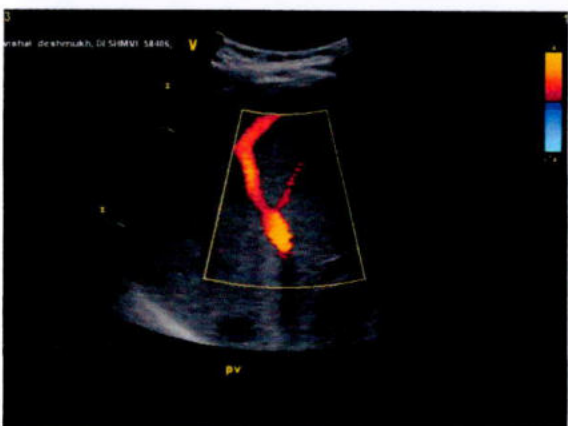
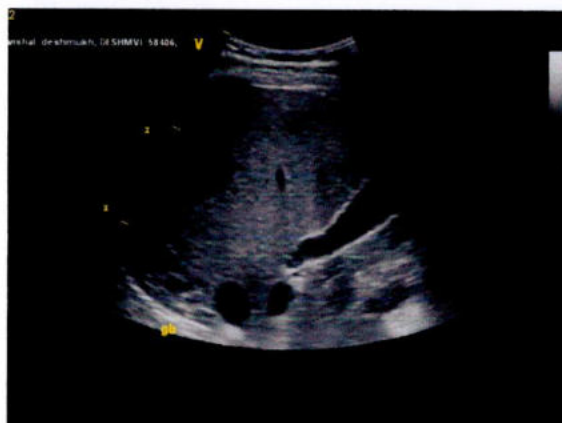
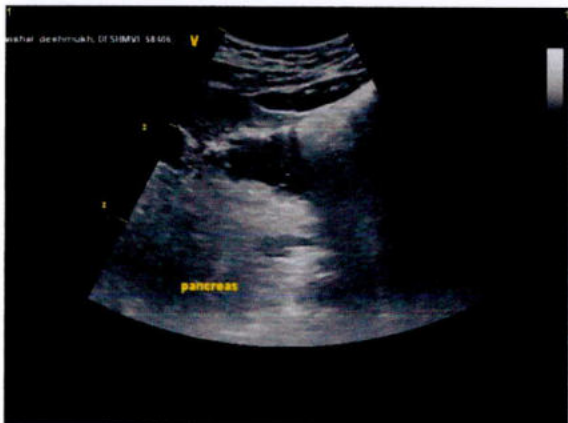MAGNUM MULTISPECIALITY HOSPITAL NASIK ROAD, NASHIK

Name **deshmukh, vishal**

Sex

Age

Date **24/11/2022**





Chopda Medicare & Research Centre Pvt. Ltd's

MAGNUM

HEART INSTITUTE

ISO 9001 : 2008 CERTIFIED HOSPITAL

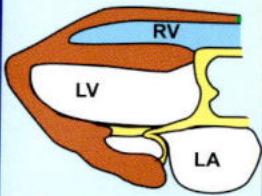
ECHOCARDIOGRAPHY AND COLOUR DOPPLER IMAGING

PATIENT NAME :- VISHAL DESHMUKH
DATE:- 24.11.2022

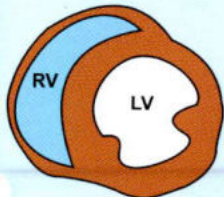
AGE/SEX:-35/M

REGIONAL ANALYSIS OF THE HEART

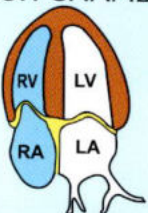
PARASTERNAL LONG AXIS



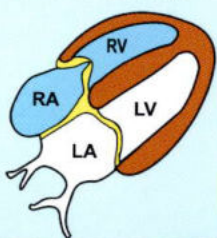
PARASTERNAL SHORT AXIS



APICAL FOUR CHAMBER



SUBCOSTAL



OBSERVATION

NORMAL SIZE LV WITH GOOD LV FUNCTION EF= 60%

LEFT VENTRICLE - NORMAL SIZED
NO REGIONAL WALL MOTION ABNORMALITY
NO S/O LV HYPERTROPHY IVS = 10mm, PW = 10mm PRESENT
NO S/O DIASTOLIC DYSFUNCTION.
OVERALL GOOD LV FUNCTION..

LEFT ATRIUM -(30MM) NORMAL SIZED

AORTA=(20MM)

RIGHT ATRIUM /VENTRICLE - NORMAL SIZED
OVERALL GOOD RV FUNCTION.

ALL VALVES - NORMAL

NO S/O PULMONARY HYPERTENSION PRESENT
PULMONARY ARTERY SYSTOLIC PRESSURE = mm Hg

NO S/O PERICARDIAL EFFUSION NOTED
IVC NORMAL.



Dr. MANOJ B. CHOPDA
M.D. (Medicine) D.M. (Cardiology)
INTERVENTIONAL CARDIOLOGIST

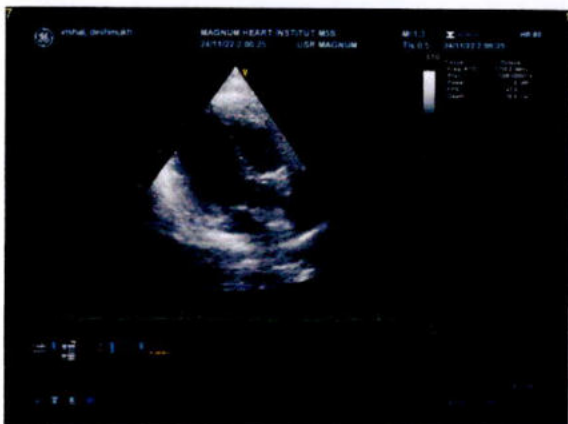
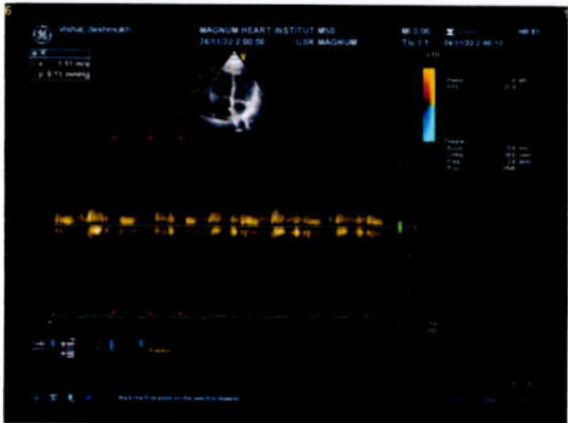
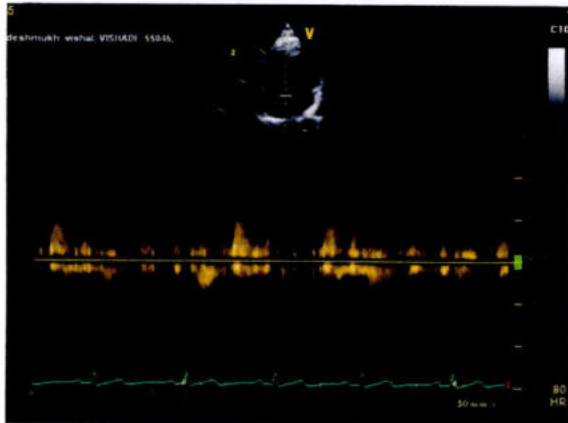
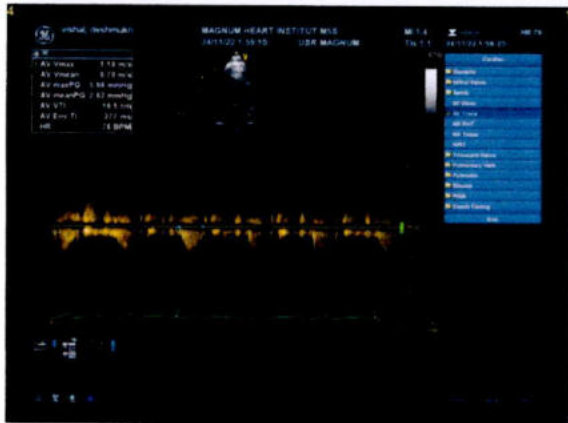
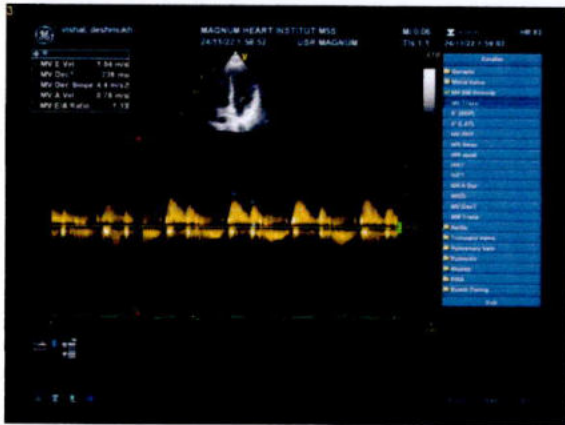
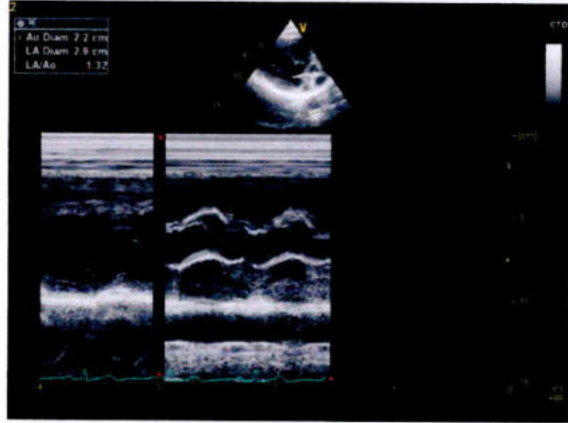
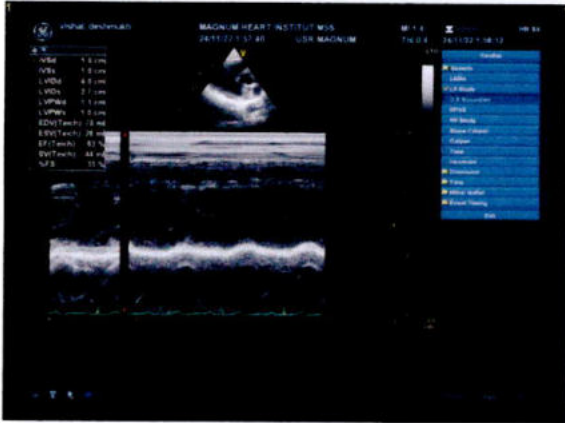MAGNUM MULTISPECIALITY HOSPITAL NASIK ROAD, NASHIK

Name vishal, deshमुख

Sex

Age

Date 24/11/2022

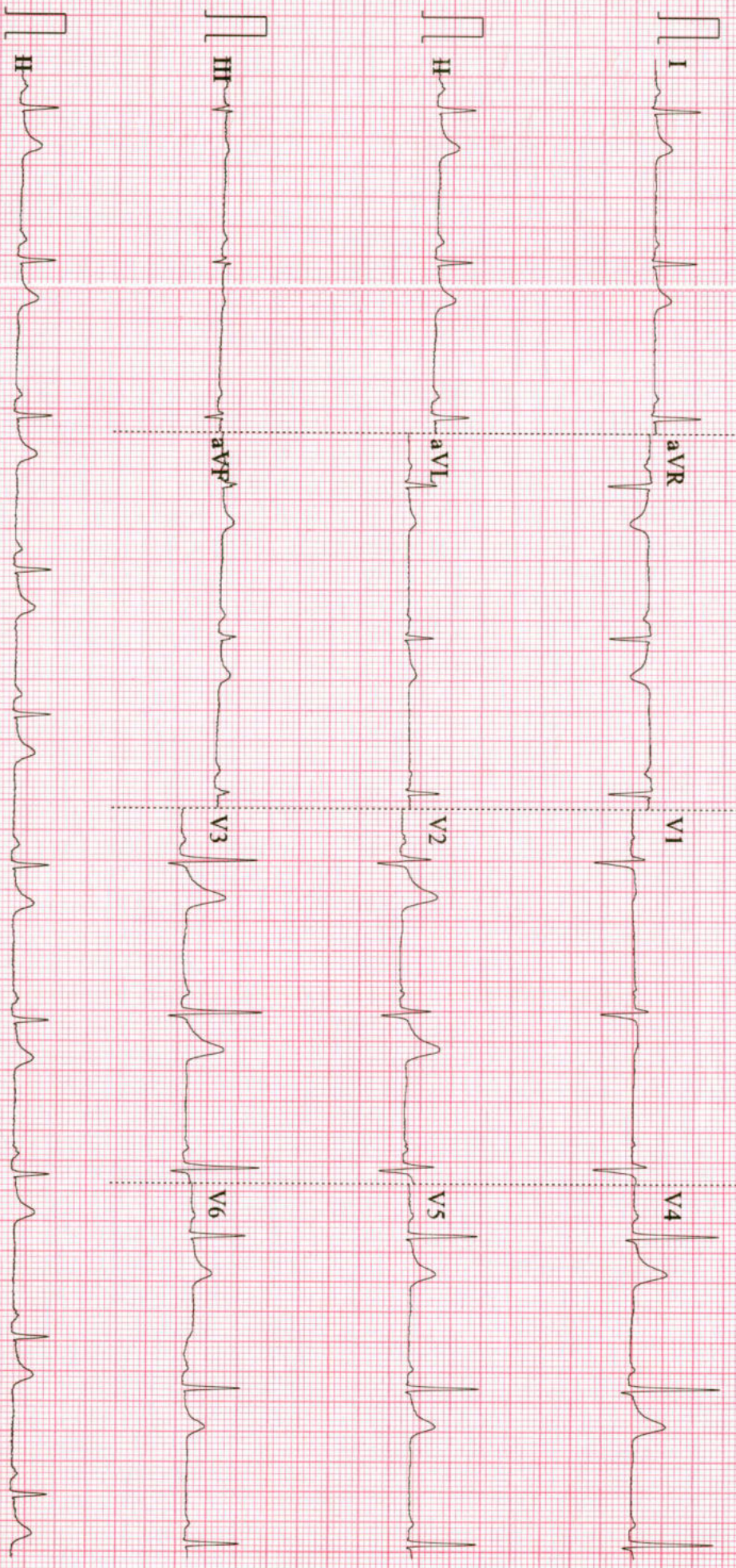


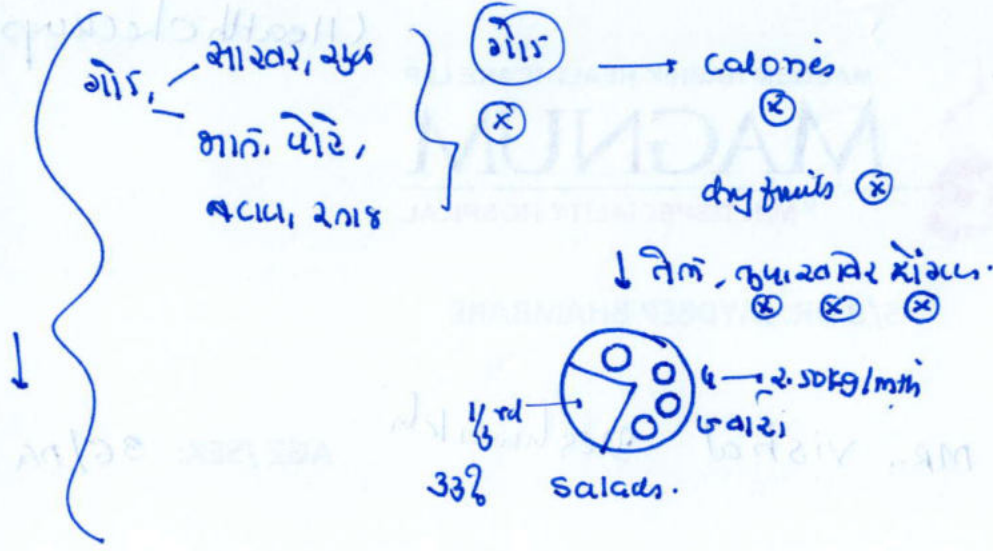
ID: 1
VISHAL DESHMUKH
Male 35Years
Department: ER

24-11-2022 09:37:46 AM
HR : 58 bpm
P : 100 ms
PR : 150 ms
QRS : 78 ms
QT/QTc : 388/381 ms
P/QRS/T : 51/27/39 °
RV5/SV1 : 1.134/0.586 mV

Diagnosis Information:
Sinus bradycardia
Normal ECG except for rate

Report Confirmed by:





5-7km walk 10km

दिल्ली

महाराष्ट्र

गुजरात

कर्नाटक

आंध्र प्रदेश

99

97

95

20

21

22

Cholesterol - 200

Triglycerides - 150

LDL - 100

HDL - 50