



# ABI SCANS & LABS

A unit of Aarthi Scans and Labs

Patient Name	MR.VENKATRAMANAN N	Age	36 Y
Patient ID	101020	Sex	Male
Referral Dr	MEDIWHEEL	Study Date	10 Jun 2022

## X-RAY - CHEST PA VIEW

### OBSERVATION:

The trachea is central.  
The mediastinal and cardiac silhouette are normal.  
Cardiothoracic ratio is normal.  
Cardiophrenic and costophrenic angles are normal.  
Both hila are normal.  
Lung zones are clear.  
Bones of the thoracic cage are normal.  
Soft tissues of the chest wall are normal.

### IMPRESSION:

No significant abnormality seen.

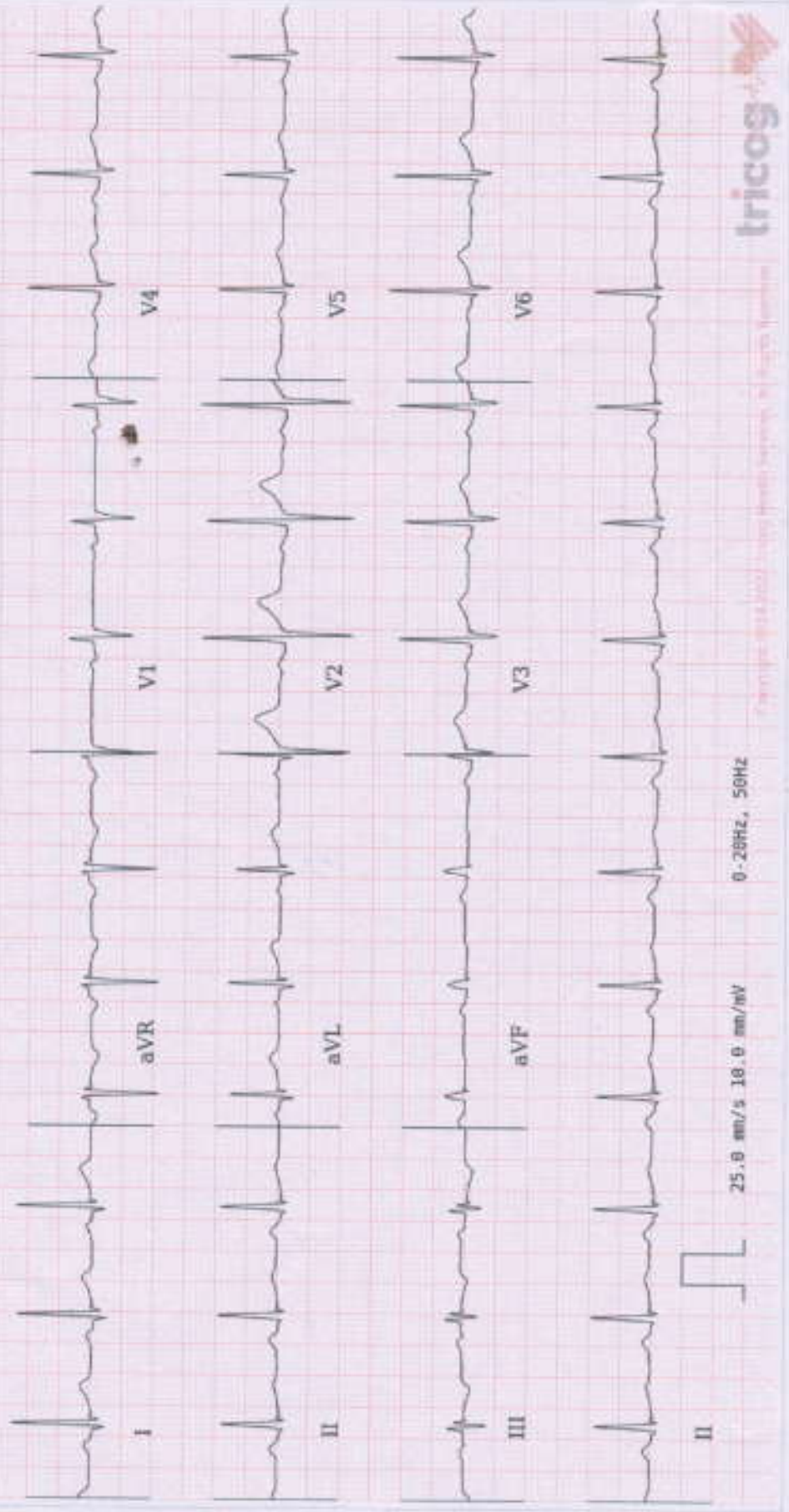
Dr. Abinaya., MD., (RD)  
Consultant Radiologist



# Aarthi CT and MRI Scans, R S Puram West

Age / Gender: 36/Male  
Date and Time: 10th Jun 22 10:58 AM  
Patient ID: 0000096635  
Patient Name: MR. VENKATRAMANAN N

Bp 120/80mmHg



Within Normal Limits: Sinus Rhythm, Normal Axis. Please correlate clinically.



# ABI SCANS & LABS

A unit of Aarthi Scans and Labs

NAME	MR. VENKATRAMANAN N	PATIENT ID	96635
ACCESSION NO	101020	AGE/GENDER	36Y/MALE
REFERRED BY	MEDIWHEEL	DATE	10.06.2022

## ECHOCARDIOGRAPHIC EVALUATION

MEASUREMENTS: ACOUSTIC WINDOW: OPTIMAL

### 2D/ M MODE PARAMETERS:

Parameters	Patient Values	Normal Adult Value
LA	3.63	(2.0 - 4.0 cm)
AO	3.02	(2.0 - 4.0 cm)
LVIDD	4.52	(3.5 - 5.5 cm)
LVIDS	2.85	(2.5 - 4.3 cm)
IVSd	1.08	(0.6 - 1.2 cm)
LVPWd	0.98	(0.6 - 1.2 cm)
EF	66	(50% - 70%)

### IMPRESSION:

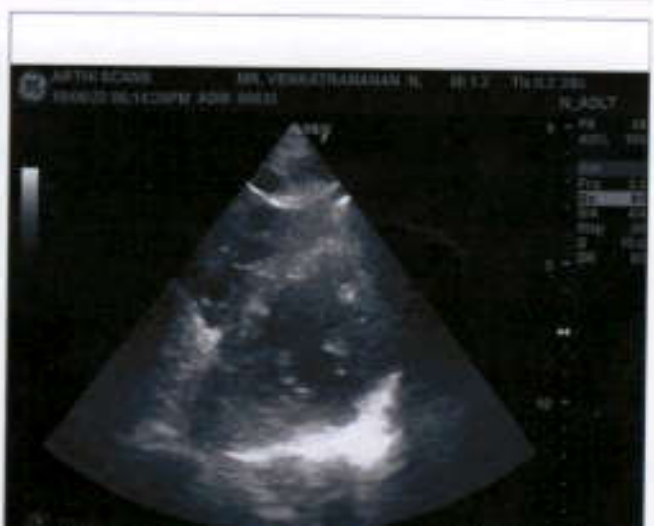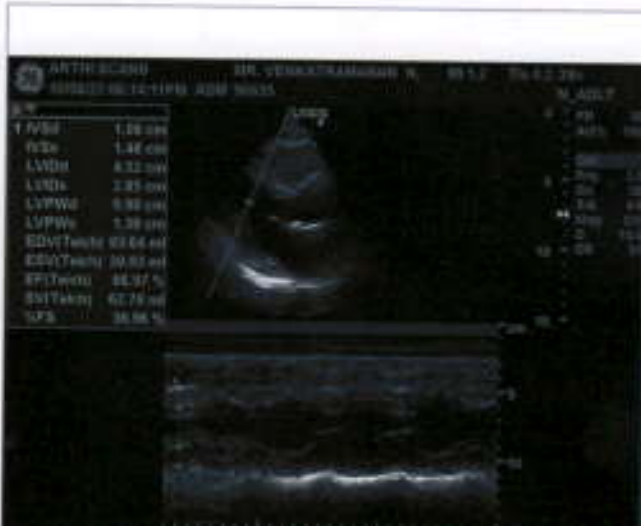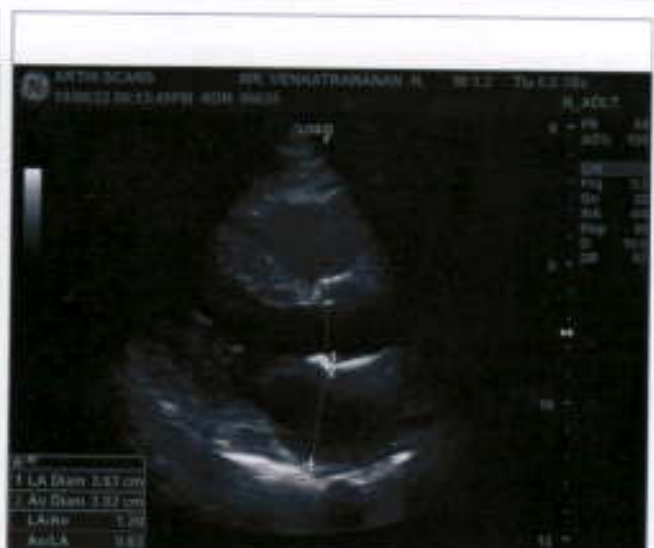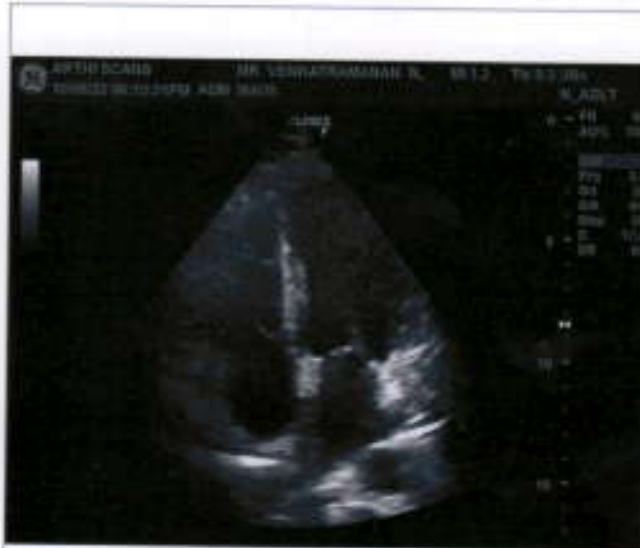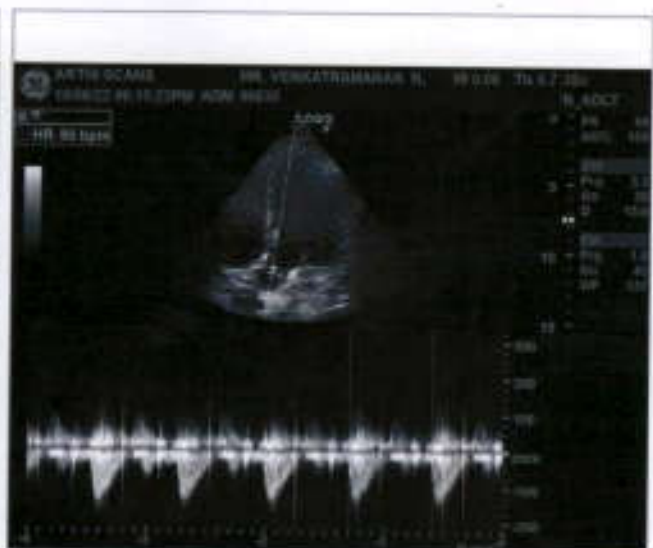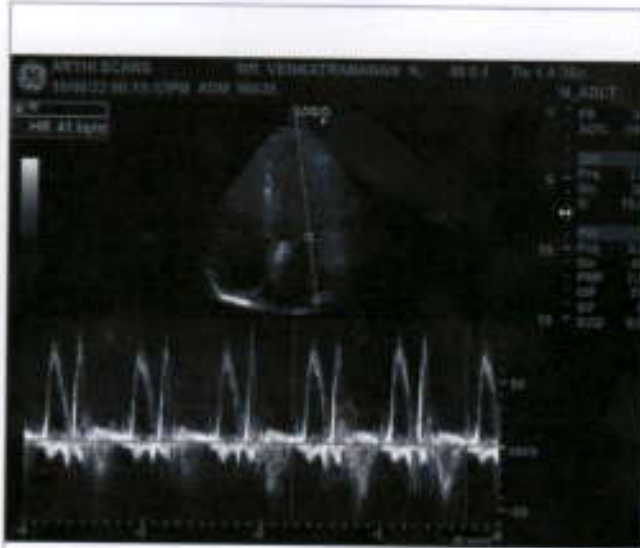- 🚫 No regional wall motion abnormality at rest.
- 🚫 Normal valves and chambers.
- 🚫 No pulmonary hypertension.
- 🚫 No pericardial effusion.
- 🚫 Normal LV systolic function.

Dr. KARTHIK C.S.MD.,PGD(CARDIOLOGY,UKR)  
CONSULTANT CARDIOLOGIST.



# ABI SCANS & LABS

MR. VENKATRAMANAN N 36Y/M 96635 10-Jun-2022 05:25:03 PM Physician Name





# ABI SCANS & LABS

A unit of Aarthi Scans and Labs

NAME	MR. VENKATRAMANAN N	PATIENT ID	96635
ACCESSION NO	101020	AGE/GENDER	36Y/MALE
REFERRED BY	MEDIWHEEL	DATE	10-JUNE-2022

## VISION TEST

### VISUAL ACUITY (VA)

If The Acuity Can Be Measures, Complete This Box Using Snellen acuities or snellen equivalents or NLP,LP,HM, or distance at which the patient sees the 20/100 letter.

### WITH BEST CORRECTION

DISTANCE VISION	
Right	11/11
Left	11/11
Both	11/11

NEAR VISION	
Right	N6
Left	N6
Both	N6

COLOUR VISION	
BOTH	Normal



# ABI SCANS & LABS

*A unit of Aarthi Scans and Labs*

Name	MR .VENKATRAMANAN N	Patient ID	96635
Accession No	101020	Age/Gender	36 Y / Male
Referred By	MEDIWHEEL	Date	10-Jun-2022

## USG REPORT - ABDOMEN AND PELVIS

### LIVER:

Liver is normal in size ( measures ~13.5 cm) and shows increased echotexture.

No focal liver lesion. No intra hepatic biliary radical dilatation seen.

### GALL BLADDER:

Is adequately distended. No calculus or cholecystitis seen.

### PANCREAS:

Appears normal in size and shows uniform echo texture. The pancreatic duct is normal. No calcifications are seen.

### SPLEEN:

Appears normal in size and it shows uniform echo texture. It measures ~ 10.4 cm in long axis.

### RIGHT KIDNEY:

Right kidney measures ~11.6 x 4.4 cm.

The shape, size and contour of the right kidney appear normal.

Cortico medullary differentiation is within normal. No evidence of pelvicalyceal dilatation.

No calculi seen.

### LEFT KIDNEY:

Left kidney measures ~10.3 x 5.4 cm.

**Few calculi (2 to 3 in no) seen, largest measuring ~ 3mm in lower pole of left kidney.**

The shape, size and contour of the left kidney appear normal.

Cortico medullary differentiation is within normal. No evidence of pelvicalyceal dilatation.

No calculi seen.





# ABI SCANS & LABS

A unit of Aarthi Scans and Labs

Name	MR .VENKATRAMANAN N	Patient ID	96635
Accession No	101020	Age/Gender	36 Y / Male
Referred By	MEDIWHEEL	Date	10-Jun-2022

## USG REPORT - ABDOMEN AND PELVIS

### URINARY BLADDER:

Is normal contour. No intra luminal echoes are seen.

### PROSTATE:

Prostate appears normal, Measures ~ 3.3 x 2.9 x 3.6cms (Vol - 15cc).


### RIGHT ILIAC FOSSA:

No focal fluid collections seen.

No evidence of hernia seen in anterior abdominal wall.

### IMPRESSION:

- ❖ Grade I fatty liver.
- ❖ Non obstructive small left intra renal calculi.
- Suggested clinical correlation.

  
Dr. Lokesh Babu, MDRD.,  
Radiologist

Thank you for the courtesy of this referral

Foot Note: Patient's identity is not verified. Report is not valid for medico legal purpose

Dr. Lokesh Babu, MD.,RD.,  
Reg. No: 113030

# ABI SCANS AND LABS

MR. VENKATRAMANAN N /M 96635 10-Jun-2022 09:40:49 AM

