

Patient Name: AMARPAL SINGH  
Patient ID: 2223924854

Date and Time: 27th Aug 22 12:01 PM

Age **53** **7** **16**  
years months days

Gender **Male**

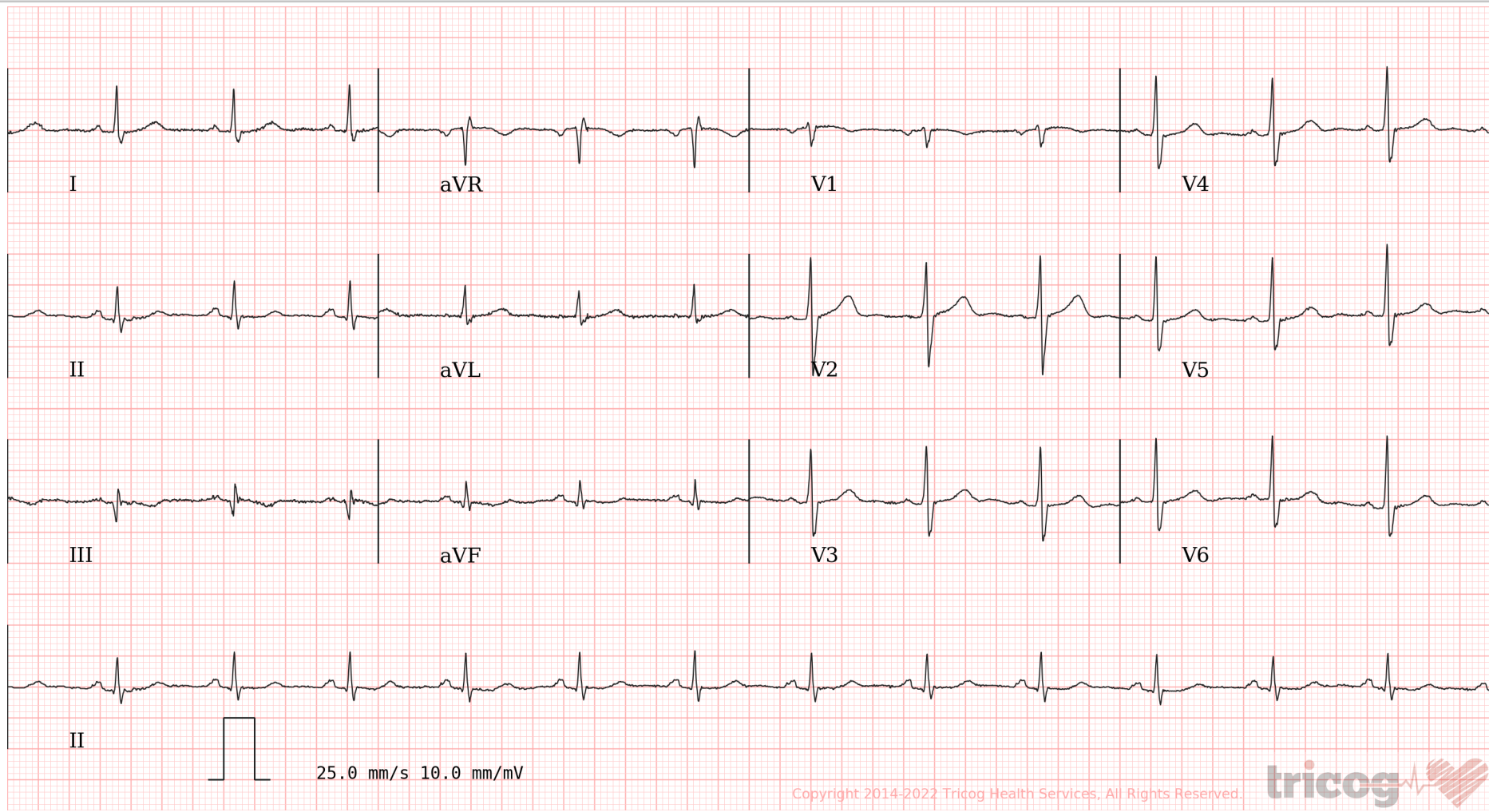
Heart Rate **80bpm**

**Patient Vitals**


BP: NA  
Weight: NA  
Height: NA  
Pulse: NA  
Spo2: NA  
Resp: NA  
Others: \_\_\_\_\_

**Measurements**

QRSD: 90ms  
QT: 380ms  
QTc: 438ms  
PR: 142ms  
P-R-T: 54° 21° 16°



Copyright 2014-2022 Tricog Health Services, All Rights Reserved.



ECG Within Normal Limits: Sinus Rhythm, Normal Axis. Please correlate clinically.

REPORTED BY

DR SHAILAJA PILLAI  
MBBS, MD Physician  
MD Physician  
49972



**CID** : 2223924854  
**Name** : Mr AMARPAL SINGH  
**Age / Sex** : 53 Years/Male  
**Ref. Dr** :  
**Reg. Location** : G B Road, Thane West Main Centre  
**Reg. Date** : 27-Aug-2022  
**Reported** : 27-Aug-2022/15:34

### USG WHOLE ABDOMEN

**LIVER:** *Liver appears enlarged in size(18.9 cm) and shows increased echoreflectivity.* There is no intra-hepatic biliary radical dilatation. No evidence of any focal lesion.

**GALL BLADDER:** *Gall bladder is distended and shows a solitary intra-luminal mobile calculus measuring 8.5 mm.* Wall thickness is within normal limits. No polyps/sludge/peri-cholecystic collection seen.

**PORTAL VEIN:** Portal vein is normal(12.5 mm). **CBD:** CBD is normal(2.2 mm).

**PANCREAS:** Pancreas appears normal in echotexture. There is no evidence of any focal lesion or calcification. Pancreatic duct is not dilated.

**KIDNEYS:** Right kidney measures 9.6 x 4.1 cm. Left kidney measures 10.5 x 4.1 cm. Both kidneys are normal in shape and echotexture. Corticomedullary differentiation is maintained. There is no evidence of any hydronephrosis, hydroureter or calculus.

**SPLEEN:** Spleen is normal in size, shape and echotexture. No focal lesion is seen.

**URINARY BLADDER:** Urinary bladder is distended and normal. Wall thickness is within normal limits.

**PROSTATE:** Prostate is normal in size and echotexture and measures 3.1 x 3.2 x 3.7 cm in dimension and 20.0 cc in volume. No evidence of any focal lesion. Median lobe does not show significant hypertrophy.

No free fluid or significant lymphadenopathy is seen.



Use a QR Code Scanner  
Application To Scan the Code

**CID** : 2223924854  
**Name** : Mr AMARPAL SINGH  
**Age / Sex** : 53 Years/Male  
**Ref. Dr** :  
**Reg. Location** : G B Road, Thane West Main Centre

**Reg. Date** : 27-Aug-2022  
**Reported** : 27-Aug-2022/15:34

**IMPRESSION:**

- **HEPATOMEGALY WITH GRADE I FATTY INFILTRATION OF LIVER.**
- **CHOLELITHIASIS WITHOUT CHOLECYSTITIS.**

Note: Investigations have their limitations. Solitary radiological investigations never confirm the final diagnosis. They only help in diagnosing the disease in correlation to clinical symptoms and other related tests. USG is known to have inter-observer variations. Further/follow-up imaging may be needed in some cases for confirmation / exclusion of diagnosis.

**Advice: Clinical co-relation and further evaluation.**

-----End of Report-----

**This report is prepared and physically checked by Dr. Devendra Patil before dispatch.**

*D Patil*

Dr. Devendra Patil  
MBBS, MD (Radio-Diagnosis)  
Consultant Radiologist  
MMC - 2013/02/0165



Use a QR Code Scanner  
Application To Scan the Code

**CID** : 2223924854  
**Name** : Mr AMARPAL SINGH  
**Age / Sex** : 53 Years/Male  
**Ref. Dr** :  
**Reg. Location** : G B Road, Thane West Main Centre

**Reg. Date** : 27-Aug-2022  
**Reported** : 27-Aug-2022/15:34



**CID** : 2223924854  
**Name** : Mr AMARPAL SINGH  
**Age / Sex** : 53 Years/Male  
**Ref. Dr** :  
**Reg. Location** : G B Road, Thane West Main Centre

**Reg. Date** : 27-Aug-2022  
**Reported** : 27-Aug-2022/12:34

**X-RAY CHEST PA VIEW**

Both lung fields are clear.

Both costo-phrenic angles are clear.

The cardiac size and shape are within normal limits.

The domes of diaphragm are normal in position and outlines.

The skeleton under review appears normal.

**IMPRESSION:**

**NO SIGNIFICANT ABNORMALITY IS DETECTED.**

-----End of Report-----

**This report is prepared and physically checked by Dr. Devendra Patil before dispatch.**

Dr. Devendra Patil  
MBBS, MD (Radio-Diagnosis)  
Consultant Radiologist  
MMC - 2013/02/0165



Use a QR Code Scanner  
Application To Scan the Code

**CID** : 2223924854  
**Name** : Mr AMARPAL SINGH  
**Age / Sex** : 53 Years/Male  
**Ref. Dr** :  
**Reg. Location** : G B Road, Thane West Main Centre

**Reg. Date** : 27-Aug-2022  
**Reported** : 27-Aug-2022/12:34



CID : 2223924854  
Name : MR.AMARPAL SINGH  
Age / Gender : 53 Years / Male  
Consulting Dr. : -  
Reg. Location : G B Road, Thane West (Main Centre)

Collected : 27-Aug-2022 / 09:14  
Reported : 27-Aug-2022 / 14:06

Use a QR Code Scanner  
Application To Scan the Code

**MEDIWHEEL FULL BODY HEALTH CHECKUP MALE ABOVE 40/2D ECHO**

**CBC (Complete Blood Count), Blood**

<u>PARAMETER</u>	<u>RESULTS</u>	<u>BIOLOGICAL REF RANGE</u>	<u>METHOD</u>
<b><u>RBC PARAMETERS</u></b>			
Haemoglobin	13.3	13.0-17.0 g/dL	Spectrophotometric
RBC	<b>3.97</b>	4.5-5.5 mil/cmm	Elect. Impedance
PCV	40.6	40-50 %	Measured
MCV	<b>102</b>	80-100 fl	Calculated
MCH	<b>33.5</b>	27-32 pg	Calculated
MCHC	32.8	31.5-34.5 g/dL	Calculated
RDW	<b>14.6</b>	11.6-14.0 %	Calculated
<b><u>WBC PARAMETERS</u></b>			
WBC Total Count	4600	4000-10000 /cmm	Elect. Impedance
<b><u>WBC DIFFERENTIAL AND ABSOLUTE COUNTS</u></b>			
Lymphocytes	<b>49.2</b>	20-40 %	
Absolute Lymphocytes	2263.2	1000-3000 /cmm	Calculated
Monocytes	4.4	2-10 %	
Absolute Monocytes	202.4	200-1000 /cmm	Calculated
Neutrophils	41.3	40-80 %	
Absolute Neutrophils	<b>1899.8</b>	2000-7000 /cmm	Calculated
Eosinophils	5.1	1-6 %	
Absolute Eosinophils	234.6	20-500 /cmm	Calculated
Basophils	<b>0.0</b>	0.1-2 %	
Absolute Basophils	<b>0.0</b>	20-100 /cmm	Calculated
Immature Leukocytes	-		

WBC Differential Count by Absorbance & Impedance method/Microscopy.





CID : 2223924854  
Name : MR.AMARPAL SINGH  
Age / Gender : 53 Years / Male  
Consulting Dr. : -  
Reg. Location : G B Road, Thane West (Main Centre)

Collected : 27-Aug-2022 / 09:14  
Reported : 27-Aug-2022 / 12:12

Use a QR Code Scanner  
Application To Scan the Code

**PLATELET PARAMETERS**

Platelet Count	151000	150000-400000 /cmm	Elect. Impedance
MPV	8.4	6-11 fl	Calculated
PDW	16.3	11-18 %	Calculated

**RBC MORPHOLOGY**

Hypochromia	-
Microcytosis	-
Macrocytosis	Mild
Anisocytosis	-
Poikilocytosis	-
Polychromasia	-
Target Cells	-
Basophilic Stippling	-
Normoblasts	-
Others	-

WBC MORPHOLOGY -

PLATELET MORPHOLOGY -

COMMENT Serum Vitamin B12 & Folic acid estimation, Reticulocyte count estimation recommended.

Specimen: EDTA Whole Blood

ESR, EDTA WB 41 2-20 mm at 1 hr. Westergren

\*Sample processed at SUBURBAN DIAGNOSTICS (INDIA) PVT. LTD G B Road Lab, Thane West



*Amit Taori*

**Dr.AMIT TAORI**  
M.D ( Path )  
Pathologist





Use a QR Code Scanner  
Application To Scan the Code

CID : 2223924854  
Name : MR.AMARPAL SINGH  
Age / Gender : 53 Years / Male  
Consulting Dr. : -  
Reg. Location : G B Road, Thane West (Main Centre)

Collected :  
Reported :

\*\*\* End Of Report \*\*\*



CID : 2223924854  
 Name : MR.AMARPAL SINGH  
 Age / Gender : 53 Years / Male  
 Consulting Dr. : -  
 Reg. Location : G B Road, Thane West (Main Centre)

Collected : 27-Aug-2022 / 12:22  
 Reported : 27-Aug-2022 / 15:00

Use a QR Code Scanner  
 Application To Scan the Code

**MEDIWHEEL FULL BODY HEALTH CHECKUP MALE ABOVE 40/2D ECHO**

<u>PARAMETER</u>	<u>RESULTS</u>	<u>BIOLOGICAL REF RANGE</u>	<u>METHOD</u>
GLUCOSE (SUGAR) FASTING, Fluoride Plasma	129.5	Non-Diabetic: < 100 mg/dl Impaired Fasting Glucose: 100-125 mg/dl Diabetic: >/= 126 mg/dl	Hexokinase
GLUCOSE (SUGAR) PP, Fluoride Plasma PP/R	122.0	Non-Diabetic: < 140 mg/dl Impaired Glucose Tolerance: 140-199 mg/dl Diabetic: >/= 200 mg/dl	Hexokinase
Urine Sugar (Fasting)	Absent	Absent	
Urine Ketones (Fasting)	Absent	Absent	
Urine Sugar (PP)	Absent	Absent	
Urine Ketones (PP)	Absent	Absent	

\*Sample processed at SUBURBAN DIAGNOSTICS (INDIA) PVT. LTD G B Road Lab, Thane West  
 \*\*\* End Of Report \*\*\*



*Amit Taori*

**Dr.AMIT TAORI**  
**M.D ( Path )**  
**Pathologist**



CID : 2223924854  
Name : MR.AMARPAL SINGH  
Age / Gender : 53 Years / Male  
Consulting Dr. : -  
Reg. Location : G B Road, Thane West (Main Centre)

Collected : 27-Aug-2022 / 09:14  
Reported : 27-Aug-2022 / 12:59

Use a QR Code Scanner  
Application To Scan the Code

**MEDIWHEEL FULL BODY HEALTH CHECKUP MALE ABOVE 40/2D ECHO**  
**KIDNEY FUNCTION TESTS**

<u>PARAMETER</u>	<u>RESULTS</u>	<u>BIOLOGICAL REF RANGE</u>	<u>METHOD</u>
BLOOD UREA, Serum	16.6	12.8-42.8 mg/dl	Urease & GLDH
BUN, Serum	7.8	6-20 mg/dl	Calculated
CREATININE, Serum	0.98	0.67-1.17 mg/dl	Enzymatic
eGFR, Serum	85	>60 ml/min/1.73sqm	Calculated
TOTAL PROTEINS, Serum	8.0	6.4-8.3 g/dL	Biuret
ALBUMIN, Serum	4.4	3.5-5.2 g/dL	BCG
GLOBULIN, Serum	3.6	2.3-3.5 g/dL	Calculated
A/G RATIO, Serum	1.2	1 - 2	Calculated
URIC ACID, Serum	7.2	3.5-7.2 mg/dl	Uricase
PHOSPHORUS, Serum	3.8	2.7-4.5 mg/dl	Ammonium molybdate
CALCIUM, Serum	8.9	8.6-10.0 mg/dl	N-BAPTA
SODIUM, Serum	137	135-148 mmol/l	ISE
POTASSIUM, Serum	4.7	3.5-5.3 mmol/l	ISE
CHLORIDE, Serum	99	98-107 mmol/l	ISE

\*Sample processed at SUBURBAN DIAGNOSTICS (INDIA) PVT. LTD G B Road Lab, Thane West  
\*\*\* End Of Report \*\*\*



*Amit Taori*

**Dr.AMIT TAORI**  
**M.D ( Path )**  
**Pathologist**



CID : 2223924854  
 Name : MR.AMARPAL SINGH  
 Age / Gender : 53 Years / Male  
 Consulting Dr. : -  
 Reg. Location : G B Road, Thane West (Main Centre)

Collected : 27-Aug-2022 / 09:14  
 Reported : 27-Aug-2022 / 13:28

Use a QR Code Scanner  
 Application To Scan the Code

**MEDIWHEEL FULL BODY HEALTH CHECKUP MALE ABOVE 40/2D ECHO**  
**GLYCOSYLATED HEMOGLOBIN (HbA1c)**

<u>PARAMETER</u>	<u>RESULTS</u>	<u>BIOLOGICAL REF RANGE</u>	<u>METHOD</u>
Glycosylated Hemoglobin (HbA1c), EDTA WB - CC	6.3	Non-Diabetic Level: < 5.7 % Prediabetic Level: 5.7-6.4 % Diabetic Level: >= 6.5 %	HPLC
Estimated Average Glucose (eAG), EDTA WB - CC	134.1	mg/dl	Calculated



Use a QR Code Scanner  
Application To Scan the Code

**CID** : 2223924854  
**Name** : MR.AMARPAL SINGH  
**Age / Gender** : 53 Years / Male  
**Consulting Dr.** : -  
**Reg. Location** : G B Road, Thane West (Main Centre)

**Collected** : 27-Aug-2022 / 09:14  
**Reported** : 27-Aug-2022 / 13:28

**Intended use:**

- In patients who are meeting treatment goals, HbA1c test should be performed at least 2 times a year
- In patients whose therapy has changed or who are not meeting glycemic goals, it should be performed quarterly
- For microvascular disease prevention, the HbA1C goal for non pregnant adults in general is Less than 7%.

**Clinical Significance:**

- HbA1c, Glycosylated hemoglobin or glycated hemoglobin, is hemoglobin with glucose molecule attached to it.
- The HbA1c test evaluates the average amount of glucose in the blood over the last 2 to 3 months by measuring the percentage of glycosylated hemoglobin in the blood.

**Test Interpretation:**

- The HbA1c test evaluates the average amount of glucose in the blood over the last 2 to 3 months by measuring the percentage of Glycosylated hemoglobin in the blood.
- HbA1c test may be used to screen for and diagnose diabetes or risk of developing diabetes.
- To monitor compliance and long term blood glucose level control in patients with diabetes.
- Index of diabetic control, predicting development and progression of diabetic micro vascular complications.

**Factors affecting HbA1c results:**

**Increased in:** High fetal hemoglobin, Chronic renal failure, Iron deficiency anemia, Splenectomy, Increased serum triglycerides, Alcohol ingestion, Lead/opiate poisoning and Salicylate treatment.

**Decreased in:** Shortened RBC lifespan (Hemolytic anemia, blood loss), following transfusions, pregnancy, ingestion of large amount of Vitamin E or Vitamin C and Hemoglobinopathies

**Reflex tests:** Blood glucose levels, CGM (Continuous Glucose monitoring)

**References:** ADA recommendations, AACC, Wallach's interpretation of diagnostic tests 10th edition.

\*Sample processed at SUBURBAN DIAGNOSTICS (INDIA) PVT. LTD SDRL, Vidyavihar Lab

\*\*\* End Of Report \*\*\*



**Dr. ANUPA DIXIT**  
**M.D.(PATH)**  
**Consultant Pathologist & Lab**  
**Director**





CID : 2223924854  
 Name : MR.AMARPAL SINGH  
 Age / Gender : 53 Years / Male  
 Consulting Dr. : -  
 Reg. Location : G B Road, Thane West (Main Centre)

Use a QR Code Scanner  
 Application To Scan the Code  
 Collected : 27-Aug-2022 / 09:14  
 Reported : 27-Aug-2022 / 17:09

**MEDIWHEEL FULL BODY HEALTH CHECKUP MALE ABOVE 40/2D ECHO**  
**PROSTATE SPECIFIC ANTIGEN (PSA)**

<u>PARAMETER</u>	<u>RESULTS</u>	<u>BIOLOGICAL REF RANGE</u>	<u>METHOD</u>
TOTAL PSA, Serum	0.341	0.03-3.5 ng/ml	ECLIA



Use a QR Code Scanner Application To Scan the Code

**CID** : 2223924854  
**Name** : MR.AMARPAL SINGH  
**Age / Gender** : 53 Years / Male  
**Consulting Dr.** : -  
**Reg. Location** : G B Road, Thane West (Main Centre)

**Collected** : 27-Aug-2022 / 09:14  
**Reported** : 27-Aug-2022 / 17:09

**Clinical Significance:**

- PSA is detected in the serum of males with normal, benign hyper-plastic, and malignant prostate tissue.
- Monitoring patients with a history of prostate cancer as an early indicator of recurrence and response to treatment.
- Prostate cancer screening 4.The percentage of Free PSA (FPSA) in serum is described as being significantly higher in patients with BPH than in patients with prostate cancer. 5.Calculation of % free PSA (ie. FPSA/TPSA x 100 ), has been suggested as way of improving the differentiation of BPH and Prostate cancer.

**Interpretation:**

**Increased In-** Prostate diseases,Cancer,Prostatitis, Benign prostatic hyperplasia, Prostatic ischemia, Acute urinary retention, Manipulations like Prostatic massage, Cystoscopy, Needle biopsy, Transurethral resection,Digital rectal examination, Radiation therapy, Indwelling catheter, Vigorous bicycle exercise, Drugs (e.g., testosterone), Physiologic fluctuations. Also found in small amounts in other cancers (sweat and salivary glands, breast, colon, lung, ovary) and in Skene glands of female urethra and in term placenta ,Acute renal failure, Acute myocardial infarction,

**Decreased In-** Ejaculation within 24-48 hours, Castration, Antiandrogen drugs (e.g., finasteride), Radiation therapy, Prostatectomy, PSA falls 17% in 3 days after lying in hospital, Artfactual (e.g., improper specimen collection; very high PSA levels).Finasteride (5- $\alpha$ -reductase inhibitor) reduces PSA by 50% after 6 months in men without cancer.

**Reflex Tests:** % FREE PSA , USG Prostate

**Limitations:**

- tPSA values determined on patient samples by different testing procedures cannot be directly compared with one another and could be the cause of erroneous medical interpretations. If there is a change in the tPSA assay procedure used while monitoring therapy, then the tPSA values obtained upon changing over to the new procedure must be confirmed by parallelmeasurements with both methods. Immediate PSA testing following digital rectal examination, ejaculation, prostatic massage, indwelling catheterization, ultrasonography and needle biopsy of prostate is not recommended as they falsely elevate levels.
- Patients who have been regularly exposed to animals or have received immunotherapy or diagnostic procedures utilizing immunoglobulins or immunoglobulin fragments may produce antibodies, e.g. HAMA, that interferes with immunoassays.
- PSA results should be interpreted in light of the total clinical presentation of the patient, including: symptoms, clinical history, data from additional tests, and other appropriate information.
- Serum PSA concentrations should not be interpreted as absolute evidence for the presence or absence of prostate cancer.

**Reference:**

- Wallach's Interpretation of diagnostic tests
- Total PSA Pack insert

\*Sample processed at SUBURBAN DIAGNOSTICS (INDIA) PVT. LTD CPL, Andheri West



*Anupa*

**Dr.ANUPA DIXIT**  
**M.D.(PATH)**  
**Consultant Pathologist & Lab**  
**Director**





Use a QR Code Scanner  
Application To Scan the Code

CID : 2223924854  
Name : MR.AMARPAL SINGH  
Age / Gender : 53 Years / Male  
Consulting Dr. : -  
Reg. Location : G B Road, Thane West (Main Centre)

Collected :  
Reported :

\*\*\* End Of Report \*\*\*



CID : 2223924854  
Name : MR.AMARPAL SINGH  
Age / Gender : 53 Years / Male  
Consulting Dr. : -  
Reg. Location : G B Road, Thane West (Main Centre)

Use a QR Code Scanner  
Application To Scan the Code  
Collected : 27-Aug-2022 / 09:14  
Reported : 27-Aug-2022 / 12:01

**MEDIWHEEL FULL BODY HEALTH CHECKUP MALE ABOVE 40/2D ECHO**  
**EXAMINATION OF FAECES**

<u>PARAMETER</u>	<u>RESULTS</u>	<u>BIOLOGICAL REF RANGE</u>
<b><u>PHYSICAL EXAMINATION</u></b>		
Colour	Brown	Brown
Form and Consistency	Semi Solid	Semi Solid
Mucus	Absent	Absent
Blood	Absent	Absent
<b><u>CHEMICAL EXAMINATION</u></b>		
Reaction (pH)	Acidic (6.5)	-
Occult Blood	Absent	Absent
<b><u>MICROSCOPIC EXAMINATION</u></b>		
Protozoa	Absent	Absent
Flagellates	Absent	Absent
Ciliates	Absent	Absent
Parasites	Absent	Absent
Macrophages	Absent	Absent
Mucus Strands	Absent	Absent
Fat Globules	Absent	Absent
RBC/hpf	Absent	Absent
WBC/hpf	Absent	Absent
Yeast Cells	Absent	Absent
Undigested Particles	Present +	-
Concentration Method (for ova)	No ova detected	Absent
Reducing Substances	-	Absent

\*Sample processed at SUBURBAN DIAGNOSTICS (INDIA) PVT. LTD G B Road Lab, Thane West  
\*\*\* End Of Report \*\*\*



*Amit Taori*

**Dr.AMIT TAORI**  
**M.D ( Path )**  
**Pathologist**



CID : 2223924854  
Name : MR.AMARPAL SINGH  
Age / Gender : 53 Years / Male  
Consulting Dr. : -  
Reg. Location : G B Road, Thane West (Main Centre)

Collected : 27-Aug-2022 / 09:14  
Reported : 27-Aug-2022 / 14:33

Use a QR Code Scanner  
Application To Scan the Code

**MEDIWHEEL FULL BODY HEALTH CHECKUP MALE ABOVE 40/2D ECHO  
URINE EXAMINATION REPORT**

<u>PARAMETER</u>	<u>RESULTS</u>	<u>BIOLOGICAL REF RANGE</u>	<u>METHOD</u>
<b><u>PHYSICAL EXAMINATION</u></b>			
Color	Pale yellow	Pale Yellow	-
Reaction (pH)	Acidic (5.0)	4.5 - 8.0	Chemical Indicator
Specific Gravity	1.015	1.010-1.030	Chemical Indicator
Transparency	Clear	Clear	-
Volume (ml)	50	-	-
<b><u>CHEMICAL EXAMINATION</u></b>			
Proteins	Absent	Absent	pH Indicator
Glucose	Absent	Absent	GOD-POD
Ketones	Absent	Absent	Legals Test
Blood	Absent	Absent	Peroxidase
Bilirubin	Absent	Absent	Diazonium Salt
Urobilinogen	Normal	Normal	Diazonium Salt
Nitrite	Absent	Absent	Griess Test
<b><u>MICROSCOPIC EXAMINATION</u></b>			
Leukocytes(Pus cells)/hpf	1-2	0-5/hpf	
Red Blood Cells / hpf	Absent	0-2/hpf	
Epithelial Cells / hpf	2-3		
Casts	Absent	Absent	
Crystals	Absent	Absent	
Amorphous debris	Absent	Absent	
Bacteria / hpf	2-3	Less than 20/hpf	

\*Sample processed at SUBURBAN DIAGNOSTICS (INDIA) PVT. LTD G B Road Lab, Thane West  
\*\*\* End Of Report \*\*\*



*Amit Taori*

**Dr.AMIT TAORI**  
**M.D ( Path )**  
**Pathologist**



Use a QR Code Scanner  
Application To Scan the Code

CID : 2223924854  
Name : MR.AMARPAL SINGH  
Age / Gender : 53 Years / Male  
Consulting Dr. : -  
Reg. Location : G B Road, Thane West (Main Centre)

Collected : 27-Aug-2022 / 09:14  
Reported : 27-Aug-2022 / 14:04

**MEDIWHEEL FULL BODY HEALTH CHECKUP MALE ABOVE 40/2D ECHO**  
**BLOOD GROUPING & Rh TYPING**

<u>PARAMETER</u>	<u>RESULTS</u>
ABO GROUP	O
Rh TYPING	Positive

NOTE: Test performed by Semi- automated column agglutination technology (CAT)

Note: This sample has also been tested for Bombay group/Bombay phenotype/Oh using anti-H lectin.

Specimen: EDTA Whole Blood and/or serum

**Clinical significance:**

ABO system is most important of all blood group in transfusion medicine

**Limitations:**

- ABO blood group of new born is performed only by cell (forward) grouping because allo antibodies in cord blood are of maternal origin.
- Since A & B antigens are not fully developed at birth, both Anti-A & Anti-B antibodies appear after the first 4 to 6 months of life. As a result, weaker reactions may occur with red cells of newborns than of adults.
- Confirmation of newborn's blood group is indicated when A & B antigen expression and the isoagglutinins are fully developed at 2 to 4 years of age & remains constant throughout life.
- Cord blood is contaminated with Wharton's jelly that causes red cell aggregation leading to false positive result
- The Hh blood group also known as Oh or Bombay blood group is rare blood group type. The term Bombay is used to refer the phenotype that lacks normal expression of ABH antigens because of inheritance of hh genotype.

**References:**

1. Denise M Harmening, Modern Blood Banking and Transfusion Practices- 6th Edition 2012. F.A. Davis company. Philadelphia
2. AABB technical manual

\*Sample processed at SUBURBAN DIAGNOSTICS (INDIA) PVT. LTD G B Road Lab, Thane West

\*\*\* End Of Report \*\*\*



*Amit Taori*

**Dr.AMIT TAORI**  
**M.D ( Path )**  
**Pathologist**



CID : 2223924854  
Name : MR.AMARPAL SINGH  
Age / Gender : 53 Years / Male  
Consulting Dr. : -  
Reg. Location : G B Road, Thane West (Main Centre)

Use a QR Code Scanner  
Application To Scan the Code

Collected : 27-Aug-2022 / 09:14  
Reported : 27-Aug-2022 / 13:48

**MEDIWHEEL FULL BODY HEALTH CHECKUP MALE ABOVE 40/2D ECHO**  
**LIPID PROFILE**

<u>PARAMETER</u>	<u>RESULTS</u>	<u>BIOLOGICAL REF RANGE</u>	<u>METHOD</u>
CHOLESTEROL, Serum	<b>213.6</b>	Desirable: <200 mg/dl Borderline High: 200-239mg/dl High: >/=240 mg/dl	CHOD-POD
TRIGLYCERIDES, Serum	<b>241.8</b>	Normal: <150 mg/dl Borderline-high: 150 - 199 mg/dl High: 200 - 499 mg/dl Very high:>/=500 mg/dl	GPO-POD
HDL CHOLESTEROL, Serum	<b>29.5</b>	Desirable: >60 mg/dl Borderline: 40 - 60 mg/dl Low (High risk): <40 mg/dl	Homogeneous enzymatic colorimetric assay
NON HDL CHOLESTEROL, Serum	<b>184.1</b>	Desirable: <130 mg/dl Borderline-high:130 - 159 mg/dl High:160 - 189 mg/dl Very high: >/=190 mg/dl	Calculated
LDL CHOLESTEROL, Serum	<b>146.0</b>	Optimal: <100 mg/dl Near Optimal: 100 - 129 mg/dl Borderline High: 130 - 159 mg/dl High: 160 - 189 mg/dl Very High: >/= 190 mg/dl	Calculated
VLDL CHOLESTEROL, Serum	<b>38.1</b>	< /= 30 mg/dl	Calculated
CHOL / HDL CHOL RATIO, Serum	<b>7.2</b>	0-4.5 Ratio	Calculated
LDL CHOL / HDL CHOL RATIO, Serum	<b>5.0</b>	0-3.5 Ratio	Calculated





CID : 2223924854  
Name : MR.AMARPAL SINGH  
Age / Gender : 53 Years / Male  
Consulting Dr. : -  
Reg. Location : G B Road, Thane West (Main Centre)

Use a QR Code Scanner  
Application To Scan the Code  
Collected : 27-Aug-2022 / 09:14  
Reported : 27-Aug-2022 / 13:48

Note : LDL test is performed by direct measurement.

\*Sample processed at SUBURBAN DIAGNOSTICS (INDIA) PVT. LTD G B Road Lab, Thane West  
\*\*\* End Of Report \*\*\*



*Amit Taori*

**Dr.AMIT TAORI**  
**M.D ( Path )**  
**Pathologist**



CID : 2223924854  
 Name : MR.AMARPAL SINGH  
 Age / Gender : 53 Years / Male  
 Consulting Dr. : -  
 Reg. Location : G B Road, Thane West (Main Centre)

Use a QR Code Scanner  
 Application To Scan the Code  
 Collected : 27-Aug-2022 / 09:14  
 Reported : 27-Aug-2022 / 12:18

**MEDIWHEEL FULL BODY HEALTH CHECKUP MALE ABOVE 40/2D ECHO**  
**THYROID FUNCTION TESTS**

<u>PARAMETER</u>	<u>RESULTS</u>	<u>BIOLOGICAL REF RANGE</u>	<u>METHOD</u>
Free T3, Serum	3.3	3.5-6.5 pmol/L	ECLIA
Free T4, Serum	3.7	11.5-22.7 pmol/L	ECLIA
sensitiveTSH, Serum	More than 100.0	0.35-5.5 microIU/ml	ECLIA

Result rechecked.  
 Kindly correlate clinically.





Use a QR Code Scanner  
Application To Scan the Code

**CID** : 2223924854  
**Name** : MR.AMARPAL SINGH  
**Age / Gender** : 53 Years / Male  
**Consulting Dr.** : -  
**Reg. Location** : G B Road, Thane West (Main Centre)

**Collected** : 27-Aug-2022 / 09:14  
**Reported** : 27-Aug-2022 / 12:18

R  
E  
P  
O  
R  
T

**Interpretation:**

A thyroid panel is used to evaluate thyroid function and/or help diagnose various thyroid disorders.

**Clinical Significance:**

- 1)TSH Values between high abnormal upto15 microIU/ml should be correlated clinically or repeat the test with new sample as physiological factors can give falsely high TSH.
- 2)TSH values may be transiently altered because of non thyroidal illness like severe infections,liver disease, renal and heart severe burns, trauma and surgery etc.

TSH	FT4 / T4	FT3 / T3	Interpretation
High	Normal	Normal	Subclinical hypothyroidism, poor compliance with thyroxine, drugs like amiodarone, Recovery phase of non-thyroidal illness, TSH Resistance.
High	Low	Low	Hypothyroidism, Autoimmune thyroiditis, post radio iodine Rx, post thyroidectomy, Anti thyroid drugs, tyrosine kinase inhibitors & amiodarone, amyloid deposits in thyroid, thyroid tumors & congenital hypothyroidism.
Low	High	High	Hyperthyroidism, Graves disease, toxic multinodular goiter, toxic adenoma, excess iodine or thyroxine intake, pregnancy related (hyperemesis gravidarum, hydatiform mole)
Low	Normal	Normal	Subclinical Hyperthyroidism, recent Rx for Hyperthyroidism, drugs like steroids & dopamine), Non thyroidal illness.
Low	Low	Low	Central Hypothyroidism, Non Thyroidal Illness, Recent Rx for Hyperthyroidism.
High	High	High	Interfering anti TPO antibodies, Drug interference: Amiodarone, Heparin, Beta Blockers, steroids & anti epileptics.

**Diurnal Variation:**TSH follows a diurnal rhythm and is at maximum between 2 am and 4 am , and is at a minimum between 6 pm and 10 pm. The variation is on the order of 50 to 206%. Biological variation:19.7%(with in subject variation)

**Reflex Tests:**Anti thyroid Antibodies,USG Thyroid ,TSH receptor Antibody. Thyroglobulin, Calcitonin

**Limitations:**

1. Samples should not be taken from patients receiving therapy with high biotin doses (i.e. >5 mg/day) until atleast 8 hours following the last biotin administration.
2. Patient samples may contain heterophilic antibodies that could react in immunoassays to give falsely elevated or depressed results. this assay is designed to minimize interference from heterophilic antibodies.

**Reference:**

- 1.O.koulouri et al. / Best Practice and Research clinical Endocrinology and Metabolism 27(2013)
- 2.Interpretation of the thyroid function tests, Dayan et al. THE LANCET . Vol 357
- 3.Tietz ,Text Book of Clinical Chemistry and Molecular Biology -5th Edition
- 4.Biological Variation:From principles to Practice-Callum G Fraser (AACC Press)

\*Sample processed at SUBURBAN DIAGNOSTICS (INDIA) PVT. LTD G B Road Lab, Thane West



*Amit Taori*

**Dr.AMIT TAORI**  
**M.D ( Path )**  
**Pathologist**



Use a QR Code Scanner  
Application To Scan the Code

CID : 2223924854  
Name : MR.AMARPAL SINGH  
Age / Gender : 53 Years / Male  
Consulting Dr. : -  
Reg. Location : G B Road, Thane West (Main Centre)

Collected :  
Reported :

\*\*\* End Of Report \*\*\*



CID : 2223924854  
Name : MR.AMARPAL SINGH  
Age / Gender : 53 Years / Male  
Consulting Dr. : -  
Reg. Location : G B Road, Thane West (Main Centre)

Collected : 27-Aug-2022 / 09:14  
Reported : 27-Aug-2022 / 12:59

Use a QR Code Scanner  
Application To Scan the Code

**MEDIWHEEL FULL BODY HEALTH CHECKUP MALE ABOVE 40/2D ECHO  
LIVER FUNCTION TESTS**

<u>PARAMETER</u>	<u>RESULTS</u>	<u>BIOLOGICAL REF RANGE</u>	<u>METHOD</u>
BILIRUBIN (TOTAL), Serum	0.33	0.1-1.2 mg/dl	Diazo
BILIRUBIN (DIRECT), Serum	0.14	0-0.3 mg/dl	Diazo
BILIRUBIN (INDIRECT), Serum	0.19	0.1-1.0 mg/dl	Calculated
TOTAL PROTEINS, Serum	8.0	6.4-8.3 g/dL	Biuret
ALBUMIN, Serum	4.4	3.5-5.2 g/dL	BCG
GLOBULIN, Serum	<b>3.6</b>	2.3-3.5 g/dL	Calculated
A/G RATIO, Serum	1.2	1 - 2	Calculated
SGOT (AST), Serum	<b>47.9</b>	5-40 U/L	IFCC without pyridoxal phosphate activation
SGPT (ALT), Serum	<b>46.5</b>	5-45 U/L	IFCC without pyridoxal phosphate activation
GAMMA GT, Serum	<b>144.3</b>	3-60 U/L	IFCC
ALKALINE PHOSPHATASE, Serum	85.3	40-130 U/L	PNPP

\*Sample processed at SUBURBAN DIAGNOSTICS (INDIA) PVT. LTD G B Road Lab, Thane West  
\*\*\* End Of Report \*\*\*



*Amit Taori*

**Dr.AMIT TAORI**  
**M.D ( Path )**  
**Pathologist**