

Facilities:

All clinical Biomedical & Hematology Investigations including Bone Marrow Examination
 VPT, Podiascan & Complete Foot Care (First Time in Purvanchal)
 All Hormonal Investigation by Chemiluminescent Method
 Visceral Fat by (AB-140) Ambulatory BP Monitoring
 CGMS & Insulin Pump Available
 PFT, 2D-ECHO (Color Doppler), Holter, TMT, Cardiac-3 available
 VIA, VILI, Colposcopy available
 Special Endocrinological Investigation Protocols.

ISO 9001:2008 Certified

Mobile: 9389994334, 9554572190, 9453837595

**Panacea Pathology****Clinical Reference Lab**

Persistence, Preparedness and Precision
 EQAS (CMC Vellore Attached) & IQAS System
 पूर्वांचल की सर्वोत्तम गुणवत्ता वाली पैथोलॉजी

PATIENT NAME : SHAILESH KUMAR	AGE/GENDER : 45YRS/MALE
REFD BY DR. : ARCO FEMI HEALTHCARE LTD.	RECEIVED DATE : 13-04-2023 (02:00PM)
SAMPLE : BLOOD & URINE	REPORT DATE : 13-04-2023 (03:30PM)

PATHOLOGY REPORT**COMPLETE BLOOD COUNT (CBC)**

TEST	LAB TEST VALUES	NORMAL RANGE
HEMOGRAM		
HEMOGLOBIN (FLOW CYTOMETRY)	14.1	13 – 16 gm/dl
TOTAL LEUCOCYTE COUNT (TLC)	8,200	4000 – 11000
RBC COUNT	5.44	3.5 – 5.5
PCV (HCT)	46.9	37 – 47
MCV	86.9	80 – 95
MCH	25.9	28 – 34
MCHC	30.0	30 – 36
PLATELET COUNT	1,85,000	1,50,000 – 4,00,000
E.S.R. (WINTROBE FIRST HOURS)	12.0	20 mm/1 st hr
DIFFERENTIAL LEUCOCYTE		
NEUTROPHILS	54	40 – 75%
LYMPHOCYTES	41	20 – 45%
EOSINOPHILS	02	1 – 6%
MONOCYTES	03	2 – 8%
BASOPHILS	00	< 2%

RANDOM/FASTING BLOOD SUGAR

TEST	LAB TEST VALUES	NORMAL RANGE
RBS/FBS		
FASTING BLOOD SUGAR	95.6	70-125 mg/dl
RANDOM BLOOD SUGAR	108.0	125-140 mg/dl

GLYCOSYLATED HEMOGLOBIN (HBA1C)

TEST	LAB TEST VALUES	NORMAL RANGE
HBA1C	5.9	Normal : <5.97 % Good Control : 5.97 – 6.81% Fair Control : 6.81 – 7.65% Poor Control : >7.65%

PAGE 1

Lab Technician

PANACEA HOSPITAL
 (A UNIT OF ARCOHA HEALTH CARE PVT. LTD.)
 REG. NO. AL-1500
 B.36/44, KABIR NAGAR
 M.D., Pathology

Timing : 8.00 a.m. to 9.00 p.m. (Sunday 8.00 a.m. to 3.00 p.m.)

This Report is not valid for medico legal purpose

Note: These tests have technical limitations. Clinico-pathological interpretation is necessary. In case of any disparity test

Facilities:

All clinical Biomedical & Hematology Investigations including Bone Marrow Examination
 VPT, Podiascan & Complete Foot Care (First Time in Purvanchal)
 All Hormonal Investigation by Chemiluminescent Method
 Visceral Fat by (AB-140) Ambulatory BP Monitoring
 CGMS & Insulin Pump Available
 PFT, 2D-ECHO (Color Doppler), Holter, TMT, Cardiac-3 available
 VIA, VILI, Colposcopy available
 Special Endocrinological Investigation Protocols.

ISO 9001:2008 Certified
 Mobile: 9389994334, 9554572190, 9453837595



Panacea Pathology

Clinical Reference Lab

Persistence, Preparedness and Precision
 EQAS (CMC Vellore Attached) & IQAS System
 पूर्वांचल की सर्वोत्तम गुणवत्ता वाली पैथोलॉजी

PATIENT NAME : SHAILESH KUMAR

AGE/GENDER : 45YRS/MALE

REFD BY DR. : ARCO FEMI HEALTHCARE LTD.

RECEIVED DATE : 13-04-2023 (02:00PM)

SAMPLE : BLOOD & URINE

REPORT DATE : 13-04-2023 (03:30PM)

PATHOLOGY REPORT

LIPID PROFILE, SERUM

TEST	LAB TEST VALUES	NORMAL RANGE
BLOOD CHEMISTRY		
TOTAL CHOLESTEROL (SERUM)	168.0	Desirable:- < 200 mg/dl Borderline:- 200 – 239 mg/dl High:- > 240 mg/dl
TRIGLYCERIDES (SERUM)	154.0	35 – 170 mg/dl
HDL CHOLESTEROL(SERUM)	45.0	35.30 – 79.50 mg/dl
LDL CHOLESTEROL (SERUM)	92.2	< 130 mg/dl
VLDL	30.8	< 40 mg/dl
CHOLESTROL/HDL RATIO	3.73	< 3.0 Low Risk Ratio 3.0 – 5.0 Avg Risk > 5.0 High Risk
LDL/HDL RATIO	2.04	< 3 Ratio

BLOOD GROUP

TEST	LAB TEST VALUES
BLOOD GROUP ABO & RH FACTOR	
BLOOD GROUP	"O"
RH FACTOR	POSITIVE

LIVER PROFILE TEST, SERUM

TEST	LAB TEST VALUES	NORMAL RANGE
BIO CHEMISTRY		
TOTAL BILIRUBIN	0.68	0.0 – 1.1 mg/dl
DIRECT BILIRUBIN	0.22	0.0 – 0.2 mg/dl
INDIRECT BILIRUBIN	0.46	< 0.90 mg/dl
SGOT (AST)	23.0	0 – 52 mg/dl
SGPT (ALT)	25.0	0 – 39 mg/dl
GGT (GYT)	19.8	< 55 U/L

THYROID PROFILE (T3, T4, TSH)

TEST	LAB TEST VALUES	NORMAL RANGE
THYROID FUNCTION TEST		
T3	1.10	0.60 – 1.81 ng/ml
T4	7.42	4.50 – 10.90 ug/dl
TSH	2.15	0.39 – 6.10 uIU/mL

PAGE 2

Lab Technician

PANACEA HOSPITAL
 (A UNIT OF ARCO FEMI HEALTHCARE PVT. LTD.)
 REGIONAL HEADQUARTERS
 B.36/44, 4-4, ABIR NAGAR
 DURGAKIND, VARANASI

Timing : 8.00 a.m. to 9.00 p.m. (Sunday 8.00 a.m. to 3.00 p.m.)

This Report is not valid for medico legal purpose

Note: These tests have technical limitations. Clinico-pathological interpretation is necessary. In case of any disparity test

Facilities:

All clinical Biomedical & Hematology Investigations including Bone Marrow Examination
 VPT, Podiascan & Complete Foot Care (First Time in Purvanchal)
 All Hormonal Investigation by Chemiluminescent Method
 Visceral Fat by (AB-140) Ambulatory BP Monitoring
 CGMS & Insulin Pump Available
 PFT, 2D-ECHO (Color Doppler), Holter, TMT, Cardiac-3 available
 VIA, VILI, Colposcopy available
 Special Endocrinological Investigation Protocols.

ISO 9001:2008 Certified
 Mobile: 9389994334, 9554572190, 9453837595



Panacea Pathology

Clinical Reference Lab

Persistence, Preparedness and Precision
 EQAS (CMC Vellore Attached) & IQAS System
 पूर्वांचल की सर्वोत्तम गुणवत्ता वाली पैथोलॉजी

PATIENT NAME : SHAILESH KUMAR

AGE/GENDER : 45YRS/MALE

REFD BY DR. : ARCO FEMI HEALTHCARE LTD.

RECEIVED DATE : 13-04-2023 (02:00PM)

SAMPLE : BLOOD & URINE

REPORT DATE : 13-04-2023 (03:30PM)

PATHOLOGY REPORT

RENAL & KIDNEY PROFILE, SERUM

TEST	LAB TEST VALUES	NORMAL RANGE
RENAL FUNCTION TESTS		
BLOOD UREA NITROGEN (BUN)	10.2	10 – 50 mg/dl
SERUM CREATININE	0.78	0.60 – 1.60 mg/dl
URIC ACID	3.76	3.60 – 7.70 mg/dl
ALKALINE PHOSPHATASE (ALP)	71.0	142 – 353 mg/dl
TOTAL PROTIENS	7.54	0 – 39 mg/dl
ALBUMIN	4.24	3.8 – 5.4 mg/dl
SERUM GLOBULIN	3.30	2.1 – 3.5 mg/dl
AG RATIO	1.28	-

URINE ROUTINE EXAMINATION

TEST	LAB TEST VALUES	NORMAL RANGE
PHYSICAL EXAMINATION		
QUANTITY	30	ML
COLOUR	STRAW	PALE YELLOW
APPEARANCE	CLEAR	CLEAR
SPECIFIC GRAVITY	1.010	1.01 – 1.03
PH	6.0	4.7 – 7.5
CHEMICAL EXAMINATION		
GLUCOSE	Not Detected	Not Detected
PROTEIN	NIL	Not Detected
MICROSCOPIC EXAMINATION		
PUS CELLS	01-02	0-5
RBC	Not Detected	Not Detected
EPITHELIAL CELLS	01-02	0-5
CASTS	Not Detected	Not Detected
CRYSTALS	Not Detected	Not Detected
BACTERIA	Not Detected	Not Detected

----- End of Report -----

Lab Technician

PANACEA HOSPITAL
 UNIT OF ARCOHA HEALTH CARE PVT. LTD.
 REG. NO. CAL/1500
 B.36/4, P.O. KABIR NAGAR
 DURGAJI, VARANASI
 M.D., Pathology

Timing : 8.00 a.m. to 9.00 p.m. (Sunday 8.00 a.m. to 3.00 p.m.)

This Report is not valid for medico legal purpose

Note: These tests have technical limitations. Clinico-pathological interpretation is necessary. In case of any disparity test



Call Now - 1800-123-3070

PANACEA HOSPITAL

A shelter for many hearts A Home for many lives

(An ISO 9001:2008 Certified Organisation)

Lab Attached with CMC Vellore Under EQAS Scheme

PATIENT'S NAME : MR.SHAILESH KUMAR
REF. BY : Dr. ASHUTOSH MISHRA(MD)

AGE/SEX: 45 Y/M
Thursday, April 13, 2023

Echo - Cardiography

MITRAL VALVE Doppler	AML - normal morphology MV Flow - E - 0.7 A-0.4 E/A=1.68	PML - normal morphology MVA - 3.0 cm ² Mitral Regurgitation - No
TRICUSPID VALVE Doppler	Normal TV Flow -No	Tricuspid Regurgitation -No
PULMONARY VALVE Doppler	Normal PV Flow -No	Pulmonary Regurgitation - No
AORTIC VALVE Doppler	Trileaflet-No AV Flow - no	Aortic Regurgitation - no
MEASUREMENT	Aorta - 21.7 (20-38) mm IVS ed - 12.0 (6 -12) mm LVID ed -43.4 (35 - 55) mm LVPW ed - 13.1 (6 -12) mm OA - 7 (> 5) mm	LA - 30.3 (24-32) mm IVS es -16.6 (6 - 12) mm LVID es - 30.8 (24 - 40) mm LVPW es -13.1 (6 -12) mm EPSS - 4 (< 9) mm


CONCLUSION

All cardiac chamber dimensions are WNL
No valvular abnormalities
Normal LV systolic function present Modified Simpson's method (4C, 2C) (LVEF=56%)
No diastolic dysfunction present (E/A = 1.68) by tissue Doppler (E/e'=6.2)
No RWMA
No pericardial effusion
Intact IAS / IV
No PAH
No intra cardiac mass /thrombus /vegetation

IMPRESSION

Normal Echocardiogram

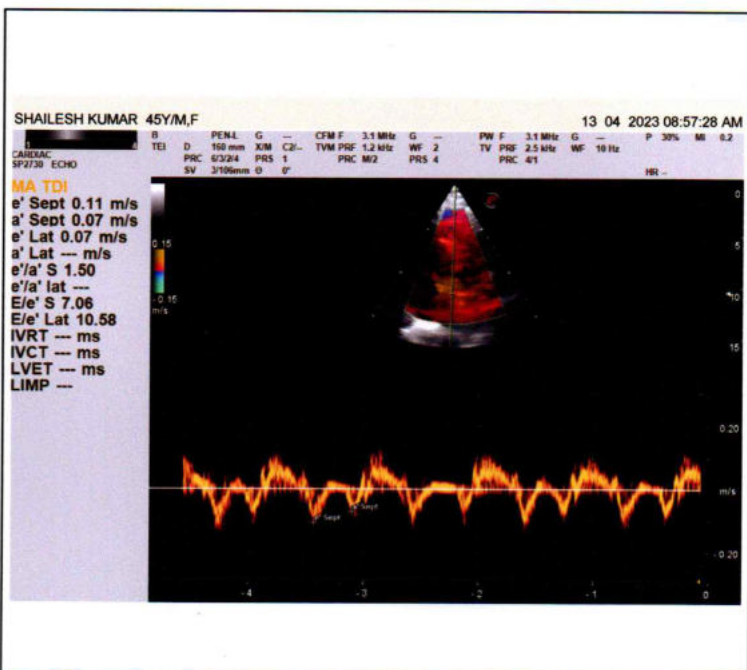
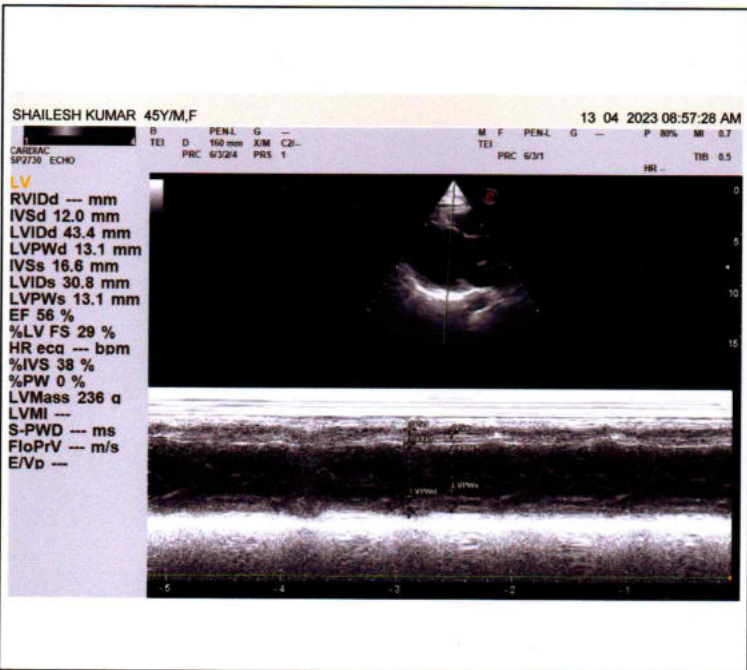
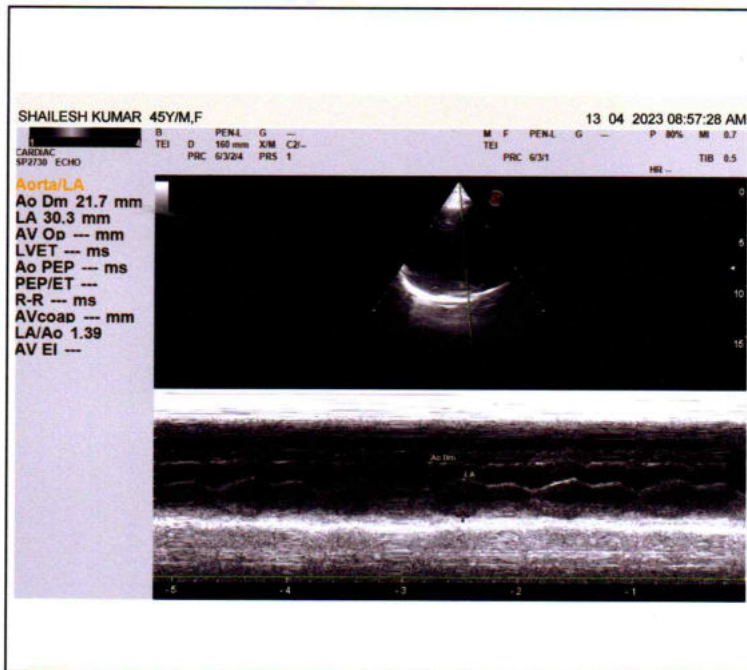
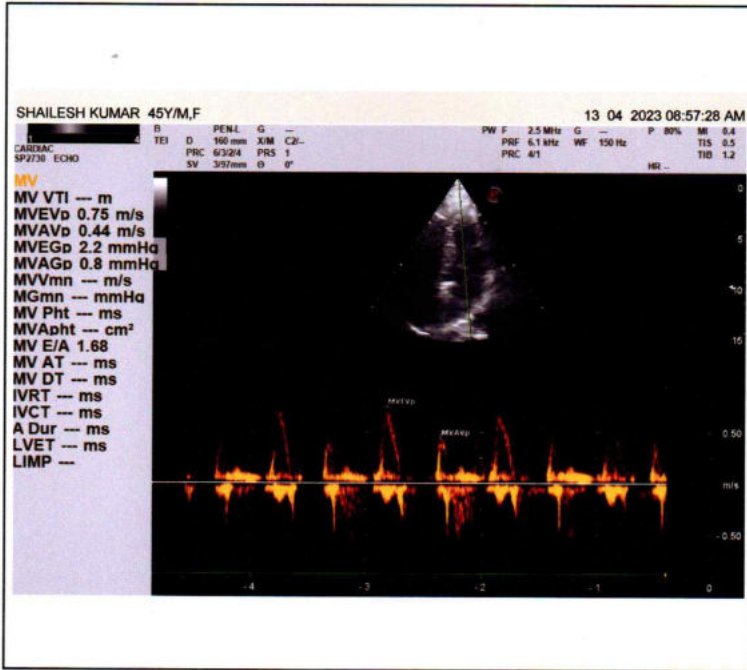

Niraj Mishra
Physician Assistant,
(PIIRE)


Dr. Pallavi Mishra
MBBS, MD (MED) Lucknow
Echocardiography Specialist, MIAE
Non-invasive cardiologist
Women Cardiologist
Diabetocardiologist

Address : Kabir Nagar (Near Sanjay Shiksha Niketan), Durgakund, Varanasi

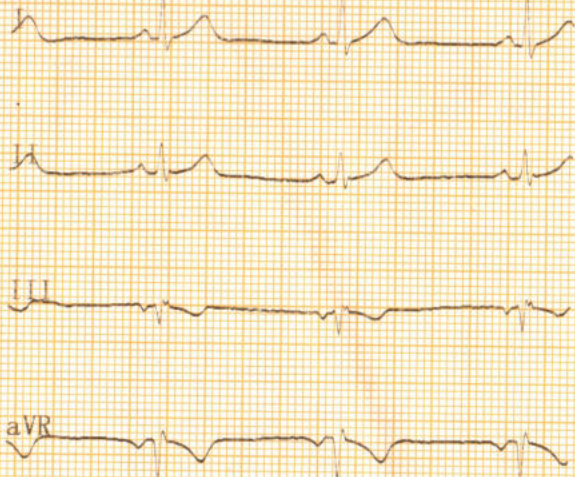Mobile : 9554572190 / 9453837595 / Recpn. 9389994334

E-mail : dramishra@gmail.com, drpallaviojha@gmail.com, Website: www.piire.org

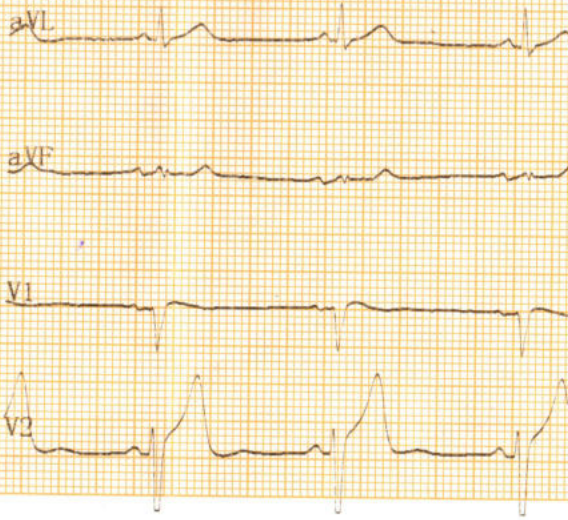


BPL

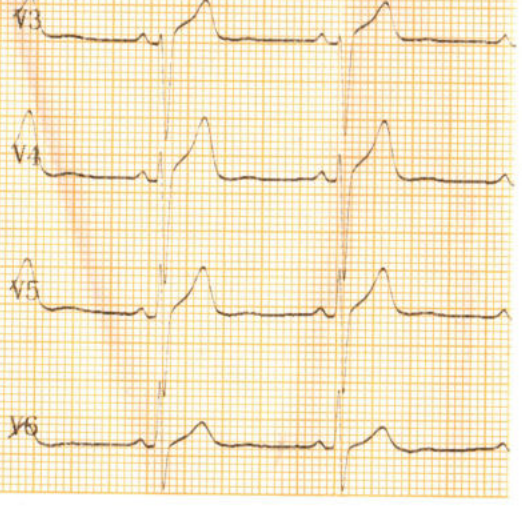
AUTO 10mm/mV



10mm/mV



10mm/mV



25mm/s AC50Hz+EMG35Hz+DFT



Call Now - 1800-123-3070

PANACEA HOSPITAL

A shelter for many hearts A Home for many lives


(An ISO 9001:2008 Certified Organisation)

Lab Attached with CMC Vellore Under EQAS Scheme

PATIENT'S NAME : SHAILESH KUMAR AGE/SEX: 45 Y/M
REF. BY : Dr. ASHUTOSH MISHRA(MD) Thursday, April 13, 2023

U/S. WHOLE ABDOMEN

- LIVER** : Liver is normal in size, shape & echotexture. Intra hepatic biliary radicals are normal. Portal venous channels are normal.
- G. B.** : Gall bladder is normal in size, lumen is clear. Wall thickness normal.
- C.B.D.** : C.B.D. is normal in caliber.
- PANCREAS** : Pancreas is normal in size, shape and echotexture. No evidence of any inflammatory disease or mass.
- SPLEEN** : Spleen is normal in size, shape and echotexture.
- Rt. KIDNEY** : Normal in size, shape and echotexture. Renal sinus is normal
Cortico medullary differentiation is normal. P. C. system is normal.
- Lt. KIDNEY** : Normal in size, shape and echotexture. Renal sinus is normal
Cortico medullary differentiation is normal. P. C. system is normal.
- URI. BLADDER** : Urinary bladder is normal in size, position. Wall thickness normal.
- PROSTATE** : Prostate is normal in size.
No ascites & retro peritoneal lymphadenopathy seen.
- IMPRESSION** : **NO OBVIOUS SONOLOGICAL ABNORMALITY SEEN.**


DR. R. K. TIWARI
Consultant radiologist
MBBS MD (GOLD MEDALIST)

King George Medical University, Lucknow

Thanks for reference.

Address : Kabir Nagar (Near Sanjay Shiksha Niketan), Durgakund, Varanasi

Mobile : 9554572190 / 9453837595 / Recpn. 9389994334

E-mail : dramishra@gmail.com, drpallaviojha@gmail.com, Website: www.piire.org

SHAILESH KUMAR 45Y/M,F
13 04 2023 08:54:19 AM
P 60% MI 0.8

ABDOMINAL AC2541 ABD
TEI D 211 mm X/M C2/-
PRC 19/2/3/5 PRS 4

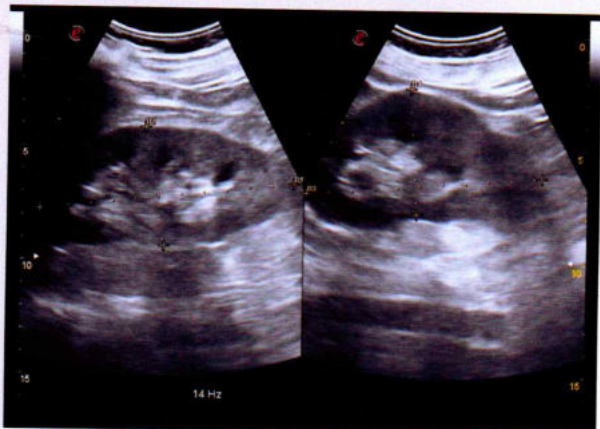
D1
135.3 mm



SHAILESH KUMAR 45Y/M,F
13 04 2023 08:54:19 AM
P 60% MI 0.8

ABDOMINAL AC2541 ABD
TEI D 152 mm X/M C2/-
PRC 19/2/3/5 PRS 4

D-Ratio
D1 111.9 mm
D2 52.7 mm
D/D 212 %
D-Ratio
D3 103.4 mm
D4 55.4 mm
D/D 187 %



SHAILESH KUMAR 45Y/M,F
13 04 2023 08:54:19 AM
P 60% MI 0.8

ABDOMINAL AC2541 ABD
TEI D 152 mm X/M C2/-
PRC 19/2/3/5 PRS 4

D1
101.9 mm



SHAILESH KUMAR 45Y/M,F
13 04 2023 08:54:19 AM
P 60% MI 0.8

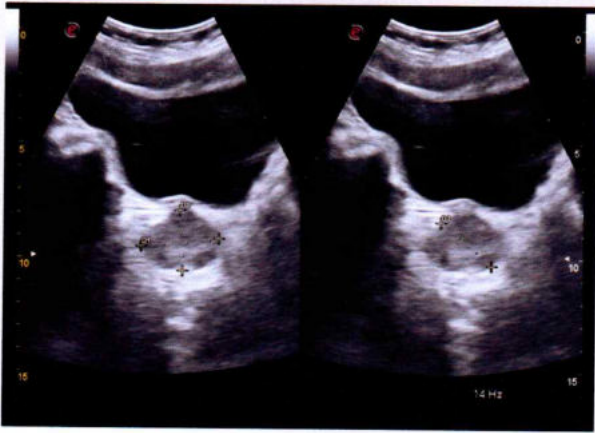
ABDOMINAL AC2541 ABD
TEI D 152 mm X/M C2/-
PRC 19/2/3/5 PRS 4



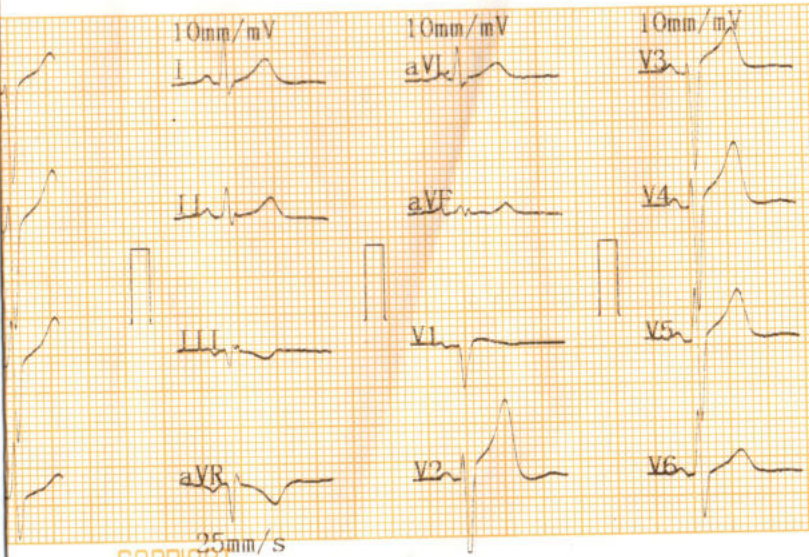
SHAILESH KUMAR 45Y/M,F
13 04 2023 08:54:19 AM
P 60% MI 0.8

ABDOMINAL AC2541 ABD
TEI D 152 mm X/M C2/-
PRC 19/2/3/5 PRS 4

Bi-Volume
D1 34.3 mm
D2 26.6 mm
D3 29.4 mm
V 14.1 ml



BPL



2023 04 13 08:53

<< Conclusions >>

ID :
 Name : **SHAIKESH KUMAR**
 Sex : **MALE** Age : **45 YRS**
 Height : _____ Weight : _____ kg
 SYS : _____
 DIA : _____

Normal Sinus Rhythm.
 Longitudinal Left axis deviation.
 Report need physician confirm

HR : 62 bpm
 PR Interval : 133 ms
 P Duration : 98 ms
 QRS Duration : 76 ms
 T Duration : 178 ms
 QT/QTc : 333/338 ms
 P/QRS/T Axis : deg : 25.7/16.2/13.2
 R(V5)/S(V1) : mV : 0.70/0.56
 R(V5) - S(V1) : mV : 1.25

DR. PALLAV MISHRA
 MBBS, MD (GENERAL MEDICINE)
 MCI Reg. No. 52033

Physician _____

CARDIART 25mm/s

Call Now - 1800-123-3070



PANACEA HOSPITAL

A shelter for many hearts A Home for many lives

(An ISO 9001:2008 Certified Organisation)

Lab Attached with CMC Vellore Under EQAS Scheme

PATIENT'S NAME : SHAILESH KUMAR	AGE/SEX: 45 Y/M
REF. BY : Dr. ASHUTOSH MISHRA(MD)	Thursday, April 13, 2023

X-RAY CHEST (PA VIEW)

BOTH LUNG FIELDS AND PLEURAE:

Both lungs show normal bronchovascular pattern.

Right & left hila are normal

No focal mass or calcification is seen

There is no evidence of any fluid in the both the pleural cavities.

Both domes of diaphragms are normal in position.

MEDIASTINUM:

Trachea is central in position.

Cardiac silhouette is of normal size and configuration.

No evidence of pericardial effusion.

No significant lymphadenopathy is seen.

Visualized skeleton is normal.

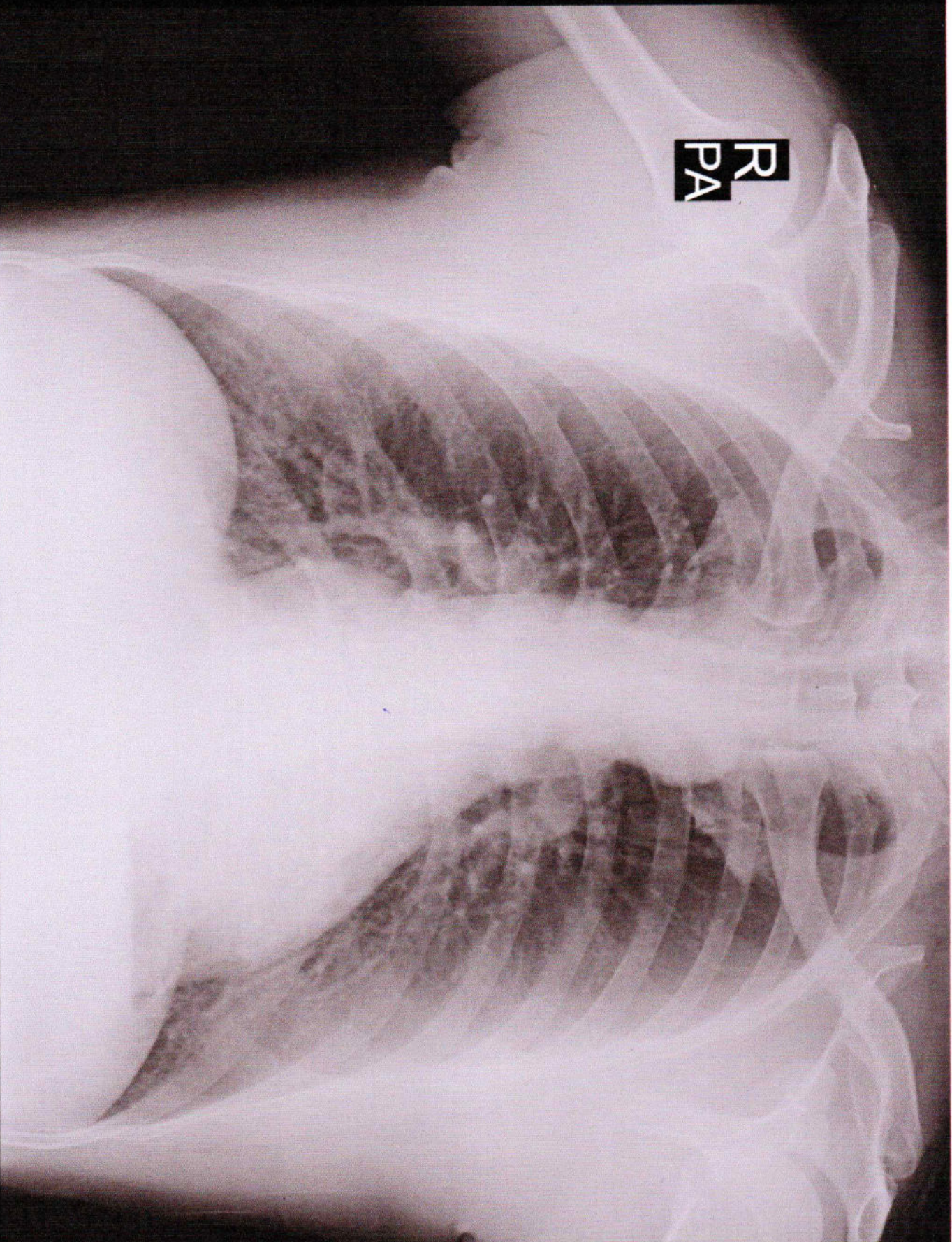
DR. R. K. TIWARI
M.B.B.S, M.D.(KGMU, LKO)
(RADIODIAGNOSIS).

Thanks for reference.

Address : Kabir Nagar (Near Sanjay Shiksha Niketan), Durgakund, Varanasi

Mobile : 9554572190 / 9453837595 / Recpn. 9389994334

E-mail : dramishra@gmail.com, drpallaviojha@gmail.com, Website: www.piire.org



R
PA

SHALESH KUMAR 45Y/M 0175 O CHEST P.A. 13-Apr-23 12:51 PM

PANACEA HOSPITAL, KABIR NAGAR, DURGAKUND, VARANASI