



## SCAN REPORT

NAME	: MRS. ARATI GHATWAL	PATIENT ID	: MH20230044312
AGE/SEX	: 54 Years / female	IP / OP NO	: OP21042316
CONSULTANT	: DR. ARUN PRAKASH	DATE	: 20/02/2023

### ULTRA SOUND SCAN OF ABDOMEN

**LIVER:** Normal in size and normal in echotexture. No focal lesions are seen. No dilatation of intra-hepatic biliary radicals present. Hepatic veins and IVC appear normal. Portal vein is normal in caliber. Common bile duct is normal in caliber.

**GALL BLADDER:** Normal in size and wall thickness. No evidence of any calculus or mass present. No evidence of pericholecystic collections.

**PANCREAS:** Normal in size and echotexture. No focal lesions are seen. No evidence of calculi or calcifications. No evidence of pancreatic duct dilation.

**PARA AORTIC AREAS:** Aorta and IVC appear normal. No evidence of para aortic lymphadenopathy.

**SPLEEN:** Normal in size and measures-7.3 cm. Normal in echotexture. No evidence of focal lesions.

**RIGHT KIDNEY:** Measures 9.4 X 4.3 cm and is normal in size and echotexture. Cortico medullary differentiation is well maintained. There is no hydronephrosis or mass.

**LEFT KIDNEY:** Measures 8.7 X 4.1 cm and is normal in size and echotexture. Cortico medullary differentiation is well maintained. There is no calculus or hydronephrosis or mass.

**Healing Hearts and Lives**

264/125, Kilpauk Garden Road, Kilpauk, Chennai - 600 010. Phone : +91 44 4644 8989 / 75500 53335

Email : muruganhosp@gmail.com | Website : www.muruganhospitals.in

**URINARY BLADDER:** Normal in size, contour and wall thickness. There is no evidence of calculus or mass. No vesical diverticulum present.

**UTERUS AND OVARIES :** Normal in size and measures- 4.3 X 3.8 cm echotexture. ET- Thin, bilateral ovaries atrophic.

No ascites present. No retroperitoneal lymphadenopathy present.

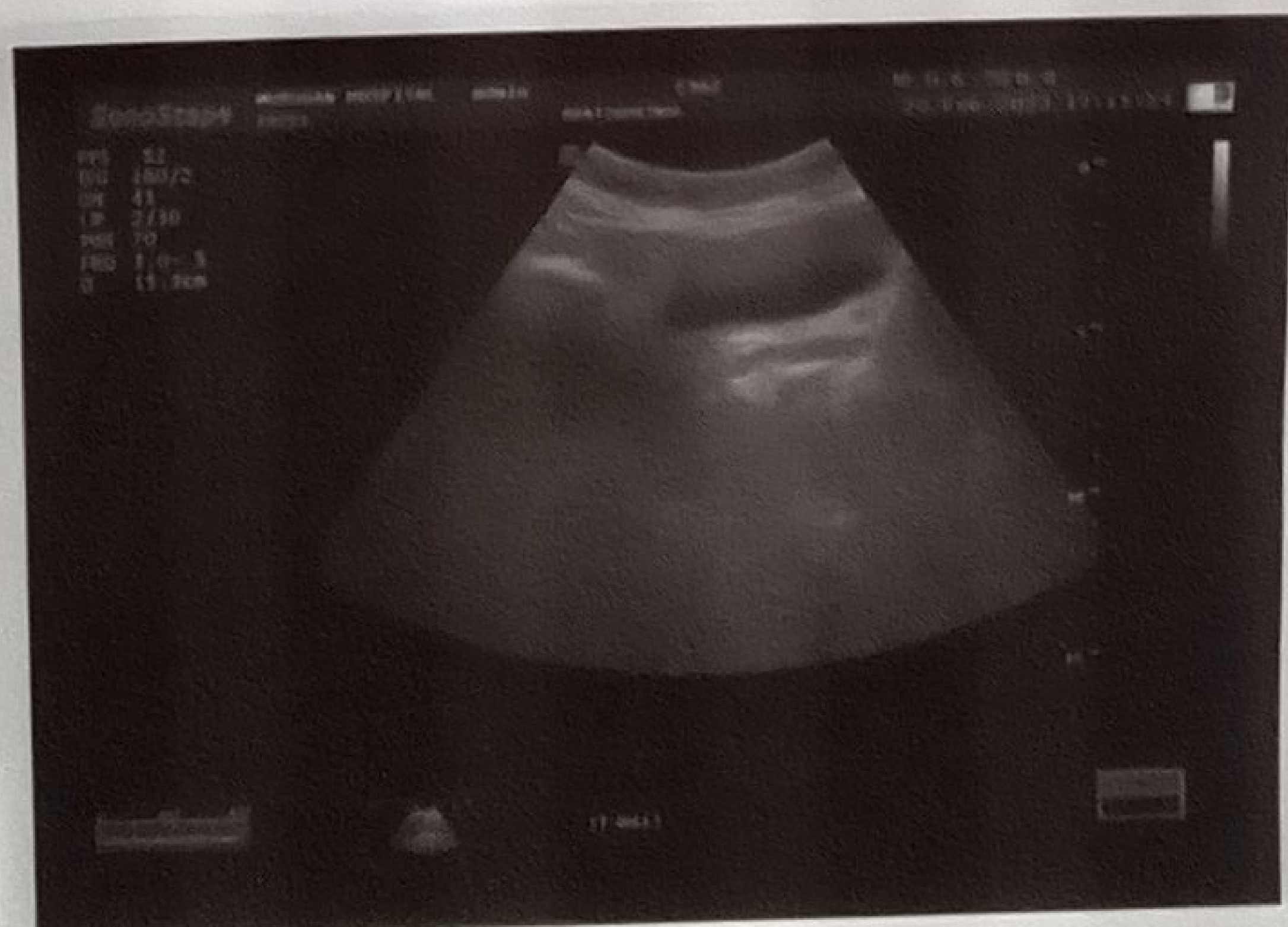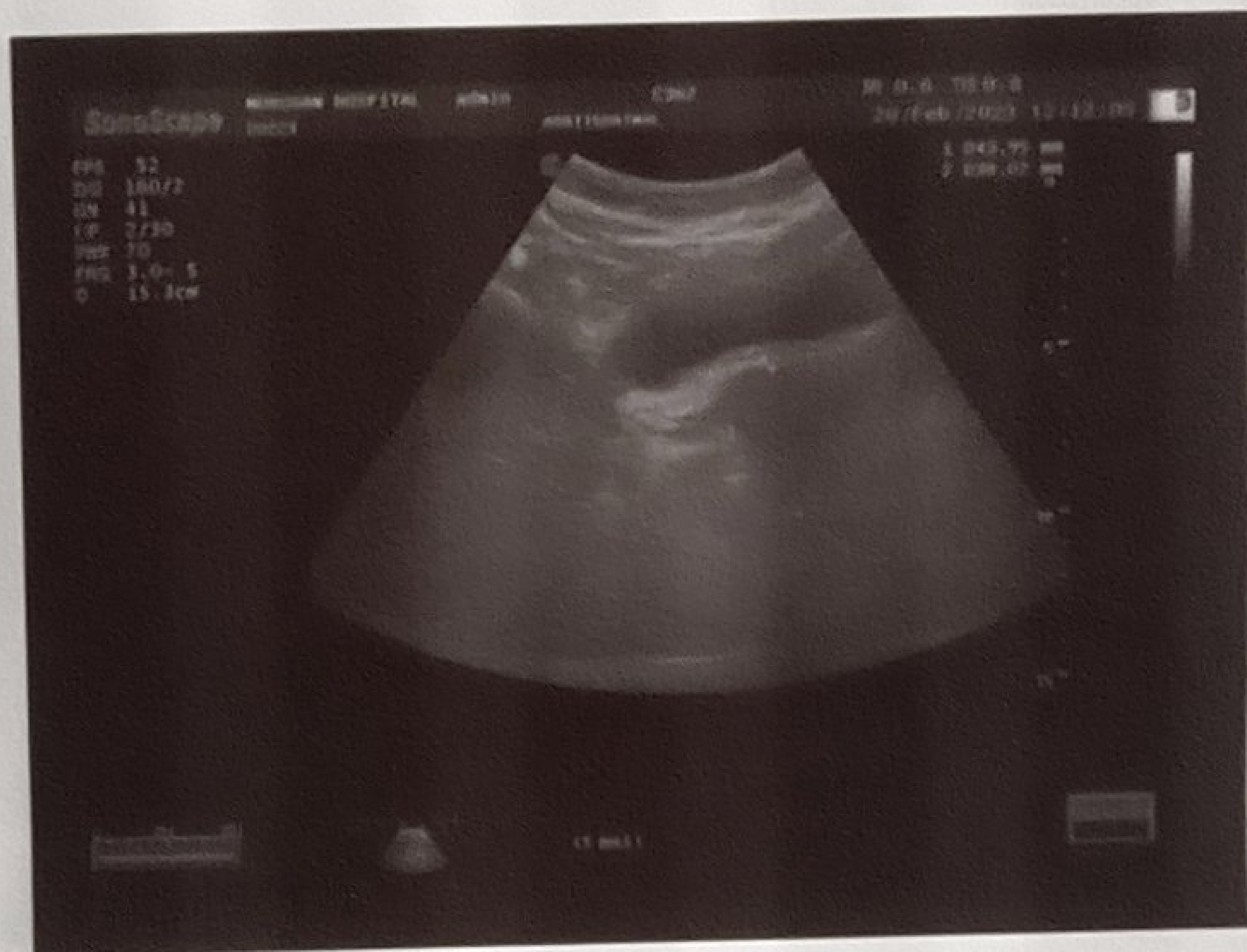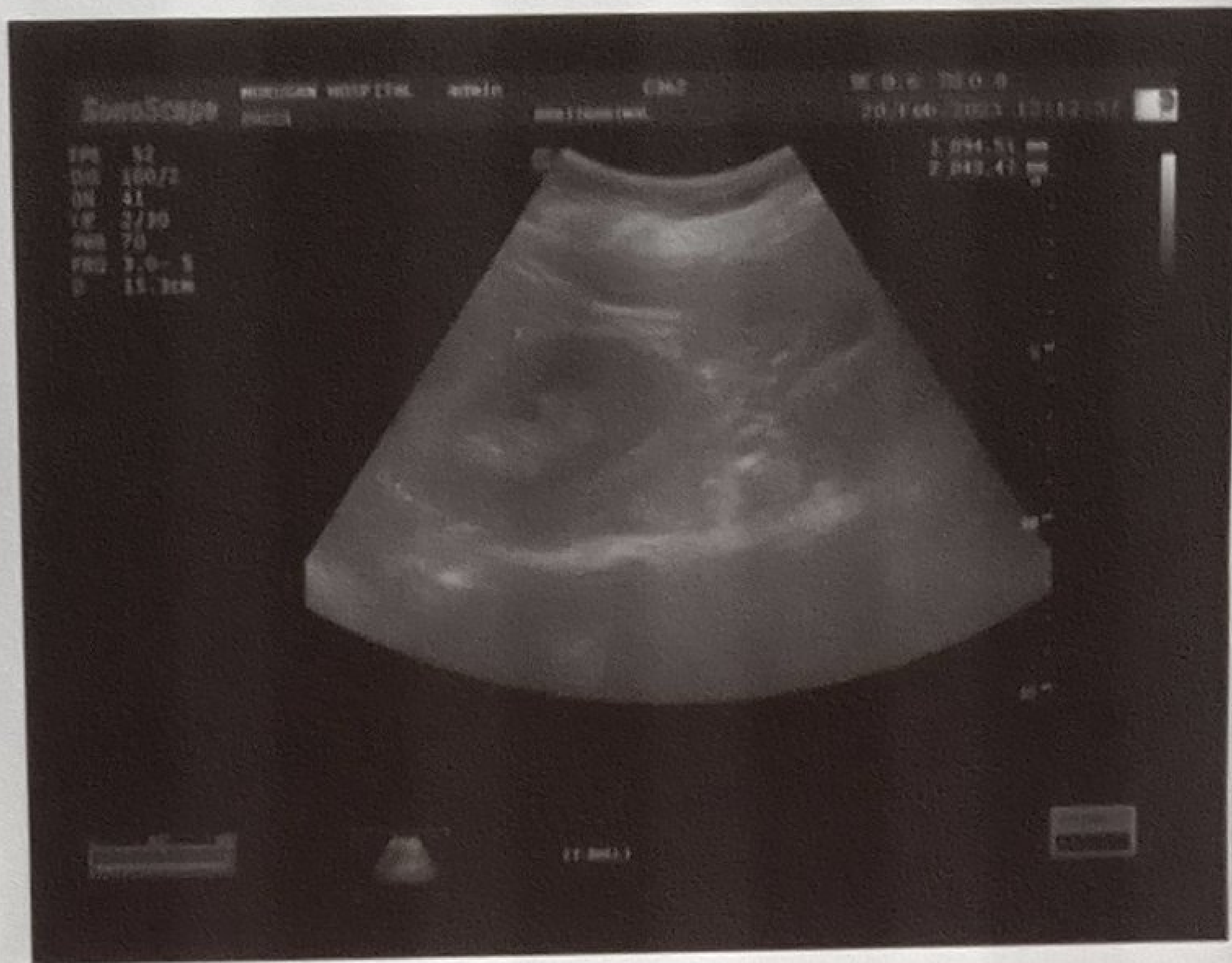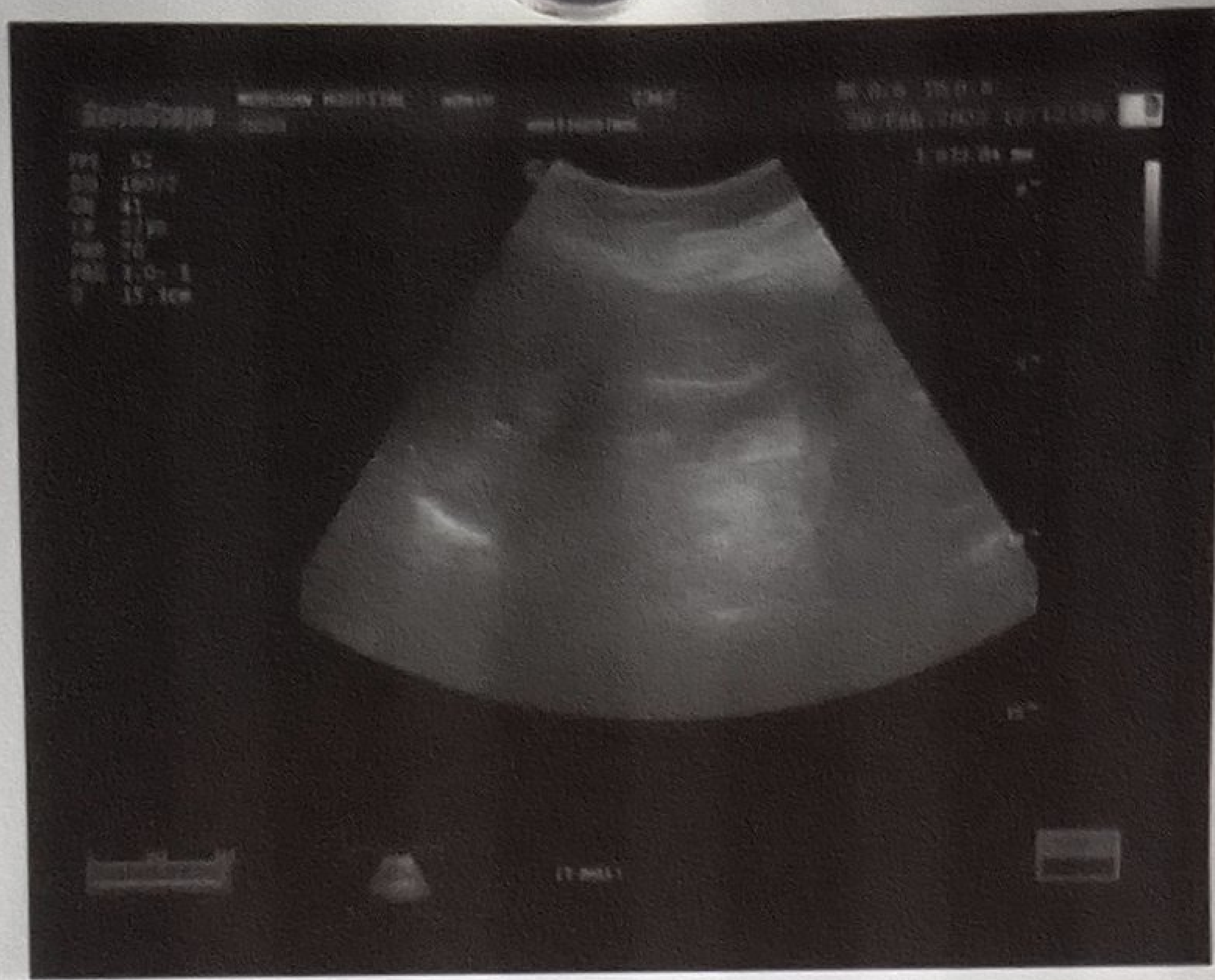**IMPRESSION:**

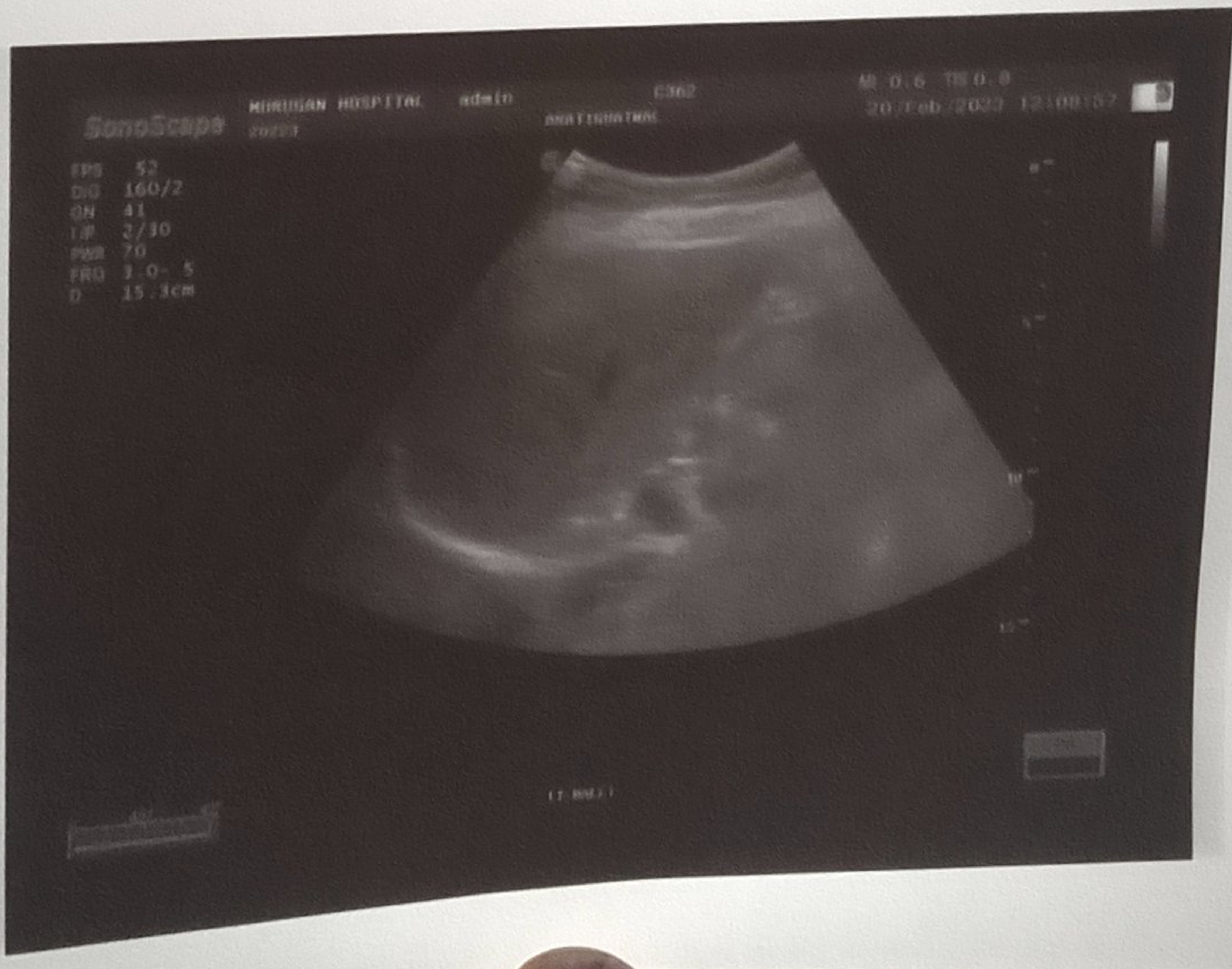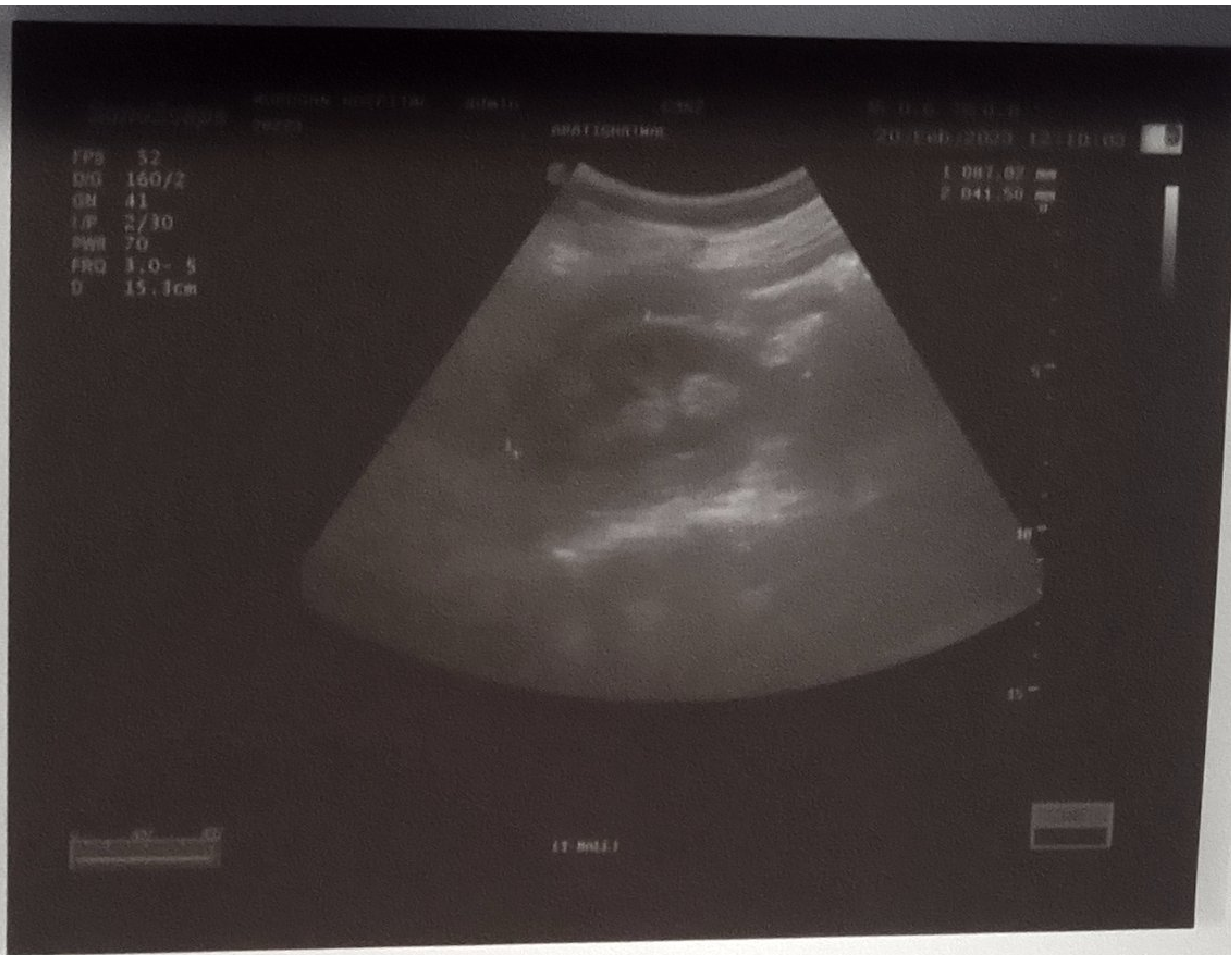***No significant abnormality detected in the visualized abdominal organs.***



**DR.SAKTHI MDRD.,**

**CONSULTANT RADIOLOGIST,**







## ECHO CARDIOGRAM REPORT

NAME : MRS. ARATI GHATWAL

PATIENT ID : MH20230044312

AGE/SEX : 54 Years / FEMALE

IP / OP NO : OP21042316

CONSULTANT : DR. ARUN PRAKASH

DATE : 20/02/2023

### 2D PLAX (mm)

RV - 22 mm

AO - 28 mm

LA - 31 mm

### M-Mode (mm)

IVS - 08 mm

PW - 08 mm

LVD - 44 mm

LVS - 29 mm

EF - 64 %

FS - 35 %

### COLOR DOPPLER

Normal

### DOPPLER (m/sec)

MITRAL E - 0.6 m/s

MITRAL A - 0.8 m/s

PULMONARY - 0.9 m/s

AORTIC - 1.1 m/s

TRICUSPID - 0.4 m/s

### IMPRESSION:

No RWMA

Normal LV Systolic function

Grade I left ventricular diastolic dysfunction

Normal RV function

No pulmonary hypertension

No pericardial effusion

No clot/Vegetation.



DR. SIDHANTIAN MD.DM.,  
CONSULTANT CARDIOLOGIST

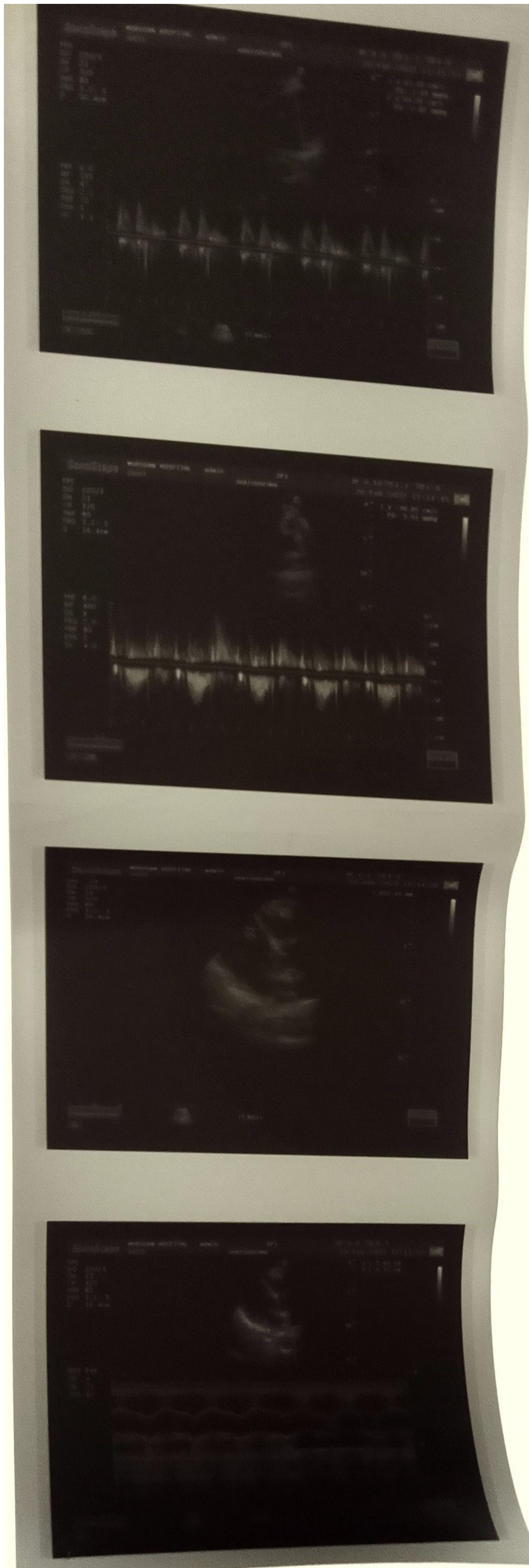
Healing Hearts and Lives

264/125, Kilpauk Garden Road, Kilpauk, Chennai - 600 010.

Phone : +91 44 4644 8989 / 75500 53335 | Email : muruganhosp@gmail.com

Website : www.muruganhospitals.in







# MURUGAN HOSPITALS

HEALING HANDS



## LAB REPORT

NAME : MRS. ARTI GHATWAL  
PIN : AND22380251006  
AGE/GENDER : 54 Year(s)/Female  
REFERRED BY : Dr. ARUN PRAKASH  
CLIENT NAME : MURUGAN HOSPITAL

SAMPLE NO : 3822164682  
COLLECTED ON : 21/02/2023 03:14 PM  
RECEIVED ON : 21/02/2023 03:14 PM  
REPORTED ON : 21/02/2023 04:56 PM  
REPRINT DATE : 21/02/2023 04:56 PM

Test	Obtained Value	Units	Bio.Ref.Intervals
<b>CLINICAL PATHOLOGY</b>			
<b>Stool Routine</b>			
<b>General Examination (Stool)</b>			
Colour	Yellow		Yellow to Brown
Form & Consistency	Semi solid		Semi solid
Mucus	Absent		Absent
Blood	Absent		Absent
<b>Chemical Examination (Stool)</b>			
pH( pH strip test)	Acidic		Variable depending on food
<b>Microscopy (Saline and Iodine mount) (Stool)</b>			
Cyst	Not Present		Absent
Ova	Not Present		Absent
Trophozoites	Not Present		
Red Blood Cells	Not Present	/hpf	Absent
Pus Cells	3 - 4	/hpf	0-5
Epithelial Cells	Not Present	/hpf	0-4
OTHER	Not present		

-- End of Report --

**Healing Hearts and Lives**





# MURUGAN HOSPITALS

HEALING HANDS



## LAB REPORT

Patient Name : Mrs. ARATI GHATWAL  
Age / Gender : 54-Years / Female  
UHID ID : MH20230044312  
Doctor Name : Dr. ARUN PRAKASH

OP Report No. : INVA2109029  
Bill No. : INV2208039  
Sample Date : 20/02/2023 - 09:30PM  
Report Date : 22/02/2023 - 01:13 PM

Test Name	Result	Units	Reference Interval
-----------	--------	-------	--------------------

### CLINICAL PATHOLOGY

URINE SUGAR (PP)

Nil

### ENDOCRINOLOGY

TSH

3.409


uIU/ml

0.39 - 6.16 uiu/ml

NITHYALAB

Verified by

\*\*\* End of Report \*\*\*



Authorized Signature

**Healing Hearts and Lives**

264/125, Kilpauk Garden Road, Kilpauk, Chennai - 600 010.  
Phone : +91 44 4644 8989 / 75500 53335 | Email : muruganhosp@gmail.com  
Website : www.muruganhospitals.in