

DATE :- 25/03/2023

UHID -

HEIGHT - 177cm

WEIGHT:- 80 kg



S/B DR. JAYDEEP BHAMBARE

PATIENT NAME :- Deodhar Sushitra

AGE /SEX:- 30/M

RR - 18/80 mmHg

P - 70/mmHg

SpO2 - 99% on RA

2D-Echo :- Myxomatous MV / Mild MVP & Good LV
function with EF - 60%.

Adv - Cardiologist opinion

Patient's Name : Mr. Soumitra Deodhar
Date : 25/03/2023
Ref. By : Dr. Manoj Chopda (MD DM) **Age/Sex** : 30yrs / Male

BIOCHEMISTRY REPORT

<u>TEST</u>	<u>OBSERVED VALUE</u>	<u>NORMAL RANGE</u>
Blood Sugar (Fasting) :	87.0 mg/dl	60 - 110 mg/dl
Urine Sugar :	Absent	
Urine Ketones :	Absent	
Blood Sugar (PP) :	104.6 mg/dl	110 - 140 mg/dl
Urine Sugar :	Absent	
Urine Ketones :	Absent	
S.Creatinine :	0.85 mg/dl	0.6 - 1.4 mg/dl
Blood Urea Nitrogen :	11.6 mg/dl	7 - 20 mg/dl
S.Uric acid :	4.5 mg/dl	2.5 - 7.2 mg/dl

Pathologist
Dr. Sudhir Sankalecha
MD (Path)
Reg. No. 70405

Check by Technician

Pathologist
Dr. S.A. Sangale
MD (Path)
Reg. No. 2002/07/2718

Patient's Name : Mr. Soumitra Deodhar

Date : 25/03/2023

Ref. By : Dr. Manoj Chopda (MD DM)

Age/Sex : 30yrs / Male

LIPID PROFILE REPORT

<u>TEST</u>	<u>OBSERVED VALUE</u>	<u>NORMAL VALUE</u>
S. Cholesterol	112.5 mg/dl	Up to 200 mg/dl
S. Triglyceride	55.0 mg/dl	Up to 160 mg/dl
HDL Cholesterol	41.7 mg/dl	30 – 65 mg/dl
LDL Cholesterol	59.8 mg/dl	75 – 165 mg/dl
VLDL Cholesterol	11.0 mg/dl	6.0 – 38.0 mg/dl
LDL/HDL Ratio	1.43	2.5 – 4
Chol/HDL Chol Ratio	2.69	3 – 5.5

Pathologist
Dr. Sudhir Sankalecha
MD (Path)
Reg. No. 70405

Check by Technician

Pathologist
Dr. S.A. Sangale
MD (Path)
Reg. No. 2002/07/2718



Patient's Name : Mr. Soumitra Deodhar

Date : 25/03/2023

Ref. By : Dr. Manoj Chopda (MD DM)

Age/Sex : 30yrs / Male

THYROID FUNCTION TEST REPORT

<u>TEST</u>	<u>OBSERVED VALUE</u>	<u>NORMAL RANGE</u>
T3	: 1.42 ng/ml	0.69 - 2.15 ng/ml
T4	: 10.01 ug/dl	5.2 - 12.7 ug/dl
TSH Ultra-Sensitive	: 2.85 uIU/ml	0.4 - 4.5 uIU/ml

METHOD : By Chemiluminescence System

Pathologist
Dr. Sudhir Sankalecha
MD (Path)
Reg. No. 70405

Check by Technician

Pathologist
Dr. S.A. Sangale
MD (Path)
Reg. No. 2002/07/2718

Patient's Name : Mr. Soumitra Deodhar

Date : 25/03/2023

Ref. By : Dr. Manoj Chopda (MD DM)

Age/Sex : 30yrs / Male

BLOOD EXAMINATION REPORT

<u>Test</u>	<u>Result</u>
Blood Group	: ' B '
Rh Factor	: Positive

HAEMATOLOGY

<u>Test</u>	<u>Result</u>	<u>Reference Range</u>
HBA1C	: 4.9 %	
METHOD	: HPLC METHOD	
Estimated Average Glucose (eAG)	: 93.93	mg/dl.

Performed On : Biorad D 10

Reference Range As per ADA

Normal : Below 5.7%

Pre-Diabetes : 5.7% - 6.4%

Diabetes : \geq 6.5%

Guidance For Known Diabetes

Good Control : Below 6.5%

Fair Control : 6.5% - 7.0%

Unsatisfactory Control : 7.0% - 8.0%

Poor Control : $>$ 8.0%

Pathologist

Dr. Sudhir Sankalecha

MD (Path)

Reg. No. 70405

Pathologist

Dr. S.A. Sangale

MD (Path)

Reg. No. 2002/07/2718

Check by Technician



Patient's Name : Mr. Soumitra Deodhar

Date : 25/03/2023

Ref. By : Dr. Manoj Chopda (MD DM)

Age/Sex : 30yrs / Male

URINE EXAMINATION REPORT

PHYSICAL CHARACTERISTICS

Volume : 20 ml
Appearance : Clear
Colour : Pale Yellow
Reaction : Acidic

CHEMICAL EXAMINATION

Albumin : Absent
Bile Salts : Absent
Sugar : Absent
Bile Pigments : Absent
Ketones : Absent

MICROSCOPIC EXAMINATION

Epithelial Cells : 1 - 2/hpf
R.B.C.s : Absent
Pus Cells : 1 - 2/hpf
Casts : Absent
Crystals : Absent
Bacilli : Present
Other : Absent

Pathologist

Dr. Sudhir Sankalecha

MD (Path)

Reg. No. 70405

Check by Technician

Pathologist

Dr. S.A. Sangale

MD (Path)

Reg. No. 2002/07/2718



Patient's Name : Mr. Soumitra Deodhar

Date : 25/03/2023

Ref. By : Dr. Manoj Chopda (MD DM)

Age/Sex : 30yrs / Male

BIOCHEMISTRY REPORT

<u>TEST</u>	<u>OBSERVED VALUE</u>	<u>NORMAL RANGE</u>
<u>LFT</u>		
S.G.O.T.	: 22.9 IU/L	8 - 40 IU/L
S.G.P.T.	: 12.0 IU/L	5 - 50 IU/L
S.Alk PO4	: 82.2 IU/L	40 - 130 IU/L
S.Bilirubin		
Total	: 2.3 mg/dl	0.2 - 1.1 mg/dl
Direct	: 1.0 mg/dl	0.0 - 0.4 mg/dl
Indirect	: 1.3 mg/dl	0.2 - 0.6 mg/dl
S.Proteins		
Total	: 6.2 g/dl	6 - 7.8 g/dl
Albumin	: 4.0 g/dl	3.2 - 4.6 g/dl
Globulin	: 2.2 g/dl	2.3 - 3.5 g/dl
A/G Ratio	: 1.81	
Gamma-GT	: 43.0 IU/L	0 - 45 IU/L

Pathologist

Dr. Sudhir Sankalecha

MD (Path)

Reg. No. 70405

Check by Technician

Pathologist

Dr. S.A. Sangale

MD (Path)

Reg. No. 2002/07/2718

ECHOCARDIOGRAPHY AND COLOUR DOPPLER IMAGING

PATIENT NAME:- SOUMITRA DEODHAR

AGE/SEX- 32 YRS/M

DATE :-25/03/2023

REF:- MEDIWHEEL INSURANCE

Myxomatous Mitral Valve

Mild Mitral Valve Prolapse

Normal LV Size & Function

No regional wall motion abnormality.

Normal LV & RV systolic function. LVEF-60%.

No S/o Diastolic Dysfunction.

Left atrium is normal.

Normal RA and RV size and shape.

Normal RV systolic function.

PASP - 20mmHg

No Pulmonary Hypertension.

IVC Collapsing with respiration. No Clot/Vegetation.

IVS and IAS are intact.

Normal pericardium. No effusion.

**IMPRESSION:- Myxomatous MV / Mild MVP with Good LV Function
with EF- 60%**

DR. RAHUL SHEWALE,
M.D. (Medicine)
D.M. (Cardiology)
Consultant Cardiologist
Regd. No. 2910041390

NAME: MR. SOUMITRA DEVDHAR	DATE: 25/03/2023
AGE/ SEX: 32 YEARS / MALE	REFERRED BY: HEALTH CHECKUP

ULTRASOUND OF ABDOMEN & PELVIS

Findings:

Liver is normal in size, shape & echotexture. No parenchymal focal lesion. No sign of intrahepatic biliary dilatation. Portal vein & common bile duct is normal.

Gall bladder is well distended. The wall is normal. No mass/ calculus. No perichole-cystic collection.

Spleen is normal in size, shape & echotexture. No parenchymal focal lesion. Splenic hilum is normal.

Pancreas are normal in size & echotexture. No parenchymal calcification/ mass / cystic lesion. Pancreatic duct is normal.

Right kidney measures: 10.8 x 4.6 cm.

Left kidney measures: 10.7 x 5.3 cm.

Both kidneys are normal size, shape & echotexture. No cyst / lesion/ calculus.

Cortico-medullary differentiation is normal. No Perinephric collection.

Urinary bladder is well distended. The wall is normal. No intraluminal mass / calculus.

Prostate is normal in size & echotexture. No focal lesion.

No abdominal lymphadenopathy. No ascites. Bowels are normal.

IMPRESSION:

No significant abnormality is seen.

Thank-you.


DR MANOJ CHAUDHARI
CONSULTANT RADIOLOGIST

NAME: MR. SOUNMITRA DEODHAR	DATE: 25/03/2023
AGE/ SEX: 32 YEARS/ MALE	REFERRED BY: HEALTH CHECKUP

XRAY CHEST PA (VIEW)

Findings

- Both the lung fields are equally translucent.
 - The costo-phrenic angles are clear.
 - No hilar or mediastinal mass is seen.
 - Domes of diaphragm are normal in position and contour.
 - The cardiac outlines are normal.
 - No obvious skeletal abnormality is seen.
- Impression**
- *No significant abnormality is seen.*

Thank-you.

Manoj
DR MANOJ CHAUDHARI
CONSULTANT RADIOLOGIST.

ID: 6

SAUMITRA DEVDHAR

Male 33years

Department: ER

25-03-2023 08:54:56 AM

HR : 75 bpm

P : 118 ms

PR : 14 ms

QRS : 98 ms

QT/QTc : 388/434 ms

P/QRS/T : 58/65/44 °

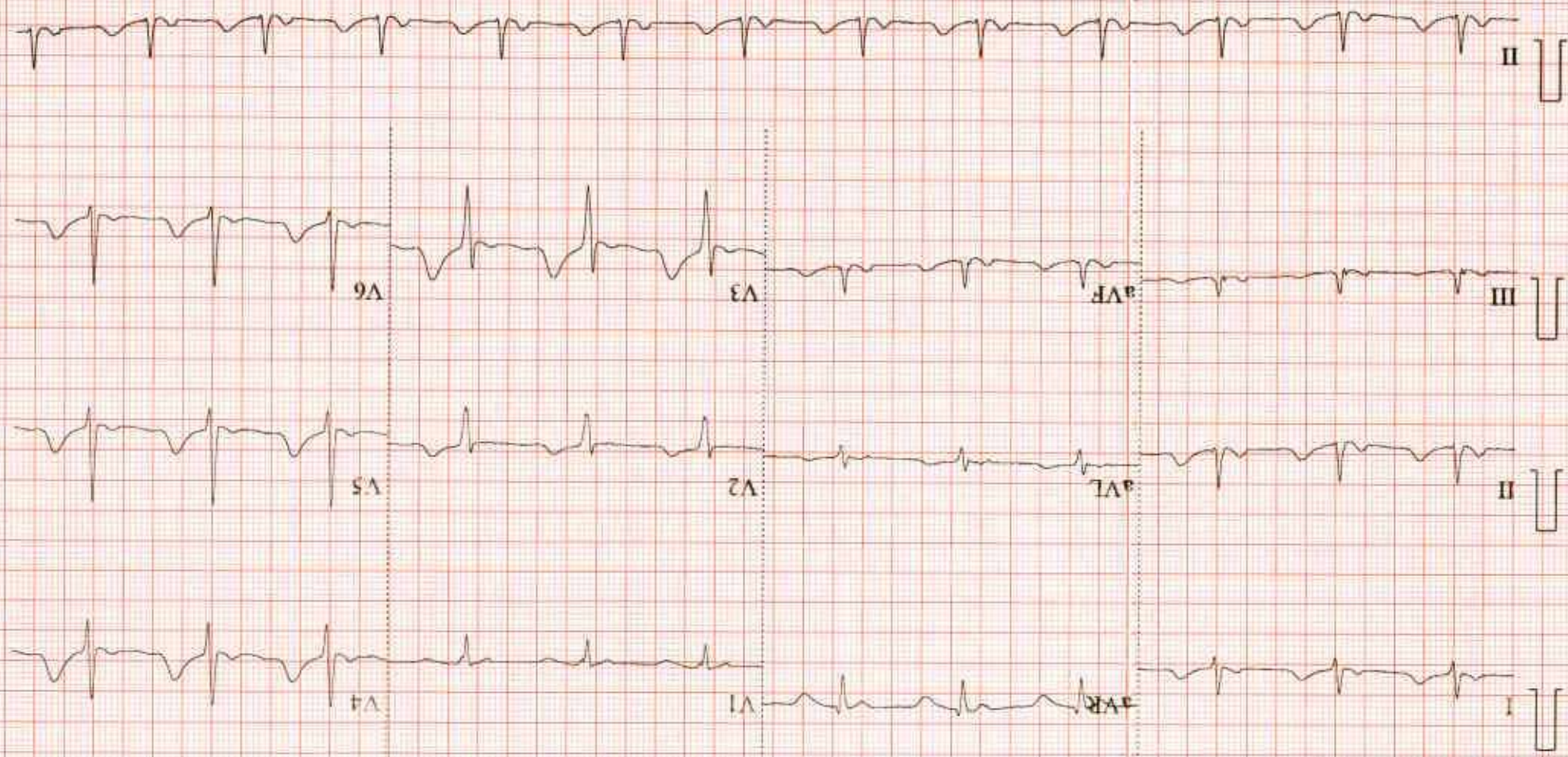
RVS/SVI : 1.223/0.415 mV

Diagnosis Information:

Sinus rhythm

Normal ECG

Report Confirmed by:



0.05~35Hz AC50 25mm/s 10mm/mV 4~2.5s+1r 75 SE-1200Express V2.21 Glasgow V28.60 MAGNUM MULTISPECIALIT