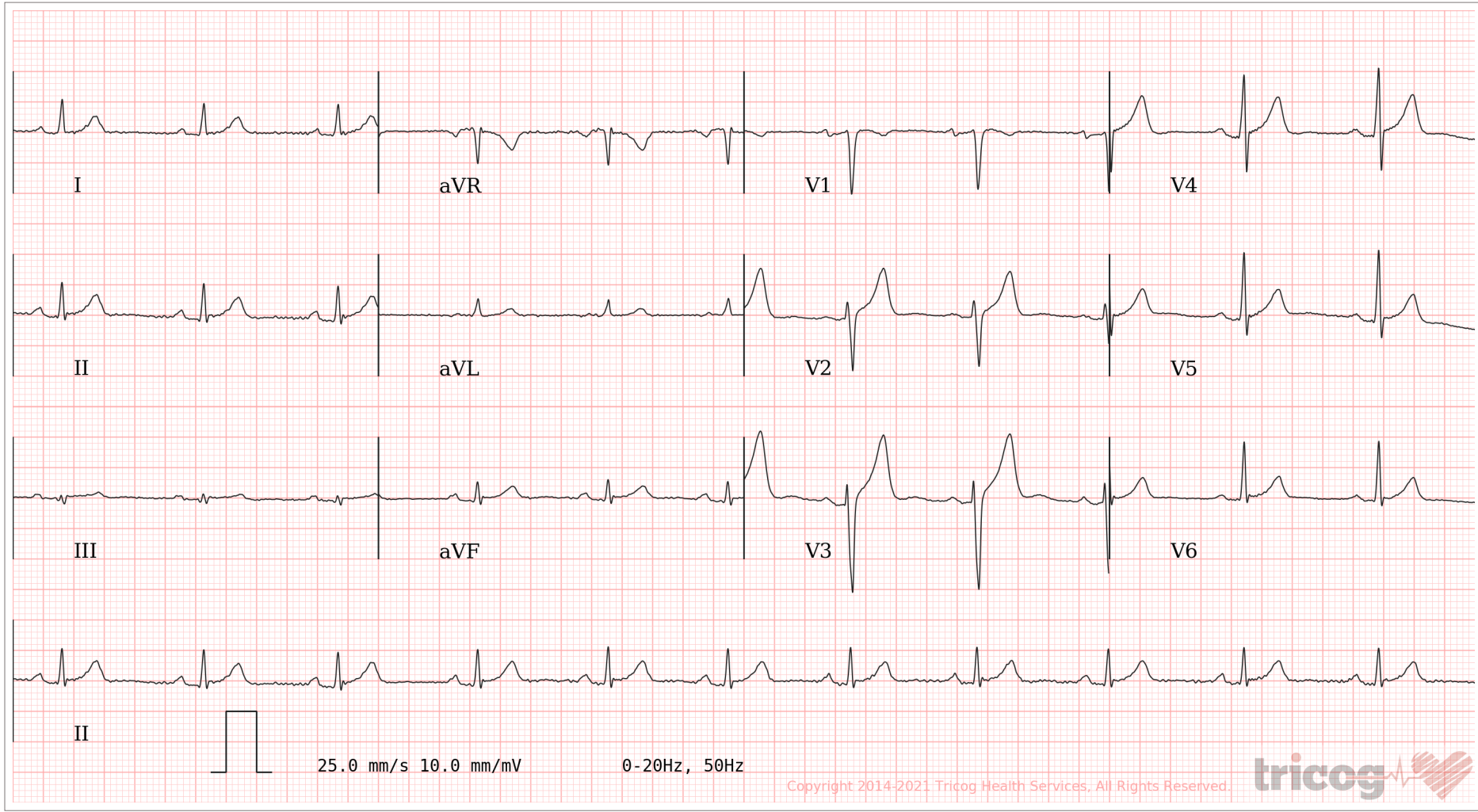




Age / Gender: 38/Male
Patient ID: CHL20210592122
Patient Name: Mr.DEEPAK TAMTA PKG10000238

Date and Time: 13th Nov 21 10:02 AM



AR: 70 bpm VR: 70 bpm QRSD: 78 ms QT: 344 ms QTc: 371 ms PRI: 166 ms P-R-T: 60° 31° 47°

ECG Within Normal Limits: Sinus Rhythm, Normal Axis. Please correlate clinically.

AUTHORIZED BY

Dr. Charit
MD, DM: Cardiology

REPORTED BY

Dr Ponnambalam