

Health Check up Booking Request(bobS24591), Beneficiary Code-56379

1 message

Mediwheel <wellness@mediwheel.in>
To: vidhidiagnostics@gmail.com
Cc: mediwheelwellness@gmail.com

5 January 2023 at 17:57

011-41195959**Email:wellness@mediwheel.in**Dear **VIDHI DIAGNOSTICS,**

City : Ahmedabad . **Address** : L-86 Swatantra - Senani Nagar , Opp- Akhbarnagar Bus Terminals, New Wadaj , Ahmedabad -13,

We have received the confirmation for the following booking .

Name : Toojan shah
Age : 30
Gender : Female
Package Name : Medi-Wheel Metro Full Body Health Checkup Male Below 40
User Location : Detroj, DETROJ, Gujarat, 382120
Contact Details : 9712983108
Booking Date : 05-01-2023
Appointment Date : 28-01-2023

Member Information			
Booked Member Name	Age	Gender	Cost(In INR)
Toojan shah	31	Male	Cashless
Total amount to be paid			Cashless

We will get back to you with confirmation update shortly. Please find the package details as attached for your reference.

Package Name : Medi-Wheel Metro Full Body Health Checkup Male Below 40 - Includes (37) Tests

Tests included in this Package : Ecg, TSH, X-ray Chest, Stress Test (tmt)/ 2d Echo, Blood Sugar Postprandial, A:g Ratio, Blood Group, Total Cholesterol, Triglycerides, Fasting Blood Sugar, Ultrasound Whole Abdomen , Glycosylated Haemoglobin (hba1c), Hdl, Vldl, Urine Analysis, LDL, Total Protine, General Consultation, HDL/ LDL ratio, GGT(Gamma-glutamyl Transferase), Eye Check-up consultation, ALP (ALKALINE PHOSPHATASE), Uric Acid, AST/ALT Ratio, Serum Protein, CBC with ESR, Stool Analysis, Urine Sugar Fasting, Urine Sugar PP, T3, T4, Cholesterol Total / HDL Ratio, BUN, BUN/Creatinine Ratio, Bilirubin Total & Direct and Indirect, Albumin, Globulin



To,

The Coordinator,
Mediwheel (Arcofemi Healthcare Limited)
Helpline number: 011- 41195959

Dear Sir / Madam,

Sub: Annual Health Checkup for the employees of Bank of Baroda

This is to inform you that the following spouse of our employee wishes to avail the facility of Cashless Annual Health Checkup provided by you in terms of our agreement.

PARTICULARS OF HEALTH CHECK UP BENEFICIARY	
NAME	POOJAN DEVENDRASHAH
DATE OF BIRTH	26-04-1991
PROPOSED DATE OF HEALTH CHECKUP FOR EMPLOYEE SPOUSE	24-12-2022
BOOKING REFERENCE NO.	22D88960100030230S
SPOUSE DETAILS	
EMPLOYEE NAME	MS. DAVE YETIKA HITESH
EMPLOYEE EC NO.	88960
EMPLOYEE DESIGNATION	FOREX BACK OFFICE
EMPLOYEE PLACE OF WORK	GANDHINAGAR,GIFT CITY,NATIONAL
EMPLOYEE BIRTHDATE.	02-08-1990

This letter of approval / recommendation is valid if submitted along with copy of the Bank of Baroda employee id card. This approval is valid from **14-11-2022** till **31-03-2023**.The list of medical tests to be conducted is provided in the annexure to this letter. Please note that the said health checkup is a **cashless facility** as per our tie up arrangement. We request you to attend to the health checkup requirement of our employee's spouse and accord your top priority and best resources in this regard. The EC Number and the booking reference number as given in the above table shall be mentioned in the invoice, invariably.

We solicit your co-operation in this regard.

Yours faithfully,

Sd/-

Chief General Manager
HRM Department
Bank of Baroda

(Note: This is a computer generated letter. No Signature required. For any clarification, please contact Mediwheel (Arcofemi Healthcare Limited))

ID: 8122

Name: pojan shah

Age: 31yrs

Sex: Male

Hospital:

Department:

Dr. Avinash Bhaskar
MS (CC) & Cardio
Reg. No.: G-45940

HR :	74 bpm
PR :	170 ms
QRS :	100 ms
QT/QTc :	382/424 ms
P/QRS/T :	38/46/62 deg.
RV5/SV1 :	1.003/-0.971 mv
RV5+SV1 :	1.974 mv

<< Analysis Result >>

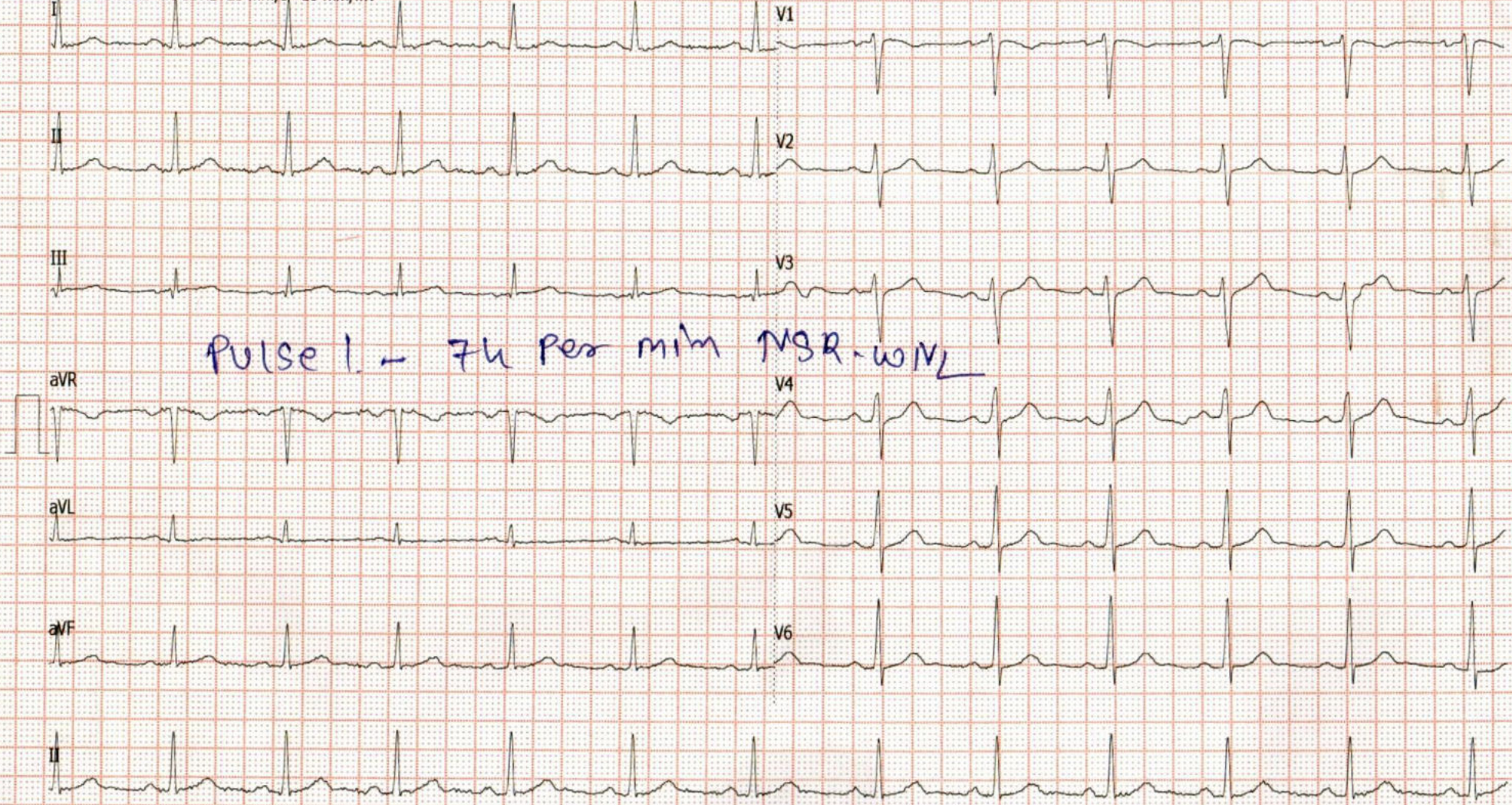
** normal ECG **

Sinus rhythm

Vidhi Diagnostics
L-86, Swatantra-Senani Nagar,
Opp. Akhbarnagar Bus Terminals,
Nr. Akhbarnagar Circle,
New Wadaj, Ahmedabad-13.

Need to be confirmed by doctor. Doctor Name: _____

0.67Hz - 35Hz AC 50Hz 25 mm/s 10 mm/mv



Dr. Dinesh S. Modh

M.D., D.M.R.E. (Radiodiagnosis)

Consultant Radiologist & Sonologist

Ex. Junior Lecturer, B.J. Medical College, Civil Hospital, A'bad.



Patient's name: POOJAN D SHAH
Reg. ID : R-13625-23
Referred by : Dr. MEDIWHEEL

Age/Sex : 31 Years/Male
Accession : 527
Date : 25/02/2023

X-RAY CHEST (PA VIEW)

Prominence broncho-vascular markings are noted in both lung fields.

No e/o consolidation or cavitations is seen.

Both costo-phrenic angles appear clear.

Cardiac size is within normal limits.

Both domes of diaphragm appear normal.

Bony thoracic cage appear normal.

Thanks for reference.

Dr. Dinesh S. Modh
MD DMRE (Radiodiagnosis)

DR DINESH S. MODH

M.D. DMRE(RADIODIAGNOSIS)

ISO 9001:2015 Certified Diagnostics Center

Vidhi Imaging Center

L-86, Swatantra Senani Nagar, Opp. Indian Oil Petrol Pump, Akhbarnagar Circle, Nava Vadaj, Ahmedabad - 380 013.

Phone : (Radiology) 079-2762 1406 | M. 98799 29406, 98250 09406 | Time (Radiology) : Mon. to Sat. 9 am to 2 pm, 5 to 9 pm, Sunday 9 am to 12 Noon

E-mail : vidhidiagnostics@gmail.com, Website : www.vidhidiagnostics.com

Multislice CT Scan | CBCT-Dental Scan | Live 3D-4D Sonography | Colour Doppler | Echo Cardiography | Interventional Radiology | Maxillofacial Radiology | Fetal Medicine
Digital X-Ray | Digital Mammography | Digital OPG/TMJ | ECG/TMT/PFT/EEG/EMG | Audiometry | Pathology Laboratory | Health Check Up Plans | Pre Employment Check Up

CT SCAN & CBCT FACILITY NOW AVAILABLE

Dr. Dinesh S. Modh

M.D., D.M.R.E. (Radiodiagnosis)
Consultant Radiologist & Sonologist
Ex. Junior Lecturer, B.J. Medical College, Civil Hospital, A'bad.



Patient's name : POOJAN D SHAH
Reg. ID : R-13625-23
Referred by : Dr. MEDIWHEEL

Age/Sex : 31 Years/Male
Accession : 527
Date : 25/02/2023

2D- ECHO REPORT

FINAL CONCLUSION:

LV IS NORMAL SIZE. GOOD LV SYSTOLIC FUNCTION NO RWMA.
LVEF - 60%. NO CONCENTRIC LVH.
NORMAL LV COMPLANCE.
LA IS NORMAL SIZE. NO LA CLOT.
RV IS NORMAL SIZE. GOOD RV SYSTOLIC FUNCTION.
RA IS NORMAL SIZE.
MITRAL VALVE IS NORMAL. NO MS. MILD MR (15%). NO MVP.
AORTIC VALVE IS NORMAL. NO AS. NO AR.
TRICUSPID VALVE IS NORMAL. NO TR. RVSP-26 mmHg. NO PAH.

NO CLOT, NO VEGETATION, NO PERICARDIAL EFFUSION.

DIMENSIONS:

AORTA	2.6 C.M
LEFT ATRIUM	2.7 C.M
LVDD	4.1 C.M.
IVSD	1.0 C.M
PWD	1.0 C.M
LVDS	2.6 C.M.

COLOUR DOPPLER FINDING:

STRUCTURE	VELOCITY m/sec
	Max
PULMONARY VALVE	0.7
MITRAL VALVE	E : 0.7 A: 0.4
AORTIC VALVE	1.0

Dr. Avinash Bhaskar
MBBS, D Cardio
Reg. No.: G-45946
DR AVINASH BHASKAR

ISO 9001:2015 Certified Diagnostics Center

Vidhi Imaging Center

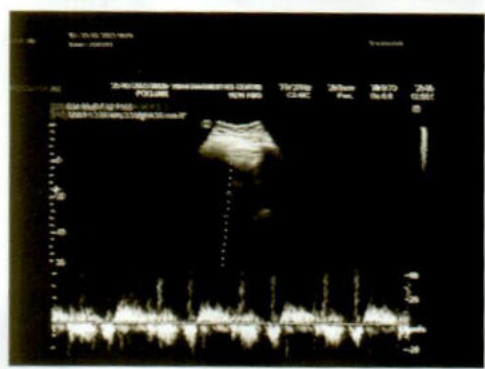
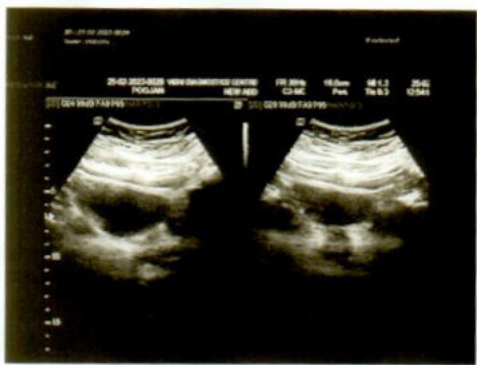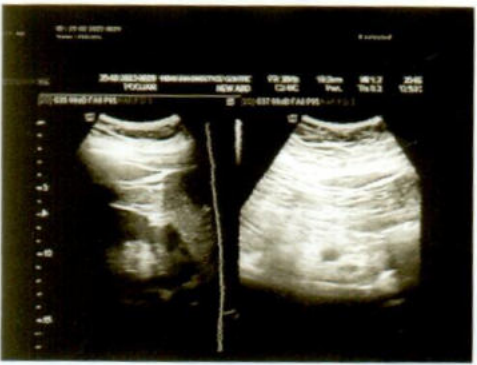
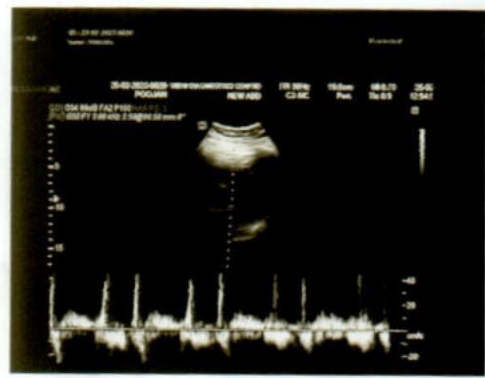
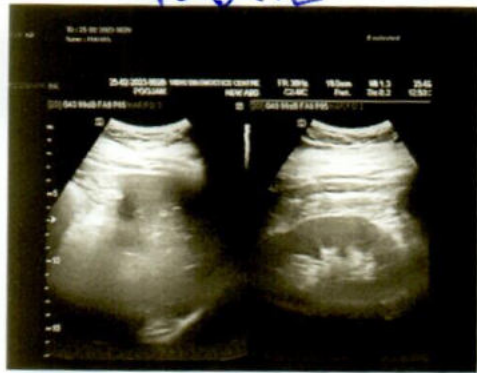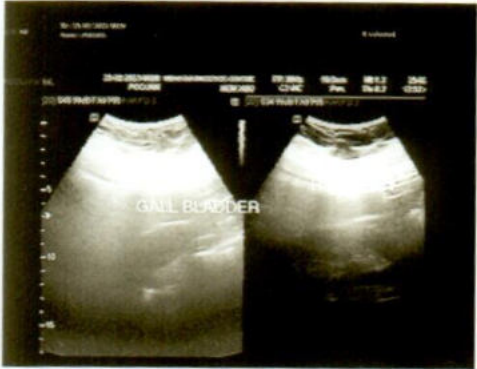
L-86, Swatantra Senani Nagar, Opp. Indian Oil Petrol Pump, Akhbar Nagar Circle, Nava Vadaj, Ahmedabad - 380 013.

Phone : (Radiology) 079-2762 1406 | M. 98799 29406, 98250 09406 | Time (Radiology) : Mon. to Sat. 9 am to 2 pm, 5 to 9 pm, Sunday 9 am to 12 Noon
E-mail : vidhidiagnostics@gmail.com, Website : www.vidhidiagnostics.com

Multislice CT Scan | CBCT-Dental Scan | Live 3D-4D Sonography | Colour Doppler | Echo Cardiography | Interventional Radiology | Maxillofacial Radiology | Fetal Medicine
Digital X-Ray | Digital Mammography | Digital OPG/TMJ | ECG/TMT/PFT/EEG/EMG | Audiometry | Pathology Laboratory | Health Check Up Plans | Pre Employment Check Up

CT SCAN & CBCT FACILITY NOW AVAILABLE

Poojan



Dr. Dinesh S. Modh

M.D., D.M.R.E. (Radiodiagnosis)
Consultant Radiologist & Sonologist
Ex. Junior Lecturer, B.J. Medical College, Civil Hospital, A'bad.



Patient's name : POOJAN D SHAH
Reg. ID : R-13625-23
Referred by : Dr. MEDIWHEEL

Age/Sex : 31 Years/Male
Accession : 527
Date : 25/02/2023

USG ABDOMEN

LIVER: Liver is normal in size and bright in echotexture s/o fatty liver grade2. Intrahepatic biliary radicals appear normal.

Portal vein is normal in caliber. Common Bile duct is normal in course & caliber. No e/o calculus is seen in biliary tree.

GALL BLADDER: is distended & appear normal. No e/o calculus or cholecystitis is seen. GB wall thickness appears normal. No evidence of pericholecystic fluid is seen.

SPLEEN: Spleen is normal in size & shows normal echo texture. No evidence of diffuse or focal lesion is seen. Splenic vein appears normal.

PANCREAS: Pancreas appears normal in size & echotexture. No evidence of diffuse or focal lesion is seen. Main pancreatic duct is normal.

KIDNEY: Both kidneys appear normal in size and echopattern. Corticomedullary differentiation is maintained.

No evidence of calculus or hydronephrosis is seen on both sides.
Both supra renal region appear normal.

No evidence of pre & para aortic lymphadenopathy is seen.

Gas filled non-dilated bowel loops are seen in abdomen.

No evidence of free fluid is seen in abdomen.

No evidence of dilated or thickened bowel loops is seen.

Urinary bladder appears normal. No e/o calculus or mass lesion is seen.

Prostate appears normal in size & echopattern.

Thanks for reference.

Dr. Dinesh S. Modh
MD DMRE (Radiodiagnosis)
DR DINESH S. MODH
G-23825
M.D. DMRE(RADIODIAGNOSIS)

ISO 9001:2015 Certified Diagnostics Center

Vidhi Imaging Center

L-86, Swatantra Senani Nagar, Opp. Indian Oil Petrol Pump, Akhbaragar Circle, Nava Vadaj, Ahmedabad - 380 013.

Phone : (Radiology) 079-2762 1406 | M. 98799 29406, 98250 09406 | Time (Radiology) : Mon. to Sat. 9 am to 2 pm, 5 to 9 pm, Sunday 9 am to 12 Noon

E-mail : vidhidiagnostics@gmail.com, Website : www.vidhidiagnostics.com

Multislice CT Scan | CBCT-Dental Scan | Live 3D-4D Sonography | Colour Doppler | Echo Cardiography | Interventional Radiology | Maxillofacial Radiology | Fetal Medicine
Digital X-Ray | Digital Mammography | Digital OPG/TMJ | ECG/TMT/PFT/EEG/EMG | Audiometry | Pathology Laboratory | Health Check Up Plans | Pre Employment Check Up

CT SCAN & CBCT FACILITY NOW AVAILABLE

Medical Examination Report

Date : 25/02/2023

1. Personal Particulars

Name : Poojam Devendrahebhai Shah
Age : 31 years Gender : Male / Female
Marital Status : Married

Past & Present Medical History :

} No

2. Clinical Medical Examination

Height : 179 cm Weight : 77.2 kg
Blood Pressure : 130/90 mmHg Pulse : 74 p/min

General Condition : } Normal Skin : } Normal
Central Nervous System : } Normal Head & Neck : } Normal
Cardiovascular System : } Normal Chest : } Normal
Abdomen : } Normal Limbs : } Normal
Last menstrual period : NA

Vision: : Right: 6/6 with specs Left: 6/6 with specs
N/G with normal N/G with normal
Colour vision : Normal/Colour Blind

Personal Habit : Habit of smoking & Drinking
Alcohol

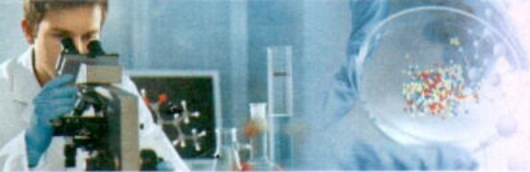Remarks : Fit / Unfit for employment

Dr. Vidhi D. Modh
MBBS

Reg No. 74540

Dr's name, signature & chop

Vidhi Diagnostics
L-86, Swatantra-Senani Nagar,
Opp. Akharnagar Bus Terminal,
Nr. Akharnagar Circle,
New Wadaj, Ahmedabad-13.



Pathology Department

VIDHI
DIAGNOSTICS



Patient's name : POOJAN SHAH
Age/Sex : 32 Years/Male
Referred by : Dr. MEDIWHEEL
Collection Time : 10:29

Reg. ID : P-7612-23
Accession : 485
Order Dt/time : 25/02/2023 10:29

Complete Blood Count

Sample Type: EDTA

Test Name	Result	Units	Biological Reference Interval
<u>Blood Counts</u>			
Haemoglobin :	13.3	Gms%	13.5 - 18.0
Total R.B.C. :	4.68	mill/c.mm	4.7 - 6.0
Total W. B. C. :	8,260	/cu mm	4000 - 10500
Platelet Count :	2,88,000	/cu.mm	1,50,000 - 4,50,000
<u>Differential Count</u>			
Neutrophils :	60	%	40 - 70
Lymphocytes :	36	%	20 - 40
Eosinophils :	02	%	1 - 4
Monocytes :	02	%	2 - 6
Basophils :	00	%	0 - 01
<u>Blood Indices</u>			
P. C. V :	41.1	%	42 - 52
M. C. V. :	87.8	fl	78 - 100
M.C.H :	28.5	pg	27 - 31
M. C. H. C :	32.5	%	32 - 36
R.D.W :	14.2	%	11.5 - 14.0
<u>E.S.R.(Westergren Method)</u>			
After one hour :	04	mm/hr	1 - 7

TESTS DONE ON FULLY AUTOMATED HEMATOLOGY ANALYZER.

Dr. Gayatri M. Mehta

M. D. (Patho)

Reg. No. G-32215

DR GAYATRI MEHTA
MD(PATHOLOGY)

DR. ANAND D. PARIKH
MD(PATHOLOGY)

LAB USE ONLY (Entered by :GM Enter Date/Time:25/02/2023 1:28:00 PM) (Verify by :GM Verify Date/Time:25/02/2023 1:28:00 PM)

ISO 9001:2015 Certified Diagnostics Center

Vidhi Imaging Center | Pathology Department

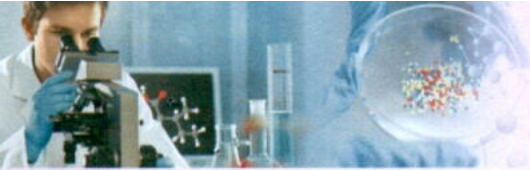L-86, Swatantra Senani Nagar, Opp. Akhbarnagar Petrol Pump, Nr. Akhbarnagar Circle, Nava-Vadaj, Ahmedabad - 380 013.

Ph. (Pathology) : 079-2762 1406, 8849893954 M. 98799 29406, 98250 09406, E-mail : vidhidiagnostics@gmail.com, Web. : www.vidhidiagnostics.com

Time (Pathology) : Mon. to Sat. 8.30 am to 8.00 pm, Sunday 9 am to 12 Noon

Pathology means science behind medicine

CT SCAN & CBCT FACILITY NOW AVAILABLE



Pathology Department

Patient's name : POOJAN SHAH
Age/Sex : 32 Years/Male
Referred by : Dr. MEDIWHEEL
Collection Time : 10:29

Reg. ID : P-7612-23
Accession : 485
Order Dt/time : 25/02/2023 10:29

Blood Group

Sample Type: EDTA sample.

Test Name	Result
BG :	" B "
RH :	POSITIVE
Remarks	Done by forward grouping method.

Blood Glucose

Sample Type: Serum

Test Name	Result	Units	Biological Reference Interval
Fasting Blood Glucose :	110.0	mg/dl	70 - 110
<i>GOD-POD Method.</i>			

Blood Glucose

Sample Type: Serum

Test Name	Result	Units	Biological Reference Interval
Post Prandial Blood Glucose After 2hr. :	116.0	mg/dl	80 - 140
<i>GOD-POD Method.</i>			

Dr. Gayatri M. Mehta

M. D. (Patho)

Reg. No. G-33215
DR GAYATRI MEHTA
MD(PATHOLOGY)

DR. ANAND D. PARIKH
MD(PATHOLOGY)

LAB USE ONLY (Entered by :GM Enter Date/Time:25/02/2023 4:43:00 PM) (Verify by :GM Verify Date/Time:25/02/2023 4:43:00 PM)

ISO 9001:2015 Certified Diagnostics Center

Vidhi Imaging Center | Pathology Department

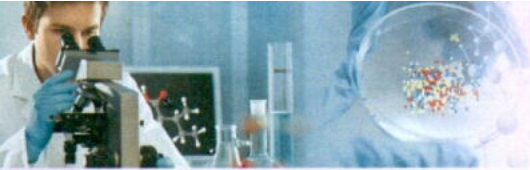L-86, Swatantra Senani Nagar, Opp. Akhbarnagar Petrol Pump, Nr. Akhbarnagar Circle, Nava-Vadaj, Ahmedabad - 380 013.

Ph. (Pathology) : 079-2762 1406, 8849893954 M. 98799 29406, 98250 09406, E-mail : vidhidiagnostics@gmail.com, Web. : www.vidhidiagnostics.com

Time (Pathology) : Mon. to Sat. 8.30 am to 8.00 pm, Sunday 9 am to 12 Noon

Pathology means science behind medicine

CT SCAN & CBCT FACILITY NOW AVAILABLE



Pathology Department

VIDHI
DIAGNOSTICS



Patient's name : POOJAN SHAH
Age/Sex : 32 Years/Male
Referred by : Dr. MEDIWHEEL
Collection Time : 10:29

Reg. ID : P-7612-23
Accession : 485
Order Dt/time : 25/02/2023 10:29

Lipid Profile

Sample Type: Serum

Test Name	Result	Units	Biological Reference Interval
S. Cholesterol : Oxidase-esterase method.	167.0	mg/dl	0 - 200
S. Triglyceride : Enzymatic Colorimetry method	137.2	mg/dL	0 - 200
S. HDL - Cholesterol : Serum by Enzymatic method.	39.1	mg/dL	35 - 65
S. LDL - Cholesterol : Serum by Enzymatic method	100.46	mg/dL	0 - 130
S. VLDL - Cholesterol :	27.44	mg/dL	0 - 30
S. Chole/HDL.Ratio :	4.27		1 - 6
S. LDL / HDL Cholesterol Ratio :	2.57		0 - 3.5

Dr. Gayatri M. Mehta

M. D. (Patho)

Reg. No. G-32215

DR GAYATRI MEHTA
MD(PATHOLOGY)

DR. ANAND D. PARIKH
MD(PATHOLOGY)

LAB USE ONLY (Entered by :GM Enter Date/Time:25/02/2023 4:43:00 PM) (Verify by :GM Verify Date/Time:25/02/2023 4:43:00 PM)

ISO 9001:2015 Certified Diagnostics Center

Vidhi Imaging Center | Pathology Department

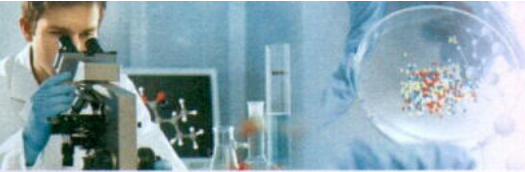L-86, Swatantra Senani Nagar, Opp. Akhbarnagar Petrol Pump, Nr. Akhbarnagar Circle, Nava-Vadaj, Ahmedabad - 380 013.

Ph. (Pathology) : 079-2762 1406, 8849893954 M. 98799 29406, 98250 09406, E-mail : vidhidiagnostics@gmail.com, Web. : www.vidhidiagnostics.com

Time (Pathology) : Mon. to Sat. 8.30 am to 8.00 pm, Sunday 9 am to 12 Noon

Pathology means science behind medicine

CT SCAN & CBCT FACILITY NOW AVAILABLE



Patient's name : POOJAN SHAH
 Age/Sex : 32 Years/Male
 Referred by : Dr. MEDIWHEEL
 Collection Time : 10:29

Reg. ID : P-7612-23
 Accession : 485
 Order Dt/time : 25/02/2023 10:29

HbA1C

Sample Type: Serum

Test Name	Result	Units	Biological Reference Interval
HbA1C :	5.7	%	Non-diabetic: 4.2-6.2 Pre-diabetic : 6.3-7.2 Diabetic : 7.3-8.2
Mean Blood Glucose of Last 03 months.	116.89	mg/dl	

Comment *As per the new 2009 update of American Diabetes Association regarding HbA1C & Mean Blood Glucose relationship.
NOTE: This test is used to monitor diabetic patients compliance with the therapeutic regimen and logo It's level is proportional to both the average blood glucose concentration and the life span of the red blood cells (RBC) in circulation. HbA1c values are free of day to day glucose fluctuations and are unaffected by exercise or recent food intake.

Dr. Gayatri M. Mehta
 M. D. (Patho)
 Reg. No. G-32215

DR GAYATRI MEHTA
MD(PATHOLOGY)

DR. ANAND D. PARIKH
MD(PATHOLOGY)

LAB USE ONLY (Entered by :GM Enter Date/Time:25/02/2023 4:43:00 PM) (Verify by :GM Verify Date/Time:25/02/2023 4:43:00 PM)

ISO 9001:2015 Certified Diagnostics Center

Vidhi Imaging Center | Pathology Department

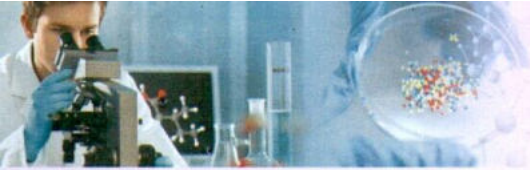L-86, Swatantra Senani Nagar, Opp. Akhbarnagar Petrol Pump, Nr. Akhbarnagar Circle, Nava-Vadaj, Ahmedabad - 380 013.

Ph. (Pathology) : 079-2762 1406, 8849893954 M. 98799 29406, 98250 09406, E-mail : vidhidiagnostics@gmail.com, Web. : www.vidhidiagnostics.com

Time (Pathology) : Mon. to Sat. 8.30 am to 8.00 pm, Sunday 9 am to 12 Noon

Pathology means science behind medicine

CT SCAN & CBCT FACILITY NOW AVAILABLE



Pathology Department

VIDHI
DIAGNOSTICS



Patient's name : POOJAN SHAH
Age/Sex : 32 Years/Male
Referred by : Dr. MEDIWHEEL
Collection Time : 10:29

Reg. ID : P-7612-23
Accession : 485
Order Dt/time : 25/02/2023 10:29

BIOCHEMISTRY

Sample type :Serum

Test Name	Result	Units	Biological Reference Interval
Urea , (Serum by GLDH method) :	17.1	mg/dl	10 - 50
S.Uric acid , (Serum by Uricase method) :	5.0	mg/dl	3.4 - 7.0
Bun :	8	mg/dl	6-20
Creatinine , (Serum by Enzymatic reaction) :	0.80	mg/dl	0.5-1.2
S.G.P.T (ALT) : (Serum by IFCC method)	34.4	U/L	0 - 40
S.G.O.T (AST) : (Serum by IFCC method)	22.9	U/L	0 - 37
ALK.PHOSPHATASE : (Serum by PNP method)	105.0	U/L	40-129
G.G.T :	16.8	U/L	8 - 78
<u>BILIRUBIN</u>			
Total :	0.28	mg/dl	Up to 1.2
Direct :	0.17	mg/dl	0-0.7
Indirect :	0.11	mg/dl	0 - 0.5
<u>SERUM PROTEINS</u>			
Total Protein (Serum by Biuret method) :	7.00	gms/dl	6.4 - 8.5
Albumin (Serum by BCG method) :	4.06	gms/dl	3.97-4.94
Globulins :	2.94	gms/dl	2.3 - 3.5
A/G Ratio :	1.381		0.9 - 2.9

Dr. Gayatri M. Mehta

M. D. (Patho)

Reg. No. G-32215

DR GAYATRI MEHTA
MD(PATHOLOGY)

DR.ANAND D.PARIKH
MD(PATHOLOGY)

LAB USE ONLY (Entered by :GM Enter Date/Time:25/02/2023 4:42:00 PM) (Verify by :GM Verify Date/Time:25/02/2023 4:42:00 PM)

ISO 9001:2015 Certified Diagnostics Center

Vidhi Imaging Center | Pathology Department

L-86, Swatantra Senani Nagar, Opp. Akhbarnagar Petrol Pump, Nr. Akhbarnagar Circle, Nava-Vadaj, Ahmedabad - 380 013.

Ph. (Pathology) : 079-2762 1406, 8849893954 M. 98799 29406, 98250 09406, E-mail : vidhidiagnostics@gmail.com, Web. : www.vidhidiagnostics.com

Time (Pathology) : Mon. to Sat. 8.30 am to 8.00 pm, Sunday 9 am to 12 Noon

Pathology means science behind medicine

CT SCAN & CBCT FACILITY NOW AVAILABLE



Pathology Department

VIDHI
DIAGNOSTICS



Patient's name : POOJAN SHAH
Age/Sex : 32 Years/Male
Referred by : Dr. MEDIWHEEL
Collection Time : 10:29

Reg. ID : P-7612-23
Accession : 485
Order Dt/time : 25/02/2023 10:29

Thyroid Function Test

Sample Type: Serum

Test Name	Result	Units	Biological Reference Interval
TOTAL T3 :	1.48	ng/ml	0.84 - 2.0
TOTAL T4 :	6.95	ug/dl	5.1 - 14.0
TSH(Ultra sensitive) :	1.909	mIU/L	0.27 - 4.2

Dr. Gayatri M. Mehta

M. D. (Patho)

Reg. No. G-32215

DR GAYATRI MEHTA
MD(PATHOLOGY)

DR. ANAND D. PARIKH
MD(PATHOLOGY)

LAB USE ONLY (Entered by :GM Enter Date/Time:25/02/2023 4:43:00 PM) (Verify by :GM Verify Date/Time:25/02/2023 4:43:00 PM)

ISO 9001:2015 Certified Diagnostics Center

Vidhi Imaging Center | Pathology Department

L-86, Swatantra Senani Nagar, Opp. Akhbar Nagar Petrol Pump, Nr. Akhbar Nagar Circle, Nava-Vadaj, Ahmedabad - 380 013.

Ph. (Pathology) : 079-2762 1406, 8849893954 M. 98799 29406, 98250 09406, E-mail : vidhidiagnostics@gmail.com, Web. : www.vidhidiagnostics.com

Time (Pathology) : Mon. to Sat. 8.30 am to 8.00 pm, Sunday 9 am to 12 Noon

Pathology means science behind medicine

CT SCAN & CBCT FACILITY NOW AVAILABLE



Pathology Department

VIDHI
DIAGNOSTICS



Patient's name : POOJAN SHAH
Age/Sex : 32 Years/Male
Referred by : Dr. MEDIWHEEL
Collection Time : 10:29

Reg. ID : P-7612-23
Accession : 485
Order Dt/time : 25/02/2023 10:29

Urine Analysis

Sample Type: Urine

Test Name	Result	Units	Biological Reference Interval
-----------	--------	-------	-------------------------------

Physical Examination

Quantity :	30	ml	0 - 500 ml
Colour :	Pale Yellow		Pale Yellow
Transparency :	Clear.		Clear
Reaction :	Acidic		4.6 - 8.0
Specific Gravity :	1.030		1.016 - 1.022
Sediment :	Present		

Chemical Examination

Albumin :	Present (Faint Trace)		Absent
Sugar :	NIL		Absent
Acetone :	Absent		Absent
Bile Salts :	Absent		Absent
Bile Pigments :	Absent		Absent
Urobilogen :	Absent		Absent
Nitrites :	Absent		Absent

Microscopic Examination

Red blood Cells :	Occasional	/h.p.f	Absent
Pus Cells :	2-3	/h.p.f	Absent
Epithelial Cells :	1-2	/h.p.f	< 10.0
Amorphous :	Absent	/h.p.f	Absent
Bacteria :	Absent	/h.p.f	Absent
Crystals :	Absent	/h.p.f	Absent
Casts :	Absent	/h.p.f	Absent
Fungus :	Not seen	/h.p.f	Absent

Dr. Gayatri M. Mehta

M. D. (Patho)

Reg. No. G-32215

DR GAYATRI MEHTA
MD(PATHOLOGY)

DR. ANAND D. PARIKH
MD(PATHOLOGY)

ISO 9001:2015 Certified Diagnostics Center

LAB USE ONLY (Entered by : GM Enter Date/Time: 25/02/2023 4:43:00 PM Verify by : GM Verify Date/Time: 25/02/2023 4:43:00 PM)

L-86, Swatantra Senani Nagar, Opp. Akhbar Nagar Petrol Pump, Nr. Akhbar Nagar Circle, Nava-Vadaj, Ahmedabad - 380 013.

Ph. (Pathology) : 079-2762 1406, 8849893954 M. 98799 29406, 98250 09406, E-mail : vidhidiagnostics@gmail.com, Web. : www.vidhidiagnostics.com

Time (Pathology) : Mon. to Sat. 8.30 am to 8.00 pm, Sunday 9 am to 12 Noon

Pathology means science behind medicine

CT SCAN & CBCT FACILITY NOW AVAILABLE

भारत सरकार

शह पूजन देवेंद्रभाई
Shah Poojan Devendrabhai
जन्म तिथि/ DOB: 26/04/1991
पुरुष / MALE

5241 1754 2485

भारो आधार, भारी ओणभ



x
Lujan

Dr. Vidhi D. Modh
MBBS
Reg. No. G-74548



 **GPS Map Camera**


Ahmedabad, Gujarat, India

3H96+6PR, Chandlodiya Rd,
Swatantra Senani Nagar, Nava Vadaj,
Ahmedabad, Gujarat 380013, India

Lat 23.068134°

Long 72.56178°

25/02/23 12:34 PM GMT +05:30



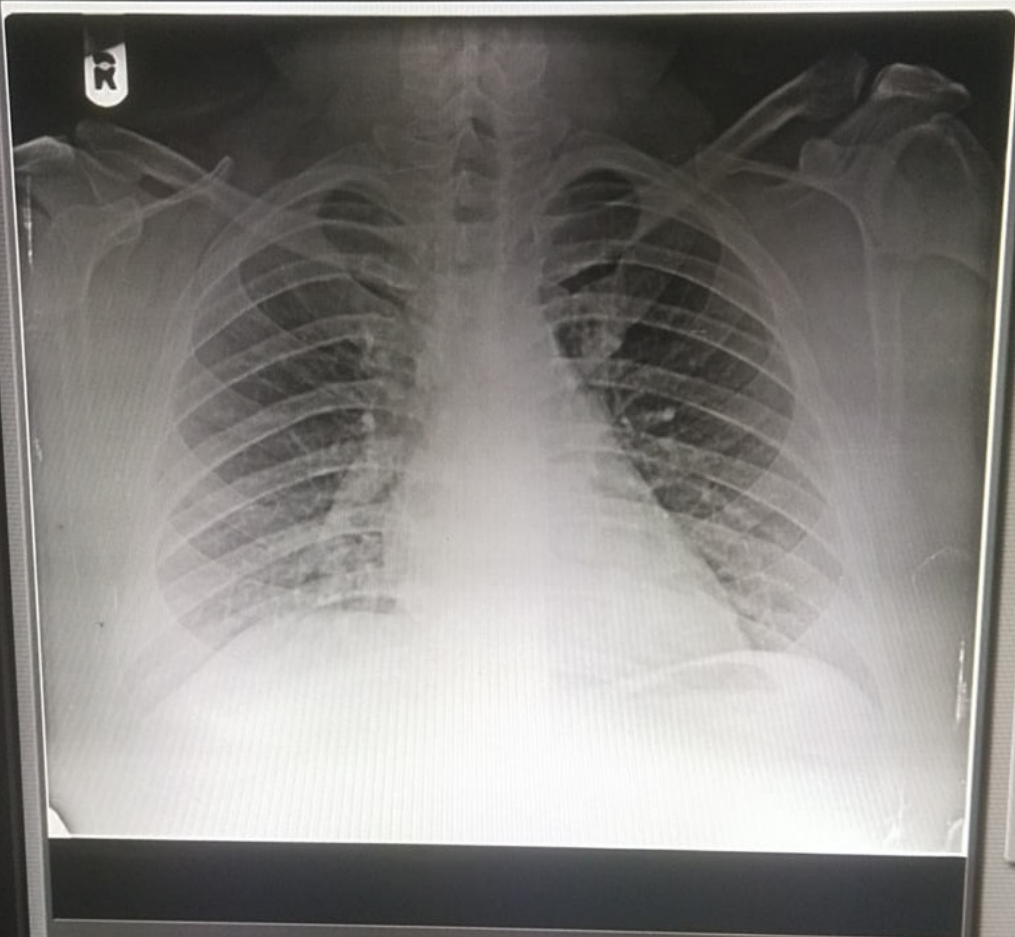
Dr. Vidhi D. Modh
MBBS
Reg. No. G-74540

Vidhi Diagnostics
L-86, Swatantra-Senani Nagar,
Opp. Akhbarnagar Bus Terminals,
Nr. Akhbarnagar Circle,
New Vadaj, Ahmedabad-13.

Dr. Dinesh S. M.

25022318

POOJAN D SHAH 31YRS



Navigation and control icons for the medical software interface, including a left arrow, a purple box with '1 (1)', a right arrow, a red 'X' icon, a magnifying glass icon, an 'ALL' icon with a circular arrow, a key icon, and a blue square icon.

DELL