

**Health Check up Booking Request(bobE41454), Beneficiary Code-49222**

1 message

Mediwheel <wellness@mediwheel.in>  
 To: vidhidiagnostics@gmail.com  
 Cc: customercare@mediwheel.in

30 June 2023 at 11:52



011-41195959

Email:wellness@mediwheel.in

Dear **VIDHI DIAGNOSTICS,**

**City :** Ahmedabad . **Address :** L-86 Swatantra - Senani Nagar , Opp- Akhbarnagar Bus Terminals, New Wadaj , Ahmedabad -13,

We have received the confirmation for the following booking .

**Name :** MR. KUMAR AKHILESH  
**Age :** 27  
**Gender :** Male  
**Package Name :** Medi-Wheel Metro Full Body Health Checkup Male Below 40  
**Contact Details :** 7677903253  
**Booking Date :** 30-06-2023  
**Appointment Date :** 01-07-2023

Member Information			
Booked Member Name	Age	Gender	Cost(In INR)
MR. KUMAR AKHILESH	27	Male	Cashless
<b>Total amount to be paid</b>			<b>Cashless</b>

We will get back to you with confirmation update shortly. Please find the package details as attached for your reference.

**Package Name :** Medi-Wheel Metro Full Body Health Checkup Male Below 40 - Includes (37)Tests  
**Tests included in this Package :** Ecg, TSH, X-ray Chest, Stress Test (tmt)/ 2d Echo, Blood Sugar Postprandial, A:g Ratio, Blood Group, Total Cholesterol, Triglycerides, Fasting Blood Sugar, Ultrasound Whole Abdomen , Glycosylated Haemoglobin (hba1c), Hdl, Vldl, Urine Analysis, LDL, Total Protine, General Consultation, HDL/ LDL ratio, GGT(Gamma-glutamyl Transferase), Eye Check-up consultation, ALP (ALKALINE PHOSPHATASE), Uric Acid, AST/ALT Ratio, Serum Protein, CBC with ESR, Stool Analysis, Urine Sugar Fasting, Urine Sugar PP, T3, T4, Cholesterol Total / HDL Ratio, BUN, BUN/Creatinine Ratio, Bilirubin Total & Direct and Indirect, Albumin, Globulin

**PRE EMPLOYMENT HEALTH SCREENING**

Date : 04/07/2023

**1. Personal Particulars**

Name : Akhil Keshav Umars S mchto NRIC No : \_\_\_\_\_  
Age : 29 years male Gender : Male / Female  
Marital Status : married

Past & Present Medical History : \_\_\_\_\_  
Family Medical History : \_\_\_\_\_  
Allergy : \_\_\_\_\_

**2. Clinical Medical Examination**

Height : 177 cm Weight : 82 kg  
Blood Pressure : 126/85 mmHg Pulse : 86 p/min  
Vision : Uncorrected : (R) \_\_\_\_\_ (L) \_\_\_\_\_ Corrected : (R) \_\_\_\_\_ (L) \_\_\_\_\_  
Colour Vision : Normal / Colour Blind  
General Condition : \_\_\_\_\_ Skin : \_\_\_\_\_  
Central Nervous System : \_\_\_\_\_ Head & Neck : \_\_\_\_\_  
Cardiovascular System : \_\_\_\_\_ Chest : \_\_\_\_\_  
Abdomen : \_\_\_\_\_ Limbs : \_\_\_\_\_  
Last menstrual period : N/A

**3. Investigations**

Chest X-Ray : Normal

Habit! - Smoking since 2 years 3 cigarette per day

I, the undersigned hereby authorize the doctor to release my medical check-up

Signature of applicant

Remarks :  Fit /  Unfit for employment

Dr. Vidhi D. Modh  
MBBS

Reg. No. 674540

Dr's name, signature & chop

**Vidhi Diagnostics**  
L-86, Swatantra-Sonani Nagar,  
Opp. Akhbarnagar Bus Terminals,  
Nr. Akhbarnagar Circle,  
New Wadaj, Ahmedabad-13.

**Dr. Dinesh S. Modh**

M.D., D.M.R.E. (Radiodiagnosis)

Consultant Radiologist & Sonologist

Ex. Junior Lecturer, B.J. Medical College, Civil Hospital, A'bad.

Creating life in Science  
**VIDHI**  
DIAGNOSTICS

04/07/2023

Akhil'sh Kumar S. Mahato  
29 years / male

Height :- 177 cm

Weight :- 82 kg

Bp :- 126/88 mmHg

Pulse :- 66 Per min

SpO2 :- 98

T :- (N)

RS ? (N)  
CNS ? (N)

Asymptomatic

No H/O DM, HTN, TB or thyroid

Adv! :-

He is medically fit

Dr. Vidhi D. Modh  
Reg. No. G-74540

ISO 9001:2015 Certified Diagnostics Center

Vidhi Imaging Center

L-86, Swatantra Senani Nagar, Opp. Indian Oil Petrol Pump, Akhbar Nagar Circle, Nava Vadaj, Ahmedabad - 380 013.

Phone : (Radiology) 079-2762 1406 | M. 98799 29406, 98250 09406 | Time (Radiology) : Mon. to Sat. 9 am to 2 pm, 5 to 9 pm, Sunday 9 am to 12 Noon

E-mail : vidhidiagnostics@gmail.com, Website : www.vidhidiagnostics.com

Multislice CT Scan | CBCT-Dental Scan | Live 3D-4D Sonography | Colour Doppler | Echo Cardiography | Interventional Radiology | Maxillofacial Radiology | Fetal Medicine  
Digital X-Ray | Digital Mammography | Digital OPG/TMJ | ECG/TMT/PFT/EEG/EMG | Audiometry | Pathology Laboratory | Health Check Up Plans | Pre Employment Check Up

**CT SCAN & CBCT FACILITY NOW AVAILABLE**

Vidhi Diagnostics  
L-86, Swatantra Senani Nagar,  
Opp. Akhbar Nagar Bus Terminals,  
New Vadaj, Ahmedabad - 380 013.

ID: 9896  
Name: akhileshkumar s mahto  
Age: 29yrs  
Sex: Male  
Hospital:  
Department:

HR : 66 bpm  
PR : 138 ms  
QRS : 102 ms  
QT/QTc : 378/396 ms  
P/QRS/T: 13/68/44 deg.  
RV5/SV1: 1.386/-0.392 mv  
RV5+SV1: 1.778 mv

\*\* normal ECG \*\*  
Sinus rhythm

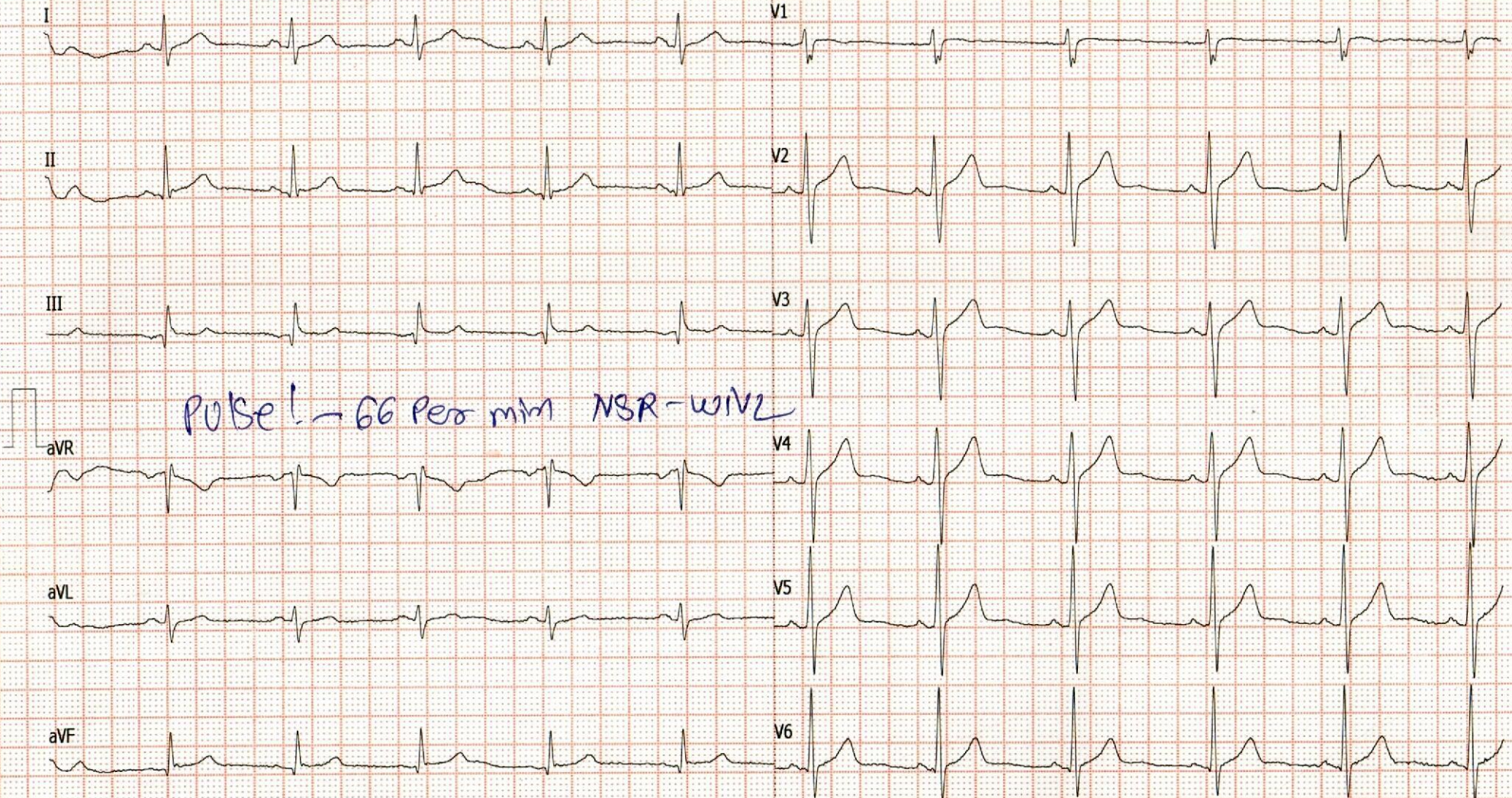
**Vidhi Diagnostics**  
L-86, Swatantra-Senani Nagar,  
Opp. Akhbarnagar Bus Terminals,  
Nr. Akhbarnagar Circle,  
New Wadaj, Ahmedabad-13.

**Dr. Avinash Bhaskar**

**Reg. No. - 3-45946**

Need to be confirmed by doctor. Doctor Name: \_\_\_\_\_

0.67Hz - 35Hz AC 50Hz 25 mm/s 10 mm/mv



# Dr. Dinesh S. Modh

M.D., D.M.R.E. (Radiodiagnosis)  
Consultant Radiologist & Sonologist  
Ex. Junior Lecturer, B.J. Medical College, Civil Hospital, A'bad.



Patient's name : AKHILESHKUMAR S. MAHTO  
Reg. ID : R-3823-23  
Referred by : Dr. MEDIWHEEL

Age/Sex : 29 Years/Male  
Accession : 8593  
Date : 04/07/2023

## 2D- ECHO REPORT

### FINAL CONCLUSION:

LV IS NORMAL SIZE. GOOD LV SYSTOLIC FUNCTION NO RWMA.  
LVEF - 60%. NO CONCENTRIC LVH.  
NORMAL LV COMPLANCE.  
LA IS NORMAL SIZE. NO LA CLOT.  
RV IS NORMAL SIZE. GOOD RV SYSTOLIC FUNCTION.  
RA IS NORMAL SIZE.  
MITRAL VALVE IS NORMAL. NO MS. MILD MR (15%). NO MVP.  
AORTIC VALVE IS NORMAL. NO AS. NO AR.  
TRICUSPID VALVE IS NORMAL. NO TR. RVSP-26 mmHg. NO PAH.

NO CLOT, NO VEGETATION, NO PERICARDIAL EFFUSION.

### DIMENSIONS:

AORTA	2.6 C.M
LEFT ATRIUM	2.7 C.M
LVDD	4.1 C.M.
IVSD	1.0 C.M
PWD	1.0 C.M
LVDS	2.6 C.M.

### COLOUR DOPPLER FINDING:

STRUCTURE	VELOCITY m/sec
	Max
PULMONARY VALVE	0.7
MITRAL VALVE	E : 0.7 A: 0.4
AORTIC VALVE	1.0

Dr. Avinash Bhaskar  
M.B.B.S. D Cardio  
DR AVINASH BHASKAR  
Reg. No. 0905

ISO 9001:2015 Certified Diagnostics Center

Vidhi Imaging Center

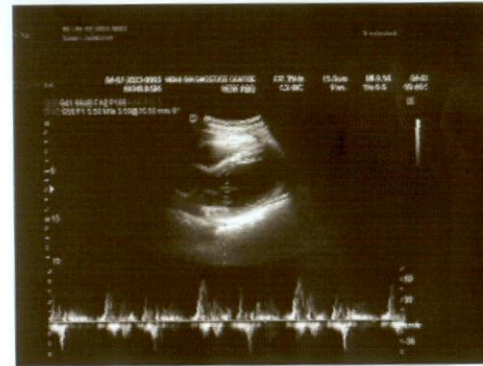
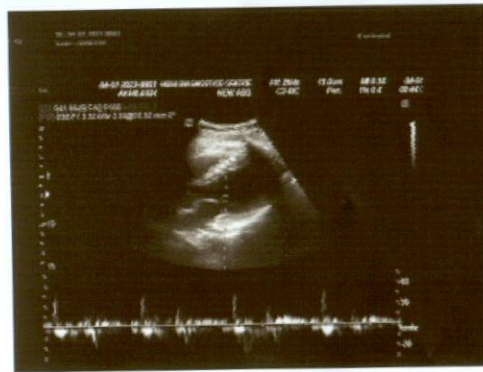
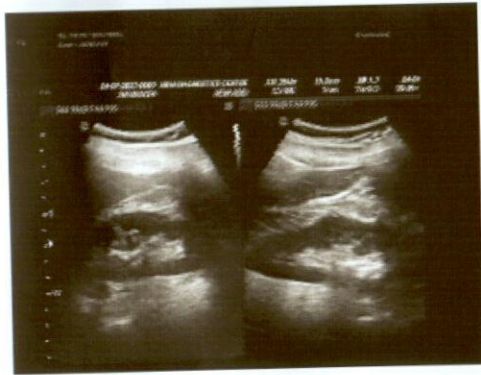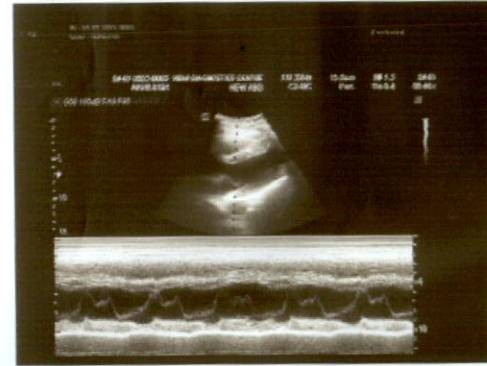
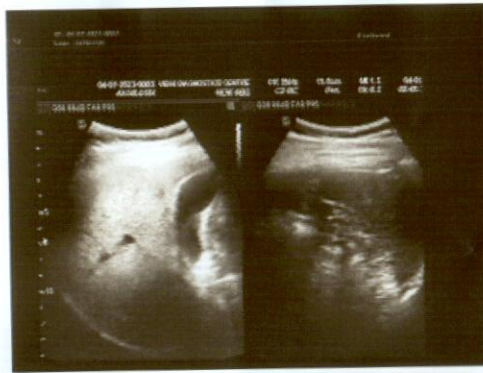
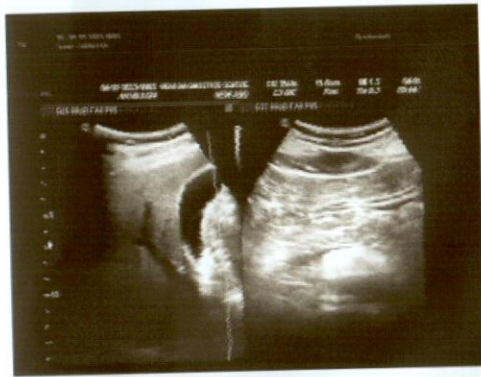L-86, Swatantra Senani Nagar, Opp. Indian Oil Petrol Pump, Akhbarnagar Circle, Nava Vadaj, Ahmedabad - 380 013.

Phone : (Radiology) 079-2762 1406 | M. 98799 29406, 98250 09406 | Time (Radiology) : Mon. to Sat. 9 am to 2 pm, 5 to 9 pm, Sunday 9 am to 12 Noon  
E-mail : vidhidiagnostics@gmail.com, Website : www.vidhidiagnostics.com

Multislice CT Scan | CBCT-Dental Scan | Live 3D-4D Sonography | Colour Doppler | Echo Cardiography | Interventional Radiology | Maxillofacial Radiology | Fetal Medicine  
Digital X-Ray | Digital Mammography | Digital OPG/TMJ | ECG/TMT/PFT/EEG/EMG | Audiometry | Pathology Laboratory | Health Check Up Plans | Pre Employment Check Up

**CT SCAN & CBCT FACILITY NOW AVAILABLE**

Akhilesh Kumar



## Dr. Dinesh S. Modh

M.D., D.M.R.E. (Radiodiagnosis)

Consultant Radiologist & Sonologist

Ex. Junior Lecturer, B.J. Medical College, Civil Hospital, A'bad.



Patient's name : AKHILESHKUMAR S. MAHTO  
Reg. ID : R-3823-23  
Referred by : Dr. MEDIWHEEL

Age/Sex : 29 Years/Male  
Accession : 8593  
Date : 04/07/2023

### X-RAY CHEST (PA VIEW)

Both lung fields appear normal.  
No e/o consolidation or cavitations is seen.  
Both costo-phrenic angles appear clear.  
Cardiac size is with in normal limits.  
Both domes of diaphragm appear normal.  
Bony thoracic cage appears normal.

Thanks for reference.

Dr. Dinesh S. Modh  
MD DMRE (Radiodiagnosis)  
DR DINESH S. MODH  
M.D. DMRE(RADIODIAGNOSIS)

ISO 9001:2015 Certified Diagnostics Center

Vidhi Imaging Center

L-86, Swatantra Senani Nagar, Opp. Indian Oil Petrol Pump, Akhbarnagar Circle, Nava Vadaj, Ahmedabad - 380 013.

Phone : (Radiology) 079-2762 1406 | M. 98799 29406, 98250 09406 | Time (Radiology) : Mon. to Sat. 9 am to 2 pm, 5 to 9 pm, Sunday 9 am to 12 Noon

E-mail : vidhidiagnostics@gmail.com, Website : www.vidhidiagnostics.com

Multislice CT Scan | CBCT-Dental Scan | Live 3D-4D Sonography | Colour Doppler | Echo Cardiography | Interventional Radiology | Maxillofacial Radiology | Fetal Medicine  
Digital X-Ray | Digital Mammography | Digital OPG / TMJ | ECG / TMT / PFT / EEG / EMG | Audiometry | Pathology Laboratory | Health Check Up Plans | Pre Employment Check Up

**CT SCAN & CBCT FACILITY NOW AVAILABLE**

## Dr. Dinesh S. Modh

M.D., D.M.R.E. (Radiodiagnosis)

Consultant Radiologist & Sonologist

Ex. Junior Lecturer, B.J. Medical College, Civil Hospital, A'bad.



Patient's name : AKHILESHKUMAR S. MAHTO  
Reg. ID : R-3823-23  
Referred by : Dr. MEDIWHEEL

Age/Sex : 29 Years/Male  
Accession : 8593  
Date : 04/07/2023

### USG ABDOMEN

LIVER: Liver is normal in size and bright in echotexture s/o fatty liver grade1. Intrahepatic biliary radicals appear normal.

Portal vein is normal in caliber. Common Bile duct is normal in course & caliber. No e/o calculus is seen in biliary tree.

GALL BLADDER: is distended & appear normal. No e/o calculus or cholecystitis is seen. GB wall thickness appears normal. No evidence of pericholecystic fluid is seen.

SPLEEN: Spleen is normal in size & shows normal echo texture. No evidence of diffuse or focal lesion is seen. Splenic vein appears normal.

PANCREAS: Pancreas appears normal in size & echotexture. No evidence of diffuse or focal lesion is seen. Main pancreatic duct is normal.

KIDNEY: Both kidneys appear normal in size and echopattern. Corticomedullary differentiation is maintained.

No evidence of calculus or hydronephrosis is seen on both sides.

Both supra renal region appear normal.

No evidence of pre & para aortic lymphadenopathy is seen.

Gas filled non-dilated bowel loops are seen in abdomen.

No evidence of free fluid is seen in abdomen.

No evidence of dilated or thickened bowel loops is seen.

Urinary bladder appears normal. No e/o calculus or mass lesion is seen.

Prostate appears normal in size & echopattern.

Thanks for reference.

Dr. Dinesh S. Modh  
MD DMRE (Radiodiagnosis)

DR DINESH S. MODH

M.D. DMRE(RADIODIAGNOSIS)

ISO 9001:2015 Certified Diagnostics Center

Vidhi Imaging Center

L-86, Swatantra Senani Nagar, Opp. Indian Oil Petrol Pump, Akhbarnagar Circle, Nava Vadaj, Ahmedabad - 380 013.

Phone : (Radiology) 079-2762 1406 | M. 98799 29406, 98250 09406 | Time (Radiology) : Mon. to Sat. 9 am to 2 pm, 5 to 9 pm, Sunday 9 am to 12 Noon

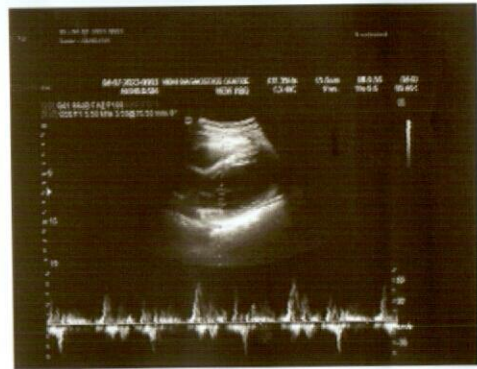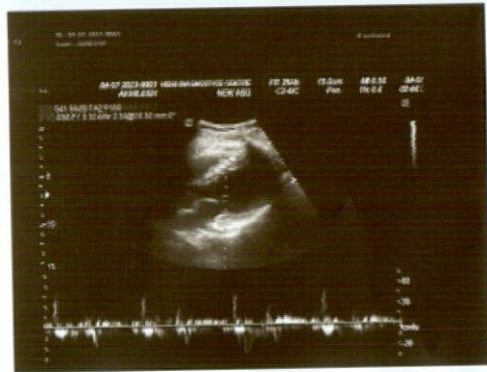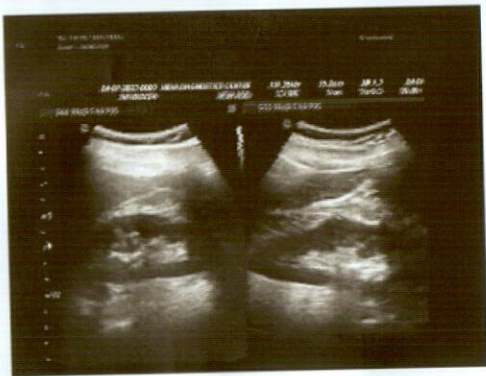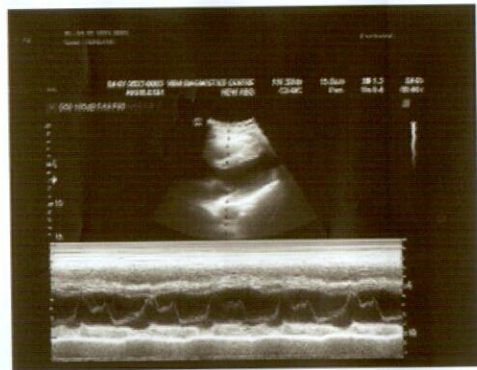
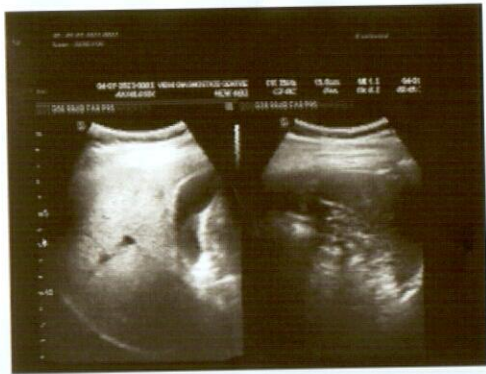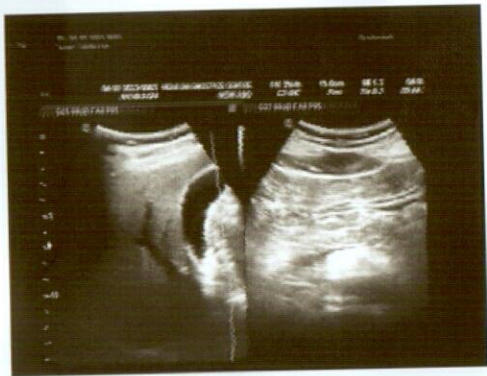E-mail : vidhidiagnostics@gmail.com, Website : www.vidhidiagnostics.com

Multislice CT Scan | CBCT-Dental Scan | Live 3D-4D Sonography | Colour Doppler | Echo Cardiography | Interventional Radiology | Maxillofacial Radiology | Fetal Medicine  
Digital X-Ray | Digital Mammography | Digital OPG/TMJ | ECG/TMT/PFT/EEG/EMG | Audiometry | Pathology Laboratory | Health Check Up Plans | Pre Employment Check Up

**CT SCAN & CBCT FACILITY NOW AVAILABLE**



Akhilesh Kumar



## Dr. Dinesh S. Modh

M.D., D.M.R.E. (Radiodiagnosis)

Consultant Radiologist & Sonologist

Ex. Junior Lecturer, B.J. Medical College, Civil Hospital, A'bad.



04/07/2023.

Akhilesh kumar.

I hereby declare that I am not conducting  
the stool test as of now.

**Vidhi Diagnostics**  
L-86, Swatantra-Senani Nagar,  
Opp. Akharnagar Bus Terminals,  
Nr. Akharnagar Circle,  
New Wadaj, Ahmedabad-13.

ISO 9001:2015 Certified Diagnostics Center

Vidhi Imaging Center

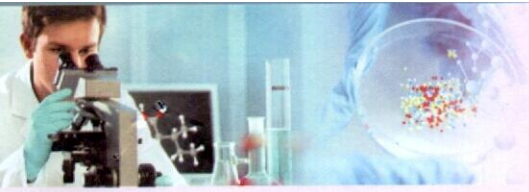L-86, Swatantra Senani Nagar, Opp. Indian Oil Petrol Pump, Akharnagar Circle, **Nava Vadaj**, Ahmedabad - 380 013.

Phone : (Radiology) 079-2762 1406 | M. 98799 29406, 98250 09406 | Time (Radiology) : Mon. to Sat. 9 am to 2 pm, 5 to 9 pm, Sunday 9 am to 12 Noon

E-mail : vidhidiagnostics@gmail.com, Website : www.vidhidiagnostics.com

Multislice CT Scan | CBCT-Dental Scan | Live 3D-4D Sonography | Colour Doppler | Echo Cardiography | Interventional Radiology | Maxillofacial Radiology | Fetal Medicine  
Digital X-Ray | Digital Mammography | Digital OPG/TMJ | ECG/TMT/PFT/EEG/EMG | Audiometry | Pathology Laboratory | Health Check Up Plans | Pre Employment Check Up

**CT SCAN & CBCT FACILITY NOW AVAILABLE**



Pathology Department



Patient's name : AKHILESHKUMAR SANJEEVKUMAR MAHTO  
 Age/Sex : 29 Years/Male  
 Referred by : Dr. MEDIWHEEL  
 Collection Time : 09:31

Reg. ID : P-1799-23  
 Accession : 8590  
 Order Dt/time : 04/07/2023 09:31

**Complete Blood Count**

Sample Type: EDTA

Test Name	Result	Units	Biological Reference Interval
<b><u>Blood Counts</u></b>			
Haemoglobin :	15.1	Gms%	13.5 - 18.0
Total R.B.C. :	4.83	mill/c.mm	4.7 - 6.0
Total W. B. C. :	6830	/cu mm	4000 - 10500
Platelet Count :	238000	/cu.mm	1,50,000 - 4,50,000
<b><u>Differential Count</u></b>			
Neutrophils :	58	%	40 - 70
Lymphocytes :	37	%	20 - 40
Eosinophils :	03	%	1 - 4
Monocytes :	02	%	2 - 6
Basophils :	00	%	0 - 01
<b><u>Blood Indices</u></b>			
P. C. V :	45.1	%	42 - 52
M. C. V. :	93.3	fl	78 - 100
M.C.H :	<b>31.2</b>	pg	27 - 31
M. C. H. C :	33.4	%	32 - 36
R.D.W :	<b>14.9</b>	%	11.5 - 14.0

**E.S.R.( Westergren Method )**

After one hour : 04 mm/hr 1 - 7

TESTS DONE ON FULLY AUTOMATED HEMATOLOGY ANALYZER.

*Dr. Gayatri M. Mehta*

M. D. (Patho)

Reg. No. G-32215

DR GAYATRI MEHTA  
 MD(PATHOLOGY)

DR.ANAND D.PARIKH  
 MD(PATHOLOGY)

LAB USE ONLY (Entered by :GM Enter Date/Time:04/07/2023 1:47:00 PM) (Verify by :GM Verify Date/Time:04/07/2023 1:47:00 PM)



Vidhi Imaging Center | Pathology Department

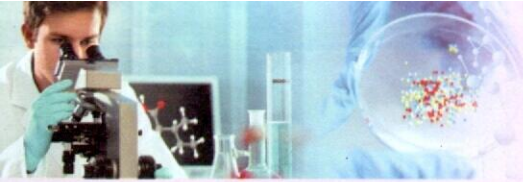L-86, Swatantra Senani Nagar, Opp. Akhbarnagar Petrol Pump, Nr. Akhbarnagar Circle, Nava-Vadaj, Ahmedabad - 380 013.

Ph. (Pathology) : 8849893954 M. 98799 29406, 98250 09406, E-mail : vidhidiagnostics@gmail.com, Web. : www.vidhidiagnostics.com

Time (Pathology) : Mon. to Sat. 8.30 am to 8.00 pm, Sunday 9 am to 12 Noon

*Pathology means science behind medicine*

**CT SCAN & CBCT FACILITY NOW AVAILABLE**



Patient's name : AKHILESHKUMAR SANJEEVKUMAR MAHTO  
Age/Sex : 29 Years/Male  
Referred by : Dr. MEDIWHEEL  
Collection Time : 09:31

Reg. ID : P-1799-23  
Accession : 8590  
Order Dt/time : 04/07/2023 09:31

**Blood Group**

Sample Type: EDTA sample.

Test Name	Result
BG :	" A "
RH :	POSITIVE
Remarks	Done by forward grouping method.

**Blood Glucose**

Sample Type: Serum

Test Name	Result	Units	Biological Reference Interval
Fasting Blood Glucose : <i>GOD-POD Method.</i>	104.7	mg/dl	70 - 110

**Blood Glucose**

Sample Type: Serum

Test Name	Result	Units	Biological Reference Interval
Post Prandial Blood Glucose After 2hr. : <i>GOD-POD Method.</i>	134.2	mg/dl	80 - 140

*Dr. Gayatri M. Mehta*

*Gayatri Mehta*  
M. D. (Patho)  
Reg. No. G-32215

DR GAYATRI MEHTA  
MD(PATHOLOGY)

DR. ANAND D. PARIKH  
MD(PATHOLOGY)

LAB USE ONLY (Entered by :GM Enter Date/Time:04/07/2023 6:23:00 PM) (Verify by :GM Verify Date/Time:04/07/2023 6:23:00 PM)



Vidhi Imaging Center | Pathology Department

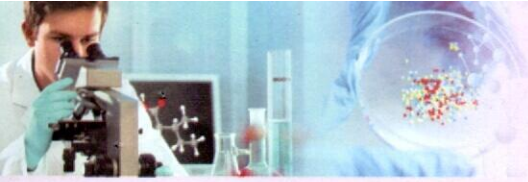L-86, Swatantra Senani Nagar, Opp. Akharnagar Petrol Pump, Nr. Akharnagar Circle, Nava-Vadaj, Ahmedabad - 380 013.

Ph. (Pathology) : 8849893954 M. 98799 29406, 98250 09406, E-mail : vidhidiagnostics@gmail.com, Web. : www.vidhidiagnostics.com

Time (Pathology) : Mon. to Sat. 8.30 am to 8.00 pm, Sunday 9 am to 12 Noon

*Pathology means science behind medicine*

**CT SCAN & CBCT FACILITY NOW AVAILABLE**



Pathology Department

**VIDHI**<sup>®</sup>  
**DIAGNOSTICS**

Creating Life in Images

Patient's name : AKHILESHKUMAR SANJEEVKUMAR MAHTO  
Age/Sex : 29 Years/Male  
Referred by : Dr. MEDIWHEEL  
Collection Time : 09:31

Reg. ID : P-1799-23  
Accession : 8590  
Order Dt/time : 04/07/2023 09:31

### Lipid Profile

Sample Type: Serum

Test Name	Result	Units	Biological Reference Interval
<b>S. Cholesterol :</b> Oxidase-esterase method.	<b><u>205</u></b>	mg/dl	0 - 200
<b>S. Triglyceride :</b> Enzymatic Colorimetry method	129.3	mg/dL	0 - 200
<b>S. HDL - Cholesterol :</b> Serum by Enzymatic method.	38.1	mg/dL	35 - 65
<b>S. LDL - Cholesterol :</b> Serum by Enzymatic method	<b><u>157.0</u></b>	mg/dL	0 - 130
<b>S. VLDL - Cholesterol :</b>	25.86	mg/dL	0 - 30
<b>S. Chole/HDL.Ratio :</b>	5.38		1 - 6
<b>S. LDL / HDL Cholesterol Ratio :</b>	<b><u>4.12</u></b>		0 - 3.5

*Dr. Gayatri M. Mehta*

M. D. (Patho)

Reg. No. G-32215

DR GAYATRI MEHTA  
MD(PATHOLOGY)

DR. ANAND D. PARIKH  
MD(PATHOLOGY)

LAB USE ONLY (Entered by :GM Enter Date/Time:04/07/2023 1:47:00 PM) (Verify by :GM Verify Date/Time:04/07/2023 1:47:00 PM)



Vidhi Imaging Center | Pathology Department

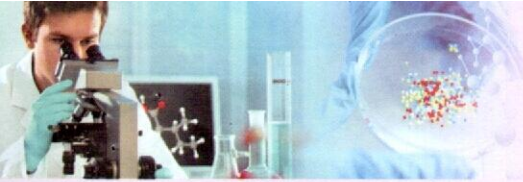L-86, Swatantra Senani Nagar, Opp. Akhbarnagar Petrol Pump, Nr. Akhbarnagar Circle, Nava-Vadaj, Ahmedabad - 380 013.

Ph. (Pathology) : 8849893954 M. 98799 29406, 98250 09406, E-mail : vidhidiagnostics@gmail.com, Web. : www.vidhidiagnostics.com

Time (Pathology) : Mon. to Sat. 8.30 am to 8.00 pm, Sunday 9 am to 12 Noon

*Pathology means science behind medicine*

**CT SCAN & CBCT FACILITY NOW AVAILABLE**



Pathology Department



Patient's name : AKHILESHKUMAR SANJEEVKUMAR MAHTO  
Age/Sex : 29 Years/Male  
Referred by : Dr. MEDIWHEEL  
Collection Time : 09:31

Reg. ID : P-1799-23  
Accession : 8590  
Order Dt/time : 04/07/2023 09:31

**HbA1C**

Sample Type: Serum

Test Name	Result	Units	Biological Reference Interval
HbA1C :	5.3	%	Non-diabetic: 4.2-6.2 Pre-diabetic : 6.3-7.2 Diabetic : 7.3-8.2
Mean Blood Glucose of Last 03 months.	105	mg/dl	

**Comment**

\*As per the new 2009 update of American Diabetes Association regarding HbA1C & Mean Blood Glucose relationship.

**NOTE:**

This test is used to monitor diabetic patients compliance with the therapeutic regimen and logo It's level is proportional to both the average blood glucose concentration and the life span of the red blood cells (RBC) in circulation. HbA1c values are free of day to day glucose fluctuations and are unaffected by exercise or recent food intake.

*Dr. Gayatri M. Mehta*

M. D. (Patho)

*Reg. No. G-32215*

DR GAYATRI MEHTA  
MD(PATHOLOGY)

DR. ANAND D. PARIKH  
MD(PATHOLOGY)

LAB USE ONLY (Entered by :GM Enter Date/Time:04/07/2023 1:47:00 PM) (Verify by :GM Verify Date/Time:04/07/2023 1:47:00 PM)



Vidhi Imaging Center | Pathology Department

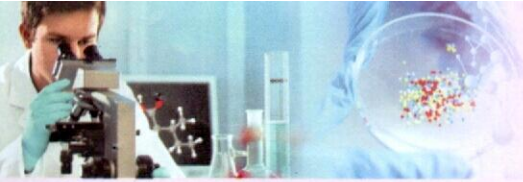L-86, Swatantra Senani Nagar, Opp. Akhbar Nagar Petrol Pump, Nr. Akhbar Nagar Circle, Nava-Vadaj, Ahmedabad - 380 013.

Ph. (Pathology) : 8849893954 M. 98799 29406, 98250 09406, E-mail : vidhidiagnostics@gmail.com, Web. : www.vidhidiagnostics.com

Time (Pathology) : Mon. to Sat. 8.30 am to 8.00 pm, Sunday 9 am to 12 Noon

*Pathology means science behind medicine*

**CT SCAN & CBCT FACILITY NOW AVAILABLE**



Patient's name : AKHILESHKUMAR SANJEEVKUMAR MAHTO  
 Age/Sex : 29 Years/Male  
 Referred by : Dr. MEDIWHEEL  
 Collection Time : 09:31

Reg. ID : P-1799-23  
 Accession : 8590  
 Order Dt/time : 04/07/2023 09:31

**BIOCHEMISTRY**

Sample type :Serum

Test Name	Result	Units	Biological Reference Interval
<b>Urea</b> , (Serum by GLDH method) :	26.3	mg/dl	10 - 50
<b>S.Uric acid</b> , (Serum by Uricase method) :	7.0	mg/dl	3.4 - 7.0
<b>Bun</b> :	12.3	mg/dl	6-20
<b>Creatinine</b> , (Serum by Enzymatic reaction) :	0.97	mg/dl	0.5-1.2
<b>BUN/CREATRATIO</b>	12.68		13 - 20
<b>S.G.P.T (ALT)</b> : (Serum by IFCC method )	39.3	U/L	0 - 40
<b>S.G.O.T (AST)</b> : (Serum by IFCC method )	21.0	U/L	0 - 37
<b>ALK.PHOSPHATASE</b> : (Serum by PNP method )	93	U/L	40-129
<b>G.G.T</b> :	33.3	U/L	8 - 78
<b><u>BILIRUBIN</u></b>			
<b>Total</b> :	0.83	mg/dl	Up to 1.2
<b>Direct</b> :	0.39	mg/dl	0-0.7
<b>Indirect</b> :	0.44	mg/dl	0 - 0.5
<b><u>SERUM PROTEINS</u></b>			
<b>Total Protein</b> (Serum by Biuret method) :	6.70	gms/dl	6.4 - 8.5
<b>Albumin</b> (Serum by BCG method) :	4.09	gms/dl	3.97-4.94
<b>Globulins</b> :	2.61	gms/dl	2.3 - 3.5
<b>A/G Ratio</b> :	1.567		0.9 - 2.9

*Dr. Gayatri M. Mehta*

M. D. (Patho)

Reg. No. G-32215

DR GAYATRI MEHTA  
MD(PATHOLOGY)

DR. ANAND D. PARIKH  
MD(PATHOLOGY)



Entered by :GM Enter Date/Time:04/07/2023 1:46:00 PM (Verify by :GM Verify Date/Time:04/07/2023 1:46:00 PM)

Vidhi Imaging Center | Pathology Department

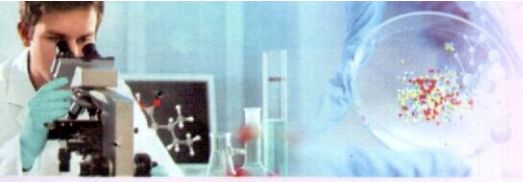L-86, Swatantra Senani Nagar, Opp. Akhbarnagar Petrol Pump, Nr. Akhbarnagar Circle, Nava-Vadaj, Ahmedabad - 380 013.

Ph. (Pathology) : 8849893954 M. 98799 29406, 98250 09406, E-mail : vidhidiagnostics@gmail.com, Web. : www.vidhidiagnostics.com

Time (Pathology) : Mon. to Sat. 8.30 am to 8.00 pm, Sunday 9 am to 12 Noon

*Pathology means science behind medicine*

**CT SCAN & CBCT FACILITY NOW AVAILABLE**



Pathology Department



Patient's name : AKHILESHKUMAR SANJEEVKUMAR MAHTO  
Age/Sex : 29 Years/Male  
Referred by : Dr. MEDIWHEEL  
Collection Time : 09:31

Reg. ID : P-1799-23  
Accession : 8590  
Order Dt/time : 04/07/2023 09:31

### Thyroid Function Test

Sample Type: Serum

Test Name	Result	Units	Biological Reference Interval
TOTAL T3 :	0.73	ng/ml	0.60 - 1.81
TOTAL T4 :	7.0	ug/dl	4.5 - 12.6
TSH(Ultra sensitive) :	2.689	mIU/L	0.55 - 4.78

*Dr. Gayatri M. Mehta*

M. D. (Patho)

Reg. No. G-32215

DR GAYATRI MEHTA  
MD(PATHOLOGY)

DR. ANAND D. PARIKH  
MD(PATHOLOGY)

LAB USE ONLY (Entered by :GM Enter Date/Time:04/07/2023 1:49:00 PM) (Verify by :GM Verify Date/Time:04/07/2023 1:49:00 PM)



Vidhi Imaging Center | Pathology Department

L-86, Swatantra Senani Nagar, Opp. Akhbarnagar Petrol Pump, Nr. Akhbarnagar Circle, Nava-Vadaj, Ahmedabad - 380 013.

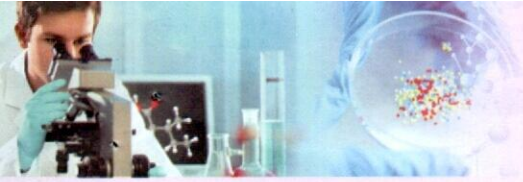Ph. (Pathology) : 8849893954 M. 98799 29406, 98250 09406, E-mail : vidhidiagnostics@gmail.com, Web. : www.vidhidiagnostics.com

Time (Pathology) : Mon. to Sat. 8.30 am to 8.00 pm, Sunday 9 am to 12 Noon

*Pathology means science behind medicine*

**CT SCAN & CBCT FACILITY NOW AVAILABLE**





Pathology Department



Patient's name : AKHILESHKUMAR SANJEEVKUMAR MAHTO  
 Age/Sex : 29 Years/Male  
 Referred by : Dr. MEDIWHEEL  
 Collection Time : 09:31

Reg. ID : P-1799-23  
 Accession : 8590  
 Order Dt/time : 04/07/2023 09:31

**Urine Analysis**

Sample Type: Urine

Test Name	Result	Units	Biological Reference Interval
<b><u>Physical Examination</u></b>			
Quantity :	20	ml	0 - 500 ml
Colour :	Yellow		Pale Yellow
Transparency :	Slight Turbid.		Clear
Reaction :	Acidic		4.6 - 8.0
Specific Gravity :	1.025		1.016 - 1.022
Sediment :	Present		
<b><u>Chemical Examination</u></b>			
Albumin :	Present (Faint Trace)		Absent
Sugar :	NIL		Absent
Acetone :	Absent		Absent
Bile Salts :	Absent		Absent
Bile Pigments :	Absent		Absent
Urobilogen :	Absent		Absent
Nitrites :	Absent		Absent
<b><u>Microscopic Examination</u></b>			
Red blood Cells :	1-2	/h.p.f	Absent
Pus Cells :	2-3	/h.p.f	Absent
Epithelial Cells :	1-2	/h.p.f	< 10.0
Amorphous :	Absent	/h.p.f	Absent
Bacteria :	Absent	/h.p.f	Absent
Crystals :	Absent	/h.p.f	Absent
Casts :	Absent	/h.p.f	Absent
Fungus :	Not seen	/h.p.f	Absent

*Dr. Gayatri M. Mehta*

M. D. (Patho)

Reg. No. G-32215

DR. GAYATRI MEHTA  
 MD(PATHOLOGY)



DR. ANAND D. PARIKH  
 MD(PATHOLOGY)

Entered by : GM Enter Date/Time: 04/07/2023 1:49:00 PM (Verify by : GM Verify Date/Time: 04/07/2023 1:49:00 PM)

Vidhi Imaging Center | Pathology Department

L-86, Swatantra Senani Nagar, Opp. Akharnagar Petrol Pump, Nr. Akharnagar Circle, Nava-Vadaj, Ahmedabad - 380 013.

Ph. (Pathology) : 8849893954 M. 98799 29406, 98250 09406, E-mail : vidhidiagnostics@gmail.com, Web. : www.vidhidiagnostics.com

Time (Pathology) : Mon. to Sat. 8.30 am to 8.00 pm, Sunday 9 am to 12 Noon

*Pathology means science behind medicine*

**CT SCAN & CBCT FACILITY NOW AVAILABLE**

**INDIAN UNION DRIVING LICENCE JHARKHAND STATE**

Name: AKHILESH KUMAR  
 S/o: SANJEEV KUMAR MAHTO

ID Mark1  
 ID Mark2

DL No.: JH-01/2015/0154169  
 Issue Dt: 03-DEC-2015  
 Validity (T): 03-DEC-2035  
 DOB: 21-JAN-1994  
 Blood Group: A+

Badge No.:  
 Endorse No.:  
 Endorse Auth.:

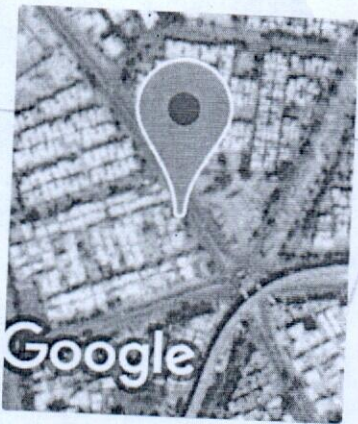Class	M.C.B.	L.V.V.	
Issued On	03 DEC 2015	03 DEC 2015	

Address: SHY RAM NIKAS H T I J COLONY  
 TETRA TOLI BARKUM, RANCHI  
 834018

Signature of Card Holder: *Akhil Kumar*  
 Issuing Authority: JH-0120150000071  
 Signature of Issuing Authority: *[Signature]*

+  
*[Handwritten Signature]*

**Vidhi Diagnostics**  
 L-86, Swatantra-Senani Nagar,  
 Opp. Akhbarnagar Bus Terminals,  
 Nr. Akhbarnagar Circle,  
 New Wadaj, Ahmedabad-13.



 **GPS Map Camera**

**Ahmedabad, Gujarat, India**

3H96+6PR, Chandlodiya Rd, Swatantra Senani Nagar,  
Nava Vadaj, Ahmedabad, Gujarat 380013, India

Lat 23.068108°

Long 72.561766°

04/07/23 09:17 AM GMT +05:30

**Vidhi Diagnostics**  
L-88, Swatantra-Senani Nagar,  
Opp. Akhbarnagar Bus Terminals,  
Nr. Akhbarnagar Circle,  
New Wadaj, Ahmedabad-13.