



DEPARTMENT OF RADIOLOGY

Patient Name	Mr VIKASH KUMAR	Billed Date	: 15/11/2023	9.43 AM
Reg No	28620	Reported Date	: 15/11/2023	
Age/Sex	40 Years 5 Months 4Days / Male	Req. No.	: 23065833	
Type	OPD	Consultant Doctor	: Dr. CONSULTANT	

X-RAY CHEST APTPA

Bilateral lungs appears normal.

Both hila are normal in size, have equal density and bear normal relationship.

The heart and trachea are central in position and no mediastinal abnormality is visible.

The cardiac size is normal for patient age and view.

The domes of the diaphragms are normal in position, and show smooth outline.

To be correlated clinically

DR BINOD KR CHAUDHARY
MBBS, MD
CONSULTANT RADIOLOGIST

(This is only professional opinion and not the diagnosis, Please correlate clinically)

J-Block, Sector-10, Near Court, Faridabad - 121004, Haryana

Tel.: 0129-4200000 E-mail : parkfaridabad@gmail.com

PARK GROUP OF HOSPITALS : West Delhi • South Delhi • Gurgaon • Karnal • Panipat • Hodal • Ambala • Behror

the **health** care providers

the **health** care providers

DEPARTMENT OF RADIOLOGY

Patient Name	Mr VIKASH KUMAR	Billed Date	15/11/2023	9.43 AM
Reg No	28620	Reported Date	15/11/2023	
Age/Sex	40 Years 5 Months 4Days / Male	Req. No.	23065633	
Type	OPD	Consultant Doctor	Dr. CONSULTANT	

USG WHOLE ABDOMEN

LIVER : The liver is normal in size, shape and echotexture.No evidence of any focal lesion. IHBR is NOT dilated. Portal vein is normal.

GALL BLADDER :The gall bladder is well distended.No evidence any calculus or mass seen. GB wall thickness with in normal limits. No evidence of pericholecystic fluid is seen.

BILE DUCT :The common bile duct is normal in caliber.

SPLEEN :The spleen is normal in size and shape. Its echotexture is homogeneous.No evidence of focal lesion is noted. Splenic vein is normal.

PANCREAS :The pancreas is normal in size, shape, contours and echotexture.

BILATERAL KIDNEYS : The bilateral kidneys are normal in size and shows grade I increased cortical echogenecity. Cortico-medullary differentiation is maintained. There is no evidence of obvious calculus or hydronephrosis seen.

Few cystic lesions are seen in both kidneys, largest measuring approx. 13 mm at mid pole of left kidney.

URINARY BLADDER :The urinary bladder is well distended.Wall thickness within normal limits.No evidence of calculus is seen.No evidence of mass or diverticulum is noted.

PROSTATE: Prostate appears normal in size, shape and echotexture.

No free fluid is seen in peritoneal cavity.

No evidence of obvious retroperitoneal or mesentric lymphadenopathy is seen.

IMPRESSION: - USG WHOLE ABDOMEN REVEALS:-

- Grade I increased renal cortical echogenecity. ADV: KFT correlation.
- Bilateral renal cysts.

TO BE CORRELATED CLINICALLY.

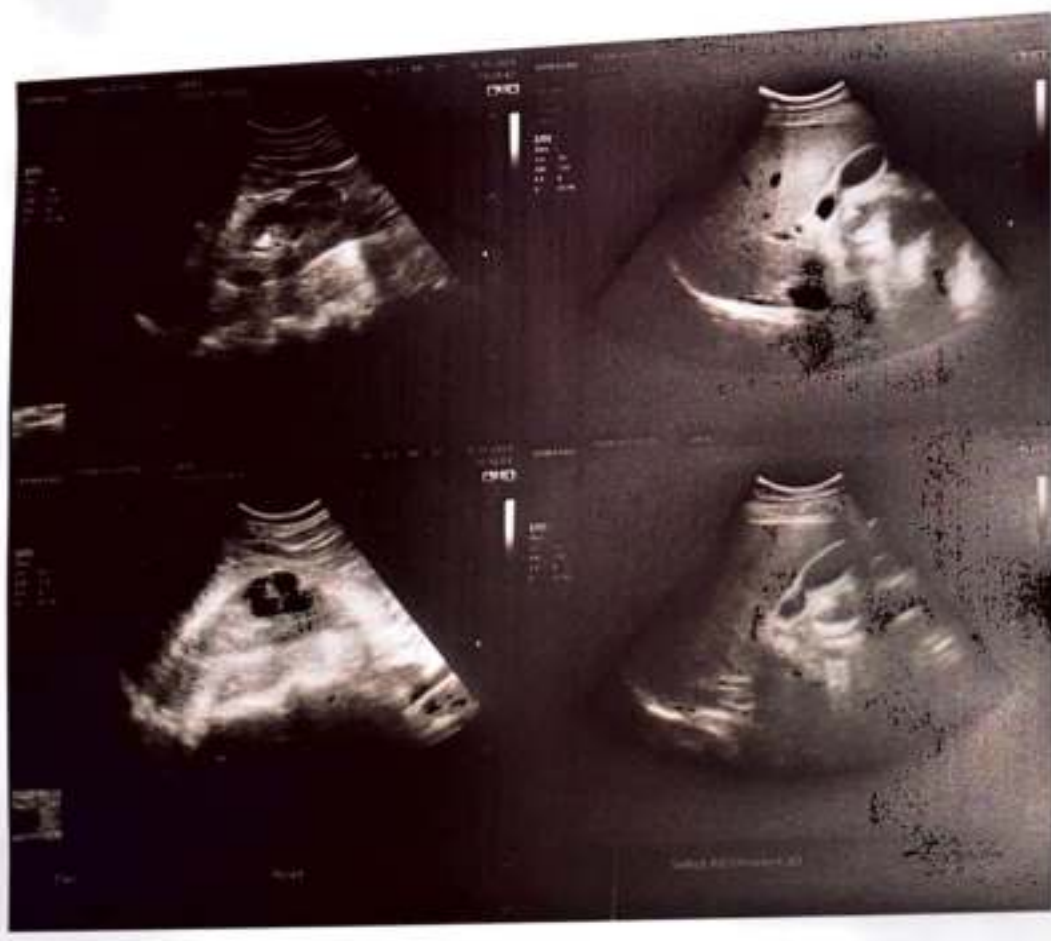
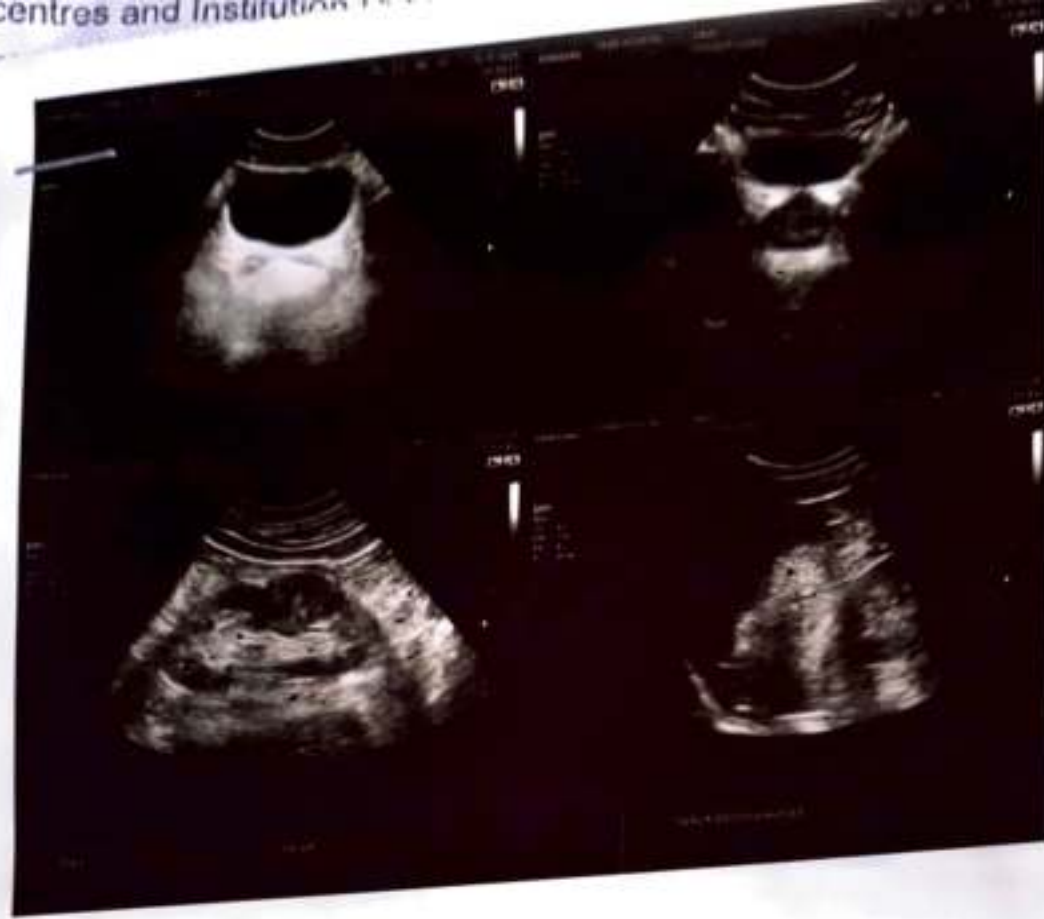
DR BINOD KR CHAUDHARY
MBBS,MD
CONSULTANT RADIOLOGIST

(This is only professional opinion and not the diagnosis, Please correlate clinically)

J-Block, Sector-10, Near Court, Faridabad - 121004, Haryana
Tel.: 0129-4200000 E-mail : parkfaridabad@gmail.com

PARK GROUP OF HOSPITALS : West Delhi • South Delhi • Gurgaon • Karnal • Panipat • Hodal • Ambala • Behror





DEPARTMENT OF PATHOLOGY

Patient Name : Mr. VIKASH KUMAR
MR No : 28620
Age/Sex : 40 Years 5 Months 4 Days / Male
Type : OPD
TPA/Corporate : MEDIWHEEL
Bill Date : 15/11/2023
Reporting Date : 15/11/2023
Sample ID : 49146
Bill/Req. No. : 23065633
Ref Doctor : Dr.CONSULTANT

Test	Result	Bio. Ref. Interval	Units
BLOOD SUGAR FASTING			
PLASMA GLUCOSE FASTING	87.2	60 - 110	mg/dl

***** END OF THE REPORT *****



Sample no.

Dr. VAISHALI YADAV Dr.REETU JADHAV Dr. PARDIP KUMAR S.C.GAUR
CONS.PATHOLOGIST CONS.PATHOLOGIST MICROBIOLOGIST & ICO LAB INCHARGE USER NM SAMAY

(This is only professional opinion and not the diagnosis, Please correlate clinically)

J-Block, Sector-10, Near Court, Faridabad - 121004, Haryana

Tel.: 0129-4200000 E-mail : parkfaridabad@gmail.com

PARK GROUP OF HOSPITALS : West Delhi • South Delhi • Gurgaon • Karnal • Panipat • Hodal • Ambala • Behror



DEPARTMENT OF PATHOLOGY

Patient Name : Mr. VIKASH KUMAR

MR No : 28620

Age/Sex : 40 Years 5 Months 4 Days / Male

Type : OPD

TPA/Corporate : MEDIWHEEL

Bill Date : 15/11/2023

Reporting Date : 15/11/2023

Sample ID : 49146

Bill/Req. No. : 23065633

Ref Doctor : Dr.CONULTANT

Test	Result	Bio. Ref. Interval	Units
BLOOD SUGAR 2 HR. PP			
BLOOD SUGAR P.P.	113.5	80 - 150	mg/dl

***** END OF THE REPORT *****



Sample no.

Dr. VAISHAL YADAV Dr.REETU JADHAV Dr. PARDIP KUMAR S.C.GAUR
CONS.PATHOLOGIST CONS.PATHOLOGIST MICROBIOLOGIST & ICO LAB INCHARGE USER NM SAMAY

(This is only professional opinion and not the diagnosis, Please correlate clinically)

J-Block, Sector-10, Near Court, Faridabad - 121004, Haryana

Tel.: 0129-4200000 E-mail : parkfaridabad@gmail.com

PARK GROUP OF HOSPITALS : West Delhi • South Delhi • Gurgaon • Karnal • Panipat • Hodal • Ambala • Behror



DEPARTMENT OF PATHOLOGY

Patient Name :	Mr. VIKASH KUMAR	Bill Date :	15/11/2023
MR No :	28620	Reporting Date :	15/11/2023
Age/Sex :	40 Years 5 Months 4 Days / Male	Sample ID :	49146
Type :	OPD	Bill/Req. No. :	23065633
TPA/Corporate :	MEDIWHEEL	Ref Doctor :	Dr.CONSULTANT

Test	Result	Bio. Ref. Interval	Units
------	--------	--------------------	-------

BLOOD GROUPING AND rh FACTOR

BLOOD GROUP	* O * Rh POSITIVE
-------------	-------------------

***** END OF THE REPORT *****



Sample no.

Dr. VAISHALI YADAV Dr. REETU JADHAV Dr. PARDIP KUMAR S.C. GAUR
CONS.PATHOLOGIST CONS.PATHOLOGIST MICROBIOLOGIST & ICO LAB INCHARGE USER NM SAMAY

(This is only professional opinion and not the diagnosis, Please correlate clinically)

J-Block, Sector-10, Near Court, Faridabad - 121004, Haryana

Tel.: 0129-4200000 E-mail : parkfaridabad@gmail.com

PARK GROUP OF HOSPITALS : West Delhi • South Delhi • Gurgaon • Karnal • Panipat • Hodal • Ambala • Behror



DEPARTMENT OF PATHOLOGY

Patient Name : Mr. VIKASH KUMAR
MR No : 28620
Age/Sex : 40 Years 5 Months 4 Days / Male
Type : OPD
TPA/Corporate : MEDIWHEEL
Bill Date : 15/11/2023
Reporting Date : 15/11/2023
Sample ID : 49146
Bill/Req. No. : 23065633
Ref Doctor : Dr.CONSULTANT

Test	Result		Bio. Ref. Interval	Units
CBC				
HAEMOGLOBIN	16.3 H	H	12 - 16	gm/dL
PACKED CELL VOLUME	50.7 H	H	35.0 - 50.0	%
RED BLOOD CELL COUNT	5.40		3.5 - 5.5	millions/ μ L
MEAN CORPUSCULAR VOLUME	93.8		83 - 101	fL
MEAN CORPUSCULAR HAEMOGLOBIN	30.2		27 - 31	pg
MEAN CORPUSCULAR HB CONC	32.1 L	L	33 - 37	g/dl
RDW	12.2		11.6 - 14.5	%
TOTAL LEUCOCYTE COUNT	8920		4000-11000	/ μ L
DIFFERENTIAL COUNT				
NEUTROPHILS	42		40.0 - 80.0	%
LYMPHOCYTES	47 H	H	20 - 40	%
MONOCYTES	08		2.0 - 10.0	%
EOSINOPHILS	03		0.0 - 5.0	%
BASOPHILS	00		0.0 - 2.0	%
PLATELET COUNT	2.57		1.50 - 4.50	lac/cumm

***** END OF THE REPORT *****



Sample ID

Dr. VAISHALI YADAV Dr.REETU JADHAV Dr. PARDIP KUMAR S.C.GAUR
 CONS.PATHOLOGIST CONS.PATHOLOGIST MICROBIOLOGIST & ICO LAB INCHARGE USER NM SAMAY

(This is only professional opinion and not the diagnosis, Please correlate clinically)

J-Block, Sector-10, Near Court, Faridabad - 121004, Haryana

Tel.: 0129-4200000 E-mail : parkfaridabad@gmail.com

PARK GROUP OF HOSPITALS : West Delhi • South Delhi • Gurgaon • Karnal • Panipat • Hodal • Ambala • Behror



DEPARTMENT OF PATHOLOGY

Patient Name : Mr. VIKASH KUMAR	Bill Date : 15/11/2023
MR No : 28620	Reporting Date : 15/11/2023
Age/Sex : 40 Years 5 Months 4 Days / Male	Sample ID : 49146
Type : OPD	Bill/Req. No. : 23085633
TPA/Corporate : MEDIWHEEL	Ref Doctor : Dr.CONSULTANT

Test	Result	Bio. Ref. Interval	Units
------	--------	--------------------	-------

HB A1C GLYCOSYLATED HAEMOGLOBIN

HBA1C	5.9		%
-------	-----	--	---

Note : Non-Diabetics 4.0 - 6.0 %

In Diabetics

Good Control 6.1 - 6.8 %

Fair Control 6.9 - 7.6 %

Poor Control > 7.6 %

***** END OF THE REPORT *****



Sample no.

Dr. VAISHALI YADAV Dr.REETU JADHAV Dr. PARDIP KUMAR S.C.GAUR
CONS.PATHOLOGIST CONS.PATHOLOGIST MICROBIOLOGIST & ICO LAB INCHARGE USER NM DEEPCHAND

(This is only professional opinion and not the diagnosis, Please correlate clinically)

J-Block, Sector-10, Near Court, Faridabad - 121004, Haryana

Tel.: 0129-4200000 E-mail : parkfaridabad@gmail.com

PARK GROUP OF HOSPITALS : West Delhi • South Delhi • Gurgaon • Karnal • Panipat • Hodal • Ambala • Behror



DEPARTMENT OF PATHOLOGY

Patient Name : Mr. VIKASH KUMAR
MR No : 28620
Age/Sex : 40 Years 5 Months 4 Days / Male
Type : OPD
TPA/Corporate : MEDIWHEEL
Bill Date : 15/11/2023
Reporting Date : 15/11/2023
Sample ID : 49146
Bill/Req. No. : 23065633
Ref Doctor : Dr.CONULTANT

Test	Result	Bio. Ref. Interval	Units
LFT (LIVER FUNCTION TEST)			
LFT			
TOTAL BILIRUBIN	0.7	0 - 1.2	mg/dL
DIRECT BILIRUBIN	0.3	0 - 0.4	mg/dL
INDIRECT BILIRUBIN	0.4	0.10 - 0.6	mg/dL
SGOT (AST)	30.3	0 - 45	U/L
SGPT (ALT)	41.4	0 - 45	U/L
ALKALINE PHOSPHATASE	132.0	30 - 170	IU/L
TOTAL PROTEIN	7.2	6.4 - 8.0	g/dL
ALBUMIN	4.5	3.3 - 5.5	g/dL
GLOBULIN	2.7	2.3 - 4.5	g/dL
A/G RATIO	1.67	1.1 - 2.2	

***** END OF THE REPORT *****



Sample no.

Dr. VAISHALI YADAV Dr. REETU JADHAV Dr. PARDIP KUMAR S.C. GAUR
 CONS. PATHOLOGIST CONS. PATHOLOGIST MICROBIOLOGIST & ICO LAB INCHARGE USER NM SAMAY

(This is only professional opinion and not the diagnosis. Please correlate clinically)

J-Block, Sector-10, Near Court, Faridabad - 121004, Haryana

Tel.: 0129-4200000 E-mail : parkfaridabad@gmail.com

PARK GROUP OF HOSPITALS : West Delhi • South Delhi • Gurgaon • Karnal • Panipat • Hodal • Ambala • Behror



DEPARTMENT OF PATHOLOGY

Patient Name : Mr. VIKASH KUMAR
MR No : 28620
Age/Sex : 40 Years 5 Months 4 Days / Male
Type : OPD
TPA/Corporate : MEDIWHEEL

Bill Date : 15/11/2023
Reporting Date : 15/11/2023
Sample ID : 49146
Bill/Req. No. : 23065633
Ref Doctor : Dr.CONULTANT

Test	Result	Bio. Ref. Interval	Units
KFT (RENAL PROFILE)			
KFT			
SERUM UREA	25.0	10 - 45	mg/dL
SERUM CREATININE	0.9	0.4 - 1.4	mg/dL
SERUM URIC ACID	5.7	2.5 - 7.0	mg/dL
SERUM SODIUM	140.3	136 - 148	mmol/L
SERUM POTASSIUM	4.7	3.5 - 5.5	mmol/L
CHLORIDE	101.0	96 - 106	mmol/L

***** END OF THE REPORT *****



Sample no.

Dr. VAISHALI YADAV Dr. REETU JADHAV Dr. PARDIP KUMAR S.C. GAUR
CONS. PATHOLOGIST CONS. PATHOLOGIST MICROBIOLOGIST & ICO LAB INCHARGE USER NM SAMAY

(This is only professional opinion and not the diagnosis, Please correlate clinically)

J-Block, Sector-10, Near Court, Faridabad - 121004, Haryana

Tel.: 0129-4200000 E-mail : parkfaridabad@gmail.com

PARK GROUP OF HOSPITALS : West Delhi • South Delhi • Gurgaon • Karnal • Panipat • Hodal • Ambala • Behror



DEPARTMENT OF PATHOLOGY

Patient Name : Mr. VIKASH KUMAR
MR No : 28620
Age/Sex : 40 Years 5 Months 4 Days / Male
Type : OPD
TPA/Corporate : MEDIWHEEL
Bill Date : 15/11/2023
Reporting Date : 16/11/2023
Sample ID : 49146
Bill/Req. No. : 23065633
Ref Doctor : Dr.CONULTANT

Test	Result	Bio. Ref. Interval	Units
------	--------	--------------------	-------

PSA - TOTAL (PROSTATIC SPECIFIC ANTIGEN) - CANCER MARKER

PROSTATE SPECIFIC ANTIGEN(PSA)	1.02	0.0 - 4.0	ng/ml
--------------------------------	------	-----------	-------

Method : chemiluminescent immunoassay

Note : Clinical Use: -

An aid in the early detection of Prostate cancer in Male. Follow up and management of Prostate cancer patients. Detect metastatic or persistent disease in patients following surgical or medical treatment of Prostate cancer

Note: -

False negative / positive results are observed in patients receiving mouse monoclonal antibodies for diagnosis or therapy. PSA levels may appear consistently elevated / depressed due to the interference by heterophilic antibodies & non-specific protein binding. PSA values regardless of levels should not be interpreted as absolute evidence of the presence or absence of disease. All values should be correlated with clinical findings and results of other investigations.

***** END OF THE REPORT *****



Sample no.

Dr. VAISHALI YADAV Dr. REETU JADHAV Dr. PARDIP KUMAR S.C. GAUR
 CONS. PATHOLOGIST CONS. PATHOLOGIST MICROBIOLOGIST & IC LAB INCHARGE USER NM DEEPCHAND

(This is only professional opinion and not the diagnosis, Please correlate clinically)

J-Block, Sector-10, Near Court, Faridabad - 121004, Haryana

Tel.: 0129-4200000 E-mail : parkfaridabad@gmail.com

PARK GROUP OF HOSPITALS : West Delhi • South Delhi • Gurgaon • Karnal • Panipat • Hodal • Ambala • Behror



DEPARTMENT OF PATHOLOGY

Patient Name : Mr. VIKASH KUMAR
MR No : 28620
Age/Sex : 40 Years 5 Months 4 Days / Male
Type : OPD
TPA/Corporate : MEDIWHEEL

Bill Date : 15/11/2023
Reporting Date : 15/11/2023
Sample ID : 49146
Bill/Req. No. : 23065633
Ref Doctor : Dr.CONULTANT

Test	Result	Bio. Ref. Interval	Units
------	--------	--------------------	-------

STOOL ROUTINE AND MICROSCOPY

STOOL ROUTINE AND MICROSCOPY

COLOUR	Yellow		
CONSISTENCY	Semi Solid	Formed	
PH	ALKALINE	>= 5.5	
RBCS	NIL	NIL	
CYSTS	NIL	NIL	
OVA	NIL	NIL	
PUS CELLS	1-2/hpf	NIL	
MUCUS	NIL	NIL	

***** END OF THE REPORT *****



Sample no.

Dr. VAISHALI YADAV Dr. REETU JADHAV Dr. PARDIP KUMAR S.C. GAUR
 CONS.PATHOLOGIST CONS.PATHOLOGIST MICROBIOLOGIST & ICO LAB INCHARGE USER NM SAMAY

(This is only professional opinion and not the diagnosis, Please correlate clinically)

J-Block, Sector-10, Near Court, Faridabad - 121004, Haryana

Tel.: 0129-4200000 E-mail : parkfaridabad@gmail.com

PARK GROUP OF HOSPITALS : West Delhi • South Delhi • Gurgaon • Karnal • Panipat • Hodal • Ambala • Behror



DEPARTMENT OF PATHOLOGY

Patient Name : Mr. VIKASH KUMAR

MR No : 28620

Age/Sex : 40 Years 5 Months 4 Days / Male

Type : OPD

TPA/Corporate : MEDIWHEEL

Bill Date : 15/11/2023

Reporting Date : 16/11/2023

Sample ID : 49146

Bill/Req. No. : 23065633

Ref Doctor : Dr. CONSULTANT

Test	Result	Bio. Ref. Interval	Units
------	--------	--------------------	-------

THYROID PROFILE

TRI-IODOTHYRONINE (T3)	1.59	0.60 - 1.81	ng/ml
THYROXINE (T4)	10.6	5.01 - 12.45	µg/dL
THYROID STIMULATING HORMONE	3.26	0.5-5.50	µIU/ml

**** END OF THE REPORT ****



Sample no.

Dr. VAISHALI YADAV Dr. REETU JADHAV Dr. PARDIP KUMAR S.C. GAUR
CONS. PATHOLOGIST CONS. PATHOLOGIST MICROBIOLOGIST & ICO LAB INCHARGE USER NM DEEPCHAND

(This is only professional opinion and not the diagnosis, Please correlate clinically)

J-Block, Sector-10, Near Court, Faridabad - 121004, Haryana

Tel.: 0129-4200000 E-mail : parkfaridabad@gmail.com

PARK GROUP OF HOSPITALS : West Delhi • South Delhi • Gurgaon • Karnal • Panipat • Hodal • Ambala • Behror



DEPARTMENT OF PATHOLOGY

Patient Name : Mr. VIKASH KUMAR

MR No : 28620

Age/Sex : 40 Years 5 Months 4 Days / Male

Type : OPD

TPA/Corporate : MEDIWHEEL

Bill Date : 15/11/2023

Reporting Date : 15/11/2023

Sample ID : 49146

Bill/Req. No. : 23065633

Ref Doctor : Dr.CONSULTANT

Test	Result	Bio. Ref. Interval	Units
URINE ROUTINE AND MICROSCOPY			
PHYSICAL CHARACTERSTICS			
QUANTITY	40.0 ML	5 - 100	ML
COLOUR	Pale Yellow		
TURBIDITY	Turbid	clear	
SPECIFIC GRAVITY	1.010	1.003 - 1.030	
PH	7.0	Acidic	
CHEMICAL EXAMINATION-1			
URINE PROTEIN	NIL	NIL	
GLUCOSE	NIL	NIL	
MICRO.EXAMINATION			
PUS CELL	1 - 2/HPF		CELLS/HPF
RED BLOOD CELLS	Nil	0-2	CELLS/HPF
EPITHELIAL CELLS	2-4/HPF	0-5	CELLS/HPF
CASTS	NIL	NIL	CELLS/HPF
CRYSTALS	NIL	NIL	CELLS/HPF
OTHER	NIL		

***** END OF THE REPORT *****



Sample no.

Dr. VAISHALI YADAV Dr. REETU JADHAV Dr. PARDIP KUMAR S.C. GAUR
 CONS. PATHOLOGIST CONS. PATHOLOGIST MICROBIOLOGIST & ICO LAB INCHARGE USER NM SAMAY

(This is only professional opinion and not the diagnosis, Please correlate clinically)

J-Block, Sector-10, Near Court, Faridabad - 121004, Haryana

Tel.: 0129-4200000 E-mail : parkfaridabad@gmail.com

PARK GROUP OF HOSPITALS : West Delhi • South Delhi • Gurgaon • Karnal • Panipat • Hodal • Ambala • Behror



ECHO REPORT

Name of the patient: MR: VIKASH KUMAR Age: 40 Sex: Male Female

UHID No: 28620 IPD No: 23065633 Date: 15/11/2023

Refer By Doctor: DR RAKESH ARORA

LVEF% 60-1

2D ECHO

> Mitral Value Normal Pulmonary Value H Pulm
 > Artery H
 > Aortic avive H Tricuspid valve H

2D RWMA

> NO RWMA (Regional wall motion abnormality) at rest

COLD DOPPLER

> NO Significant Vavular stenosis / Regurgiation

COMMENTS AND SUMMARY

> All cardiac chambers of H size and shape NO dilatation or hypertrophy.
 > NO RWMA (Regional wall motion abnormality) at rest
 > NO Cloth / Vegetation/ pericardial effusion
 > LV 60-1 Systolic function
 > NO Significant Vavular stenosis / Regurgiation

Final Impression

> EF at Rest 60-1

COMMENTS

2DECHO & Color Doppler study was

Consultant Cardiology
 Doctor Name : Dr.
 Date :

Signature
 Time

Dr. Rakesh Kumar Arora
 MBBS, MD, DM (Cardiology)
 Reg No. DMC - 16300
 Consultant - Cardiology
 Park Hospital, Faridkot, India

J BLOCK SEC-10, FARIDABAD
 28620/MR. VIKASH KUMAR
 40 Yrs/Male
 65 Kg/165 Cms
 Date: 15-Nov-2023 11:37:57 AM

HR: 96 bpm
 METS: 1.0
 BP: 120/80

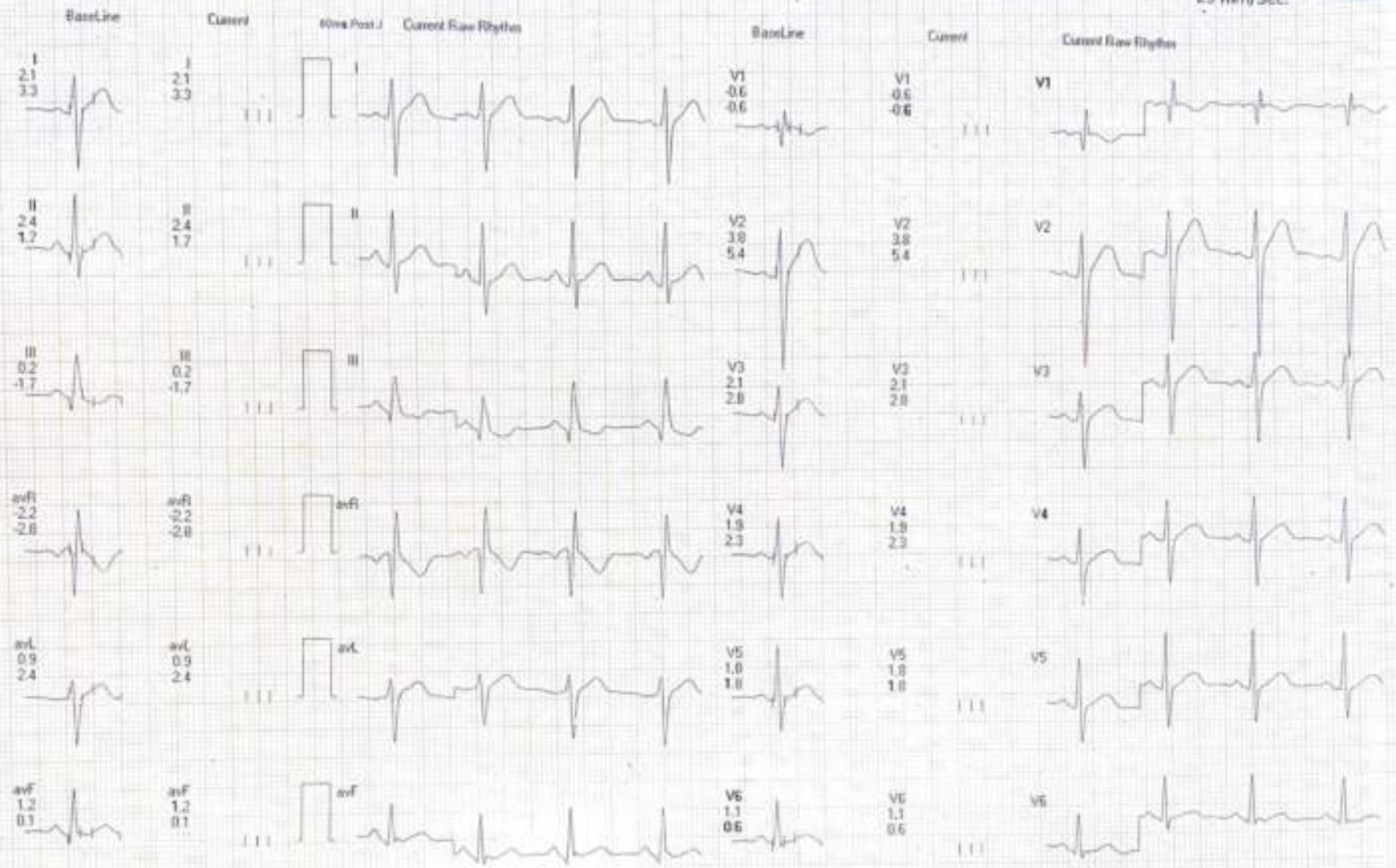
MPHR: 53% of 180
 Speed: 0.0 mph
 Grade: 0.0%

12 Lead + Comparision

Raw ECG
 □□□□□□□□
 (0.05-100)Hz

Ex Time 00:00
 BLC :On
 Notch :On

ExStrt
 10.0 mm/mV
 25 mm/Sec.





28620/MR. VIKASH KUMAR 40 Yrs/Male 65 Kg/165 Cms
Date: 15-Nov-2023 11:37:57 AM
15-Nov-2023 11:37:57 AM
Ref. By : DR. RAKESH ARORA

Protocol : BRUCE Objective :

Stage	StageTime (Min:Sec)	PhaseTime (Min:Sec)	Speed (mph)	Grade (%)	METS	H.R. (bpm)	B.P. (mmHg)	R.P.P. %100	PVC	Comments
ExStart					1.0	96	—/—	0	-	
Stage 1	3:00	3:01	1.7	10.0	4.7	120	—/—	0	-	
Stage 2	3:00	6:01	2.5	12.0	7.1	146	—/—	0	-	
Stage 3	3:00	9:01	3.4	14.0	10.2	171	—/—	0	-	
PeakEx	0:30	9:31	4.2	16.0	10.8	184	—/—	0	-	
Recovery	1:00		0.0	0.0	4.3	145	—/—	0	-	
Recovery	3:00		0.0	0.0	1.0	115	—/—	0	-	

Medication :
History :
Test End Reason :
Findings :

The patient exercised according to BRUCE for 9:31, achieving a work level of Max METS:10.8. Resting heart rate initially 96 bpm, rose to a max. heart rate of 184 bpm which represents 102% of maximum age predicted heart rate. Resting blood pressure 0/0 mmHg, rose to a maximum blood Pressure of 0/0 mmHg. The exercise stress test was stopped due to

Parameters :
Exercise Time :09:31
Max HR Attained :184 bpm 102% of Max Predictable HR 180
Max BP :0/0(mmHg)
Max WorkLoad attained :10.8(Good Effort Tolerance)

IT is Negative for Inducible Ischaemia.






*Arora
15/11/23*

Advice/Comments :

Amplitude

Amplitude

Amplitude



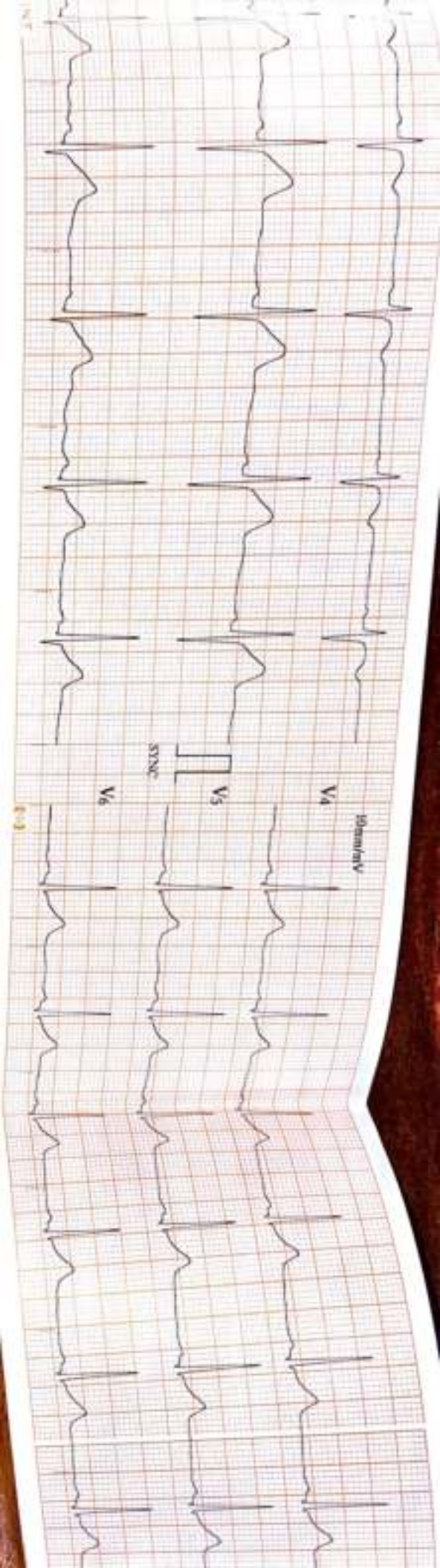


Fig 3

HR	: 63	bpm
R-R	: 951	ms
P-R	: 140	ms
QRS	: 95	ms
QT/QTc	: 374/383	ms
P/QRS/T	: 16/53/50	°
RV5/SV1	: 1.420/0.730	mV
RV5+SV1	: 2.150	mV

----- Sinus Rhythm

----- Unspecified ST-T Abnormality

verified by: