

Metro Hospital & Heart Institute, Haridwar

Health Check-up Certificate

COMPANY..... Mediwheel (PVT) Ltd

EMPLOYEE NO... 182839 DEPTT... operation DATE... 25-3-23

NAME... Mrs. Ashwini Agrawal AGE/SEX... 26y/f DOB... 14-11-96

DESIGNATION... Clerical MOBILE NO... 7451082090

CHEST (INSP)... ✓ cm. CHEST (EXP)... ✓ cm. CHEST EXPANSION... cm

HEIGHT... 149.5 cm. WEIGHT... 54 Kg. BMI.....

P/R... 72 per mt. BP... 120/80 mmHg SIGN OF EMP... Ashwini

EXAMINATION/INVESTIGATIONS

No	Investigations	Room No	Result
1	LAB INVESTIGATIONS	Path Lab	Hb <u>9.0 gm/l</u>
	BLOOD SUGAR F/PP/RANDOM	Path Lab	TLC <u>6250</u> /DLC <u>69-1</u> /SI <u>11</u> /G.C <u>2.9</u>
	BLOOD GROUP	Path Lab	F <u>89</u> /PP <u>97.0</u> /RBS <u>NA</u> /C <u>5.0</u>
2	URINE	Path Lab	<u>B+</u>
3	STOOL	Path Lab	<u>ALB NIL / Sugar NIL</u>
4	X RAY CHEST PA	Radiology	<u>CNR</u>
5	ULTRASONOGRAPHY (Whole Abd)	Radiology	<u>NO AD</u>
6	ECG	Health check up	<u>Normal study.</u>
7	ECHO	Radiology	<u>Normal study.</u>
8	TMT	Health check up	<u>---</u>
9	PFT	Health check up	<u>---</u>
10	AUDIOMETRY	25	<u>---</u>
11	ENT EXAM	25	<u>---</u>
12	DENTAL EXAMINATION	24	<u>---</u>
13	ACUITY OF VISION/COLOUR VISION	13	<u>---</u>
14	EXAMINATION BY PHYSICIAN	23	<u>---</u>

Observations - PAP Smear
Thyroid Profile
Lipid Profile
 Advice - KFT
LFT
Adv to Consultant Physician for TSH

Dr. Anil Singh, MBS, AFH, DHA
 Occupational Health Specialist
 Reg No 2331/IKMC



METRO HOSPITAL & HEART INSTITUTE

(A unit of Sunhill Hospitals Private Ltd.), CIN No. U33201DL2006PTC156918

Reg. Off : 21, Community Centre, Preet Vihar, Delhi - 92

GST No.: 05AAKCS5409G1ZD

Plot No. F-1, Sector-6A, SIDCUL, Ranipur, Haridwar (UK) - 249403, www.metrohospitals.com

Phone No.: 01334-239040, 239042, 239053

BILL OF SUPPLY (OUTPATIENT CREDIT BILL)


Bill No	: MHWOP/202230527	Date/Time	: 25/03/2023 09:51
Name	: Mrs. ASHWINI AGRAWAL	UHID	: MHWID/2023005112
Age/Sex	: 26 Y /Female	Category	: CASH
Address	: Mediwheel, Haridwar Uttarakhand India	Req. Dr.	: Dr. ANIL SINGH
Tel	: 7451082090		
Comp Name	: MEDIWHEEL#ARCOFEMI HEALTH LTD. (MEDIWHEEL_HARIDWAR)		

HEALTH CARE SERVICES	Req. No.	AMOUNT(Rs.)
Package - MediWheel Full Body Health Checkup Female Below 40(Rs.1900)Feb2022		1900.00
CBC (COMPLETE BLOOD COUNT/HAEMOGRAM)	10344628	
ESR	10344628	
URINE ROUTINE ANALYSIS	10344628	
STOOL ROUTINE EXAMINATION	10344628	
BLOOD GROUP	10344628	
BLOOD SUGAR -FASTING	10344628	
URINE SUGAR	10344628	
BLOOD SUGAR -PP	10344628	
HB1AC	10344628	
THYROID PROFILE	10344628	
LIPID PROFILE	10344628	
KFT (KIDNEY FUNCTION TEST)	10344628	
LFT (LIVER FUNCTION TEST)	10344628	
ECG	80101165	
TMT/ECHO	80101165	
X-RAY CHEST PA View	70223698	
USG WHOLE ABDOMEN	70223698	
PAP SMEAR	10344628	
Dr. Physician Consultation {Second Visit}	Patient No 3	
Dr. Eye Consultation {Second Visit}	Patient No 3	

Bill Amount: 1900.00
Net Bill Amt Credit: 1900.00

Credit Bill Towards **MEDIWHEEL#ARCOFEMI HEALTH LTD.** an Amount of Rupees One Thousand Nine Hundred Only

Signature of Patient/Attendant.....
Relation with patient-
Contact No-
Run Date : 25/03/2023 09:51



Mrs Ashwini Agrawal
26/1/25
25-3-23

UN 71 bpm

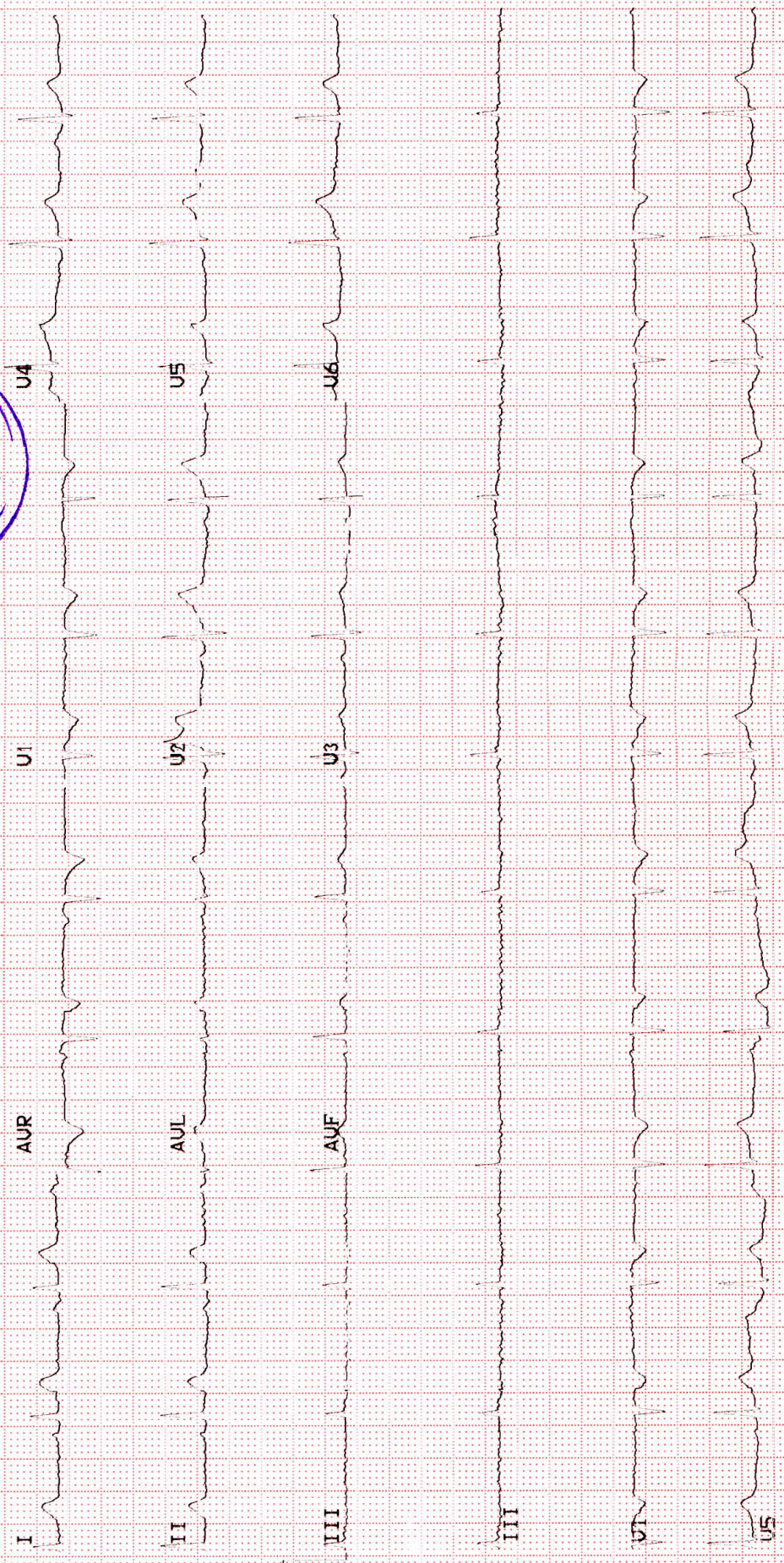
Measurement Results:

QRS	74 ms	< P
QT/QTcB	360 / 390 ms	< T
PR	148 ms	< QRS
P	88 ms	aL
RR/PP	850 / 850 ms	0 I
P/QRS/T	35/ 10/ 25 degrees	
QT/QTcBD	24 / 26 ms	III +90 II
Sokolow	1.2 mV	aUF
NK	9	

Interpretation:
Low QRS amplitudes
R/S inversion area between V1 and V2
probably abnormal ECG



Unconfirmed report





Metro Hospital & Heart Institute

(A unit of Sunhill Hospital Private Limited)

OPD CONSULTATION

Patient Name ms. Ashwani Arora Age/Sex 26/f Reg. No. _____

Doctor's Name dr. Subul

Date 25/05/25 Time _____

OPHTHALMIC EXAMINATION

VISION

DISTANCE VISION-

eglem Rt 6/6
Lt 6/6

NEAR VISION-

Rt M16
Lt M16

COLOUR VISION

Normal

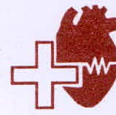EYE EXAMINATION

- Cornea
- Ant Chamber
- Pupil
- Fundus Examination

W.M.L

ADVICE-



**METRO****HOSPITAL & HEART INSTITUTE**

(A unit of Sunhill Hospitals Private Limited)

(NABH & ISO 9001: 2008 Certified)

Radiology Investigation Report

Name : Mrs. ASHWINI AGRAWAL
Ref. By : Dr. ANIL SINGH
IP/OP : OP/202230527
Date : 25/03/2023

Age/Sex : 26 Y/F
UHID NO : 2023005112
Request No : 70223698

X-RAY CHEST PA View

Trachea is central.

Bilateral hila are normal in size & density.

Cardiac silhouette is normal.

Bilateral lung fields are clear.

Bilateral Costophrenic angles are normal.

Bilateral domes of diaphragm are normal in position & contour.

Bones and soft tissues are normal.

IMPRESSION : Normal skiagram

DR. PRAKASH CHANDRA PANDEY
MBBS, DMRD
CONSULTANT RADIOLOGIST

Note:

- (1) Not Valid for medical-legal purposes.
- (2) This is a professional opinion based on imaging finding and not the diagnosis.
- (3) In case of any discrepancy due to machine error or typing error, please get it rectified immediately.

Plot No. F-1, Sector-6A, SIDCUL, Haridwar - 249 403

Emergency : +91 8191902600, Phone : 01334 - 239040 / 42 / 43, Fax : 01334 - 239043

E-mail : metroharidwar@metrohospitals.com, Website: www.metrohospitals.com

Regd. Office : 21, Community Center, Preet Vihar, New Delhi-110092

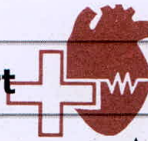
CIN No.: U33201DL2006PTC156918

MHHI/CL/0115/Rev. No. 01

27-Mar-23 11:09 AM



Pathology Report



METRO PATH LABS

Name : Mrs. ASHWINI AGRAWAL
 Ref. By : Dr. ANIL SINGH
 IP/OP : OP/202230527
 Sample Date : 25/03/2023
 Reporting Date: 25/03/2023

Age/Sex : 26 Y/F
 UHID : 2023005112
 Request No. : 10344928
 Sample Time : 09:58
 Reporting Time : 20:54

Test Result Unit Bio. Ref. Inter. Test Method

Hematology

BLOOD GROUP

ABO : B
 Rh : POSITIVE
 ESR : 18 mm/hr 20

Serology & Immunology

THYROID PROFILE

T3 : 2.38 nmol/L 1.70-3.10
 T4 : 12.8 µg/dl 5.95-15.4
 TSH : 4.70 µIU/L 0.46-4.68

Urine Examination

URINE ROUTINE ANALYSIS

PHYSICAL EXAMINATION

COLOUR : STRAW
 TRANSPARENCY : S.TURBID
 S. GRAVITY : 1.015

CHEMICAL EXAMINATION

ALBUMIN : NIL
 SUGAR : NIL
 pH : 7.0
 BLOOD : NIL
 KETONE : NIL

MICROSCOPIC EXAMINATION

PUS CELLS : 2-3
 EPITHELIAL CELLS : 6-7
 RBC : NIL
 CRYSTALS : NIL
 CAST : NIL
 BACTERIA : NIL
 AMORPHOUS PHOSPHATE : NIL
 AMORPHOUS URATES : NIL

*** End of Reports ***

Dr. Vishal Arora
 MBBS, DCP
 (Consultant Pathologist)



Note:


1. These reports are mere estimation of values at that particular time and are liable to vary/change in different conditions in different laboratories.
2. The values are to be collaborated with clinical findings by qualified doctor and any alarming and unexpected results should be reported to Lab urgently for recheck and manual typing errors.
3. These reports are not valid for medicolegal purposes and all doctor unsigned reports should be considered provisional only.
4. All card based tests are screening test therefore need confirmation by other alternative test like (PCR, ELISA).

Plot No. F-1, Sector-6A, SIDCUL, Haridwar - 249 403

Emergency : 91 8191902600, Phone : 01331-239040 / 43 / 43 Fax : 01331-239043

E-mail : metroharidwar@metrohospitals.com, Website: www.metrohospitals.com

Pathology Report



METRO PATH LABS

Name : Mrs. ASHWINI AGRAWAL
 Ref. By : Dr. ANIL SINGH
 IP/OP : OP/202230527
 Sample Date : 25/03/2023
 Reporting Date: 25/03/2023

Age/Sex : 26 Y/F
 UHID : 2023005119
 Request No. : 10344628
 Sample Time : 09:58
 Reporting Time : 20:54

Test	Result	Unit	Bio. Ref. Inter.	Test Method
Biochemistry				
HB1AC	5.8	%	4.5-6.3	
BLOOD SUGAR -FASTING	89.0	mg/dl	70.0-110.0	
BLOOD SUGAR -PP	97.0	mg/dl	70.0-140.0	
LIPID PROFILE				
TOTAL CHOLESTEROL	137.0	mg/dl	00-250.0	
HDL-CHOLESTEROL	40.0	mg/dl	00-50.0	
LDL	76.0	mg/dl	00-150.0	
TRIGLYCERIDES	105.0	md/dl	30-150	
VLDL	21.0	mg/dl	0-50	
CHOL/HDL Ratio	3.4		<4.5	
LFT (LIVER FUNCTION TEST)				
BILIRUBIN INDIRECT	0.30	mg/dl	0.2-0.8	
SGOT	24.0	U/L	10-42	
SGPT	21.0	U/L	10-42	
BIILIRUBIN TOTAL	0.60	mg/dl	0.2-1.0	
ALKALINE PHOSPHATASE	90.0	IU/L	28-111	
BILIRUBIN DIRECT	0.30	mg/dl	0.1-0.4	
TOTAL PROTEIN	6.7	gm/dl	6.4-8.2	
ALBUMIN	3.7	g/dl	3.5-5.0	
GLOBULIN	3.0	gm/dl	2.0-4.0	
AG RATIO	1.1		-	
KFT (KIDNEY FUNCTION TEST)				
UREA	25.8	mg/dl	15-45	
SODIUM	138.0	mmol/L	135-155	
CREATININE	0.67	mg/dl	0.6-1.3	
URIC ACID	5.3	mg/dl	3.0-7.6	
BUN	12.2	mg/dl	05-20	
POTTASSIUM	3.8	mmol/L	3.5-5.5	
CALCIUM	8.9	mg/dl	8.5-10.5	

*** End of Reports ***

Dr. Vishal Arora
 MBBS, DCP
 (Consultant Pathologist)

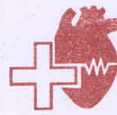**Note:**

1. These reports are mere estimation of values at that particular time and are liable to vary/change in different conditions in different laboratories.
2. The values are to be collaborated with clinical findings by qualified doctor and any alarming and unexpected results should be reported to Lab urgently for recheck and manual typing errors.
3. These reports are not valid for medicolegal purposes and all doctor unsigned reports should be considered provisional only.
4. All card based tests are screening test therefore need confirmation by other alternative test like (PCR, ELISA).

Plot No. F-1, Sector-6A, SIDCUL, Haridwar - 249 403

Emergency : +91 8191902600, Phone : 01334 239040 / 42 / 43, Fax : 01334 239043

E-mail : metroharidwar@metrohospitals.com, Website: www.metrohospitals.com



METRO

HOSPITAL & HEART INSTITUTE

(A unit of Sunhill Hospitals Private Limited)

(NABH & ISO 9001: 2008 Certified)

Radiology Investigation Report

Name : Mrs. ASHWINI AGRAWAL
Ref. By : Dr. ANIL SINGH
IP/OP : OP/202230527
Date : 25/03/2023

Age/Sex : 26 Y/F
UHID NO : 2023005112
Request No : 70223698

USG WHOLE ABDOMEN

The diaphragm is normal in contour & respiratory excursion. There is no ascitis or lymph node mass.

Liver is normal in shape, outline & echotexture. No focal lesion of abnormal ecogenecity is seen. Intrahepat biliary radicles are not dilated. Portal vein & portal venous radicles are normal.

Gall bladder is well distended, its outlines are smooth & its wall are not thick. No calculus /mass lesion is see in its lumen. Common bile duct is normal in course & caliber. No calculus is seen in its lumen.


Spleen & pancreas appears normal in shape, size, outline & echotexture.

Both the kidneys are normal in shape, size, outline & echotexture. Renal parenchymal thickness is norma Corticomedullary junction is defined & is normal. There is no hydronephrosis. **There is right renal calculu measuring approx 3.6 mm.**

Urinary bladder is normal in contour & capacity. Bladder wall is not thick. No pathological filling defect / vesic; calculus is seen in bladder. Ureterovesical junctions appear normal.

Uterus is normal in size shape, outline & echotexture. Myometrial & endometrial echoes are normal. No uterin mass is seen. Both the ovaries appear normal. There is no free fluid seen in cul de sac.

IMPRESSION : Right renal calculus.


DR. PRAKASH CHANDRA PANDEY
MBBS, DMRD
CONSULTANT RADIOLOGIST

Note:

- (1) Not Valid for medical-legal purposes.
- (2) This is a professional opinion based on imaging finding and not the diagnosis.
- (3) In case of any discrepancy due to machine error or typing error, please get it rectified immediately.

Plot No. F-1, Sector-6A, SIDCUL, Haridwar - 249 403

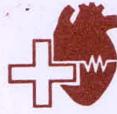Emergency : +91 8191902600, Phone : 01334 - 239040 / 42 / 43, Fax : 01334 - 239043

E-mail : metroharidwar@metrohospitals.com, Website: www.metrohospitals.com

Regd. Office : 21, Community Center, Preet Vihar, New Delhi-110092

CIN No.: U33201DL2006PTC156918

MHHI/CL/0115/Rev. No. 01



METRO

HOSPITAL & HEART INSTITUTE

(A unit of Sunhill Hospitals Private Limited)

(NABH & ISO 9001: 2008 Certified)

2D ECHOCARDIOGRAPHY

Name:	Mrs. Ashwini Agrawal	UHID No:	2023005712
Age/Sex:	26Y/F	Ward:	OPD
Referred by:	Dr. Anil Singh	Date:	25.03.2023

ACOUSTIC WINDOW: Normal

MEASUREMENTS AND CALCULATIONS

Measurements	Observed Value	Reference Value
IVS (ED)	0.8	(0.6 – 1.1 cm)
LVPW (ED)	0.9	(0.6 – 1.1 cm)
LVID (ED)	3.7	Male (3.7 – 5.5 cm) Female (3.7 – 5.2 cm)
Aortic root diameter	2.1	(2.0 – 3.7 cm)
LA dimension	2.1	Male (1.9 – 4.0 cm) Female (1.7 – 3.8 cm)
LV EF	60%	(55 – 75%)

MORPHOLOGICAL DATA

Mitral valve	Normal	Right Atrium	Normal
Aortic valve	Normal	Right Ventricle	Normal
Tricuspid valve	Normal	PA	Normal
Pulmonary valve	Normal	IVS	Intact
		IAS	Intact

DOPPLER STUDY

Valve	Regurges	Velocities (cm/s)	Gradients (mmHg)
Mitral	Nil	E – 87, A – 62, E/A>1	
Aortic	Nil	Vel – 126	
Tricuspid	Trace	Vel – 209	PASP – 22
Pulmonary	Nil	Vel – 123	

Plot No. F-1, Sector-6A, SIDCUL, Haridwar - 249 403

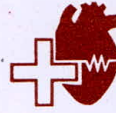Emergency : +91 8191902600, Phone : 01334 - 239040 /42 / 43, Fax : 01334 - 239043

E-mail : metroharidwar@metrohospitals.com, Website: www.metrohospitals.com

Regd. Office : 21, Community Center, Preet Vihar, New Delhi-110092

CIN No.: U33201DL2006PTC156918

MHHI/CL/0115/Rev. No. 01



METRO

HOSPITAL & HEART INSTITUTE

(A unit of Sunhill Hospitals Private Limited)
(NABH & ISO 9001: 2008 Certified)

FINAL IMPRESSION

- Normal Acoustic Window
- Normal Chambers Dimensions
- No RWMA
- LVEF~60%
- No LVDD
- Trace TR, PASP 22 mmHg
- No pericardial effusion
- No Intracardiac clot

Dr. Krishna CK

MD, DNB (Medicine), DNB (Cardiology)
Consultant Interventional Cardiology
UKMC Reg. No: 12883



Dr. Ajit Kumar

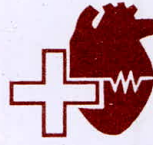MBBS, PGDCC
Associate Consultant, Cardiology
UKMC Reg. No: 7569

(Note: This document is not for medico-legal purpose)

Plot No. F-1, Sector-6A, SIDCUL, Haridwar - 249 403
Emergency : +91 8191902600, Phone : 01334 - 239040 / 42 / 43, Fax : 01334 - 239043
E-mail : metroharidwar@metrohospitals.com, Website: www.metrohospitals.com

Regd. Office : 21, Community Center, Preet Vihar, New Delhi-110092
CIN No.: U33201DL2006PTC156918

MHHI/CL/0115/Rev. No. 01



METRO PATH LABS

(A unit of Sunhill Hospitals Private Limited)

(ISO & NABH Certified)

CIN No.: U33201DL2006PTC156918

Patient Name : **Mr. ASHWANI AGARWAL**
DOB/Age/Gender : 26 Year's /Male
Pateint ID : --- 11
Referred By : **Dr.**

Sample Collected Date : Mar,25/2023
Report Date : Mar,25/2023
Report Time : 07:12 PM

Test Description	Value(S)	Unit(S)	Refrence Range
------------------	----------	---------	----------------

Complete Blood Count &:{C.B.C.} HAEMATOLOGY

Hemoglobin:-	9.8	mg/dl	12.5---16.5
T L C:-	6.250	Cells/cumm	4.000—11.000
D L C:-			
Neutrophils:-	69.1	%	45 - 75
Lymphocytes:-	21.4	%	25 - 45
Eosinophils:-	6.6	%	1 - 6
Monocytes:-	2.90	%	2 - 8
Basophils:-	0.00	%	---<2
RED BLOOD CELLS Count:R.B.C:	4.06	Million/cu/mm	3.5 - 5.5
PACKED CELL VOLUME {HCT} P.C.V	36.8	%	36 - 52
MEAN CELLS VOLUME:(M.C.V):	82.5	fl	80 - 100
MEAN CELLS HEMOGLOBIN:M.C.H	21.4	pg	27 - 32
MEAN CELLS HEMGRAM CONCENTRATION:-M.C.H.C: 28.9		gm/dl	31 - 37
PLATELETS COUNT:-	2.77	Lakh/cu mm	1.50 - 4.50
RDW:-	15.1	%	11.5 - 15.0

End Of Report



Plot No. F-1, Sector-6A, SIDCUL, Haridwar - 249 403
Emergency : +91 8191902600, Phone : 01334 - 239040 / 42 / 43, Fax : 01334 - 239043
E-mail : metroharidwar@metrohospitals.com, Website: www.metrohospitals.com