

# Metro Hospital & Heart Institute, Haridwar

## Health Check-up Certificate

COMPANY..... Mediwheel (PVT) Ltd

EMPLOYEE NO... 182839 DEPTT... Operation DATE... 25-3-23

NAME... Mrs. Ashwini Agrawal AGE/SEX... 26y/f DOB... 14-11-96

DESIGNATION... Clerical MOBILE NO... 7451082090

CHEST (INSP)... ✓ cm. CHEST (EXP)... ✓ cm. CHEST EXPANSION.....cm

HEIGHT... 149.5 cm. WEIGHT... 54 Kg. BMI.....

P/R... 72 per mt. BP... 120/80 mmHg SIGN OF EMP... Ashwini

### EXAMINATION/INVESTIGATIONS

No	Investigations	Room No	Result
1	LAB INVESTIGATIONS	Path Lab	Hb <u>9.0 gm/l</u>
	BLOOD SUGAR F/PP/RANDOM	Path Lab	TLC <u>6250</u> /DLC <u>69-1</u> /SI <u>11</u> /G.C <u>2.9</u>
	BLOOD GROUP	Path Lab	F <u>89</u> /PP <u>97.0</u> /RBS <u>NA</u> /C <u>5.0</u>
2	URINE	Path Lab	<u>B+</u>
3	STOOL	Path Lab	<u>ALB NIL / Sugar NIL</u>
4	X RAY CHEST PA	Radiology	<u>CNR</u>
5	ULTRASONOGRAPHY (Whole Abd)	Radiology	<u>NO AB</u>
6	ECG	Health check up	<u>Normal study.</u>
7	ECHO	Radiology	<u>Normal study.</u>
8	TMT	Health check up	<u>---</u>
9	PFT	Health check up	<u>---</u>
10	AUDIOMETRY	25	<u>---</u>
11	ENT EXAM	25	<u>---</u>
12	DENTAL EXAMINATION	24	<u>---</u>
13	ACUITY OF VISION/COLOUR VISION	13	<u>---</u>
14	EXAMINATION BY PHYSICIAN	23	<u>---</u>

Observations - PAP Smear  
Thyroid Profile  
Lipid Profile  
 Advice - KFT  
LFT  
Adv to Consultant Physician for TSH

Dr. Anil Singh, MBS, AFM, DHA  
 Occupational Health Specialist  
 Reg No 2331/IKMC

Mrs Ashwini Agrawal  
26 Y/F  
25-3-23

UN 71 bpm

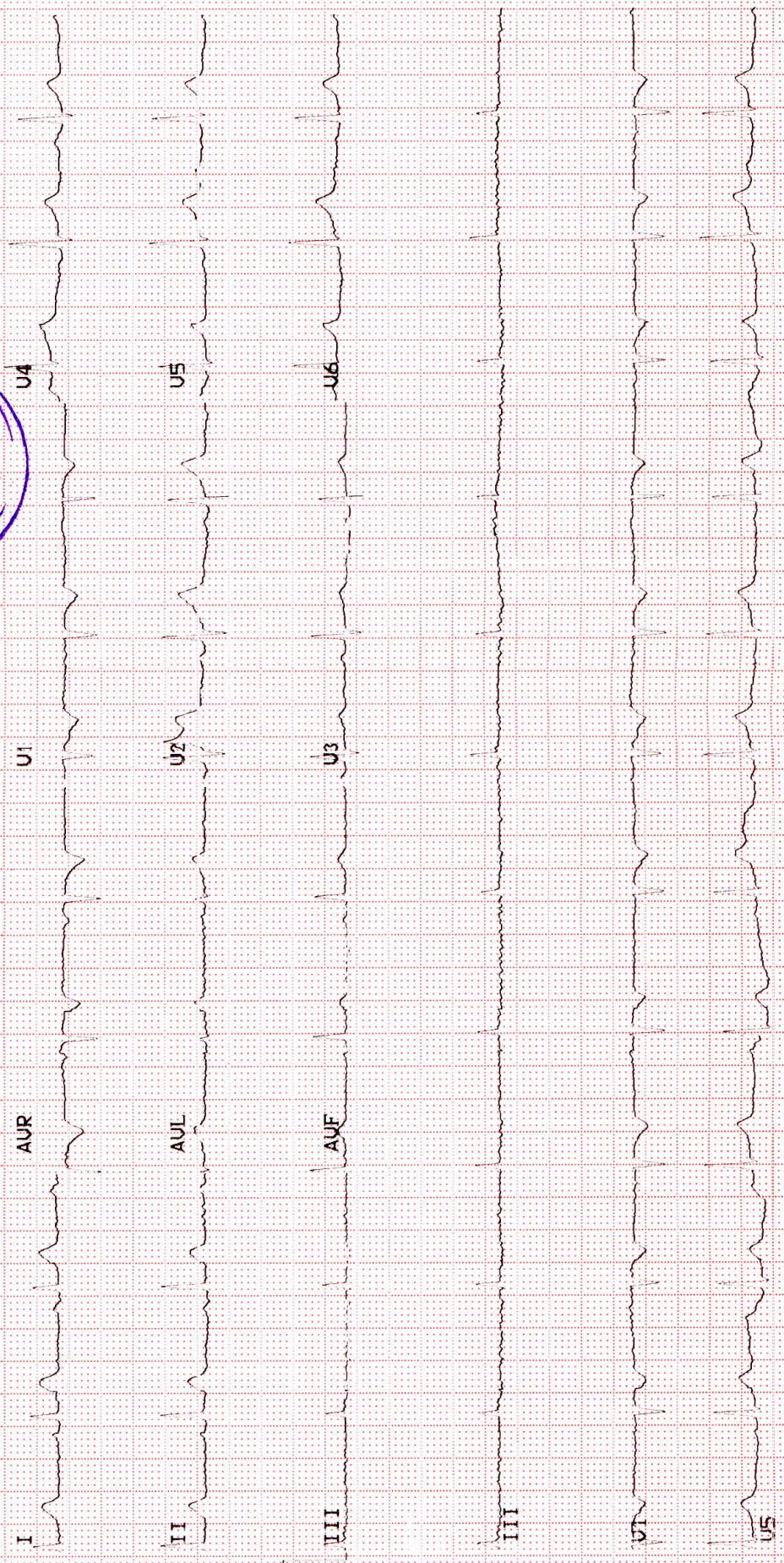
Measurement Results:

QRS	74 ms	< P
QT/QTcB	360 / 390 ms	< T
PR	148 ms	< QRS
P	88 ms	aL
RR/PP	850 / 850 ms	0 I
P/QRS/T	35/ 60/ 25 degrees	
QT/QTcBD	24 / 26 ms	III +90 II
Sokolow	1.2 mV	aUF
NK	9	

Interpretation:  
Low QRS amplitudes  
R/S inversion area between V1 and V2  
probably abnormal ECG



Unconfirmed report





# Metro Hospital & Heart Institute

(A unit of Sunhill Hospital Private Limited)

OPD CONSULTATION

Patient Name ms. Ashwani Arora Age/Sex 26/f Reg. No. \_\_\_\_\_

Doctor's Name dr. Subul

Date 25/05/25 Time \_\_\_\_\_

## OPHTHALMIC EXAMINATION

### VISION

#### DISTANCE VISION-

eglem Rt 6/6  
Lt 6/6

#### NEAR VISION-

Rt M16  
Lt M16

#### COLOUR VISION

Normal

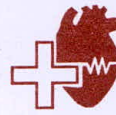### EYE EXAMINATION

- Cornea
- Ant Chamber
- Pupil
- Fundus Examination

W.N.L

#### ADVICE-

Signature

**METRO****HOSPITAL & HEART INSTITUTE**

(A unit of Sunhill Hospitals Private Limited)

(NABH &amp; ISO 9001: 2008 Certified)

**Radiology Investigation Report**

**Name** : Mrs. ASHWINI AGRAWAL  
**Ref. By** : Dr. ANIL SINGH  
**IP/OP** : OP/202230527  
**Date** : 25/03/2023

**Age/Sex** : 26 Y/F  
**UHID NO** : 2023005112  
**Request No** : 70223698

**X-RAY CHEST PA View**

*Trachea is central.*

*Bilateral hila are normal in size & density.*

*Cardiac silhouette is normal.*

*Bilateral lung fields are clear.*

*Bilateral Costophrenic angles are normal.*

*Bilateral domes of diaphragm are normal in position & contour.*

*Bones and soft tissues are normal.*

**IMPRESSION : Normal skiagram**

**DR. PRAKASH CHANDRA PANDEY**  
**MBBS, DMRD**  
**CONSULTANT RADIOLOGIST**

**Note:**

- (1) Not Valid for medical-legal purposes.
- (2) This is a professional opinion based on imaging finding and not the diagnosis.
- (3) In case of any discrepancy due to machine error or typing error, please get it rectified immediately.

Plot No. F-1, Sector-6A, SIDCUL, Haridwar - 249 403

Emergency : +91 8191902600, Phone : 01334 - 239040 / 42 / 43, Fax : 01334 - 239043

E-mail : metroharidwar@metrohospitals.com, Website: www.metrohospitals.com

Regd. Office : 21, Community Center, Preet Vihar, New Delhi-110092

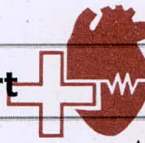
CIN No.: U33201DL2006PTC156918

MHHI/CL/0115/Rev. No. 01

27-Mar-23 11:09 AM



## Pathology Report



# METRO PATH LABS

Name : Mrs. ASHWINI AGRAWAL  
 Ref. By : Dr. ANIL SINGH  
 IP/OP : OP/202230527  
 Sample Date : 25/03/2023  
 Reporting Date: 25/03/2023

Age/Sex : 26 Y/F  
 UHID : 2023005119  
 Request No. : 10344628  
 Sample Time : 09:58  
 Reporting Time : 20:54

Test	Result	Unit	Bio. Ref. Inter.	Test Method
<b>Biochemistry</b>				
HB1AC	5.8	%	4.5-6.3	
BLOOD SUGAR -FASTING	89.0	mg/dl	70.0-110.0	
BLOOD SUGAR -PP	97.0	mg/dl	70.0-140.0	
<b>LIPID PROFILE</b>				
TOTAL CHOLESTEROL	137.0	mg/dl	00-250.0	
HDL-CHOLESTEROL	40.0	mg/dl	00-50.0	
LDL	76.0	mg/dl	00-150.0	
TRIGLYCERIDES	105.0	md/dl	30-150	
VLDL	21.0	mg/dl	0-50	
CHOL/HDL Ratio	3.4		<4.5	
<b>LFT (LIVER FUNCTION TEST)</b>				
BILIRUBIN INDIRECT	0.30	mg/dl	0.2-0.8	
SGOT	24.0	U/L	10-42	
SGPT	21.0	U/L	10-42	
BIILIRUBIN TOTAL	0.60	mg/dl	0.2-1.0	
ALKALINE PHOSPHATASE	90.0	IU/L	28-111	
BILIRUBIN DIRECT	0.30	mg/dl	0.1-0.4	
TOTAL PROTEIN	6.7	gm/dl	6.4-8.2	
ALBUMIN	3.7	g/dl	3.5-5.0	
GLOBULIN	3.0	gm/dl	2.0-4.0	
AG RATIO	1.1		-	
<b>KFT (KIDNEY FUNCTION TEST)</b>				
UREA	25.8	mg/dl	15-45	
SODIUM	138.0	mmol/L	135-155	
CREATININE	0.67	mg/dl	0.6-1.3	
URIC ACID	5.3	mg/dl	3.0-7.6	
BUN	12.2	mg/dl	05-20	
POTTASSIUM	3.8	mmol/L	3.5-5.5	
CALCIUM	8.9	mg/dl	8.5-10.5	

\*\*\* End of Reports \*\*\*

**Dr. Vishal Arora**  
 MBBS, DCP  
 (Consultant Pathologist)

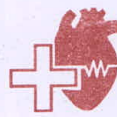
**Note:**

1. These reports are mere estimation of values at that particular time and are liable to vary/change in different conditions in different laboratories.
2. The values are to be collaborated with clinical findings by qualified doctor and any alarming and unexpected results should be reported to Lab urgently for recheck and manual typing errors.
3. These reports are not valid for medicolegal purposes and all doctor unsigned reports should be considered provisional only.
4. All card based tests are screening test therefore need confirmation by other alternative test like (PCR, ELISA).

Plot No. F-1, Sector-6A, SIDCUL, Haridwar - 249 403

Emergency : +91 8191902600, Phone : 01334 239040 / 42 / 43, Fax : 01334 239043

E-mail : metroharidwar@metrohospitals.com, Website: www.metrohospitals.com



# METRO

## HOSPITAL & HEART INSTITUTE

(A unit of Sunhill Hospitals Private Limited)

(NABH & ISO 9001: 2008 Certified)

### Radiology Investigation Report

<b>Name</b>	: Mrs. ASHWINI AGRAWAL	<b>Age/Sex</b>	: 26 Y/F
<b>Ref. By</b>	: Dr. ANIL SINGH	<b>UHID NO</b>	: 2023005112
<b>IP/OP</b>	: OP/202230527	<b>Request No</b>	: 70223698
<b>Date</b>	: 25/03/2023		

#### USG WHOLE ABDOMEN

The diaphragm is normal in contour & respiratory excursion. There is no ascitis or lymph node mass.

Liver is normal in shape, outline & echotexture. No focal lesion of abnormal ecogenecity is seen. Intrahepat biliary radicles are not dilated. Portal vein & portal venous radicles are normal.

Gall bladder is well distended, its outlines are smooth & its wall are not thick. No calculus /mass lesion is see in its lumen. Common bile duct is normal in course & caliber. No calculus is seen in its lumen.


Spleen & pancreas appears normal in shape, size, outline & echotexture.

Both the kidneys are normal in shape, size, outline & echotexture. Renal parenchymal thickness is norma Corticomedullary junction is defined & is normal. There is no hydronephrosis. **There is right renal calculu measuring approx 3.6 mm.**

Urinary bladder is normal in contour & capacity. Bladder wall is not thick. No pathological filling defect / vesic; calculus is seen in bladder. Ureterovesical junctions appear normal.

Uterus is normal in size shape, outline & echotexture. Myometrial & endometrial echoes are normal. No uterin mass is seen. Both the ovaries appear normal. There is no free fluid seen in cul de sac.

**IMPRESSION : Right renal calculus.**

  
**DR. PRAKASH CHANDRA PANDEY**  
**MBBS, DMRD**  
**CONSULTANT RADIOLOGIST**

**Note:**

- (1) Not Valid for medical-legal purposes.
- (2) This is a professional opinion based on imaging finding and not the diagnosis.
- (3) In case of any discrepancy due to machine error or typing error, please get it rectified immediately.

Plot No. F-1, Sector-6A, SIDCUL, Haridwar - 249 403

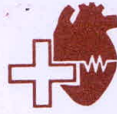Emergency : +91 8191902600, Phone : 01334 - 239040 / 42 / 43, Fax : 01334 - 239043

E-mail : metroharidwar@metrohospitals.com, Website: www.metrohospitals.com

Regd. Office : 21, Community Center, Preet Vihar, New Delhi-110092

CIN No.: U33201DL2006PTC156918

MHHI/CL/0115/Rev. No. 01



# METRO

HOSPITAL & HEART INSTITUTE

(A unit of Sunhill Hospitals Private Limited)

(NABH & ISO 9001: 2008 Certified)

## 2D ECHOCARDIOGRAPHY

Name:	Mrs. Ashwini Agrawal	UHID No:	2023005712
Age/Sex:	26Y/F	Ward:	OPD
Referred by:	Dr. Anil Singh	Date:	25.03.2023

ACOUSTIC WINDOW: Normal

### MEASUREMENTS AND CALCULATIONS

Measurements	Observed Value	Reference Value
IVS (ED)	0.8	(0.6 – 1.1 cm)
LVPW (ED)	0.9	(0.6 – 1.1 cm)
LVID (ED)	3.7	Male (3.7 – 5.5 cm) Female (3.7 – 5.2 cm)
Aortic root diameter	2.1	(2.0 – 3.7 cm)
LA dimension	2.1	Male (1.9 – 4.0 cm) Female (1.7 – 3.8 cm)
LV EF	60%	(55 – 75%)

### MORPHOLOGICAL DATA

Mitral valve	Normal	Right Atrium	Normal
Aortic valve	Normal	Right Ventricle	Normal
Tricuspid valve	Normal	PA	Normal
Pulmonary valve	Normal	IVS	Intact
		IAS	Intact

### DOPPLER STUDY

Valve	Regurges	Velocities (cm/s)	Gradients (mmHg)
Mitral	Nil	E – 87, A – 62, E/A>1	
Aortic	Nil	Vel – 126	
Tricuspid	Trace	Vel – 209	PASP – 22
Pulmonary	Nil	Vel – 123	

Plot No. F-1, Sector-6A, SIDCUL, Haridwar - 249 403

Emergency : +91 8191902600, Phone : 01334 - 239040 /42 / 43, Fax : 01334 - 239043

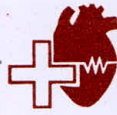E-mail : metroharidwar@metrohospitals.com, Website: www.metrohospitals.com

Regd. Office : 21, Community Center, Preet Vihar, New Delhi-110092

CIN No.: U33201DL2006PTC156918

MHHI/CL/0115/Rev. No. 01





# METRO

HOSPITAL & HEART INSTITUTE

(A unit of Sunhill Hospitals Private Limited)  
(NABH & ISO 9001: 2008 Certified)

## FINAL IMPRESSION

- Normal Acoustic Window
- Normal Chambers Dimensions
- No RWMA
- LVEF~60%
- No LVDD
- Trace TR, PASP 22 mmHg
- No pericardial effusion
- No Intracardiac clot

### Dr. Krishna CK

MD, DNB (Medicine), DNB (Cardiology)  
Consultant Interventional Cardiology  
UKMC Reg. No: 12883



### Dr. Ajit Kumar

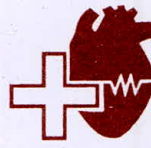MBBS, PGDCC  
Associate Consultant, Cardiology  
UKMC Reg. No: 7569

(Note: This document is not for medico-legal purpose)

Plot No. F-1, Sector-6A, SIDCUL, Haridwar - 249 403  
Emergency : +91 8191902600, Phone : 01334 - 239040 / 42 / 43, Fax : 01334 - 239043  
E-mail : metroharidwar@metrohospitals.com, Website: www.metrohospitals.com

Regd. Office : 21, Community Center, Preet Vihar, New Delhi-110092  
CIN No.: U33201DL2006PTC156918

MHHI/CL/0115/Rev. No. 01



# METRO PATH LABS

(A unit of Sunhill Hospitals Private Limited)

(ISO & NABH Certified)

CIN No.: U33201DL2006PTC156918

Patient Name : **Mr. ASHWANI AGARWAL**  
DOB/Age/Gender : 26 Year's /Male  
Pateint ID : --- 11  
Referred By : **Dr.**

Sample Collected Date : Mar,25/2023  
Report Date : Mar,25/2023  
Report Time : 07:12 PM

Test Description	Value(S)	Unit(S)	Refrence Range
------------------	----------	---------	----------------

## Complete Blood Count &:{C.B.C.} HAEMATOLOGY

Hemoglobin:-	9.8	mg/dl	12.5---16.5
T L C:-	6.250	Cells/cumm	4.000—11.000
D L C:-			
Neutrophils:-	69.1	%	45 - 75
Lymphocytes:-	21.4	%	25 - 45
Eosinophils:-	6.6	%	1 - 6
Monocytes:-	2.90	%	2 - 8
Basophils:-	0.00	%	---<2
RED BLOOD CELLS Count:R.B.C:	4.06	Million/cu/mm	3.5 - 5.5
PACKED CELL VOLUME {HCT} P.C.V	36.8	%	36 - 52
MEAN CELLS VOLUME:(M.C.V):	82.5	fl	80 - 100
MEAN CELLS HEMOGLOBIN:M.C.H	21.4	pg	27 - 32
MEAN CELLS HEMGRAM CONCENTRATION:-M.C.H.C: 28.9		gm/dl	31 - 37
PLATELETS COUNT:-	2.77	Lakh/cu mm	1.50 - 4.50
RDW:-	15.1	%	11.5 - 15.0

\*\*\*End Of Report\*\*\*



Plot No. F-1, Sector-6A, SIDCUL, Haridwar - 249 403  
Emergency : +91 8191902600, Phone : 01334 - 239040 / 42 / 43, Fax : 01334 - 239043  
E-mail : metroharidwar@metrohospitals.com, Website: www.metrohospitals.com