

Please note the following health check-up booking summary on 08/04/2023


1 message

Customer Care :Mediwheel : New Delhi <customercare@mediwheel.in>
To: "vidhidiagnostics@gmail.com" <vidhidiagnostics@gmail.com>

7 April 2023 at 19:11

Member Name	Member Age	Mobile	Package Name
MR. JOSHI YOGESH PRASAD	33	9601255932	Medi-Wheel Metro Full Body Health Checkup Male Below 40

Thanks & Regards

 cid:part1.98B1C0C3.53433036@mediwheel.in

Arcofemi Health Care Ltd. | F-701 A, Lado Sarai, Mehrauli | New Delhi – 110 030

Ph No. 011-41195959

Email : customercare@mediwheel.in; | Web: www.mediwheel.in

Medical Examination Report

Date : 08/04/2023

1. Personal Particulars

Name : Yogesh P Jashi

Age : 35 years

Gender : Male / Female

Marital Status : Married

Past & Present Medical History : No

2. Clinical Medical Examination

Height : 173 cm

Weight : 87 kg

Blood Pressure : 122/82 mmHg

Pulse : 68 p/min

General Condition : Good
Central Nervous System : Good
Cardiovascular System : Good
Abdomen : Good
Last menstrual period : -NA-

Skin : Good
Head & Neck : Good
Chest : Good
Limbs : Good

Vision: Right: 6/6 with spectacles, Left: 6/6 with spectacles
N/G normal vision N/G normal vision
Colour vision : Normal/Colour Blind

Personal Habit : No

Remarks : Fit / Unfit for employment

Dr's name, signature & chop: Dr. Vidhi D. Modh, MBS, Reg. No. 274540

Vidhi Diagnostics, L-86, Swatantra-Senani Nagar, Opp. Akhbarnagar Bus Terminals, Nr. Akhbarnagar Circle, New Wadaj, Ahmedabad-13.

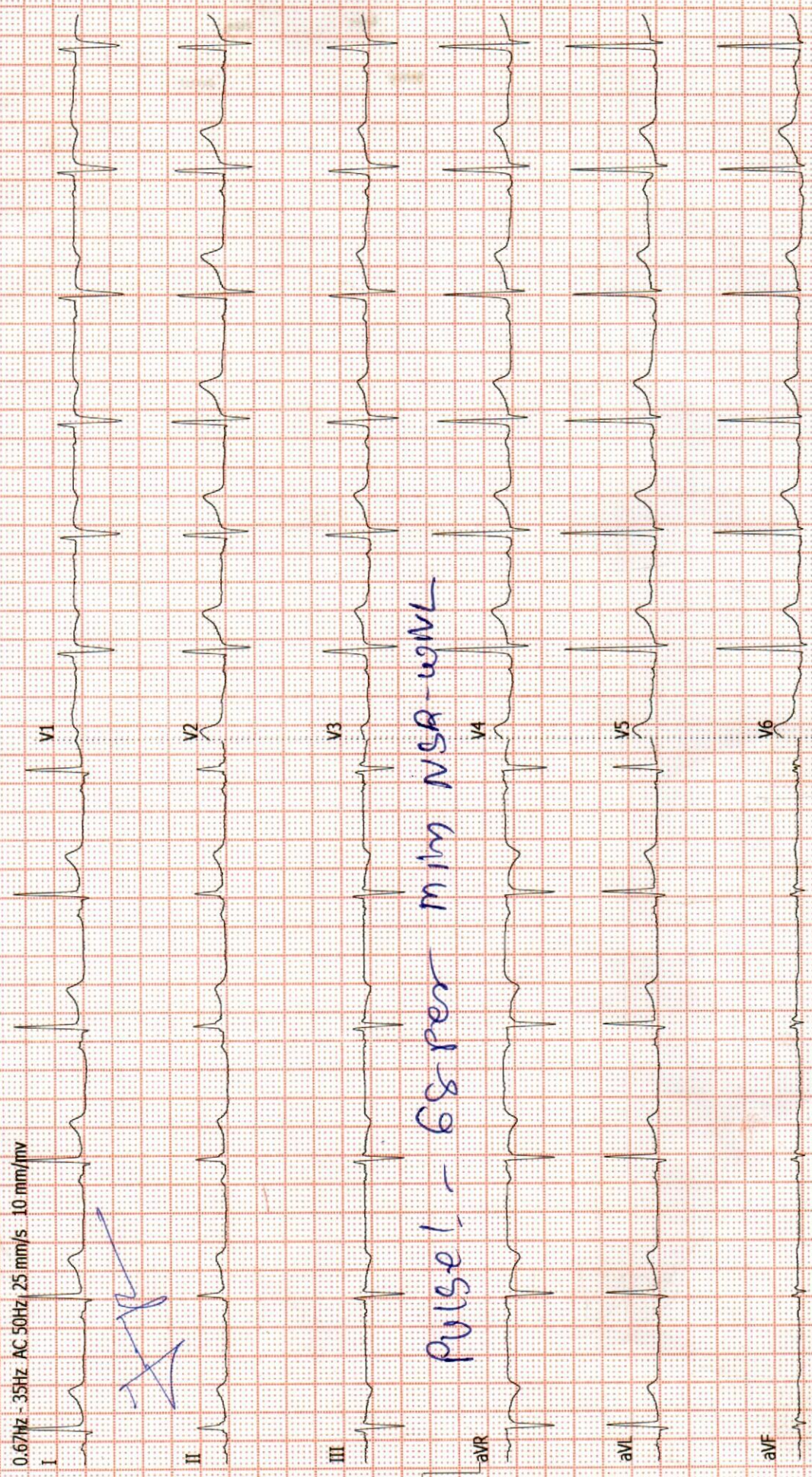
HR : 69 bpm
 PR : 158 ms
 QRS : 90 ms
 QT/QTc : 374/400 ms
 P/QRS/T : 13/4/0 deg.
 RV5/SV1 : 1.400/-0.826 mv
 RV5+SV1 : 2.226 mv

ID: 8951
 Name: yogesh pjoshi
 Age: 35yrs
 Sex: Male
 Hospital:

Dr. Avinash Purohit
 MBBS, D. Cardiol
G-45946

Vidhi Diagnostics
 Sinus rhythm
 L-86, Swatantra-Senani Nagar,
 Opp. Akhbarnagar Bus Terminals,
 Mr. Akhbarnagar Circle,
 New Wadaj, Ahmedabad-13.

Need to be confirmed by doctor. Doctor Name: _____



Pulse! - 68 per min NSA-w/mL

YR

Dr. Dinesh S. Modh

M.D., D.M.R.E. (Radiodiagnosis)

Consultant Radiologist & Sonologist

Ex. Junior Lecturer, B.J. Medical College, Civil Hospital, A'bad.

Panel Doctor of L.I.C.



Patient's name : YOGESH P JOSHI

Reg. ID : R-348-23

Referred by : Dr. MEDIWHEEL

Age/Sex : 35 Years/Male

Accession : 3472

Date : 08/04/2023

X-RAY CHEST (PA VIEW)

Both lung fields appear normal.
No e/o consolidation or cavitations is seen.
Both costo-phrenic angles appear clear.
Cardiac size is within normal limits.
Both domes of diaphragm appear normal.
Bony thoracic cage appears normal.

Thanks for reference.

Dr. Dinesh S. Modh

MD DMRE (Radiodiagnosis)

DR DINESH S. MODH

M.D. DMRE(RADIODIAGNOSIS)

ISO 9001:2015 Certified Diagnostics Center

Vidhi Imaging Center

L-86, Swatantra Senani Nagar, Opp. Indian Oil Petrol Pump, Akhbarnagar Circle, Nava Vadaj, Ahmedabad - 380 013.

Phone : (Radiology) 079-2762 1406 | M. 98799 29406, 98250 09406 | Time (Radiology) : Mon. to Sat. 9 am to 2 pm, 5 to 9 pm, Sunday 9 am to 12 Noon

E-mail : vidhidiagnostics@gmail.com, Website : www.vidhidiagnostics.com

Multislice CT Scan | CBCT-Dental Scan | Live 3D-4D Sonography | Colour Doppler | Echo Cardiography | Interventional Radiology | Maxillofacial Radiology | Fetal Medicine
Digital X-Ray | Digital Mammography | Digital OPG/TMJ | ECG/TMT/PFT/EEG/EMG | Audiometry | Pathology Laboratory | Health Check Up Plans | Pre Employment Check Up

CT SCAN & CBCT FACILITY NOW AVAILABLE

Dr. Dinesh S. Modh

M.D., D.M.R.E. (Radiodiagnosis)

Consultant Radiologist & Sonologist

Ex. Junior Lecturer, B.J. Medical College, Civil Hospital, A'bad.

Panel Doctor of L.I.C.



Patient's name : YOGESH P JOSHI
Reg. ID : R-348-23
Referred by : Dr. MEDIWHEEL

Age/Sex : 35 Years/Male
Accession : 3472
Date : 08/04/2023

USG ABDOMEN

LIVER: Liver is normal in size and bright in echotexture s/o fatty liver grade1. Intrahepatic biliary radicals appear normal.

Portal vein is normal in caliber. Common Bile duct is normal in course & caliber. No e/o calculus is seen in biliary tree.

GALL BLADDER: is distended & appear normal. No e/o calculus or cholecystitis is seen. GB wall thickness appears normal. No evidence of pericholecystic fluid is seen.

SPLEEN: Spleen is normal in size & shows normal echo texture. No evidence of diffuse or focal lesion is seen. Splenic vein appears normal.

PANCREAS: Pancreas appears normal in size & echotexture. No evidence of diffuse or focal lesion is seen. Main pancreatic duct is normal.

KIDNEY: Both kidneys appear normal in size and echopattern.

Corticomedullary differentiation is maintained.

No evidence of calculus or hydronephrosis is seen on both sides.

Both supra renal region appear normal.

No evidence of pre & para aortic lymphadenopathy is seen.

Gas filled non-dilated bowel loops are seen in abdomen.

No evidence of free fluid is seen in abdomen.

No evidence of dilated or thickened bowel loops is seen.

Urinary bladder appears normal. No e/o calculus or mass lesion is seen.

Prostate appears normal in size & echopattern.

Thanks for reference.

Dr. Dinesh S. Modh
DR DINESH S. MODH
M.D. DMRE (RADIOLOGIST)

ISO 9001:2015 Certified Diagnostics Center

Vidhi Imaging Center

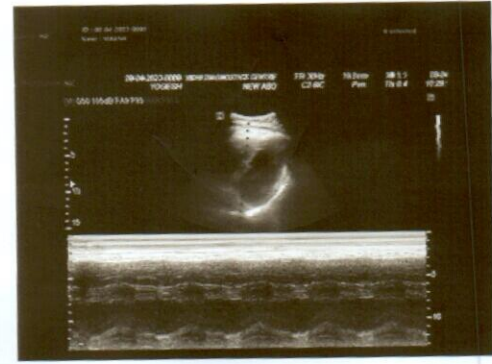
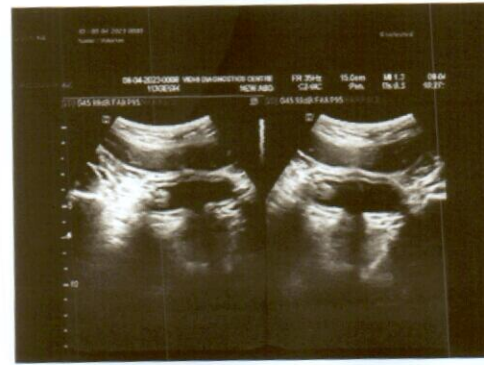
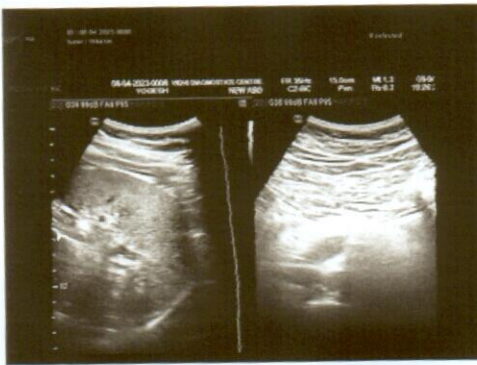
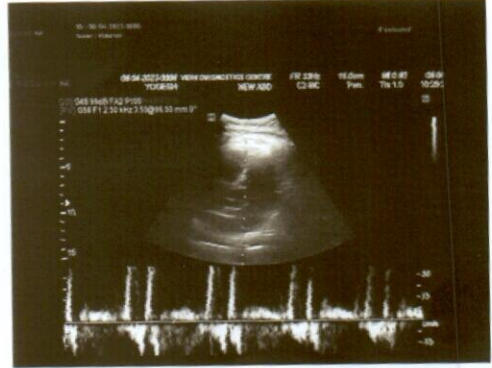
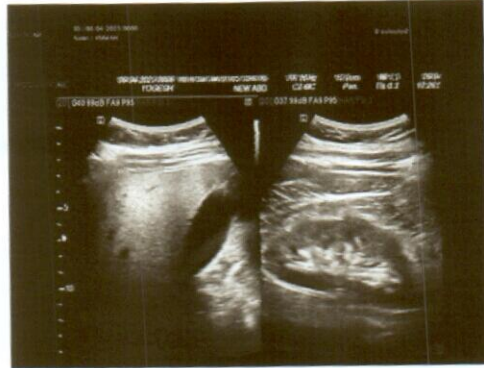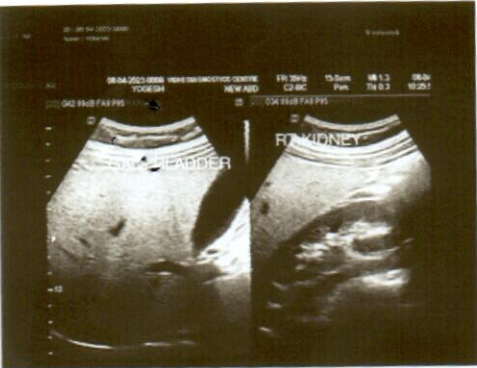
L-86, Swatantra Senani Nagar, Opp. Indian Oil Petrol Pump, Akhbarnagar Circle, Nava Vadaj, Ahmedabad - 380 013.

Phone : (Radiology) 079-2762 1406 | M. 98799 29406, 98250 09406 | Time (Radiology) : Mon. to Sat. 9 am to 2 pm, 5 to 9 pm, Sunday 9 am to 12 Noon

E-mail : vidhidiagnostics@gmail.com, Website : www.vidhidiagnostics.com

Multislice CT Scan | CBCT-Dental Scan | Live 3D-4D Sonography | Colour Doppler | Echo Cardiography | Interventional Radiology | Maxillofacial Radiology | Fetal Medicine
Digital X-Ray | Digital Mammography | Digital OPG/TMJ | ECG/TMT/PFT/EEG/EMG | Audiometry | Pathology Laboratory | Health Check Up Plans | Pre Employment Check Up

CT SCAN & CBCT FACILITY NOW AVAILABLE



Dr. Dinesh S. Modh

M.D., D.M.R.E. (Radiodiagnosis)
Consultant Radiologist & Sonologist
Ex. Junior Lecturer, B.J. Medical College, Civil Hospital, A'bad.
Panel Doctor of L.I.C.



Patient's name : YOGESH P JOSHI
Reg. ID : R-348-23
Referred by : Dr. MEDIWHEEL

Age/Sex : 35 Years/Male
Accession : 3472
Date : 08/04/2023

2D- ECHO REPORT

FINAL CONCLUSION:

LV IS NORMAL SIZE. GOOD LV SYSTOLIC FUNCTION NO RWMA.
LVEF - 60%. NO CONCENTRIC LVH.
NORMAL LV COMPLANCE.
LA IS NORMAL SIZE. NO LA CLOT.
RV IS NORMAL SIZE. GOOD RV SYSTOLIC FUNCTION.
RA IS NORMAL SIZE.
MITRAL VALVE IS NORMAL. NO MS. MILD MR (15%). NO MVP.
AORTIC VALVE IS NORMAL. NO AS. NO AR.
TRICUSPID VALVE IS NORMAL. NO TR. RVSP-26 mmHg. NO PAH.

NO CLOT, NO VEGETATION, NO PERICARDIAL EFFUSION.

DIMENSIONS:

AORTA	2.6 C.M
LEFT ATRIUM	2.7 C.M
LVDD	4.1 C.M.
IVSD	1.0 C.M
PWD	1.0 C.M
LVDS	2.6 C.M.

COLOUR DOPPLER FINDING:

STRUCTURE	VELOCITY m/sec
	Max
PULMONARY VALVE	0.7
MITRAL VALVE	E : 0.7 A: 0.4
AORTIC VALVE	1.0

Dr. Avinash Bhaskar
M.D. D-Cardio
DR AVINASH BHASKAR

ISO 9001:2015 Certified Diagnostics Center

Vidhi Imaging Center

L-86, Swatantra Senani Nagar, Opp. Indian Oil Petrol Pump, Akhbarnagar Circle, Nava Vadaj, Ahmedabad - 380 013.

Phone : (Radiology) 079-2762 1406 | M. 98799 29406, 98250 09406 | Time (Radiology) : Mon. to Sat. 9 am to 2 pm, 5 to 9 pm, Sunday 9 am to 12 Noon
E-mail : vidhidiagnostics@gmail.com, Website : www.vidhidiagnostics.com

Multislice CT Scan | CBCT-Dental Scan | Live 3D-4D Sonography | Colour Doppler | Echo Cardiography | Interventional Radiology | Maxillofacial Radiology | Fetal Medicine
Digital X-Ray | Digital Mammography | Digital OPG/TMJ | ECG/TMT/PFT/EEG/EMG | Audiometry | Pathology Laboratory | Health Check Up Plans | Pre Employment Check Up

CT SCAN & CBCT FACILITY NOW AVAILABLE

Dr. Dinesh S. Modh

M.D., D.M.R.E. (Radiodiagnosis)

Consultant Radiologist & Sonologist

Ex. Junior Lecturer, B.J. Medical College, Civil Hospital, A'bad.

Panel Doctor of L.I.C.



Dear Sir,

This is to request you good-sir that. I don't want to give my stool sample for the time in being in force

Thanking You.

Jyotesh B. Joshi

9601255932

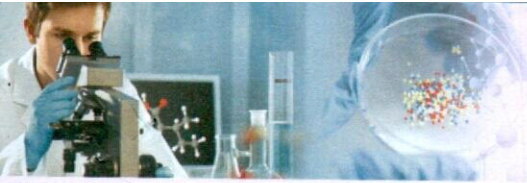(BOB)

ISO 9001:2015 Certified Diagnostics Center

Vidhi Imaging Center, L-86, Swatantra Senani Nagar, Opp. Akhbarnagar Petrol Pump, Nr. Akhbarnagar Circle, Nava-Vadaj, Ahmedabad - 380 013.

Phone : 079-2762 1406, Mobile : 98799 29406, 98250 09406, E-mail : vidhidiagnostics@gmail.com, Website : www.vidhidiagnostics.com

FACILITIES : Live 3D-4D Sonography | Colour Doppler | Echo Cardiography | Interventional Radiology | Fetal Medicine | Digital X-Ray
Digital Mammography | Digital OPG / TMJ | ECG / TMT / PFT / EEG / EMG | Pathology Laboratory | Health Check Up Plans | Pre Employment Check Up



Pathology Department



Patient's name : YOGESH P JOSHI
Age/Sex : 35 Years/Male
Referred by : Dr. MEDIWHEEL
Collection Time : 10:23

Reg. ID : P-166-23
Accession : 3473
Order Dt/time : 08/04/2023 10:23

Complete Blood Count

Sample Type: EDTA

Test Name	Result	Units	Biological Reference Interval
<u>Blood Counts</u>			
Haemoglobin :	14.4	Gms%	13.5 - 18.0
Total R.B.C. :	4.95	mill/c.mm	4.7 - 6.0
Total W. B. C. :	7280	/cu mm	4000 - 10500
Platelet Count :	176000	/cu.mm	1,50,000 - 4,50,000
<u>Differential Count</u>			
Neutrophils :	52	%	40 - 70
Lymphocytes :	43	%	20 - 40
Eosinophils :	03	%	1 - 4
Monocytes :	02	%	2 - 6
Basophils :	00	%	0 - 01
<u>Blood Indices</u>			
P. C. V :	45.8	%	42 - 52
M. C. V. :	92.6	fl	78 - 100
M.C.H :	29.0	pg	27 - 31
M. C. H. C :	32.0	%	32 - 36
R.D.W :	14.4	%	11.5 - 14.0
<u>E.S.R.(Westergren Method)</u>			
After one hour :	04	mm/hr	1 - 7

TESTS DONE ON FULLY AUTOMATED HEMATOLOGY ANALYZER.

Dr. Gayatri M. Mehta

M. D. (Patho)

Reg. No. G-32215

DR GAYATRI MEHTA
MD(PATHOLOGY)

DR. ANAND D. PARIKH
MD(PATHOLOGY)

LAB USE ONLY (Entered by :GM Enter Date/Time:08/04/2023 5:03:00 PM) (Verify by :GM Verify Date/Time:08/04/2023 5:03:00 PM)

ISO 9001:2015 Certified Diagnostics Center

Vidhi Imaging Center | Pathology Department

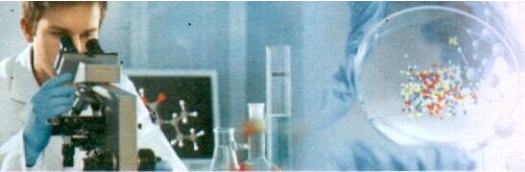L-86, Swatantra Senani Nagar, Opp. Akhbarnagar Petrol Pump, Nr. Akhbarnagar Circle, Nava-Vadaj, Ahmedabad - 380 013.

Ph. (Pathology) : 079-2762 1406, 8849893954 M. 98799 29406, 98250 09406, E-mail : vidhidiagnostics@gmail.com, Web. : www.vidhidiagnostics.com

Time (Pathology) : Mon. to Sat. 8.30 am to 8.00 pm, Sunday 9 am to 12 Noon

Pathology means science behind medicine

CT SCAN & CBCT FACILITY NOW AVAILABLE



Pathology Department

VIDHI
DIAGNOSTICS



Patient's name : YOGESH P JOSHI
Age/Sex : 35 Years/Male
Referred by : Dr. MEDIWHEEL
Collection Time : 10:23

Reg. ID : P-166-23
Accession : 3473
Order Dt/time : 08/04/2023 10:23

Blood Group

Sample Type: EDTA sample.

Test Name	Result
BG :	" B "
RH :	POSITIVE
Remarks	Done by forward grouping method.

Blood Glucose

Sample Type: Serum

Test Name	Result	Units	Biological Reference Interval
Fasting Blood Glucose :	110.0	mg/dl	70 - 110
<i>GOD-POD Method.</i>			

Blood Glucose

Sample Type: Serum

Test Name	Result	Units	Biological Reference Interval
Post Prandial Blood Glucose After 2hr. :	115.5	mg/dl	80 - 140
<i>GOD-POD Method.</i>			

Dr. Gayatri M. Mehta

M. D. (Patho)

Reg. No. G-32215

DR GAYATRI MEHTA
MD(PATHOLOGY)

DR. ANAND D. PARIKH
MD(PATHOLOGY)

LAB USE ONLY (Entered by :GM Enter Date/Time:08/04/2023 5:04:00 PM) (Verify by :GM Verify Date/Time:08/04/2023 5:05:00 PM)

ISO 9001:2015 Certified Diagnostics Center

Vidhi Imaging Center | Pathology Department

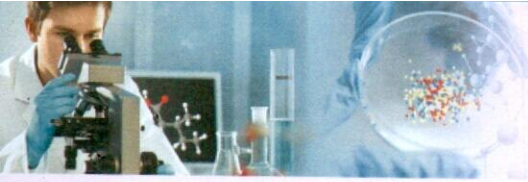L-86, Swatantra Senani Nagar, Opp. Akhbarnagar Petrol Pump, Nr. Akhbarnagar Circle, Nava-Vadaj, Ahmedabad - 380 013.

Ph. (Pathology) : 079-2762 1406, 8849893954 M. 98799 29406, 98250 09406, E-mail : vidhidiagnostics@gmail.com, Web. : www.vidhidiagnostics.com

Time (Pathology) : Mon. to Sat. 8.30 am to 8.00 pm, Sunday 9 am to 12 Noon

Pathology means science behind medicine

CT SCAN & CBCT FACILITY NOW AVAILABLE



Pathology Department

VIDHI[®]
DIAGNOSTICS

Creating life in
Imaging

Patient's name : YOGESH P JOSHI
Age/Sex : 35 Years/Male
Referred by : Dr. MEDIWHEEL
Collection Time : 10:23

Reg. ID : P-166-23
Accession : 3473
Order Dt/time : 08/04/2023 10:23

Lipid Profile

Sample Type: Serum

Test Name	Result	Units	Biological Reference Interval
S. Cholesterol : Oxidase-esterase method.	188	mg/dl	0 - 200
S. Triglyceride : Enzymatic Colorimetry method	217.6	mg/dL	0 - 200
S. HDL - Cholesterol : Serum by Enzymatic method.	48.3	mg/dL	35 - 65
S. LDL - Cholesterol : Serum by Enzymatic method	96.18	mg/dL	0 - 130
S. VLDL - Cholesterol :	43.52	mg/dL	0 - 30
S. Chole/HDL.Ratio :	3.89		1 - 6
S. LDL / HDL Cholesterol Ratio :	1.99		0 - 3.5

Dr. Gayatri M. Mehta
M. D. (Patho)

DR. GAYATRI MEHTA
MD(PATHOLOGY)

DR. ANAND D. PARIKH
MD(PATHOLOGY)

LAB USE ONLY (Entered by :GM Enter Date/Time:08/04/2023 5:04:00 PM) (Verify by :GM Verify Date/Time:08/04/2023 5:04:00 PM)

ISO 9001:2015 Certified Diagnostics Center

Vidhi Imaging Center | Pathology Department

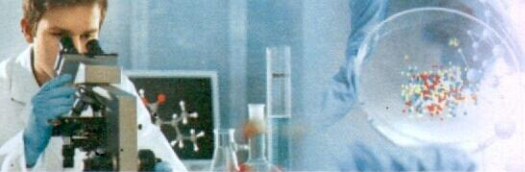L-86, Swatantra Senani Nagar, Opp. Akhbarnagar Petrol Pump, Nr. Akhbarnagar Circle, Nava-Vadaj, Ahmedabad - 380 013.

Ph. (Pathology) : 079-2762 1406, 8849893954 M. 98799 29406, 98250 09406, E-mail : vidhidiagnostics@gmail.com, Web. : www.vidhidiagnostics.com

Time (Pathology) : Mon. to Sat. 8.30 am to 8.00 pm, Sunday 9 am to 12 Noon

Pathology means science behind medicine

CT SCAN & CBCT FACILITY NOW AVAILABLE



Pathology Department

VIDHI
DIAGNOSTICS



Patient's name : YOGESH P JOSHI
Age/Sex : 35 Years/Male
Referred by : Dr. MEDIWHEEL
Collection Time : 10:23

Reg. ID : P-166-23
Accession : 3473
Order Dt/time : 08/04/2023 10:23

HbA1C

Sample Type: Serum

Test Name	Result	Units	Biological Reference Interval
HbA1C :	5.6	%	Non-diabetic: 4.2-6.2 Pre-diabetic : 6.3-7.2 Diabetic : 7.3-8.2
Mean Blood Glucose of Last 03 months.	114	mg/dl	

Comment

*As per the new 2009 update of American Diabetes Association regarding HbA1C & Mean Blood Glucose relationship.

NOTE:

This test is used to monitor diabetic patients compliance with the therapeutic regimen and logo It's level is proportional to both the average blood glucose concentration and the life span of the red blood cells (RBC) in circulation. HbA1c values are free of day to day glucose fluctuations and are unaffected by exercise or recent food intake.

Dr. Gayatri M. Mehta
M. D. (Patho)

DR. GAYATRI MEHTA
MD(PATHOLOGY)

DR. ANAND D. PARIKH
MD(PATHOLOGY)

LAB USE ONLY (Entered by :GM Enter Date/Time:08/04/2023 5:04:00 PM) (Verify by :GM Verify Date/Time:08/04/2023 5:04:00 PM)

ISO 9001:2015 Certified Diagnostics Center

Vidhi Imaging Center | Pathology Department

L-86, Swatantra Senani Nagar, Opp. Akhbarnagar Petrol Pump, Nr. Akhbarnagar Circle, Nava-Vadaj, Ahmedabad - 380 013.

Ph. (Pathology) : 079-2762 1406, 8849893954 M. 98799 29406, 98250 09406, E-mail : vidhidiagnostics@gmail.com, Web. : www.vidhidiagnostics.com

Time (Pathology) : Mon. to Sat. 8.30 am to 8.00 pm, Sunday 9 am to 12 Noon

Pathology means science behind medicine

CT SCAN & CBCT FACILITY NOW AVAILABLE



Pathology Department

VIDHI[®]
DIAGNOSTICS



Creating Life in Progress

Patient's name : YOGESH P JOSHI
Age/Sex : 35 Years/Male
Referred by : Dr. MEDIWHEEL
Collection Time : 10:23

Reg. ID : P-166-23
Accession : 3473
Order Dt/time : 08/04/2023 10:23

BIOCHEMISTRY

Sample type :Serum

Test Name	Result	Units	Biological Reference Interval
Urea , (Serum by GLDH method) :	17.0	mg/dl	10 - 50
S.Uric acid , (Serum by Uricase method) :	7.0	mg/dl	3.4 - 7.0
Bun :	7.9	mg/dl	6-20
Creatinine , (Serum by Enzymatic reaction) :	1.01	mg/dl	0.5-1.2
S.G.P.T (ALT) : (Serum by IFCC method)	46.5	U/L	0 - 40
S.G.O.T (AST) : (Serum by IFCC method)	26.4	U/L	0 - 37
ALK.PHOSPHATASE : (Serum by PNP method)	67	U/L	40-129
G.G.T :	19.4	U/L	8 - 78
<u>BILIRUBIN</u>			
Total :	0.71	mg/dl	Up to 1.2
Direct :	0.29	mg/dl	0-0.7
Indirect :	0.42	mg/dl	0 - 0.5
<u>SERUM PROTEINS</u>			
Total Protein (Serum by Biuret method) :	6.49	gms/dl	6.4 - 8.5
Albumin (Serum by BCG method) :	4.13	gms/dl	3.97-4.94
Globulins :	2.36	gms/dl	2.3 - 3.5
A/G Ratio :	1.75		0.9 - 2.9

Dr. Gayatri M. Mehta
M. D. (Patho)
Reg. No. G-32215
DR GAYATRI MEHTA
MD(PATHOLOGY)

DR.ANAND D.PARIKH
MD(PATHOLOGY)

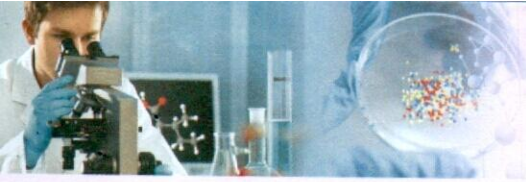LAB USE ONLY (Entered by :GM Enter Date/Time:08/04/2023 5:03:00 PM) (Verify by :GM Verify Date/Time:08/04/2023 5:03:00 PM)

ISO 9001:2015 Certified Diagnostics Center
Vidhi Imaging Center | Pathology Department

L-86, Swatantra Senani Nagar, Opp. Akhbarnagar Petrol Pump, Nr. Akhbarnagar Circle, Nava-Vadaj, Ahmedabad - 380 013.
Ph. (Pathology) : 079-2762 1406, 8849893954 M. 98799 29406, 98250 09406, E-mail : vidhidiagnostics@gmail.com, Web. : www.vidhidiagnostics.com
Time (Pathology) : Mon. to Sat. 8.30 am to 8.00 pm, Sunday 9 am to 12 Noon

Pathology means science behind medicine

CT SCAN & CBCT FACILITY NOW AVAILABLE



Pathology Department

VIDHI[®]
DIAGNOSTICS

Creating life in samples

Patient's name : YOGESH P JOSHI
Age/Sex : 35 Years/Male
Referred by : Dr. MEDIWHEEL
Collection Time : 10:23

Reg. ID : P-166-23
Accession : 3473
Order Dt/time : 08/04/2023 10:23

Thyroid Function Test

Sample Type: Serum

Test Name	Result	Units	Biological Reference Interval
TOTAL T3 :	1.33	ng/ml	0.84 - 2.0
TOTAL T4 :	10.60	ug/dl	5.1 - 14.0
TSH(Ultra sensitive) :	2.412	mIU/L	0.27 - 4.2

Dr. Gayatri M. Mehta

M. D. (Patho)

Reg. No. G-32215

DR GAYATRI MEHTA
MD(PATHOLOGY)

DR. ANAND D. PARIKH
MD(PATHOLOGY)

LAB USE ONLY (Entered by :GM Enter Date/Time:08/04/2023 5:14:00 PM) (Verify by :GM Verify Date/Time:08/04/2023 5:14:00 PM)

ISO 9001:2015 Certified Diagnostics Center

Vidhi Imaging Center | Pathology Department

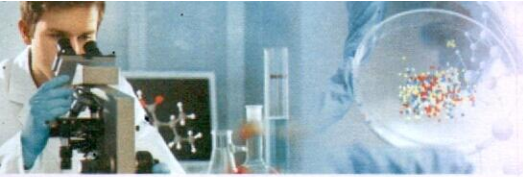L-86, Swatantra Senani Nagar, Opp. Akhbarnagar Petrol Pump, Nr. Akhbarnagar Circle, Nava-Vadaj, Ahmedabad - 380 013.

Ph. (Pathology) : 079-2762 1406, 8849893954 M. 98799 29406, 98250 09406, E-mail : vidhidiagnostics@gmail.com, Web. : www.vidhidiagnostics.com

Time (Pathology) : Mon. to Sat. 8.30 am to 8.00 pm, Sunday 9 am to 12 Noon

Pathology means science behind medicine

CT SCAN & CBCT FACILITY NOW AVAILABLE



Creating Life in Images



Pathology Department

Patient's name : YOGESH P JOSHI
Age/Sex : 35 Years/Male
Referred by : Dr. MEDIWHEEL
Collection Time : 10:23

Reg. ID : P-166-23
Accession : 3473
Order Dt/time : 08/04/2023 10:23

Urine Analysis

Sample Type: Urine

Test Name	Result	Units	Biological Reference Interval
<u>Physical Examination</u>			
Quantity :	30	ml	0 - 500 ml
Colour :	Pale Yellow		Pale Yellow
Transparency :	Slight Turbid.		Clear
Reaction :	Acidic		4.6 - 8.0
Specific Gravity :	1.030		1.016 - 1.022
Sediment :	Present		
<u>Chemical Examination</u>			
Albumin :	Present (Faint Trace)		Absent
Sugar :	NIL		Absent
Acetone :	Absent		Absent
Bile Salts :	Absent		Absent
Bile Pigments :	Absent		Absent
Urobilogen :	Absent		Absent
Nitrites :	Absent		Absent
<u>Microscopic Examination</u>			
Red blood Cells :	Occasional	/h.p.f	Absent
Pus Cells :	1-2	/h.p.f	Absent
Epithelial Cells :	1-2	/h.p.f	< 10.0
Amorphous :	Absent	/h.p.f	Absent
Bacteria :	Absent	/h.p.f	Absent
Crystals :	Absent	/h.p.f	Absent
Casts :	Absent	/h.p.f	Absent
Fungus :	Not seen	/h.p.f	Absent

Dr. Gayatri M. Mehta
M. D. (Patho)

Reg. No. G-32215

DR GAYATRI MEHTA
MD(PATHOLOGY)

DR. ANAND D. PARIKH
MD(PATHOLOGY)

ISO 9001:2015 Certified Diagnostics Center

LAB USE ONLY (Entered by : GM Enter Date/Time: 08/04/2023 5:08:00 PM Verify Date/Time: 08/04/2023 5:08:00 PM)

L-86, Swatantra Senani Nagar, Opp. Akhbarnagar Petrol Pump, Nr. Akhbarnagar Circle, Nava-Vadaj, Ahmedabad - 380 013.

Ph. (Pathology) : 079-2762 1406, 8849893954 M. 98799 29406, 98250 09406, E-mail : vidhidiagnostics@gmail.com, Web. : www.vidhidiagnostics.com

Time (Pathology) : Mon. to Sat. 8.30 am to 8.00 pm, Sunday 9 am to 12 Noon

Pathology means science behind medicine

CT SCAN & CBCT FACILITY NOW AVAILABLE

आयकर विभाग
INCOME TAX DEPARTMENT

भारत सरकार
GOVT. OF INDIA

स्थायी लेखा संख्या कार्ड
Permanent Account Number Card

AILPJ2205P

नाम / Name
YOGESH P JOSHI

पिता का नाम / Father's Name
PADMA DUTT JOSHI

जन्म की तारीख / Date of Birth
26/01/1988


हस्ताक्षर / Signature



Vidhi Diagnostics
L-86, Swatantra-Senani Nagar,
Opp. Akhbarnagar Bus Terminals,
Nr. Akhbarnagar Circle,
New Wadaj, Ahmedabad-13.

Dr. Vidhi D. Modh
Reg. No. G74640

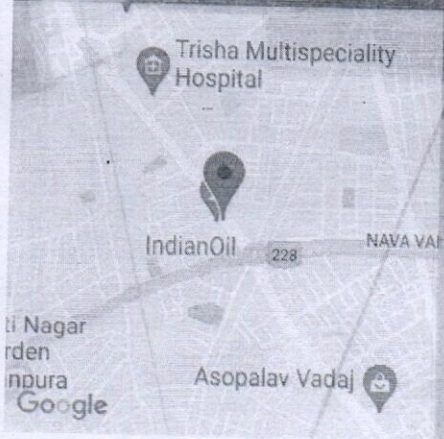
Lift



Apr 8, 2023 10:13:54 AM

Nirnay Nagar
Ahmedabad

Gujarat


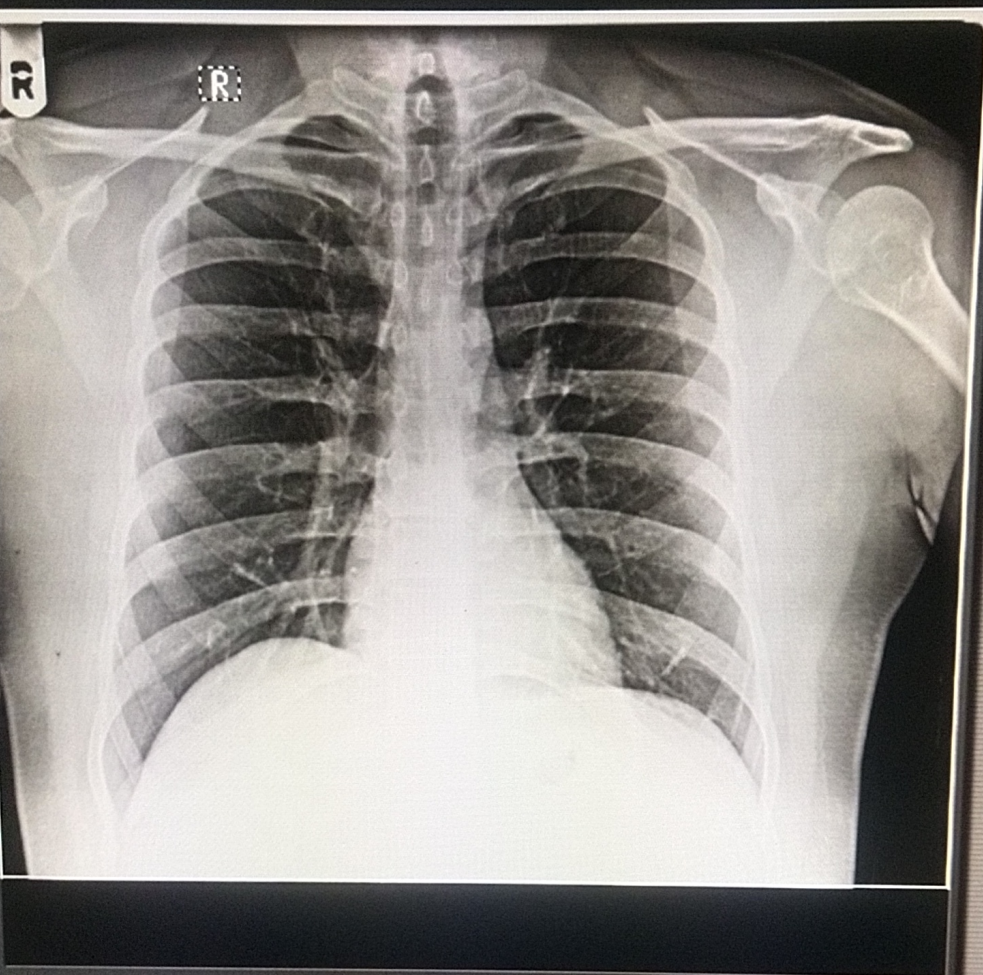


Dr. Vidhi A. Modh
MBBS
Reg. No. G-14540

Vidhi Diagnostics
L-86, Swatantra-Senani Nagar,
Opp. Akhbarnagar Bus Terminals,
Nr. Akhbarnagar Circle,
New Wadaj, Ahmedabad-13.

YOGESH P JOSHI 35/YRS

08042309



DELL