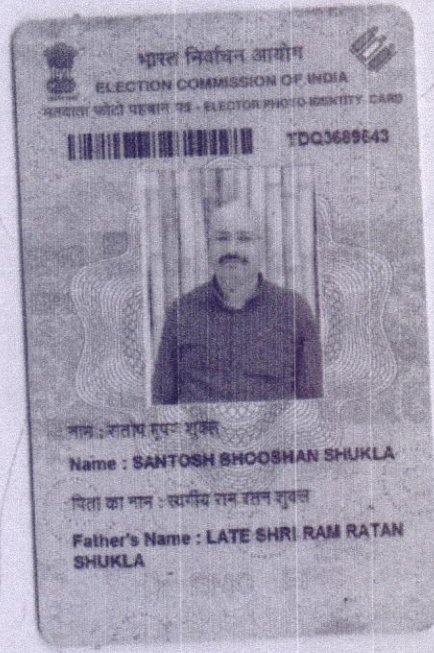
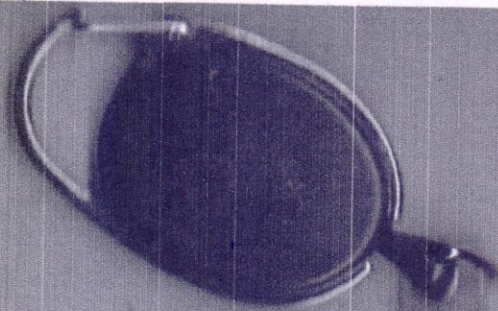
*Santosh*  
89600813378



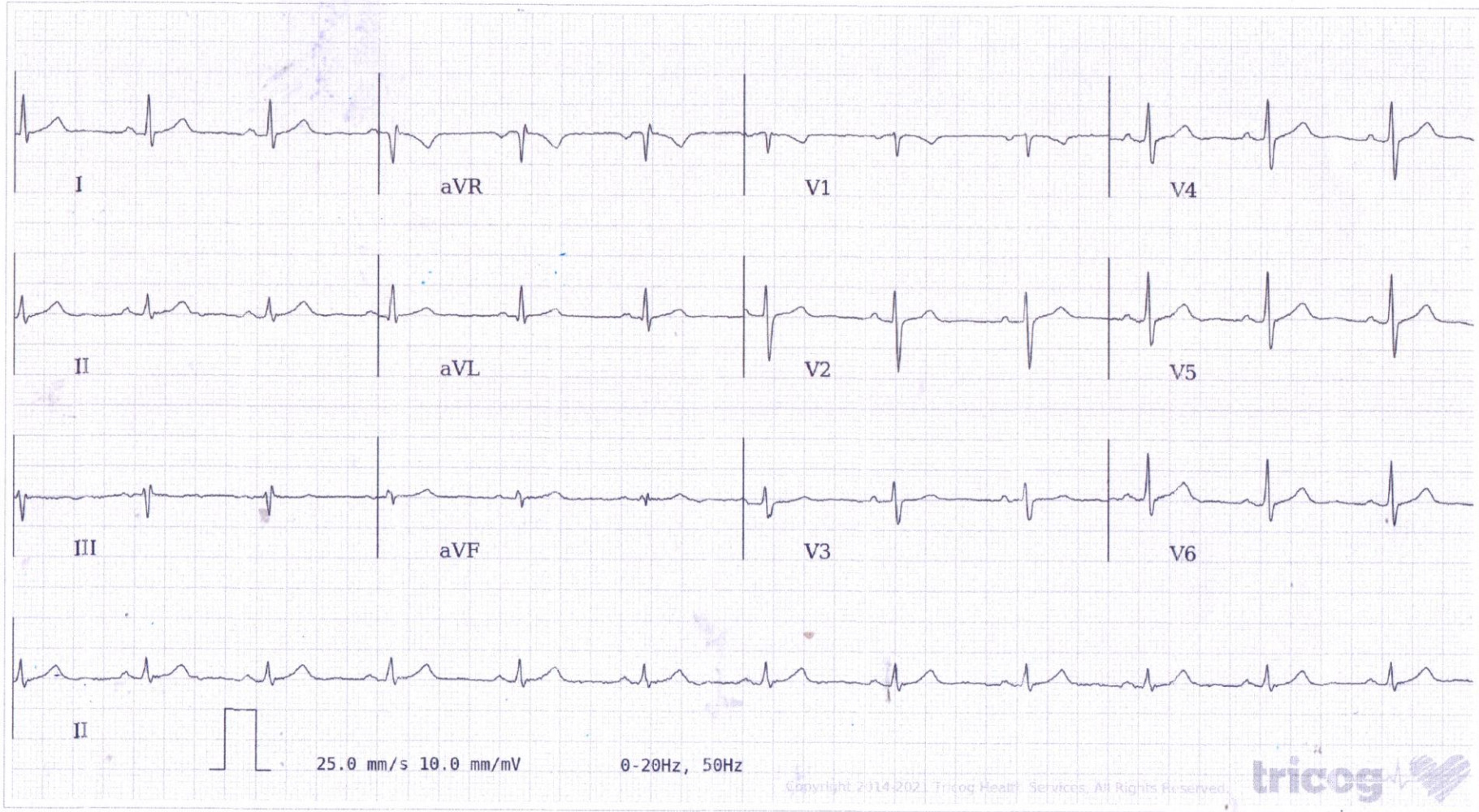


Age / Gender: 44/Male

Date and Time: 23rd Jul 21 11:29 AM

Patient ID: IDCD0190572122

Patient Name: Mr.SANTOSH BHOOSHAN SHUKLA



AR: 73 bpm VR: 73 bpm QRSD: 84 ms QT: 356 ms QTc: 392 ms PRI: 142 ms P-R-T: 19° -4° 22°

ECG Within Normal Limits: Sinus Rhythm, Normal Axis. Please correlate clinically.

AUTHORIZED BY

Dr. Charit  
MD, DM: Cardiology

REPORTED BY

Dr Nethra

Disclaimer: Analysis in this report is based on ECG alone and should only be used as an adjunct to clinical history, symptoms and results of other invasive and non-invasive tests and must be interpreted by a qualified physician.

63382