

Aarthi CT and MRI Scans, R S Puram West

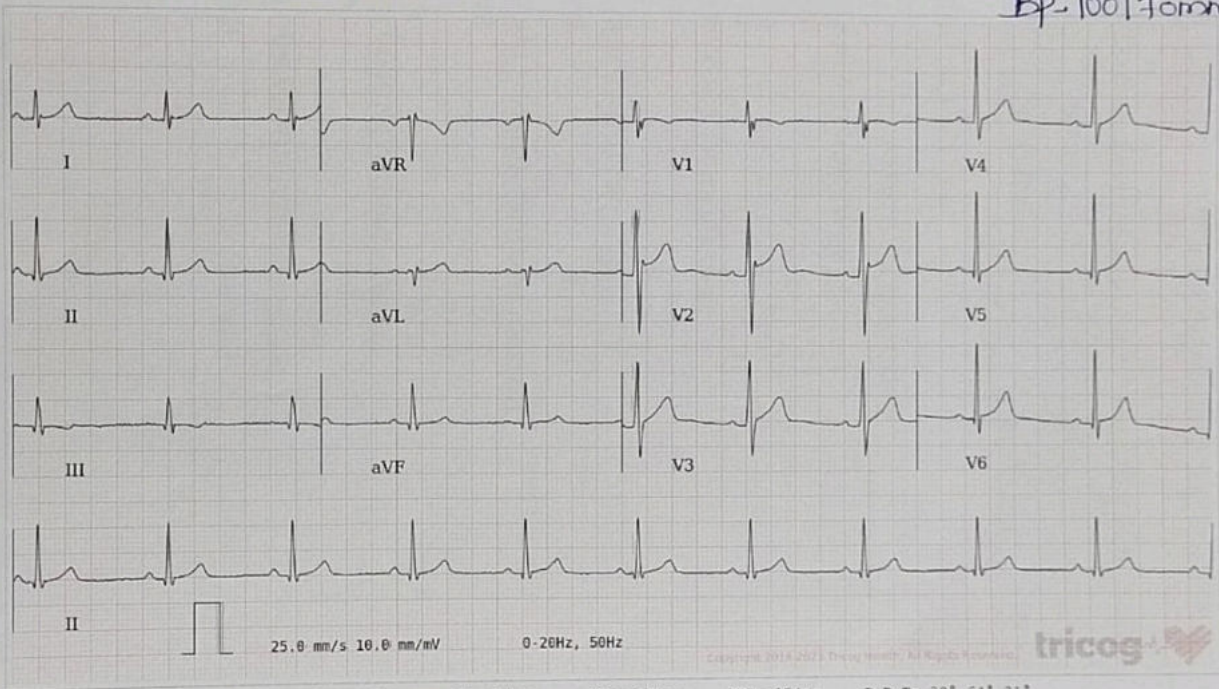
Age / Gender: 30/Male

Date and Time: 10th Feb 23 9:48 AM

Patient ID: 0900121251

Patient Name: MR. MAHENDRAN M

Bp-100/70mmHg



AR: 64bpm VR: 64bpm QRSD: 86ms QT: 370ms QTc: 381ms PRI: 154ms P-R-T: 39° 64° 21°

Sinus Rhythm, Non-specific ST segment elevation. Please correlate clinically.

Disclaimer: Analysis in this report is based on ECG alone and should only be used as an adjunct to clinical history, symptoms and results of other invasive and non-invasive tests and must be interpreted by a qualified physician.





ABI SCANS & LABS

A unit of Aarthi Scans and Labs

NAME	MR. MAHENDRAN M	PATIENT ID	121251
ACCESSION NO	128010	AGE/GENDER	30Y/MALE
REFERRED BY	MEDIWHEEL	DATE	10-SEP-2023

VISUAL ACUITY (VA)

WITH BEST CORRECTION

DISTANCE VISION (With glasses)

Right	10/11
Left	10/11
Both	11/11

NEAR VISION (With glasses)

Both	N6
------	----

COLOUR VISION (With glasses)

BOTH	Normal
------	--------

DISTANCE VISION (Without glasses)

Right	9/10
Left	9/10
Both	9/10

NEAR VISION (Without glasses)

Both	N6
------	----

COLOUR VISION (Without glasses)

BOTH	Normal
------	--------

Door No. 452/493, PN Road, Millar Stop,
Tirupur - 641 602. Phone: 99434 99994

Obli Towers, #594, D. B. Road - Cowley Brown Road Jn.,
Coimbatore - 641 002. Phone: 99430 99994

email: info@abiscans.com

www.abiscans.com



ABI SCANS & LABS

A unit of Aarthi Scans and Labs

NAME	MR. MAHENDRAN M	PATIENT ID	121251
ACCESSION NO	128010	AGE/GENDER	30Y/FEMALE
REFERRED BY	MEDIWHEEL	DATE	10-FEB-2023

ECHOCARDIOGRAPHIC EVALUATION

MEASUREMENTS: ACOUSTIC WINDOW: OPTIMAL

2D/ M MODE PARAMETERS:

Parameters	Patient Values	Normal Adult Value
LA	2.62	(2.0 - 4.0 cm)
AO	2.33	(2.0 - 4.0 cm)
LVIDD	4.09	(3.5 - 5.5 cm)
LVIDS	2.20	(2.5 - 4.3 cm)
IVSd	0.83	(0.6 - 1.2 cm)
LVPWd	0.90	(0.6 - 1.2 cm)
EF	75	(50% - 70%)

IMPRESSION:

- ✚ No regional wall motion abnormality at rest.
- ✚ Normal valves and chambers.
- ✚ No pulmonary hypertension.
- ✚ No pericardial effusion.
- ✚ Normal LV systolic function.

Dr. KARTHIK C.S.MD.,PGD(CARDIOLOGY,UKR)
CONSULTANT CARDIOLOGIST
TMC REG. No. 88567

Dr. KARTHIK C.S.MD.,PGD(CARDIOLOGY,UKR)
CONSULTANT CARDIOLOGIST.

Door No. 452/493, PN Road, Millar Stop,
Tirupur - 641 602. Phone: 99434 99994

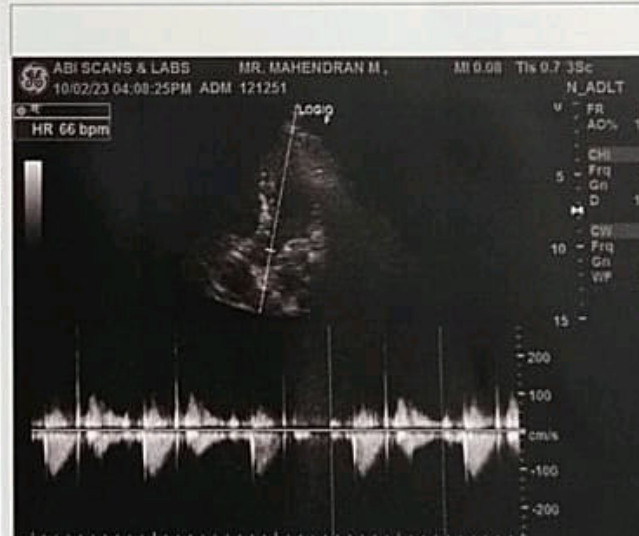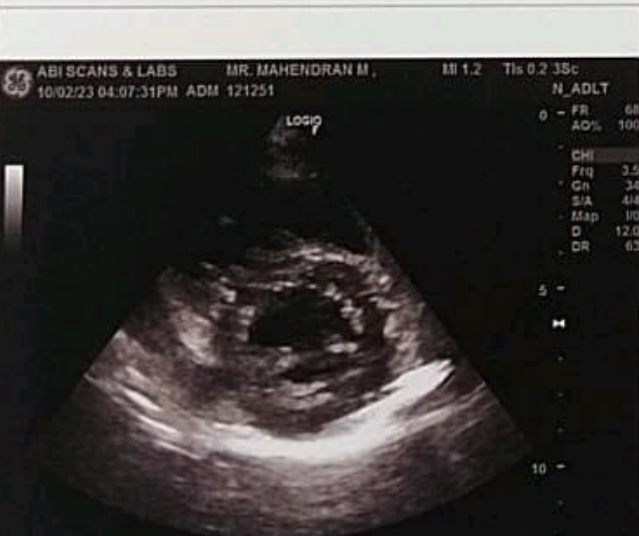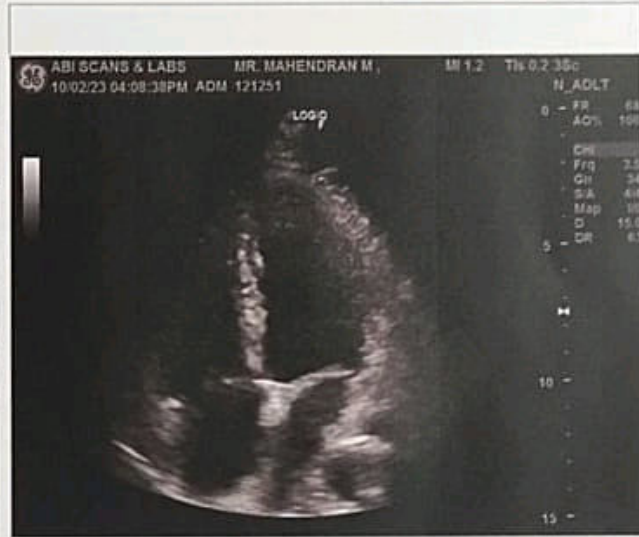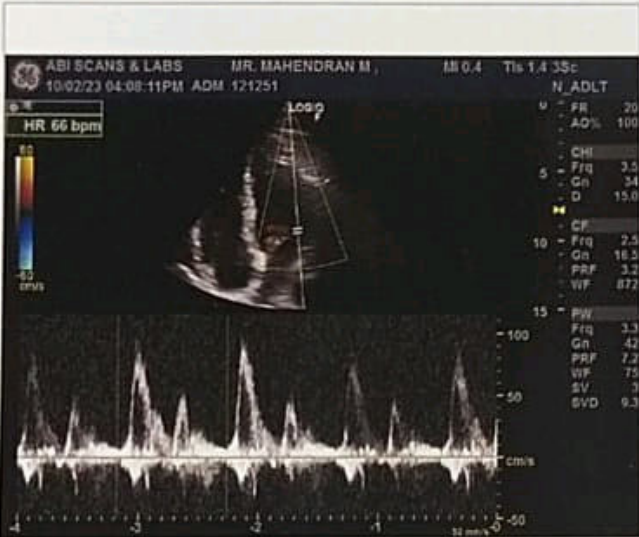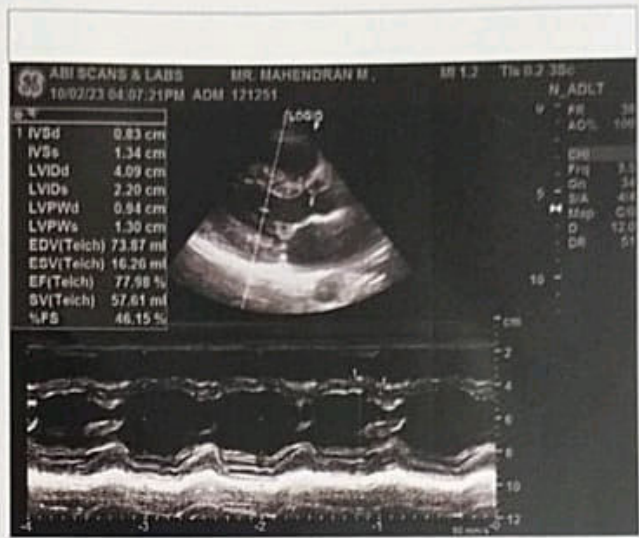
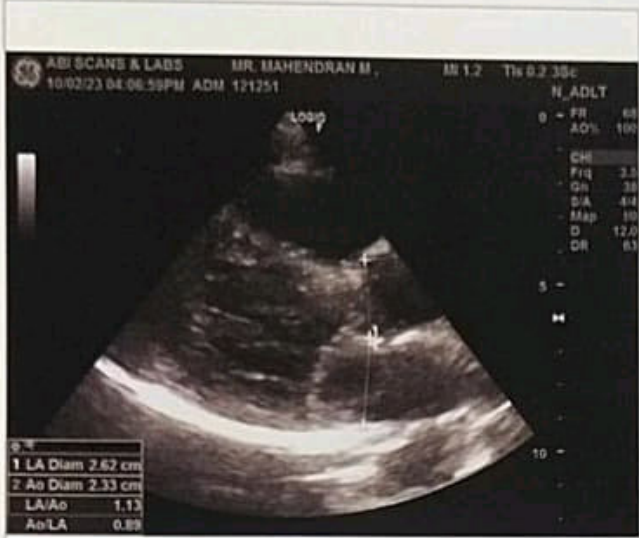Obli Towers, #594, D. B. Road - Cowley Brown Road Jn.,
Coimbatore - 641 002. Phone: 99430 99994

email: info@abiscans.com

www.abiscans.com

ABI SCANS & LABS COMBATORE

MR. MAHENDRAN M 30Y/M 121251 10-Feb-2023 04:06:02 PM Physician Name





ABI SCANS & LABS

A unit of Aarthi Scans and Labs

Patient Name	MR. MAHENDRAN M	Age	30Yr
Patient ID	121251	Sex	Male
Referral Dr	MEDIWHEEL	Study Date	10 Feb 2023

USG REPORT - ABDOMEN AND PELVIS

LIVER:

Is normal in size ~ 13.4 cm and shows normal echo texture.

No obvious focal lesion seen. No intra – Hepatic biliary radical dilatation seen.

GALL BLADDER:

Is adequately distended.

Calculus measuring ~ 1.5 cm seen with in the lumen of gall bladder. Wall thickness is normal (measures ~2mm). No evidence of pericholecystic fluid.

PANCREAS:

Appears normal in size and it shows uniform echo texture.

SPLEEN:

Is normal in size ~ 10 cm and shows uniform echogenicity.

RIGHT KIDNEY:

Right kidney measures ~ 10.2 x 4.1 cms.

The shape, size and contour of the right kidney appear normal.

Cortico medullary differentiation is within normal. No evidence of pelvicalyceal dilatation.

No calculi seen.

LEFT KIDNEY:

Left kidney measures ~ 9.3 x 4.2 cms.

The shape, size and contour of the left kidney appear normal.

Cortico medullary differentiation is within normal. No evidence of pelvicalyceal dilatation.

No calculi seen.

URINARY BLADDER:

Is normal contour. No intra luminal echoes are seen.

PROSTATE:

Prostate appears normal, Measures ~ 2.9 x 3.3 x 2.6 cms (Vol – 13 cc).



ABI SCANS & LABS

A unit of Aarthi Scans and Labs

Patient Name	MR. MAHENDRAN M	Age	30Yr
Patient ID	121251	Sex	Male
Referral Dr	MEDIWHEEL	Study Date	10 Feb 2023

RIGHT ILIAC FOSSA:

No focal fluid collections seen.

No evidence of hernia seen in anterior abdominal wall.

IMPRESSION:

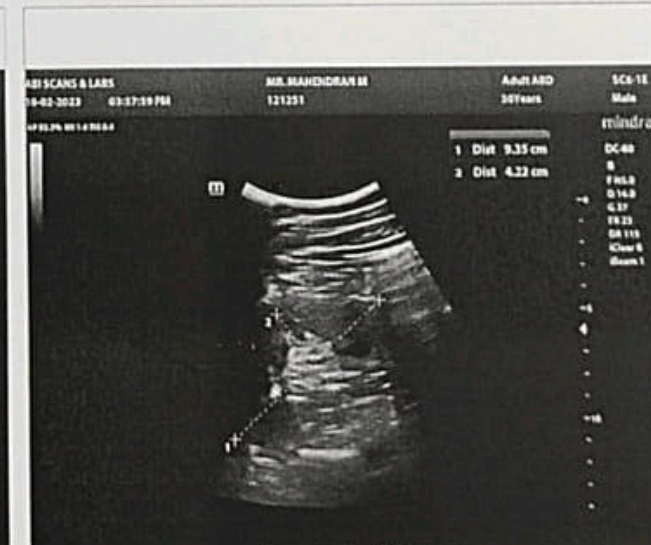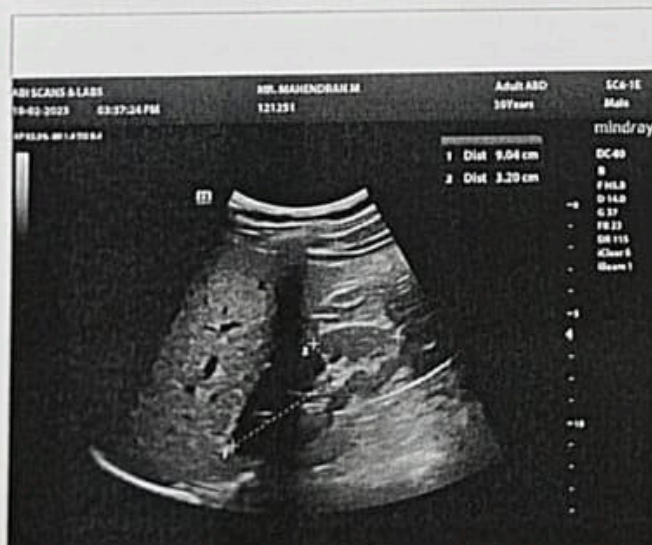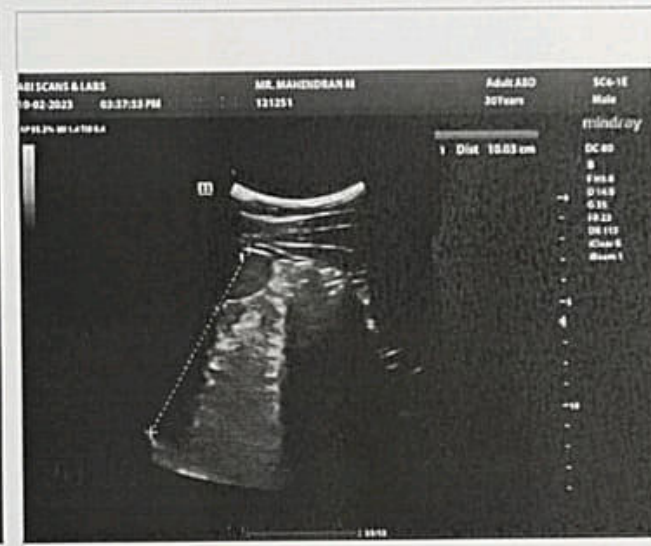
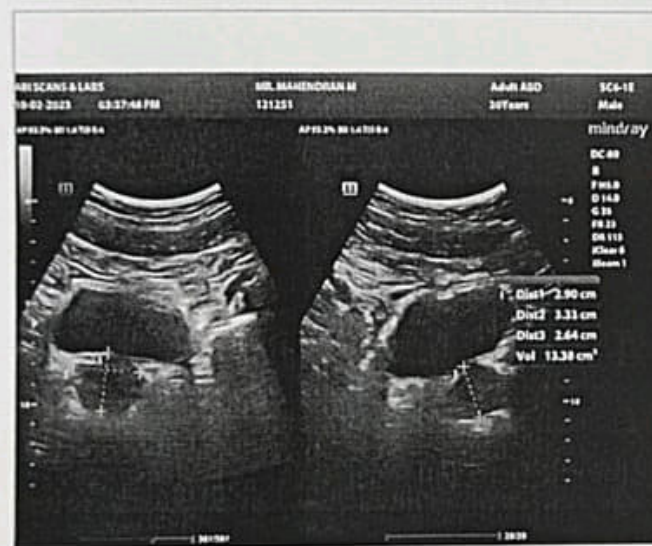
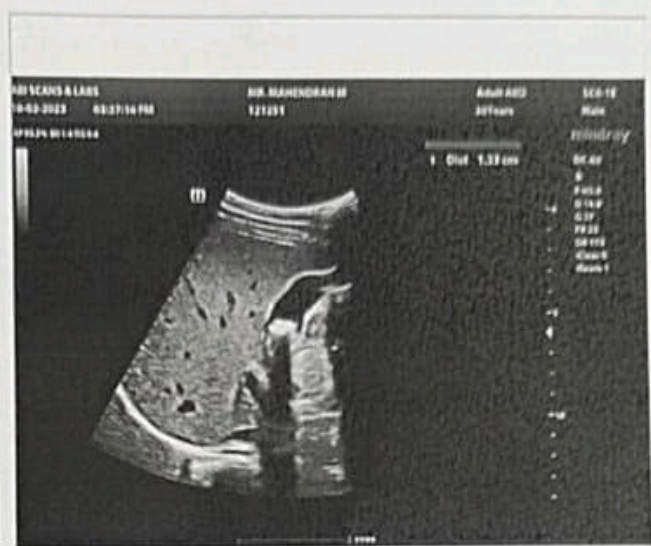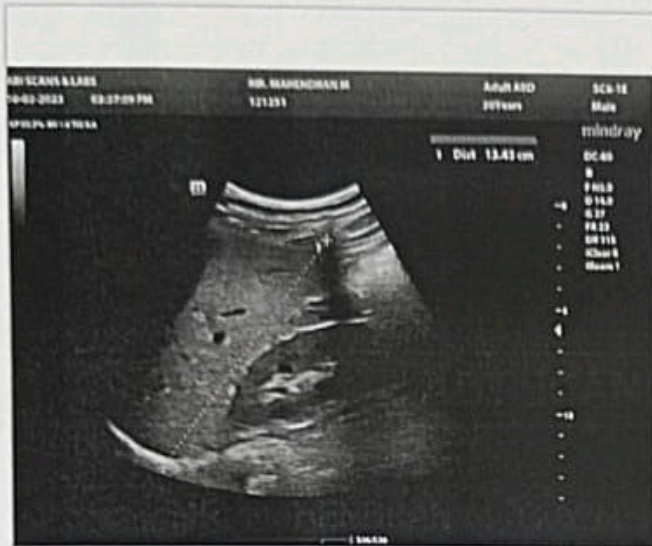- Grade I fatty liver.
 - Cholelithiasis. No evidence of cholecystitis.
- Suggested clinical correlation.

Dr. Abinaya., MD., (RD)
Consultant Radiologist

*Dr. Abinaya Rajasekaran, MD., RD.,
Reg. No: 119338*

ABI SCANS AND LABS

MR. MAHENDRAN M 030Y/M 121251 10-Feb-2023 09:37:10 AM





ABI SCANS & LABS

A unit of Aarthi Scans and Labs

Patient Name	MR.MAHENDRAN M	Age	30Yr
Patient ID	128010	Sex	Male
Referral Dr	MEDIWHEEL	Study Date	10 Feb 2023

X-RAY - CHEST PA VIEW

OBSERVATION:

The trachea is central.
The mediastinal and cardiac silhouette are normal.
Cardiothoracic ratio is normal.
Cardiophrenic and costophrenic angles are normal.
Both hila are normal.
Lung zones are clear.
Bones of the thoracic cage are normal.
Soft tissues of the chest wall are normal.

IMPRESSION:

No significant abnormality seen.

Dr. Abinaya., MD., (RD)
Consultant Radiologist